

ONEPLUS ULTRASOUND LAB
47, Harsh Vihar, Pitam Pura,
Delhi-110034
Ph. 011-42480101, 9559913051
E-mail: onepiusul@gmail.com

DR. NITIN AGARWAL
MBBS, MD
Regn. No. DMC-R-1436

भारतीय विशिष्ट पहचान प्राधिकरण
Unique Identification Authority of India

पता:
संबोधित: राजेश अग्निहोत्री, मकान न-137-138 ऊपरी भूतल
सेक्टर 24 रोहिणी उत्तर पश्चिम दिल्ली दिल्ली 110085

Address:
S/O: Rajesh Agnihotri, H No-137-138 Upper
Ground Floor Pocket-7, Sector 24 Rohini,
North West Delhi, Delhi 110085

Download Date: 07/01/2015

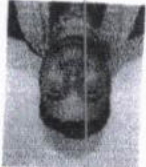


9972 5792 9687
VID : 9124 0175 7501 7043

1947 | help@uidai.gov.in | www.uidai.gov.in

भारत सरकार, श्री परमेश्वर

9972 5792 9687
VID : 9124 0175 7501 7043



प्रा अग्निहोत्री
Dhruv Agnihotri
प्रा/DOB: 12/12/1988
प्रा/ MALE

भारत सरकार
Government of India

Issue Date: 17/01/2015

ONEPLUS ULTRASOUND LAB
47, Harsh Vihar, Pitam Pura,
Delhi-110034
Ph: 011-42480101, 959913051
E-mail: oneplusul@gmail.com

DR. NITIN AGARWAL
MBBS, MD
Regn. No. DMC-R-1436





OnePLUS
Ultrasound Lab
— QUALITY FIRST... ALWAYS!

Dr. Nitin Agarwal | Pathologist & Director
EX. Sr. Res. MAMC & Lok Nayak Hospital
EX. Chief of Lab Dr. Lal Path Labs.

Dr. Pooja (Garg) Agarwal | Radiologist & Director
MAMC & Lok Nayak Hospital

Date - 15-04-2027

To, One Plus Ultrasound Lab,
Harsh Vihar, Pitampura,

Dear Sir,
Subject: Do not with to go for
stool test and post lunch
collection.

As per subject, I, Dr. Nitin Agarwal
do not with to go for
stool test and post lunch
sample collection.

DR. NITIN AGARWAL
MBBS, MD
Regn. No. DMC-R-1436

Regards
~~Dr. Nitin Agarwal~~
(Dr. Nitin Agarwal)
Bani of Baroda
ETN - 104995
Mobile - 9140137520

47, Harsh Vihar, Pitampura, New Delhi-110034 | Ph.: 011-42480101, 9599913051
E-mail: onepiusul@gmail.com | Web.: www.onepiusul.in

Clinical correlation is essential for final diagnosis. • If test results are unsatisfactory please contact personally or on phone. • This report is for perusal of doctors only. • All disputes Subject to Delhi Jurisdiction only. • Not for medicolegal purposes. • All congenital anomalies in a foetus may not be diagnosed in routine obstetric ultrasound.

ONEPLUS ULTRASOUND LAB

47, HARSH VIHAR, PITAMPURA, DELHI- 110034

Mr. DHRUV AGNIHOTRI

Age: 35M

Ref. by: MEDIWHHEEL

Indication 1:

Indication 2:

Indication 3:

COMMENTS: Normal ECG.

ID: 2214

HVWT: 178/112

Recorded: 15-4-2023 8:43

Medication 1:

Medication 2:

Medication 3:

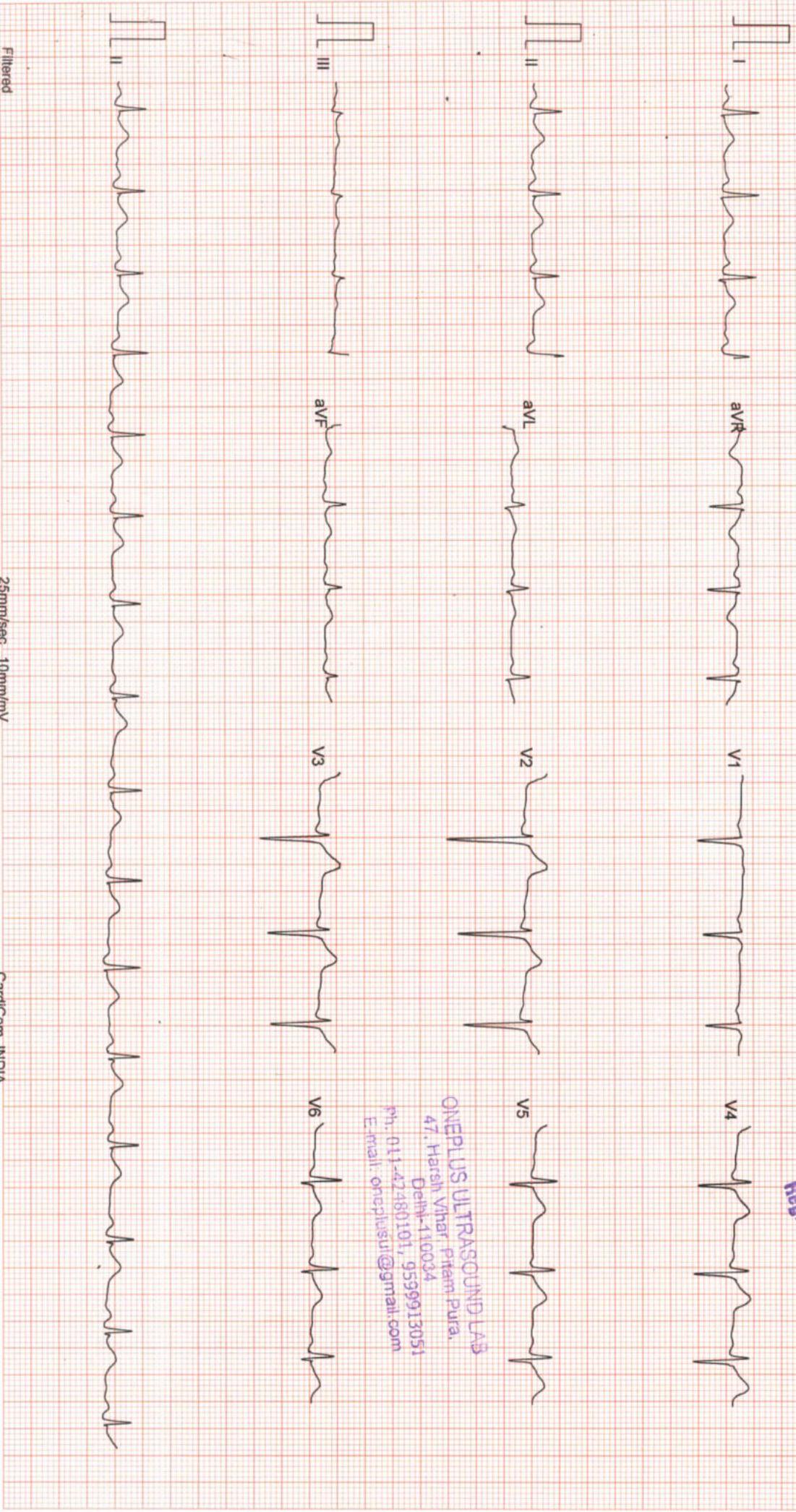
HR : 94
BP : 138/88
P Axis : 39 deg
QRS Axis : 33 deg
T Axis : 40 deg

P duration : 93 msec
PR duration : 136 msec
QRS duration : 103 msec
QT interval : 296 msec
QTc interval : 355 msec

Raw E.C.G. (Seq)

Unconfirmed Report Reviewed By:
Cardiologist

Dr. S. S. Mittal
MD
Reg. No. AIP-1071



Filtered

25mm/sec - 10mm/mV

CardiCom, INDIA

ONEPLUS ULTRASOUND LAB
47, Harsh Vihar Pitampura,
Delhi-110034
Ph: 011-47480101, 95399913051
E-mail: oneplusul@gmail.com

ONEPLUS ULTRASOUND LAB

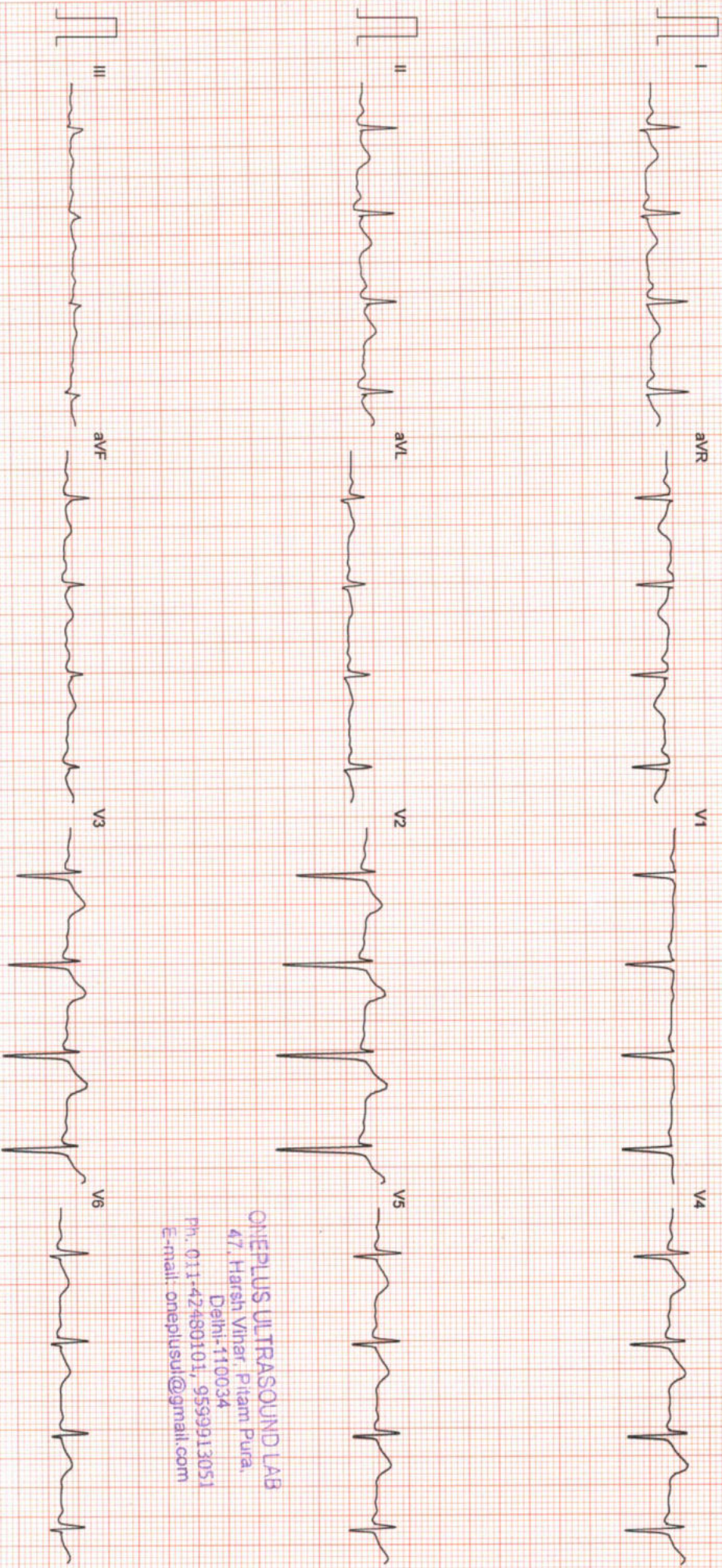
SUPINE
PRETEST

ST @ 10mm/mV
80ms PostJ

Mr. DHRUV AGNIHOTRI
I.D. : 995
AGE/SEX : 35/M
RECORDED : 15-4-2023 8:46

RATE : 98 BPM
B.P. : 138/88 mmHg

RAW E.C.G.



ONEPLUS ULTRASOUND LAB
47, Harsh Vilnar, Pitam Pura,
Delhi-110034
Ph. 011-42480101, 9599913051
E-mail: oneplusul@gmail.com

Filtered

25mm/Sec 10mm/mV

CardiCom, INDIA Ph.:091-731-2620740, Telefax:091-731-2431214

ONEPLUS ULTRASOUND LAB

47, HARSH VIHAR PITAMPURA DELHI 110034

Mr. DHIRUV AGNIHOTRI

Age/Sex : 35M
Ref. by : MEDIVHEEL

Indication1 :
Indication2 :
Indication3 :

ID : 995
HWT : 178/112
Recorded : 15-4-2023 8:46

TREADMILL TEST SUMMARY REPORT
Protocol: BRUCE
History:
Medication1 :
Medication2 :
Medication3 :

PHASE	PHASE TIME	STAGE TIME	SPEED (Km./Hr.)	GRADE (%)	H.R. (BPM)	B.P. (mmHg)	RPP X100	II	ST LEVEL (mm) V2	V5	METS
SUPINE STANDING					98	138/88	135	1.7	2.5	1.9	
					96	138/88	132	1.8	2.5	1.9	
STAGE 1	2:59	2:59	2.70	10.00	135	138/88	186	1.8	3.4	2.5	4.80
STAGE 2	5:59	2:59	4.00	12.00	162	150/90	243	1.4	3.3	2.3	7.10
STAGE 3	6:29	0:29	5.40	14.00	174	160/94	278	1.6	3.1	2.5	7.57
PEAK EXER	6:31	0:31			176	160/94	281	1.2	2.8	2.3	
RECOVERY	2:59	2:59	0.00	0.00	110	138/88	151	1.3	2.0	1.5	7.60

RESULTS

Exercise Duration : 6:31 Minutes
Max Heart Rate : 176 bpm 95 % of target heart rate 185 bpm
Max Blood Pressure : 160/94 mmHg
Max Work Load : 7.60 METS
Reason of Termination :

Stop for skill test

IMPRESSIONS

Dr. P. K. GUPTA
M.B.B.S., MD
Reg. No-1071
Cardiologist



ONEPLUS ULTRASOUND LAB
47, Harsh Vihar Pitam Pura
Delhi-110034
Ph: 011-42250101, 9599913051
E-mail: oneplusul@gmail.com

ONEPLUS ULTRASOUND LAB

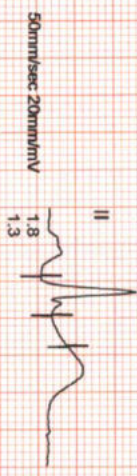
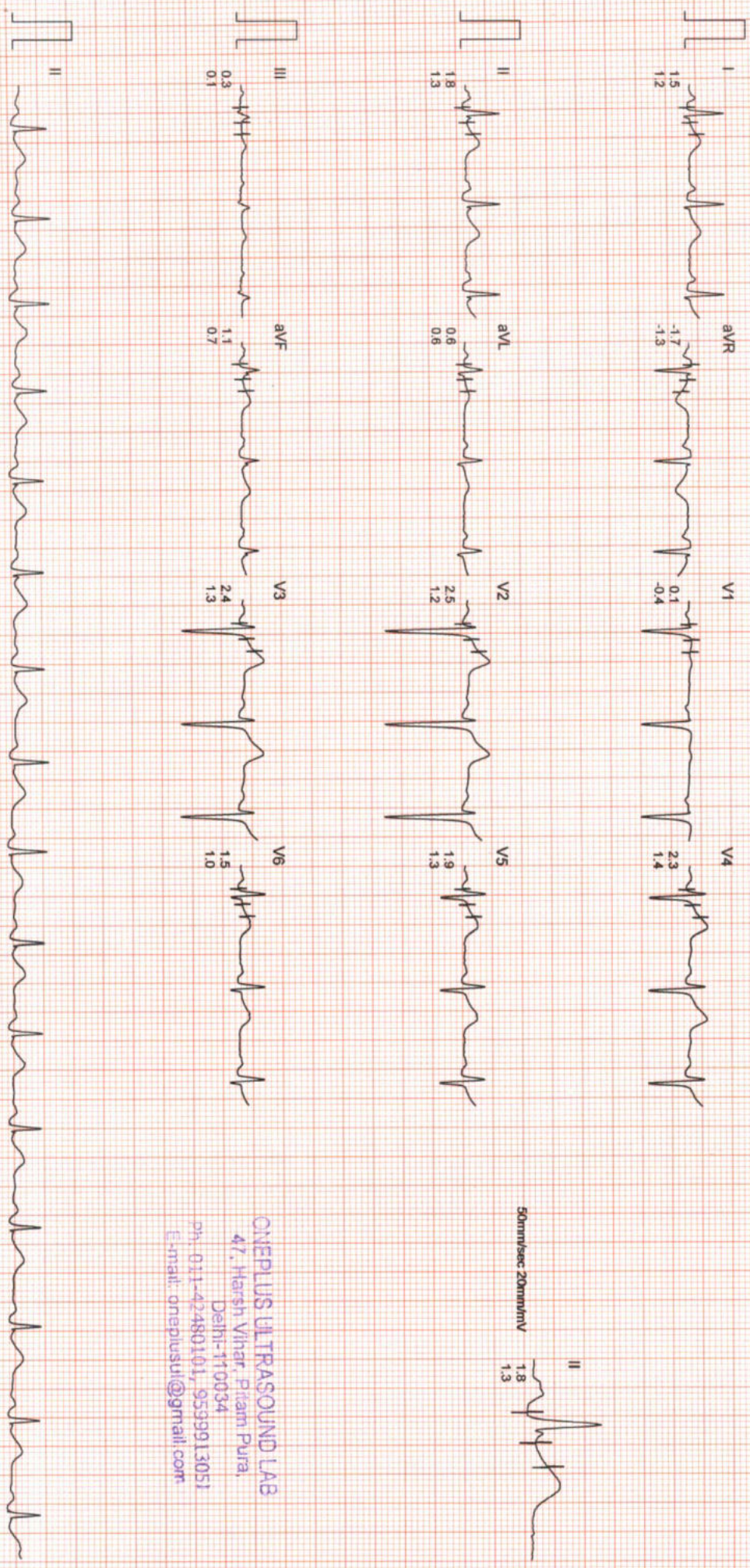
STANDING
PRETEST

ST @ 10mm/mV
80ms PostJ

Mr. DHRUV AGNIHOTRI
I.D. : 995
AGE/SEX : 35/M

RATE : 96 BPM
B.P. : 138/88 mmHg

LINKED MEDIUM



ONEPLUS ULTRASOUND LAB
47, Harsh Vihar, Pitam Pura,
Delhi-110034
Ph: 011-42480101, 9539913051
E-mail: oneplusul@gmail.com

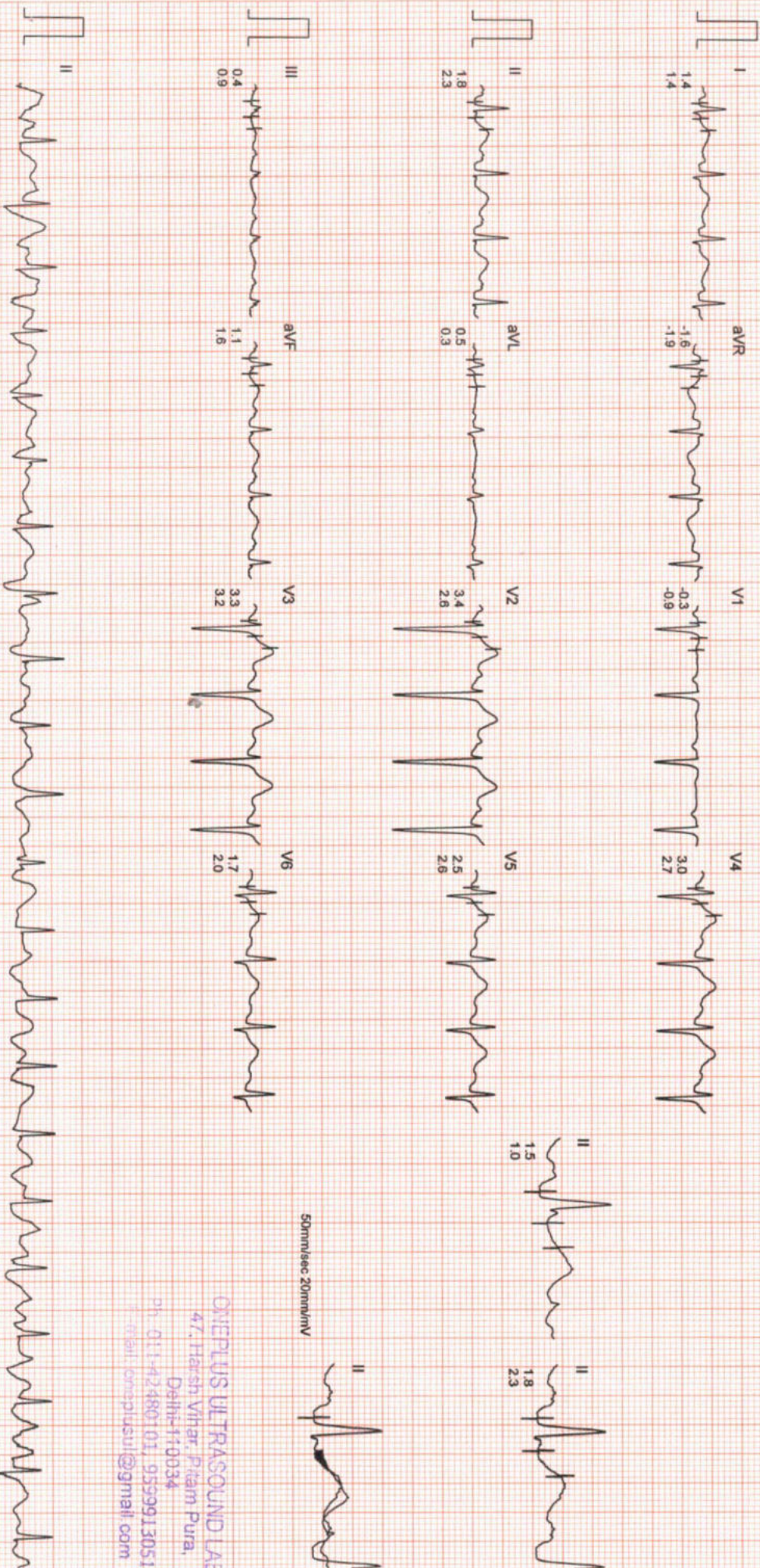
ONEPLUS ULTRASOUND LAB

Mr. DHRUV AGNIHOTRI
I.D. : 995
AGE/SEX : 35/M
RECORDED : 15-4-20 3 8:46

RATE : 135 BPM
B.P. : 138/88 mmHg

BRUCE
EXERCISE 1
PHASE TIME : 2:59
STAGE TIME : 2:59

ST @ 10mm/mV
80ms PostJ
SPEED : 2.7 Km./Hr.
GRADE : 10.0 %
LINKED MEDIAN



ONEPLUS ULTRASOUND LAB
47, Hersh Vihar, Patam Pura,
Delhi-110034
Ph. 011-42480101, 9599913051
Email: oneplusul@gmail.com

Filtered Computer-Corrected Baseline

25mm/sec 10mm/mV

CardiCom, INDIA Ph.:091-731-2620740, Telefax:091-731-2431214

ONEPLUS ULTRASOUND LAB

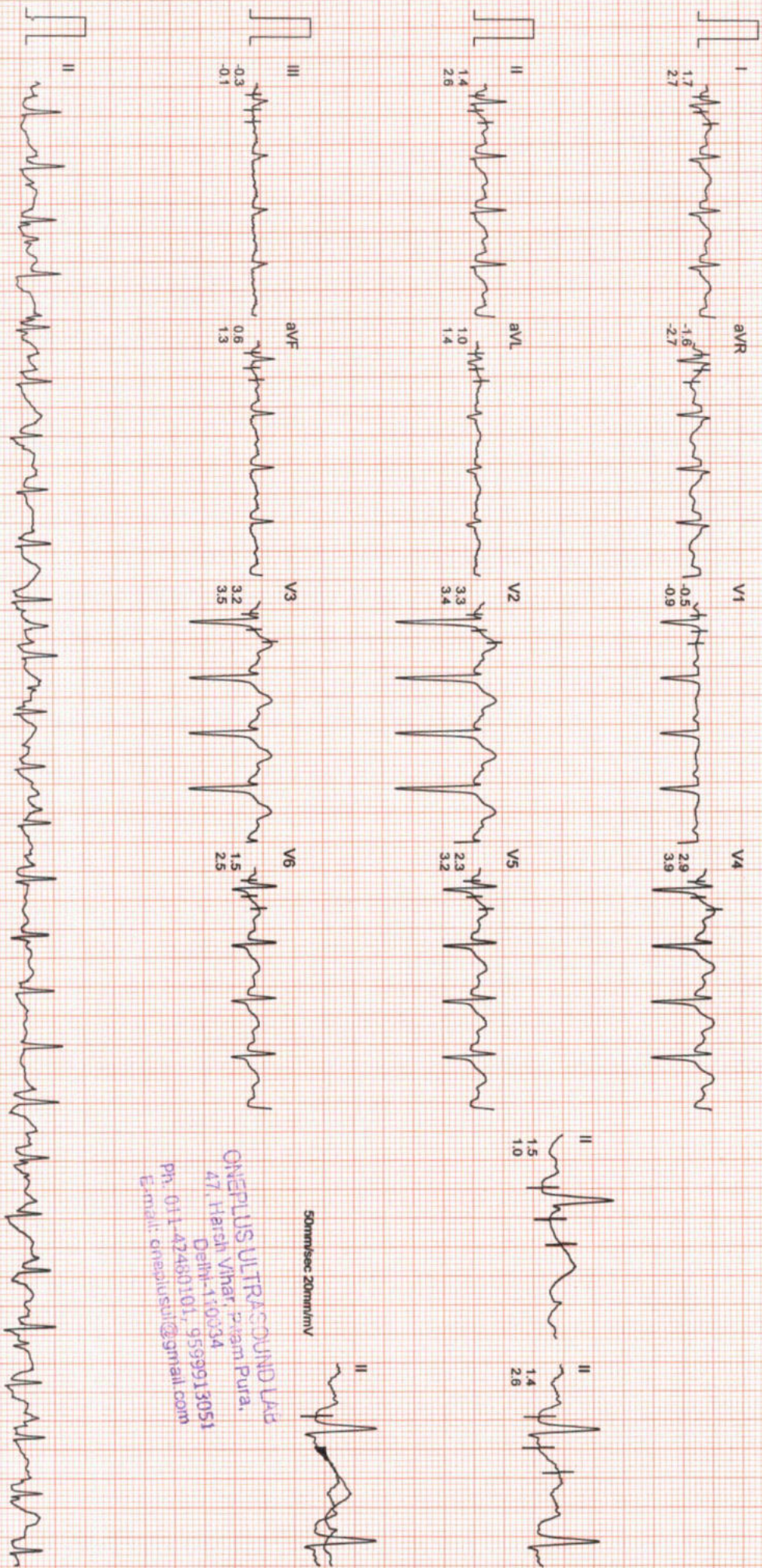
Mr. DHRUV AGNIHOTRI
I.D. : 995
AGE/SEX : 35/M
RECORDED : 15-4-2023 8:46

RATE : 162 BPM
B.P. : 150/90 mmHg

BRUCE
EXERCISE 2
PHASE TIME : 5:59
STAGE TIME : 2:59

ST @ 10mm/mV
80ms PostJ
SPEED : 4.0 Km./Hr.
GRADE : 12.0 %

LINKED MEDIAN



50mm/sec 20mm/mV
ONEPLUS ULTRASOUND LAB
47, Harsh Vihar, 2yam Pura,
Delhi-110034
Ph: 011-42480101, 9599913051
E-mail: oneplusul@gmail.com

ONEPLUS ULTRASOUND LAB

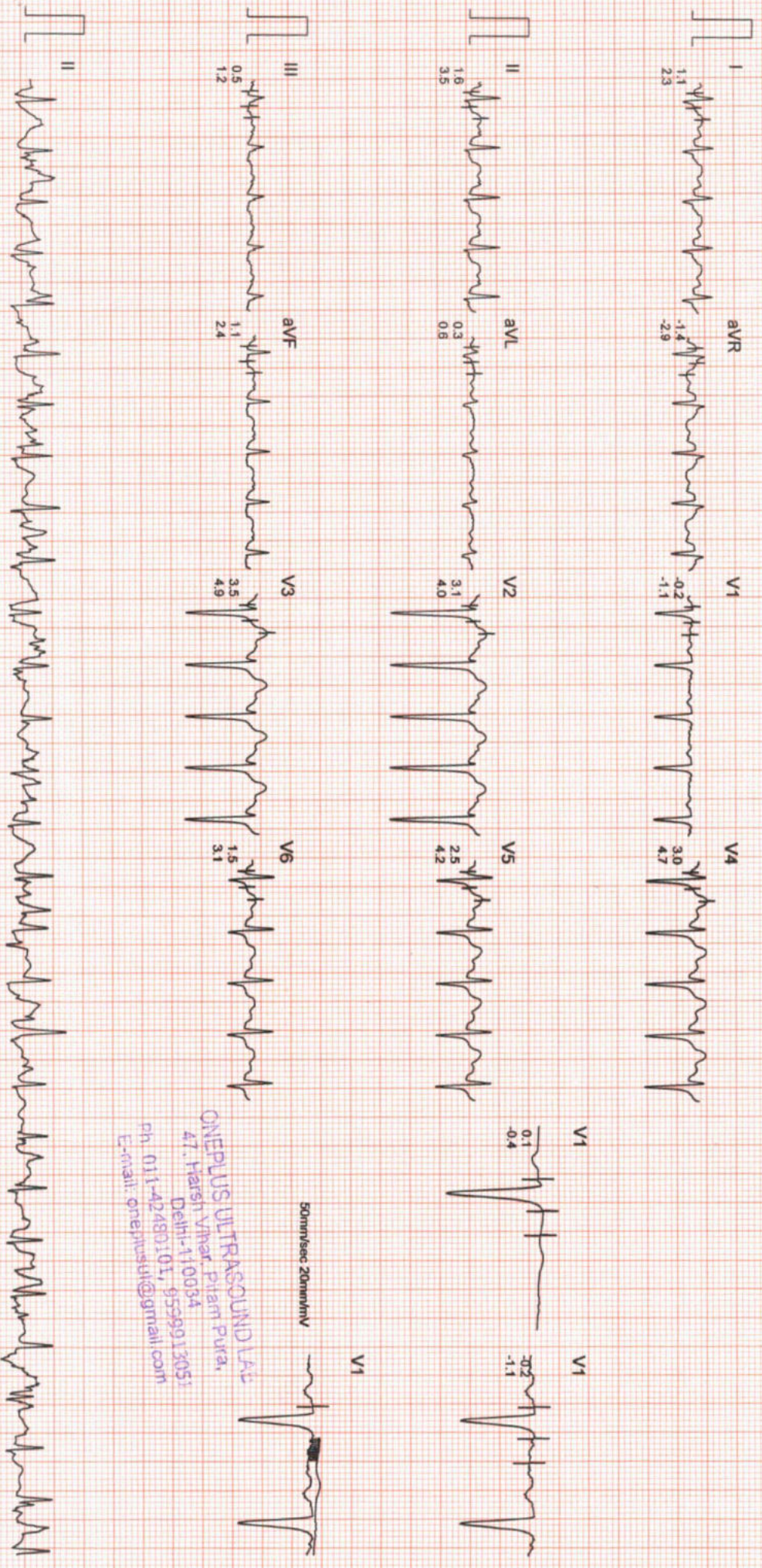
Mr. DHRUV AGNIHOTRI
 ID : 995
 AGE/SEX : 35/M
 RECORDED : 15-4-2023 8:46

RATE : 174 BPM
 B.P. : 160/94 mmHg

BRUCE
 EXERCISE 3
 PHASE TIME : 6:29
 STAGE TIME : 0:29

ST @ 10mm/mV
 80ms PostJ
 SPEED : 5.4 Km./Hr.
 GRADE : 14.0 %

LINKED MEDIAN



ONEPLUS ULTRASOUND LAB
 47, Harsh Vihar, Piam Pura,
 Delhi-110034
 Ph. 011-42480101, 9599913053
 Email: oneplusul@gmail.com

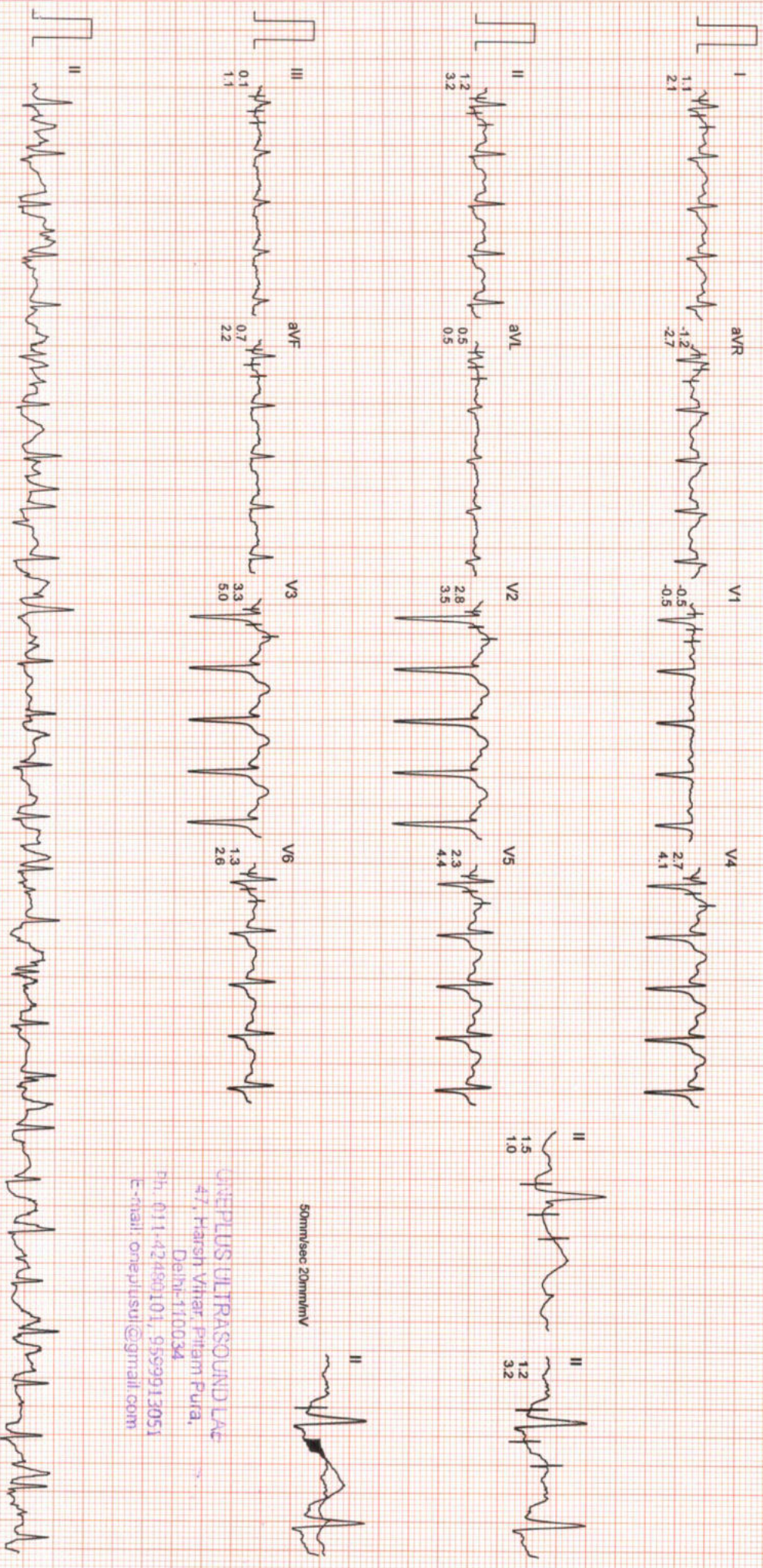
ONEPLUS ULTRASOUND LAB

Mr. DHRUV AGNIHOTRI
 I.D. : 995
 AGE/SEX : 35/M
 RECORDED : 15-4-2023 8:4

RATE : 176 BPM
 S.P. : 160/94 mmHg

BRUCE
 PEAK EXER
 PHASE TIME : 6:31
 STAGE TIME : 0:31

ST @ 10mm/mV
 80ms PostJ
 SPEED : 5.4 Km/Hr.
 GRADE : 14.0 %
 LINKED MEDIAN



ONEPLUS ULTRASOUND LAB
 47, Harsh Vihar, Pitam Pura,
 Delhi-110034
 Ph: 011-42480101, 9859913051
 E-mail: oneplusul@gmail.com

ONEPLUS ULTRASOUND LAB

BRUCE

RECOVERY

PHASE TIME : 2:59

ST @ 10mm/mV

80ms PostJ

SPEED : 0.0 Km./Hr.

GRADE : 0.0 %

LINKED MEDIAN

Mr. DHIRUV AGNIHOTRI

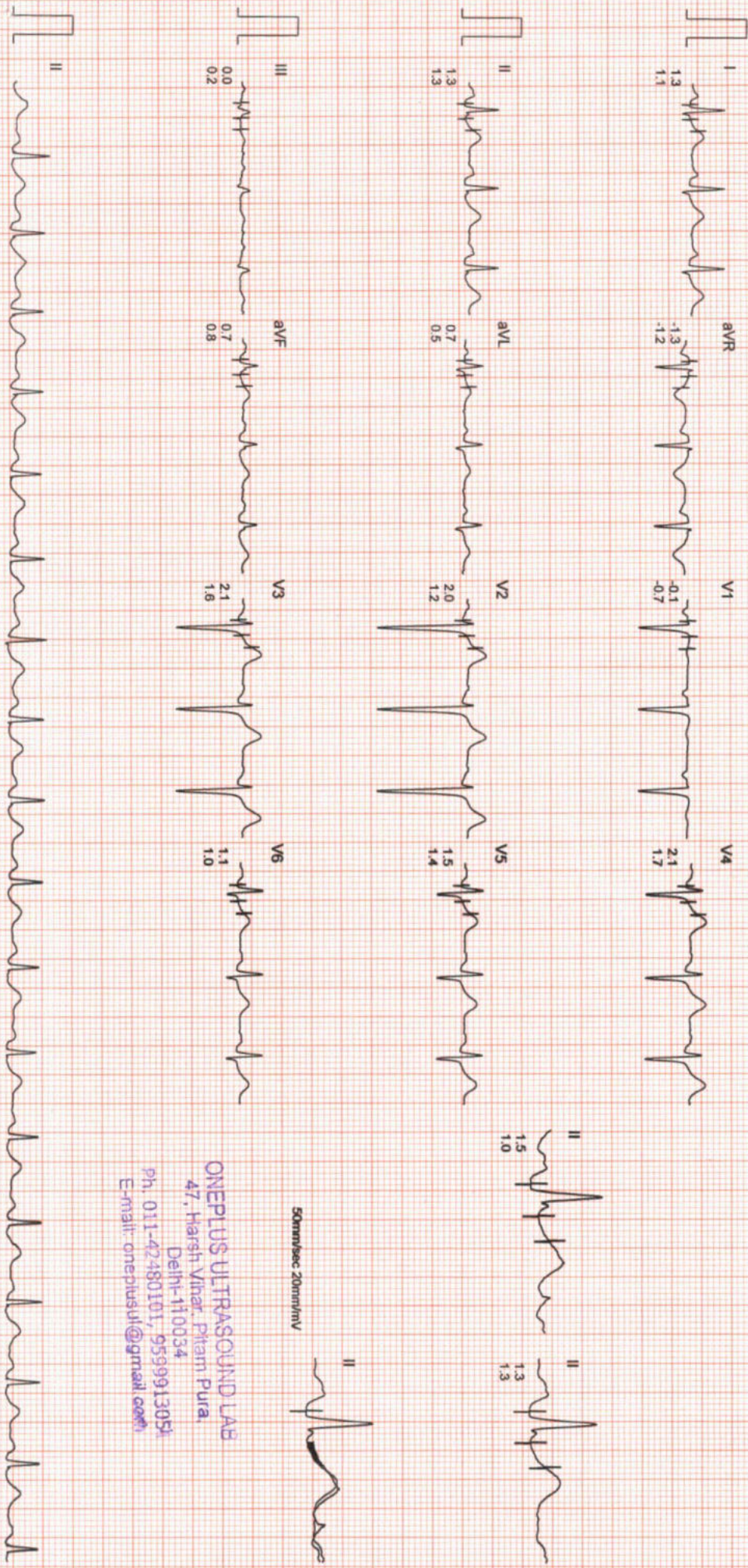
I.D. : 995

AGE/SEX : 35/M

RECORDED : 15-4-2023 8:46

RATE : 110 BPM

B.P. : 139/88 mmHg



50mm/sec 20mm/mV

ONEPLUS ULTRASOUND LAB
47, Harsh Vihar, Pitam Pura,
Delhi-110034
Ph. 011-42480101, 9599913051
E-mail: oneplusul@gmail.com

Filtered

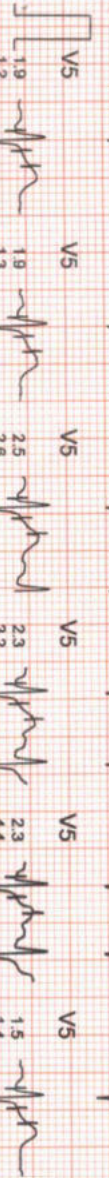
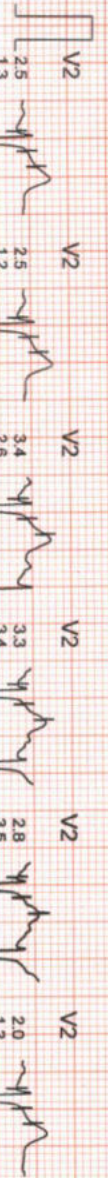
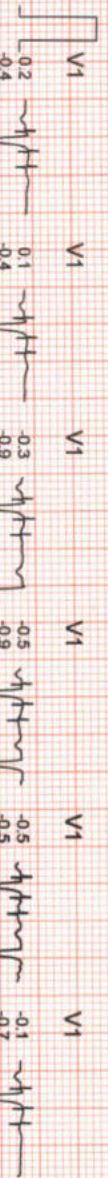
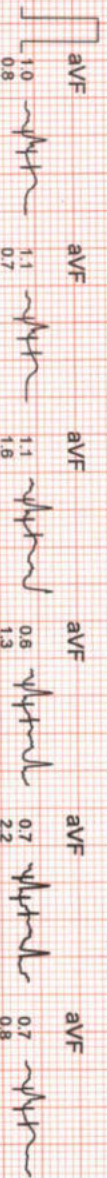
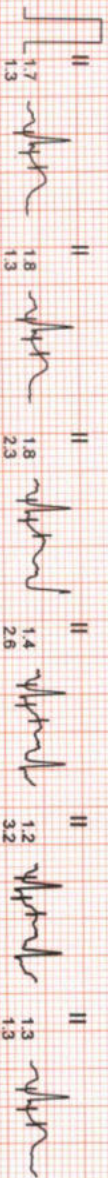
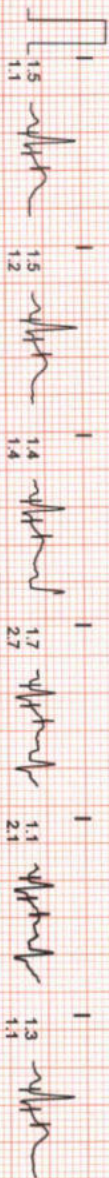
Computer-Corrected Baseline

25mm/sec 10mm/mV

CardiCom, INDIA Ph.:091-731-2620740, TeleFax:091-731-2431214

ONEPLUS ULTRASOUND LAB

STAGE	STAGE 1	STAGE 2	PEAK EXERCISE	RECOVERY
SUPINE	STANDING	STAGE 1	PEAK EXERCISE	RECOVERY
0.0Kmph 0.0%	0.0Kmph 0.0%	2.7Kmph 10.0%	6.31 0.31	2:59
98 bpm	96 bpm	136 bpm	5.4Kmph 14.0%	0.0Kmph 0.0%
B.P. 138/88	B.P. 138/88	B.P. 150/90	176 bpm	110 bpm
80ms Post	80ms Post	80ms Post	B.P. 160/94	B.P. 138/88
			80ms Post	90ms Post



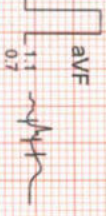
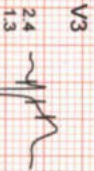


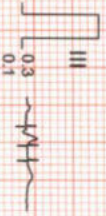
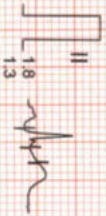
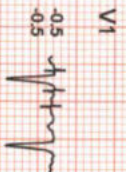
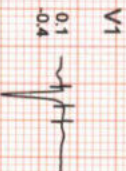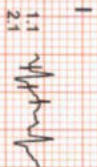
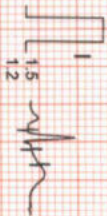
ONEPLUS ULTRASOUND LAB
 47, Harsh Vihar, Pitam, Pura,
 Delhi-110034
 Ph. 011-42480101, 9539913051
 E-mail: onepplusult@gmail.com

STANDING
0.0kmph
0.0%
96 bpm
B.P. 138/88
80ms PostU

PEAK EXERCISE
6:31
0:31
5.4kmph
14.0%
176 bpm
B.P. 160/94
80ms PostU

STANDING
0.0kmph
0.0%
96 bpm
B.P. 138/88
80ms PostU

PEAK EXERCISE
6:31
0:31
5.4kmph
14.0%
176 bpm
B.P. 160/94
80ms PostU



ONEPLUS ULTRASOUND LAB
47, Harsh Vihar, Pitam Pura,
Delhi-110034
Ph. 011-42480101, 9599913051
E-mail: onepplusul@gmail.com



OnePLUS
Ultrasound Lab
— QUALITY FIRST... ALWAYS! —

Dr. Nitin Agarwal Pathologist & Director
Ex. Sr. Res. MAMC & Lok Nayak Hospital
Ex. Chief of Lab Dr. Lal Path Labs.

Dr. Pooja (Garg) Agarwal Radiologist & Director
MAMC & Lok Nayak Hospital

NAME	: Mr. AGNIHOTRI DHRUV	Barcode No	: 10142594
AGE/GENDER	: 35 YRS/Male	SPECIMEN DATE	: 15/Apr/2023 08:28AM
PATIENT ID	: 112653	SPECIMEN RECEIVED	: 15/Apr/2023 11:22AM
REFERRED BY	: Dr. MEDIWHEEL	REPORT DATE	: 15/Apr/2023 01:46PM
CENTRE NAME	: ONEPLUS ULTRASOUND LAB	LAB NO.	: 012304150001



HAEMATOLOGY

Medi Wheel Health checkup < 40 Male

Glycosylated Hemoglobin (HbA1c)

5.6

%

Non Diabetic adults <5.7
Prediabetic (at risk) 5.7-6.4
Diabetes >6.4

Estimated average blood glucose (eag)

114

Reference range (mg/dl):

90 - 120: Excellent control, 121 - 150: Good Control, 151 - 180: Average Control, 181 - 210: Action Suggested >211: Panic value

BLOOD GROUP (ABO)

A

Rh typing

POSITIVE

NOTE :

- * Apart from major A,B,H antigens which are used for ABO grouping and Rh typing, many minor blood group antigens exist. Agglutination may also vary according to titre of antigen and antibody.
- * So before transfusion, reconfirmation of blood group as well as cross-matching is needed.
- * Presence of maternal antibodies in newborns, may interfere with blood grouping.
- * Auto agglutination (due to cold antibody, falciparum malaria, sepsis, internal malignancy etc.) may also cause erroneous result.

CBC

Haemoglobin	13.0	g/dl	13.0-17.0
Total Leucocyte Count	10000	/cumm	4000-10000
Differential leucocyte count			
Neutrophils	70.1	%	40-80
Lymphocyte	26.10	%	20-40
Monocytes	2.00	%	2-10
Eosinophils	1.0	%	1-6
Basophils	0.8	%	0-2
RBC Count	4.80	million/cumm	4.5 - 5.5

Checked By:

DR. NITIN AGARWAL
MBBS, MD
Regn. No. DMCB-5436

DR. NITIN AGARWAL
MBBS, MD (PATHOLOGIST)

47, Harsh Vihar, Pitampura, New Delhi-110034 | Ph.: 011-42480101, 9599913051

E-mail: onepplus@gmail.com | Web.: www.oneplusul.in

Page 1 of 5

Clinical correlation is essential for final diagnosis. * If test results are unsatisfactory please contact personally or on phone. * This report is for perusal of doctors only. * All disputes Subject to Delhi Jurisdiction only. * Not for medicolegal purposes. * All congenital anomalies in a fetus may not be diagnosed in routine obstetric ultrasound.



OnePLUS
Ultrasound Lab
— QUALITY FIRST... ALWAYS —

Dr. Nitin Agarwal
Pathologist & Director
Ex. Sr. Res. MAMC
& Lok Nayak Hospital
Ex. Chief of Lab Dr. Lal Path Labs.

Dr. Pooja (Garg) Agarwal
Radiologist & Director
MAMC & Lok Nayak Hospital

NAME	:MR. AGNIHOTRI DHRUV		
AGE/GENDER	:35 YRS/Male		
PATIENT ID	:112653		
REFERRED BY	:DR. MEDIWHEEL		
CENTRE NAME	:ONEPLUS ULTRASOUND LAB		
LAB NO.	:10142594		
SPECIMEN DATE	:15/Apr/2023 08:28AM		
SPECIMEN RECEIVED	:15/Apr/2023 11:22AM		
REPORT DATE	:15/Apr/2023 01:46PM		
	:012304150001		



Test Name	Result	Unit	Ref. Range
-----------	--------	------	------------

PCV(Hematocrit)	44.1	%	40-50
MCV	91.7	fL	83-101
MCH	27.1	Pg	27-32
MCHC	29.6	G/dL	32-35
RDW-CV	15.5	%	11.4-14.0
Platelet count	263000	/cumm	150000-450000

BIOCHEMISTRY

Blood sugar fasting	114	mg/dL	70-110
Bun (blood urea nitrogen)	12.60	mg/dl	8.9-21.6
Uric acid, serum	4.6	mg/dl	3.5-7.2
Creatinine, serum	0.7	mg/dl	0.60-1.2

LFT(LIVER FUNCTION TEST)

Bilirubin Total	0.54	mg/dl	0.1-1.2
Bilirubin Conjugated	0.23	mg/dl	0-0.4
Bilirubin Unconjugated	0.31	mg/dl	up to 0.7
SGOT (AST)	33	U/L	0-46
SGPT (ALT)	42	U/L	0-49
Alkaline phosphatase	105	U/L	40-129
Gamma glutamyl transpeptidase	27	U/L	10-45
Total Protein	7.4	g/dl	6.60 - 8.70
Albumin serum	4.6	g/dL	3.0-5.2
Globulin	2.80	g/dl	1.8-3.4
Albumin/Globulin Ratio	1.64		1.10 - 2.50

LIPID PROFILE

Cholesterol	161	mg/dl	50-200
Triglycerides	162	mg/dL	25-150
HDL Cholesterol	45	mg/dL	40 - 60
LDL cholesterol	84	mg/dL	<130

Checked By.

DR. NITIN AGARWAL
MBBS, MD
Regn. No. DMC-1436

DR. NITIN AGARWAL
MBBS, MD(PATHOLOGIST)

47, Harsh Vihar, Pitampura, New Delhi-110034 | Ph.: 011-42480101, 9599913051
E-mail: oneplusul@gmail.com | Web.: www.oneplusul.in



OnePLUS
Ultrasound Lab
— QUALITY FIRST... ALWAYS! —

Dr. Nitin Agarwal
Pathologist & Director
Ex. Sr. Res. MAMC
& Lok Nayak Hospital
Ex. Chief of Lab Dr. Lal Path Labs.
Dr. Pooja (Garg) Agarwal
Radiologist & Director
MAMC & Lok Nayak Hospital

NAME	: Mr. AGNIHOTRI DHRUV	Barcode No	: 10142594
AGE/GENDER	: 35 YRS/Male	SPECIMEN DATE	: 15/Apr/2023 08:28AM
PATIENT ID	: 112653	SPECIMEN RECEIVED	: 15/Apr/2023 11:22AM
REFERRED BY	: Dr. MEDIWHEEL	REPORT DATE	: 15/Apr/2023 01:46PM
CENTRE NAME	: ONEPLUS ULTRASOUND LAB	LAB NO.	: 012304150001

Test Name	Result	Unit	Ref. Range
-----------	--------	------	------------

VLDL cholesterol	32.4	mg/dL	5-40
Cholesterol/HDL Ratio	3.6		Low Risk 3.3-4.97 Average Risk 4.4-7.1 Moderate Risk 7.1-11.0 High Risk >11.0
LDL/HDL Ratio	1.9		0 - 3.55

According to ATP III and NCEP guidelines

Parameter	Normal	Desirable	Borderline	High
Total cholesterol	<200	200-239	240	
Triglycerides	<150	150-199	200-499	500
LDL	Optimal <100	130-159	160-180	190
HDL	Near Optimal 100-129			
	<40 : LOW 60 : HIGH			

BUN/Creatinine ratio			
Bun (blood urea nitrogen)	12.60	mg/dl	8.9-21.6
CREATININE	0.70	mg/dl	0.30-1.10
BUN/Creatinine ratio	18.00		10.0 - 20.0

THYROID PROFILE(T3,T4,TSH)			
Triiodothyronine total [t3]	0.84	ng/dl	0.52-1.9
Thyroxine total [t4]	7.60	µg/dl	4.4 - 10.8
TSH (Thyroid Stimulating Hormone)	4.10	µIU/ml	0.25-5.0

AGE WISE VARIATION IN TSH

AGE	TSH(µIU/ml)	AGE	TSH(µIU/ml)
1-4 weeks	1.00 - 19.0	16-20 yrs	0.25 - 5.0

Checked By.

DR. NITIN AGARWAL
MBBS, MD
Regn. No. DMC-R-1106

DR. NITIN AGARWAL
MBBS, MD(PATHOLOGIST)

47, Harsh Vihar, Pitampura, New Delhi-110034 | Ph.: 011-42480101, 9599913051
E-mail: onepusul@gmail.com | Web.: www.onepusul.in



OnePLUS
Ultrasound Lab

QUALITY FIRST... ALWAYS!

Dr. Pooja (Garg) Agarwal
Radiologist & Director
MAMC & Lok Nayak Hospital

Dr. Nitin Agarwal
Pathologist & Director
Ex. Sr. Res. MAMC
& Lok Nayak Hospital
Ex. Chief of Lab Dr. Lal Path Labs.

NAME	: Mr. AGNIHOTRI DHRUV	Barcode No	: 10142594
AGE/GENDER	: 35 YRS/Male	SPECIMEN DATE	: 15/Apr/2023 08:28AM
PATIENT ID	: 112653	SPECIMEN RECEIVED	: 15/Apr/2023 11:22AM
REFERRED BY	: Dr. MEDIWHEEL	REPORT DATE	: 15/Apr/2023 01:46PM
CENTRE NAME	: ONEPLUS ULTRASOUND LAB	LAB NO.	: 012304150001

Test Name	Result	Unit	Ref. Range
-----------	--------	------	------------

1-12 mths	1.70 - 9.1	21 - 80 yrs	0.25 - 5.0
1-5 yrs	0.80 - 8.2	1st trimester	0.25 - 5.0
6-10 yrs	0.25 - 5.0	II nd trimester	0.50 - 5.0
11-15 yrs	0.25 - 5.0	III rd trimester	0.4 - 6.0

Reference ranges - Interpretation of Diagnostic tests - (Jacques Wallach)

1. Primary hypothyroidism is accompanied by depressed serum T3 and T4 values and elevated serum TSH level.
2. Primary hyperthyroidism is accompanied by elevated serum T3 and T4 levels along with depressed TSH values.
3. Slightly elevated T3 levels may be found in pregnancy and estrogen therapy, while depressed levels may be encountered in severe illness, renal failure and during therapy with drugs like propranolol and propyl thiouracil.
4. Although elevated TSH levels are nearly always indicative of primary hypothyroidism, and may be seen in secondary thyrotoxicosis

CLINICAL PATHOLOGY
URINE ROUTINE

Physical examination

Quantity

20

Colour

PALE YELLOW

Transparency

CLEAR

Sp. gravity

1.015

pH

6.00

Reaction

ACIDIC

Chemical examination

Urine protein

NIL

Urine sugar

NIL

Bilirubin, urine

NEGATIVE

Urobilinogen

NORMAL

Ketones

NEGATIVE

Microscopic examination

Pus cells.

1-2

Epithelial cells

1-2

Checked By.

47, Harsh Vihar, Pitampura, New Delhi-110034 | Ph.: 011-42480101, 9599913051

E-mail: onepplus@gmail.com | Web.: www.oneplusul.in

DR. NITIN AGARWAL
MBBS,MD(PATHOLOGIST)

Regn. No. DMC-R-1436

DR. NITIN AGARWAL
MBBS, MD

0-2
NIL

/HPF
/HPF

NEGATIVE

NORMAL

NEGATIVE

NIL

NIL

ACIDIC

1.010-1.030

CLEAR

ML



OnePLUS
Ultrasound Lab
— QUALITY FIRST... ALWAYS! —

Dr. Nitin Agarwal
Pathologist & Director
Ex. Sr. Res. MAMC
& Lok Nayak Hospital
Ex. Chief of Lab Dr. Lal Path Labs.

Dr. Pooja (Garg) Agarwal
Radiologist & Director
MAMC & Lok Nayak Hospital



NAME	MR. AGNIHOTRI DHIRU
AGE/GENDER	35 YRS/Male
PATIENT ID	112653
REFERRED BY	DR. MEDIWHEEL
CENTRE NAME	ONEPLUS ULTRASOUND LAB
Barcode No	10142594
SPECIMEN DATE	15/Apr/2023 08:28AM
SPECIMEN RECEIVED	15/Apr/2023 11:22AM
REPORT DATE	15/Apr/2023 01:46PM
LAB NO.	012304150001

Test Name	Result	Unit	Ref. Range
R.B.C.	NIL	/HPF	NIL
Casts	NIL	/HPF	NIL
Crystals	NIL	/HPF	NIL
Bacteria	NIL	/HPF	NIL
Others.	NIL	/HPF	NIL

*** End Of Report ***

Checked By.

47, Harsh Vihar, Pitampura, New Delhi-110034 | Ph.: 011-42480101, 9599913051

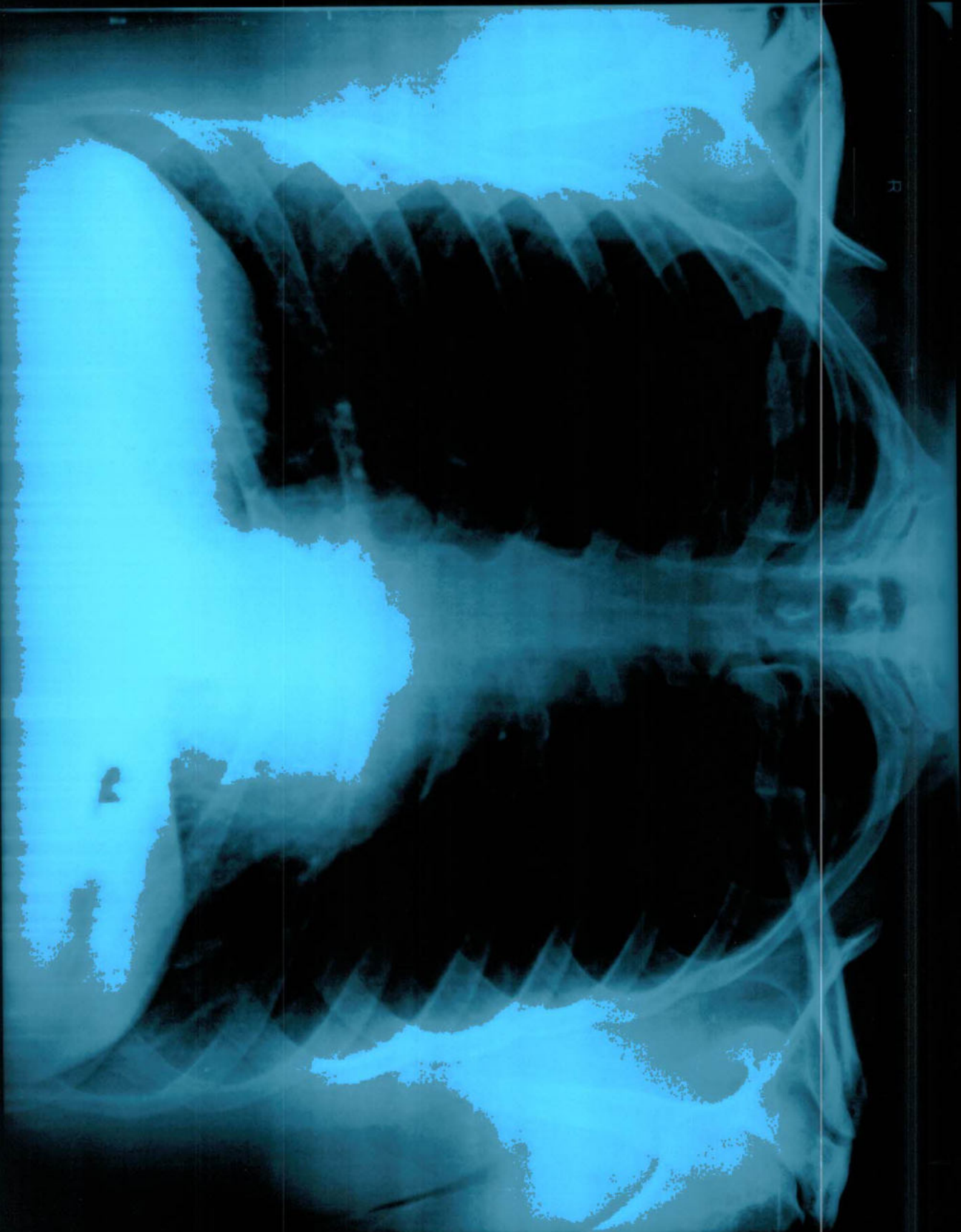
E-mail: oneplusul@gmail.com | Web.: www.oneplusul.in

Page 5 of 5

Clinical correlation is essential for final diagnosis. • If test results are unsatisfactory please contact personally or on phone. • This report is for perusal of doctors only. • All disputes Subject to Delhi Jurisdiction only. • Not for medicolegal purposes. • All congenital anomalies in a foetus may not be diagnosed in routine obstetric ultrasound.

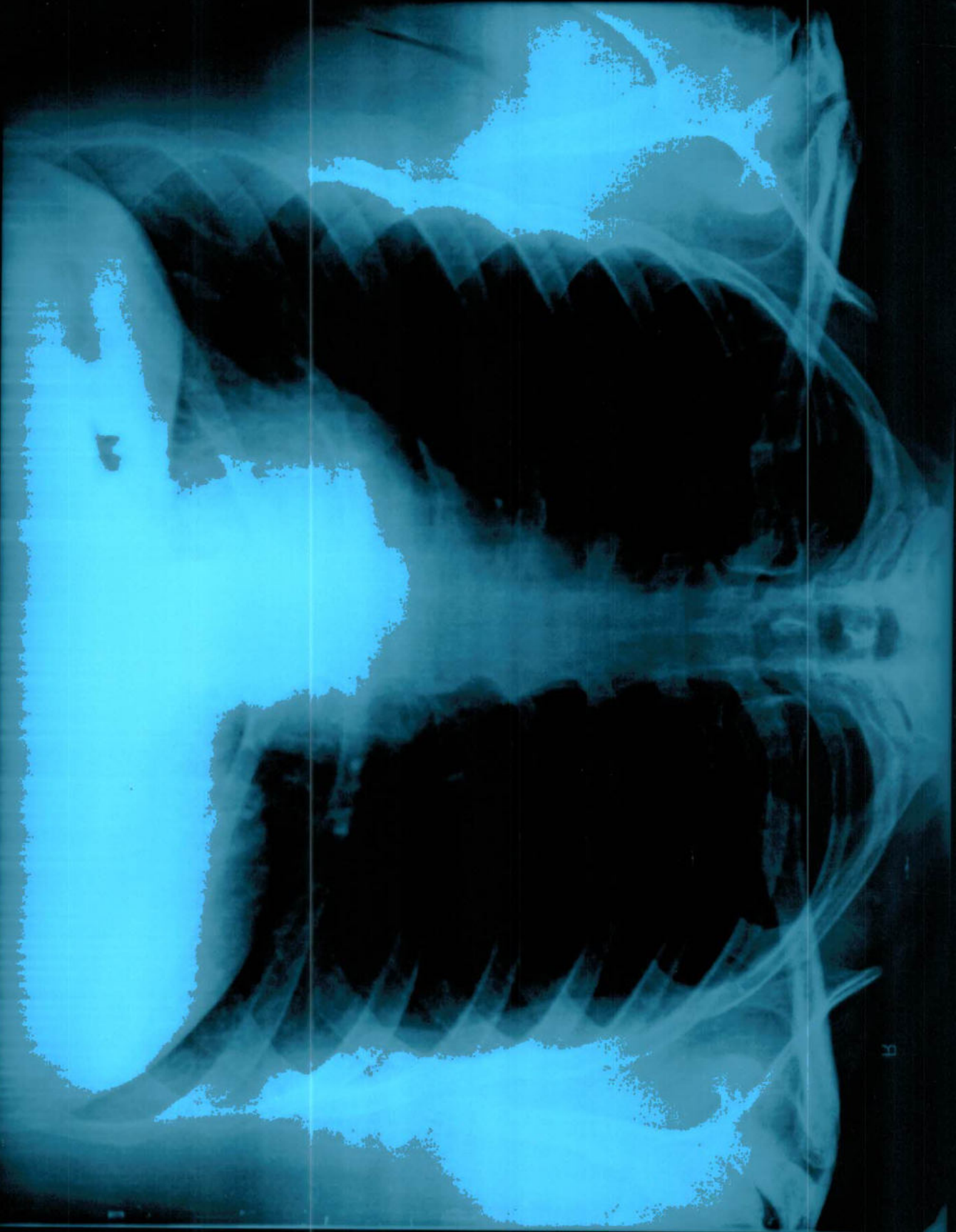
DR. NITIN AGARWAL
MBBS, MD (PATHOLOGIST)

DR. NITIN AGARWAL
MBBS, MD
Regn. No. DMC-R-1436



MR AGNIHOTRI DHIRUV 35 YRS 15/04/2023 M CHEST PA VIEW 4/15/2023
ONEPLUS ULTRASOUND LAB 47 HARSH VIHAR PITAMPURA

МІСЦЕ ПРОВІДЕННЯ ДІАГНОСТИЧНИХ ДІЙ: ПЕРІОДИЧНО ПОВТОРЮВАТИ
МІСЦЕ ПРОВІДЕННЯ ДІАГНОСТИЧНИХ ДІЙ: ПЕРІОДИЧНО ПОВТОРЮВАТИ



Р



OnePLUS
Ultrasound Lab
— QUALITY FIRST... ALWAYS! —

Dr. Nitin Agarwal
Pathologist & Director
Ex. Sr. Res. MAMC
& Lok Nayak Hospital
Ex. Chief of Lab Dr. Lal Path Labs.

Dr. Pooja (Garg) Agarwal
Radiologist & Director
MAMC & Lok Nayak Hospital

Name	: Mr. AGNIHOTRI DHRUV
Ref. By	: Dr. MEDIWHEEL
Date	: 15-Apr-2023
Age/Sex	: 35 YRS/Male
Lab No	: 012304150001
Patient ID	: LSHH112653

X-ray-Chest PA view

Bony cage and soft tissues are normal.
Cardiothoracic ratio is normal.
Mediastinum is normal.
Both hila are normal.
Both costophrenic angles are clear.
Both domes of diaphragm are normal.
Lung fields are clear. No parenchymal lesion seen.

IMPRESSION: Normal Study.

DR. POOJA GARG
RADIOLOGIST
REG NO- DMC/R/03398

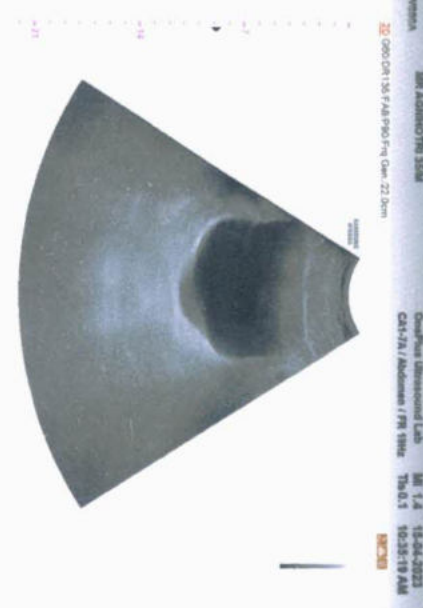
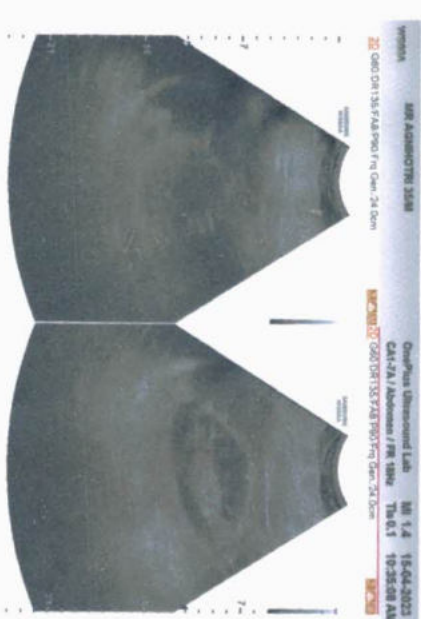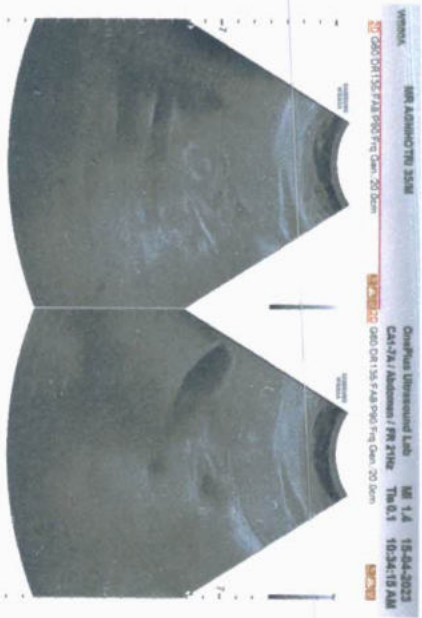
[Signature]

DR. POOJA GARG
M.B.B.S. (RADIOLOGY)
Reg No. DMC/R/03398
Radiologist

Type By : pooja

47, Harsh Vihar, Pitampura, New Delhi-110034 | Ph.: 011-42480101, 9599913051
E-mail: oneplusul@gmail.com | Web.: www.oneplusul.in

Clinical correlation is essential for final diagnosis. • If test results are unsatisfactory please contact personally or on phone. • This report is for perusal of doctors only. • All disputes Subject to Delhi Jurisdiction only. • Not for medicolegal purposes. • All congenital anomalies in a foetus may not be diagnosed in routine obstetric ultrasound.





Dr. Nitin Agarwal Pathologist & Director
Ex. Sr. Res. MAMC & Lok Nayak Hospital
Ex. Chief of Lab Dr. Lal Path Labs.

Dr. Pooja (Garg) Agarwal Radiologist & Director
MAMC & Lok Nayak Hospital

Name	: Mr. AGNIHOTRI DHRUV	Age/Sex	: 35 YRS/Male
Ref. By	: Dr. MEDIWHEEL	Lab No	: 012304150001
Date	: 15-Apr-2023	Patient ID	: LSHH112653

ULTRASOUND EXAMINATION---WHOLE ABDOMEN

Liver is enlarged in size (16.9 cm) and normal in outline with altered echopattern. Diffuse increase in echogenicity of liver parenchyma is noted, suggestive of fatty infiltration (grade II). Intrahepatic biliary radicles are not dilated. No abscess or mass lesion seen. Hepatic veins, portal vein, IVC and aorta are normal. CBD is normal in caliber.

Gall bladder is well distended with anechoic lumen. Wall thickness is normal.

Both kidneys are normal in size, shape, position, outline and echopattern. Corticomedullary differentiation is maintained. No pelvicalyceal dilation or mass lesion is seen.

Spleen is normal in size and echotexture. No mass lesion seen.

Pancreas is normal in size, outline and echotexture.

Urinary bladder is normal in shape and position. No evidence of intravesical stone or mass seen.

Prostate is normal in size, shape and echopattern. Prostate measures 2.6 x 2.8 x 3.4 cm. Weight of prostate is 12.9 grams.

No abnormal bowel wall thickening seen in right iliac fossa. No free fluid seen anywhere in abdomen.

IMPRESSION:

- Fatty infiltration of liver (grade II) with hepatomegaly.

DR. POOJA GARG
RADIOLOGIST
REG NO- DMC/R/03398

DR. POOJA GARG
M.B.B.S., D.M.R.D.
Reg No. DMC/R/03398
Radiologist

Type By : pooja

47, Harsh Vihar, Pitampura, New Delhi-110034 | Ph.: 011-42480101, 9599913051
E-mail: onepiusul@gmail.com | Web.: www.onepiusul.in