



MITTAL HOSPITAL

ਮਿੱਤਲ ਹਸਪਤਾਲ

ਨੇੜੇ ਗਲੀ ਨੰ: 2, ਐਸ ਏ ਐਸ ਨਗਰ, ਬੱਸ ਸਟੈਂਡ ਰੋਡ,
ਬਰਨਾਲਾ-148101 (ਪੰਜਾਬ)
Near Street No. 2, SAS Nagar, Bus Stand Road,
BARNALA-148101 (Pb.)

For Emergency : 99142-16070

For Appointment : 01679-237777
For Endoscopy : 62398-83393

Dr. Parshant Mittal

M.D. Medicine (D.M.C. Ludhiana)
Consultant Physician
Ex. Medical Officer, Civil Hospital, Barnala
Ex. Sen. Registrar, Fortis Hospital, Mohali
Ex. Specialist, Radha Soami Hospital, Beas
PMC Regd. No. 37514
Email : mittal_parshant@yahoo.com

Dr. Priya Garg

M.D. Anaesthesiology
Consultant Anaesthesiology
(I.C.U. & Critical Care Specialist)
Ex. Registrar DMC, Ludhiana
Ex. Sr. Registrar PGI, Chandigarh
Ex. Cons. Radha Soami Hospital, Beas
PMC Regd. No. 36677

ECHOCARDIOGRAPHY REPORT

NAME: BAKSHI RAM

Date: 02.06.2023

AGE: 59 YEARS

Sex: MALE

Done by: Dr. Parshant Mittal

MEASUREMENTS

		NORMAL VALUES
AORTIC ROOT	: 30.0	(22 – 37 mm)
LEFT ATRIUM	: 33.6	(20 – 40 mm)
RVID (D)	: 20.0	(10 – 20 mm)
IVST (D)	: 10.0	(07 – 11 mm)
IVST (S)	: 11.4	(07 – 11 mm)
LVID (D)	: 40.7	(35 – 55 mm)
LVID (S)	: 28.6	(25 – 42 mm)
LVPW (D)	: 08.6	(07 – 11 mm)
LVPW (S)	: 10.7	(07 – 11 mm)

L.V. FUNCTION

EJECTION FRACTION	: 68.53%	(50 – 80%) (mod. simpson)
FRACTIONAL SHORTENING	: 34.82%	(28 – 40%)

Mitral Valve : Thin, opens normally. No mitral regurgitation present.
MVA=3.82cm², EPSS=0.50cm, MAPSE=11mm. "E" wave more than
"A". E/A ratio=1.34

Aortic Valve : Thin, opens normally, tricuspid.
No aortic regurgitation present.

Tricuspid Valve : Thin, opens normally.
No tricuspid regurgitation present.

Pulmonary Valve : Thin, opens normally.

Pericardium : No pericardial effusion.

Wall Motion Abnormalities: No regional wall motion abnormalities present.

Cardiac Chambers: All the cardiac chambers are normal in size.

DOPPLER EVALUATION

VELOCITY (GRADIENT)	(GRADE)	
MV : E=74, A=55	cm/sec.	MR: NIL
AV : 93	cm/sec.	AR: NIL
TV :	cm/sec.	TR: NIL
PV :	cm/sec.	PR: NIL

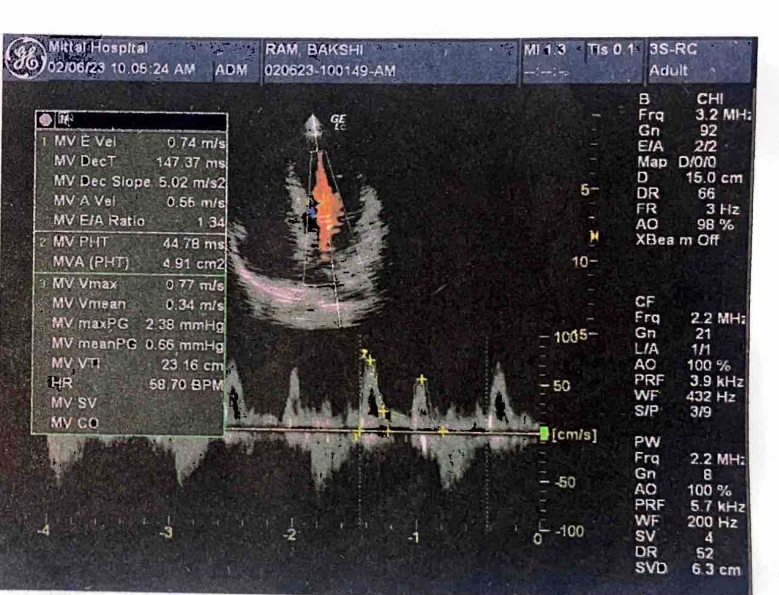
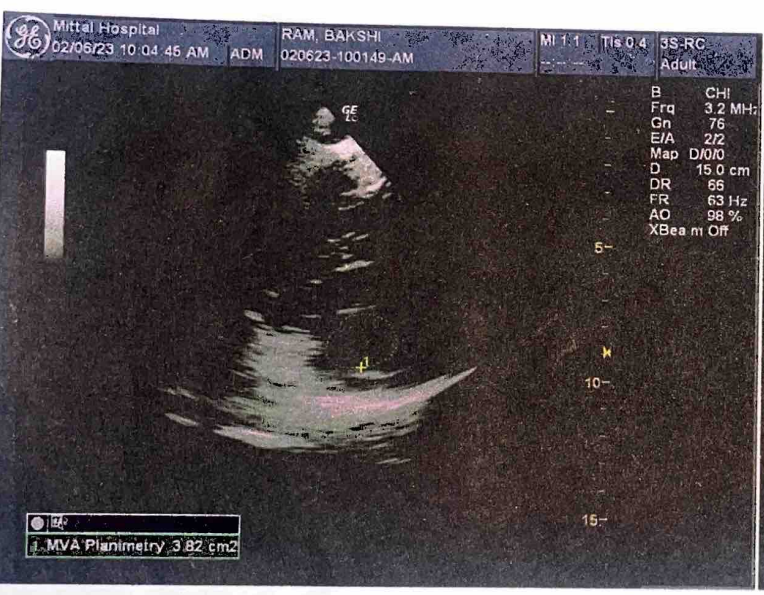
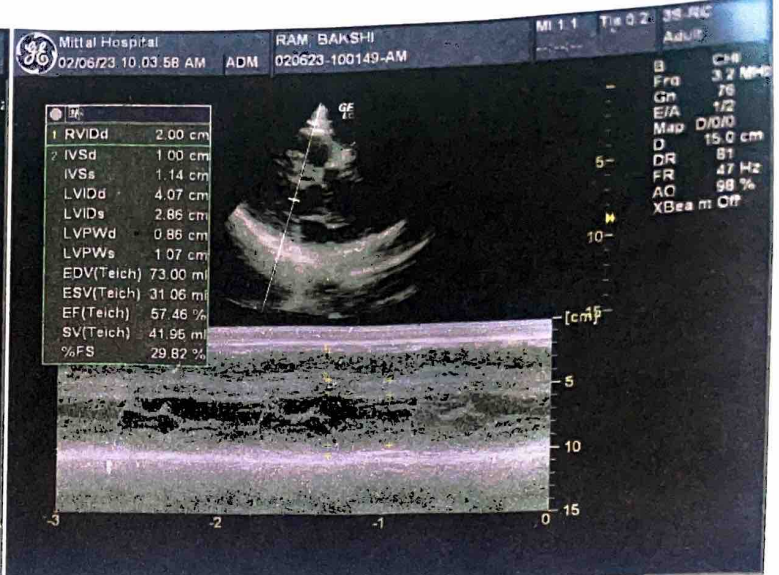
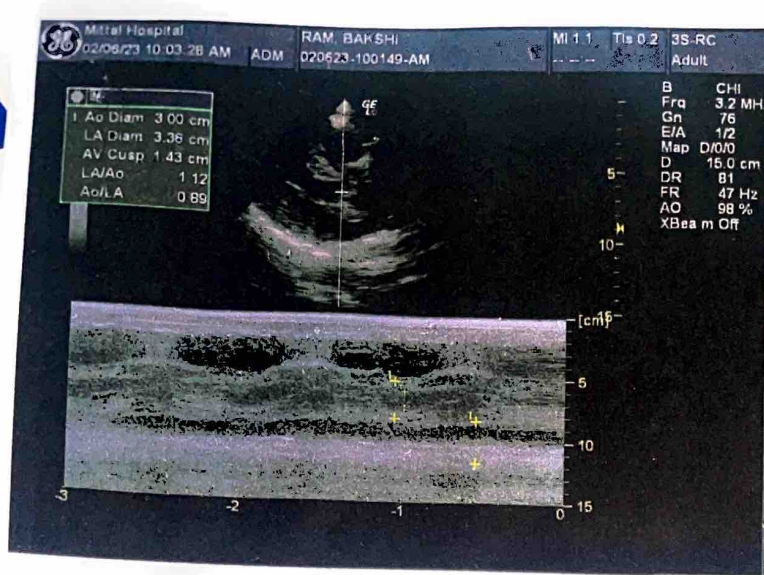
IMPRESSION:

➤ **NO REGIONAL WALL MOTION ABNORMALITIES
PRESENT WITH NORMAL LV SYSTOLIC FUNCTION
(EF =68.53%).**


DR. PARSHANT MITTAL
MD (MEDICINE)
MITTAL HOSPITAL, BARNALA

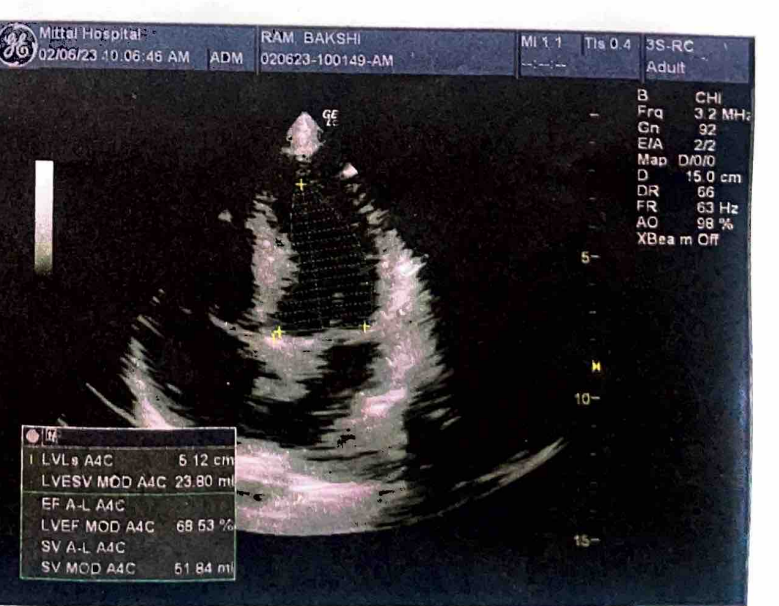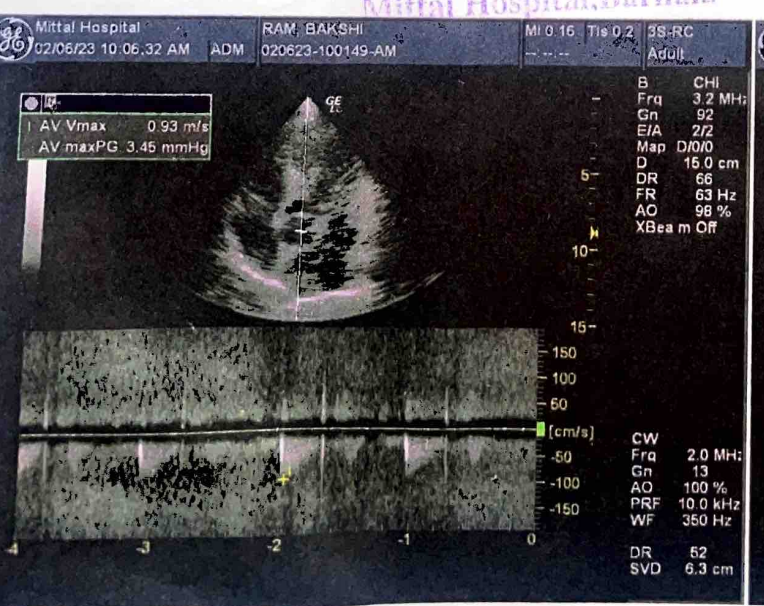
Not valid for Medico Legal Purpose

Dr. Parshant Mittal
M.D. Medicine
PMIC Regd. No. 37514
Mittal Hospital, Barnala



Dr Parshant Mittal
M.D. Medicine
PMC Regd. No. 37514
Mittal Hospital, Barnala

Signature



MITTAL COMPUTERISED LAB.

Inside Mittal Hospital, BARNALA-148101

Patient's Name **BAKSHI RAM 59/M** Ref. By Dr. **PARSHANT MITTAL** Dated **02-06-2023****HEMATOLOGY**

TEST	RESULT	NORMAL RANGE
Haemoglobin	14.8 gm/dl	Male 12.0-15.5 gm/dl Female 10-13.5 gm/dl
T.L.C.	6500 /cumm	4000-11000/cumm
D.L.C. (Different Leucocyte Count)		
Neutrophils	62 %	40-75%
Lymphocytes	29 %	20-45%
Eosinophils	04 %	1-6%
Monocytes	05 %	2-10%
Basophils	00 %	0-1%
MCV	93	80-99 fl
MCH	31	26-32 pg
MCHC	34	32-36 gm/dl
RDW	38	37-54 fl
Hematocrit	46	37-52
ESR (Westergreen)	04 mm. 1st Hr.	Male upto 10mm. 1st Hour. Female upto 20mm. 1st Hour.
Platelet Count	312000 /cumm.	1,50000-4,00000/cu.mm.
T Eosinophil Count	/Cumm	40-440 Cell/cumm
Total RBC COUNT	5.9	4.7-6.2 to 10 ⁶ /μl

SEROLOGY

Widal Test	1:20	1:40	1:80	1:160	1:320	1:640
S. Typhi O	-	-	-	-	-	-
S. Typhi H	-	-	-	-	-	-
S. Paratyphi AH	-	-	-	-	-	-
S. Paratyphi BH	-	-	-	-	-	-
Dengue NS1						
Dengue IgM/IgG						
TSH:	3.92	(0.550-4.780 uIU/ml)				
S. T4 LEVEL:	9.41	(5.4-11.5 mcg/dl)				
S. T3 LEVEL:	136	(80-220 ng/dl)				
S. PSA LEVEL:	1.89	(0-4 ng/mL)				

URINE EXAMINATION

ROUTINE EXAMINATION	
Appearance :	CLEAR
Colour :	STRAW
Sp. Gravity :	1.005
Reaction :	ACIDIC
Albumin :	NIL
Sugar :	NIL
Bile Salts:	NIL
Bile Pigments :	NIL
MICROSCOPIC EXAMINATION	
RBC	NIL
Pus Cells	RARE
Epithelial Cells	0-1/hpf
Calcium Oxalate	NIL
Spermatozoa	
URINE FOR MICROALBUMIN :	(0.00-25.0 mg/l)
URINE FOR NICOTINE:	(<5ng/ml)

BIO-CHEMISTRY

TEST	RESULT	NORMAL RANGE
Blood Sugar Fasting	92 mg/dl.	80-120 mg/dl.
Blood Sugar PP/Random	113 Mg/dl.	Upto 140 mg/dl.
Blood Urea Nitrogen	13 Mg/dl.	10-20 mg/dl.
S. Creatinine	0.8 mg/dl.	0.8-1.4 gm/dl.
S. Uric Acid	3.1 mg/dl.	Male 2-5 mg/dl.
BUN: Creatinine ratio	16.25	10-20:1.
Blood Group	O POSITIVE	

LIVER FUNCTION TEST

S. Bilirubin (Total)	0.54 mg/dl.	0.2-1.0 mg/dl.
Conjugated	0.26	0.1-0.4 mg/dl
Unconjugated	0.28	0.1-0.6 mg/dl
S. Alkaline Phosphatase	98 U/L	37-147U/L
S.G.O.T.	25 U/L	10-40 Units/ml
S.G.P.T.	22 U/L	10-35 Units/ml
G.G.T.P	19	0-40 U/L
AST:ALT ratio	1.13	Below 1.5
CHOL:HDL ratio	3.85	1-5
Total Serum Proteins	7.7 gm/dl.	6.0-8.0 gm/dl.
Albumin	4.6 Gm/dl.	3.5-5.0 gm/dl.
Globulin	3.1 gm/dl.	2.0-3.5 gm/dl
A:G ratio	1.48	1-5
HDL:LDL ratio	2.29	1-3.5

LIPIDOGRAM

S. Cholesterol	158 mg/dl.	130-240 mg/dl.
S. Triglycerides	147 mg/dl.	60-170 mg/dl.
S. HDL Cholesterol	41 mg/dl.	30-60 mg/dl.
S. LDL Cholesterol	94 Mg/dl.	Upto 150 mg/dl
S. VLDL Cholesterol	29 Mg/dl.	Upto 45 mg/dl.

ELECTROLYTES TEST

S. Chloride	mmol/L.	96-106 mmol/L.
S. Sodium	Mmol/L	135-155 mmol/L
S. Potassium	mmol/L	3.5-5.5 mmol/L

GLYCOSYLATED HEMOGLOBIN (HbA1c)

Reference Range	4.0 - 6.0 %	5.7 %
Good Diabetic Control	6.0 - 7.0 %	
Fair Control	7.0 - 8.0 %	
Poor Control	Above 8.0 %	
HbA1C test Value in %	Mean Plasma Glucose Level	
12.0	345	
11.0	310	
10.0	275	
9.0	240	
8.0	205	
7.0	170	
6.0	135	
5.0	100	

Dr. Suman Kaur
M.D. Pathology
Reg. No. 45679

Medical Technologist



Mittal Hospital

For Appointment PH: 01679-237777
For Emergency M: 99142-16070
mittal_parshant@yahoo.com

ਮਿੱਤਲ ਹਸਪਤਾਲ

ਡਾ. ਪ੍ਰਸ਼ਾਂਤ ਮਿੱਤਲ

ਨੇੜੇ ਗਲੀ ਨੰ: 2, ਐਸ ਏ ਐਸ ਨਗਰ, ਬੱਸ ਸਟੈਂਡ ਰੋਡ, ਬਰਨਾਲਾ-148101 (ਪੰਜਾਬ)

Near Street No. 2, SAS Nagar, Bus Stand Road,
BARNALA-148101 (Pb.)

ਡਾ: ਪ੍ਰੀਆ ਗਰਗ

ਐਮ.ਡੀ. ਮੈਡੀਸਨ (ਡੀ.ਐਮ.ਸੀ. ਲੁਧਿਆਣਾ)
ਐਕਸ ਮੈਡੀਕਲ ਅਫਸਰ, ਸਿਵਲ ਹਸਪਤਾਲ, ਬਰਨਾਲਾ
ਐਕਸ ਸੀਨੀਅਰ ਰਜਿਸਟਰਾਰ, ਫੋਰਟੀਜ਼ ਹਸਪਤਾਲ, ਮੁਹਾਲੀ
ਐਕਸ ਸਪੈਸ਼ਲਿਸਟ, ਰਾਧਾ ਸੁਆਮੀ ਹਸਪਤਾਲ, ਬਿਆਸ
(ਦਿਲ, ਪੇਟ, ਫਾਤੀ, ਸ਼ੂਗਰ ਅਤੇ ਕਾਲੇ ਪੀਲੀਏ ਦੇ ਮਾਹਿਰ)
PMC Regd. No. 37514

ਐਮ.ਡੀ. ਐਨਸਥੀਜ਼ੀਆ (ਡੀ.ਐਮ.ਸੀ. ਲੁਧਿਆਣਾ)
ਐਕਸ ਸੀਨੀਅਰ ਰਜਿਸਟਰਾਰ ਡੀ ਐਮ ਸੀ, ਲੁਧਿਆਣਾ
ਐਕਸ ਸੀਨੀਅਰ ਰਜਿਸਟਰਾਰ ਪੀ ਜੀ ਆਈ, ਚੰਡੀਗੜ੍ਹ
ਐਕਸ ਕਨਸਲਟੈਂਟ ਰਾਧਾ ਸੁਆਮੀ ਹਸਪਤਾਲ, ਬਿਆਸ
(ਆਈ.ਸੀ.ਯੂ. ਅਤੇ ਕਰੀਟੀਕਲ ਕੇਅਰ ਸਪੈਸ਼ਲਿਸਟ)
PMC Regd. No. 36677

Name..... Age..... Sex..... Dated.....
Name- BAKSHI RAM Ref by: Dr. PARSHANT MITTAL
Age/sex - 59/M Date-June 2, 2023

USG WHOLE ABDOMEN

Liver- is mildly enlarged in size (15.4 cm) but normal in shape, position and echotexture. No obvious focal lesion is seen. Intrahepatic biliary radicals are not dilated. Portal vein is normal in course and caliber.

Gall Bladder is normally distended. Wall thickness is normal. No evidence of calculus.

Common bile duct is normal in course and caliber.

Pancreas is normal in size and echotexture. Main pancreatic duct is not dilated.

Right Kidney is normal in size, position and echotexture. Corticomedullary differentiation maintained. No evidence of calculus/ hydronephrosis.

Left Kidney is normal in size, position and echotexture. Corticomedullary differentiation maintained. No evidence of calculus/ hydronephrosis.

Spleen is normal in size, shape and echotexture. Splenic vein is normal in caliber.

Urinary bladder is distended. Wall thickness is normal. No evidence of calculus.

Prostate ~ measures 24cc in volume and shows normal echopattern.

No e/o free fluid in peritoneal cavity.

IMPRESSION- USG abdomen reveals- Fatty Liver Grade I.

Kindly correlate clinically/Lab parameters (CBC, Urine C/E).

DR. PARSHANT MITTAL

Dr. Parshant Mittal
M.D. MEDICINE
M.D. Medicine
PMC Regd. No. 37514
Mittal Hospital, Barnala



Mittal Hospital

For Appointment PH: 01679-237777
For Emergency M: 99142-16070
mittal_parshant@yahoo.com

ਮਿੱਤਲ ਹਸਪਤਾਲ

ਨੇੜੇ ਗਲੀ ਨੰ: 2, ਐਸ ਏ ਐਸ ਨਗਰ, ਬੱਸ ਸਟੈਂਡ ਰੋਡ, ਬਰਨਾਲਾ-148101 (ਪੰਜਾਬ)

ਡਾ. ਪ੍ਰਸ਼ਾਂਤ ਮਿੱਤਲ

Near Street No. 2, SAS Nagar, Bus Stand Road,
BARNALA-148101 (Pb.)

ਡਾ: ਪ੍ਰੀਆ ਗਰਗ

ਐਮ.ਡੀ. ਮੈਡੀਸਨ (ਡੀ.ਐਮ.ਸੀ. ਲੁਧਿਆਣਾ)
ਐਕਸ ਮੈਡੀਕਲ ਅਫਸਰ, ਸਿਵਲ ਹਸਪਤਾਲ, ਬਰਨਾਲਾ
ਐਕਸ ਸੀਨੀਅਰ ਰਜਿਸਟਰਾਰ, ਫੋਰਟੀਜ਼ ਹਸਪਤਾਲ, ਮੁਹਾਲੀ
ਐਕਸ ਸਪੈਸ਼ਲਿਸਟ, ਰਾਧਾ ਸੁਆਮੀ ਹਸਪਤਾਲ, ਬਿਆਸ
(ਦਿਲ, ਪੇਟ, ਫਾਤੀ; ਸ਼ੂਗਰ ਅਤੇ ਕਾਲੇ ਪੀਲੀਏ ਦੇ ਮਾਹਿਰ)
PMC Regd. No. 37514

ਐਮ.ਡੀ. ਐਨਸਥੀਜ਼ੀਆ (ਡੀ.ਐਮ.ਸੀ. ਲੁਧਿਆਣਾ)
ਐਕਸ ਸੀਨੀਅਰ ਰਜਿਸਟਰਾਰ ਡੀ ਐਮ ਸੀ, ਲੁਧਿਆਣਾ
ਐਕਸ ਸੀਨੀਅਰ ਰਜਿਸਟਰਾਰ ਪੀ ਜੀ ਆਈ, ਚੰਡੀਗੜ੍ਹ
ਐਕਸ ਕਨਸਲਟੈਂਟ ਰਾਧਾ ਸੁਆਮੀ ਹਸਪਤਾਲ, ਬਿਆਸ
(ਆਈ.ਸੀ.ਯੂ. ਅਤੇ ਕਰੀਟੀਕਲ ਕੇਅਰ ਸਪੈਸ਼ਲਿਸਟ)
PMC Regd. No. 36677

Name.....Age.....Sex..... Dated.....

X-RAY REPORT

Name: BAKSHI RAM
Dr.: PARSHANT MITTAL

59/M

Date: 02/06/23

X- Ray Report: Chest pa view:

Bony cage unremarkable.
Both CP angles clear.
Trachea central.
Cardiac shadow normal.
Lungs show normal parenchyma with no other active lung lesion.

DR. PARSHANT MITTAL
M. D. MEDICINE

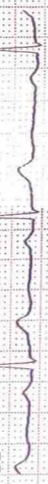Dr. Parshant Mittal
M.D. Medicine
PMC Regd. No. 37514
Mittal Hospital, Barnala

AUTO 10mm/mV

I



II



III




10mm/mV

aVR



10mm/mV

aVL



10mm/mV

aVF



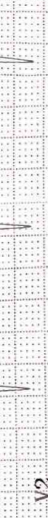
10mm/mV

II



10mm/mV

V1



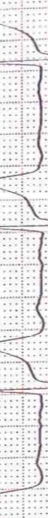10mm/mV

V2



10mm/mV

V3




10mm/mV

V4



10mm/mV

V5



10mm/mV

V6



25mm/s AC50Hz+EMG25Hz+DFT

10mm/mV

V4

V5

V6

10mm/mV

I

II

III

aVR

10mm/mV

aVL

aVF

V1

V2

10mm/mV

V3

V4

V5

V6

MITTAL HOSPITAL

2023-06-02 14:56

ID:

Name: BALSHI Anu 57

Sex: M

Age: 57

Height: cm

Weight: kg

SYS: mmHg

DIA: mmHg

HR [bpm]: 61

PR Interval [ms]: 200

P Duration [ms]: 135

QRS Duration [ms]: 92

T Duration [ms]: 217

QT/QTc [ms]: 420/426

P/QRS/T Axis [deg]: 64.4/45.2/67.8

R(V5)/S(V1) [mV]: 1.17/0.74

R(V5)+S(V1) [mV]: 1.91

<< Conclusions >>

Normal Sinus Rhythm,
Normal Cardiac Electric Axis,
aVL Abnormal T wave.

Report need physician confirm

NORMAL ECG

Dr. Parshant Mittal
MBB, Medicine
Reg. No. 37514
oncpb

Abhika

25mm/s

Physician

Dr. Parshant Mittal
M.D. Medicine
Consultant Physician



GPS Map Camera

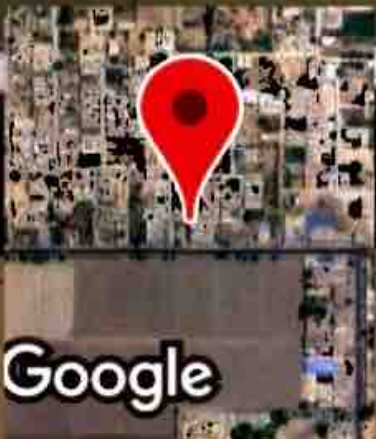Barnala, Punjab, India

street no 2, New Bus Stand Rd, Sas Nagar, Barnala,
Punjab 148101, India

Lat 30.378059°

Long 75.535619°

02/06/23 07:40 AM GMT +05:30





ਭਾਰਤ ਸਰਕਾਰ

GOVERNMENT OF INDIA

नाम :-

Bakshi Ram

जन्म तिथि / Year of Birth: 1964

लिंग - Male

9931 8214 1365



ਆਧਾਰ - ਆਮ ਆਦਮੀ ਦਾ ਅਧਿਕਾਰ



ਭਾਰਤੀ ਵਿਲੱਖਣ ਪਛਾਣ ਅਥਾਰਿਟੀ

UNIQUE IDENTIFICATION AUTHORITY OF INDIA

ਪਤਾ: S/O ਨਾਠੂ ਰਾਮ, ਵਾਰਡ ਨੰਬਰ 1

ਕਰਤਾਰਪੁਰਾ ਬਸਤੀ, ਸੰਗਰੂਰ, ਸੰਗਰੂਰ, ਸੰਗਰੂਰ

ਪਿੰਨਾਬ 148001

Address: S/O Nathu Ram,
WARD NUMBER 1,
KARTARPURA BASTI,,
SANGRUR, Sangrur,
Sangrur, Punjab, 148001



1800 180 1947



help@uidai.gov.in

www

www.uidai.gov.in



P.O. Box No.1947,
Bengaluru-560 001

