

LETTER OF APPROVAL / RECOMMENDATION

To,

The Coordinator,
Mediwheel (Arcofemi Healthcare Limited)
Helpline number: 011- 41195959

Dear Sir / Madam,

Sub: Annual Health Checkup for the employees of Bank of Baroda

This is to inform you that the following employee wishes to avail the facility of Cashless Annual Health Checkup provided by you in terms of our agreement.

PARTICULARS	EMPLOYEE DETAILS
NAME	MR. JOSHI CHIRAG BALAVANTRAI
EC NO.	199322
DESIGNATION	SINGLE WINDOW OPERATOR A
PLACE OF WORK	ALIPURA
BIRTHDATE	06-11-1984
PROPOSED DATE OF HEALTH CHECKUP	24-09-2022
BOOKING REFERENCE NO.	22S199322100026172E

This letter of approval / recommendation is valid if submitted along with copy of the Bank of Baroda employee id card. This approval is valid from **19-09-2022** till **31-03-2023** The list of medical tests to be conducted is provided in the annexure to this letter. Please note that the said health checkup is a **cashless facility** as per our tie up arrangement. We request you to attend to the health checkup requirement of our employee and accord your top priority and best resources in this regard. The EC Number and the booking reference number as given in the above table shall be mentioned in the invoice, invariably.

We solicit your co-operation in this regard.

Yours faithfully,

Sd/-

Chief General Manager
HRM Department
Bank of Baroda

(Note: This is a computer generated letter. No Signature required. For any clarification, please contact Mediwheel (Arcofemi Healthcare Limited))

SUGGESTIVE LIST OF MEDICAL TESTS

FOR MALE	FOR FEMALE
CBC	CBC
ESR	ESR
Blood Group & RH Factor	Blood Group & RH Factor
Blood and Urine Sugar Fasting	Blood and Urine Sugar Fasting
Blood and Urine Sugar PP	Blood and Urine Sugar PP
Stool Routine	Stool Routine
Lipid Profile	Lipid Profile
Total Cholesterol	Total Cholesterol
HDL	HDL
LDL	LDL
VLDL	VLDL
Triglycerides	Triglycerides
HDL / LDL ratio	HDL / LDL ratio
Liver Profile	Liver Profile
AST	AST
ALT	ALT
GGT	GGT
Bilirubin (total, direct, indirect)	Bilirubin (total, direct, indirect)
ALP	ALP
Proteins (T, Albumin, Globulin)	Proteins (T, Albumin, Globulin)
Kidney Profile	Kidney Profile
Serum creatinine	Serum creatinine
Blood Urea Nitrogen	Blood Urea Nitrogen
Uric Acid	Uric Acid
HBA1C	HBA1C
Routine urine analysis	Routine urine analysis
USG Whole Abdomen	USG Whole Abdomen
General Tests	General Tests
X Ray Chest	X Ray Chest
ECG	ECG
2D/3D ECHO / TMT	2D/3D ECHO / TMT
Stress Test	Thyroid Profile (T3, T4, TSH)
PSA Male (above 40 years)	Mammography (above 40 years) and Pap Smear (above 30 years).
Thyroid Profile (T3, T4, TSH)	Dental Check-up consultation
Dental Check-up consultation	Physician Consultation
Physician Consultation	Eye Check-up consultation
Eye Check-up consultation	Skin/ENT consultation
Skin/ENT consultation	Gynaec Consultation



Savita

Superspeciality Hospital
(A Unit of Solace Healthcare Pvt. Ltd.)

Parivar Char Rasta, Waghodia-Dabhoi Ring Road, Vadodara-390019

0265-2578844 / 2578849 ✉ mh@savitahospital.com 🌐 savitahospital.com

PHYSICIAN EXAMINATION

Name:-CHIRAGBHAI JOSHI

Age: 38/MALE

Reg.No:20221005398

DOE: 8/10/2022

Physical Examination:

Height: 164CM

Weight: 72KG

PULSE: 88 Temperature: NORMAL

BMI: 26.08

BP: 146/108

SPO2- 99%

Chief Complaint: NAD

Past History: NAD

General Examination: NAD

Systemic Examination: NAD

INVESTIGATION :

ADVICE: TAB-ROSUNAS(10) -: 0-0-1

DR HIREN PATEL.





Savita

Superspeciality Hospital
(A Unit of Solace Healthcare Pvt. Ltd.)

Parivar Char Rasta, Waghodia-Dabhoi Ring Road, Vadodara-390019

☎ 0265-2578844 / 2578849 ✉ mh@savitahospital.com 🌐 savitahospital.com

Examination By Ophthalmologist

Name:-CHIRAGBHAI JOSHI

Reg.No: 20221005398

Age:38/MALE

DOE: 8/10/2022

Present Complaints: NAD

Medical History: NAD

Examination Of Eye:	<u>Right</u>	<u>Left</u>
External Examination :	NAD	NAD
Ati Seg Examination:	A/S WNL	NAD
Schiotz Tonometry IOP:	RRRL	RRRL

Fundus: NILL

Without Glass Distant Vision: ___NAD___NAD___

Near Vision: _NAD _NAD _

With Glass Distant Vision: 6/6+0.50/170 ___6/6+0.50/10

Near Vision: N6_____N6

Colour Vision (With Ishihara Chart): WNL

Advice: NAD



DR CHETAN CHAUHAN

CANON RK-F2

08/OCT/2022 11:58

No. : 003204

NAME :

M/F

<RIGHT>

[REF]

**SPH
+0.25**

**VD; 80
CYL AX
+0.50 161**

<LEFT >

[REF]

+0.25 +0.50 8

PD : 64 mm

**SOLACE HEALTH CARE
WAGHODIA ROAD,
VADODARA.**

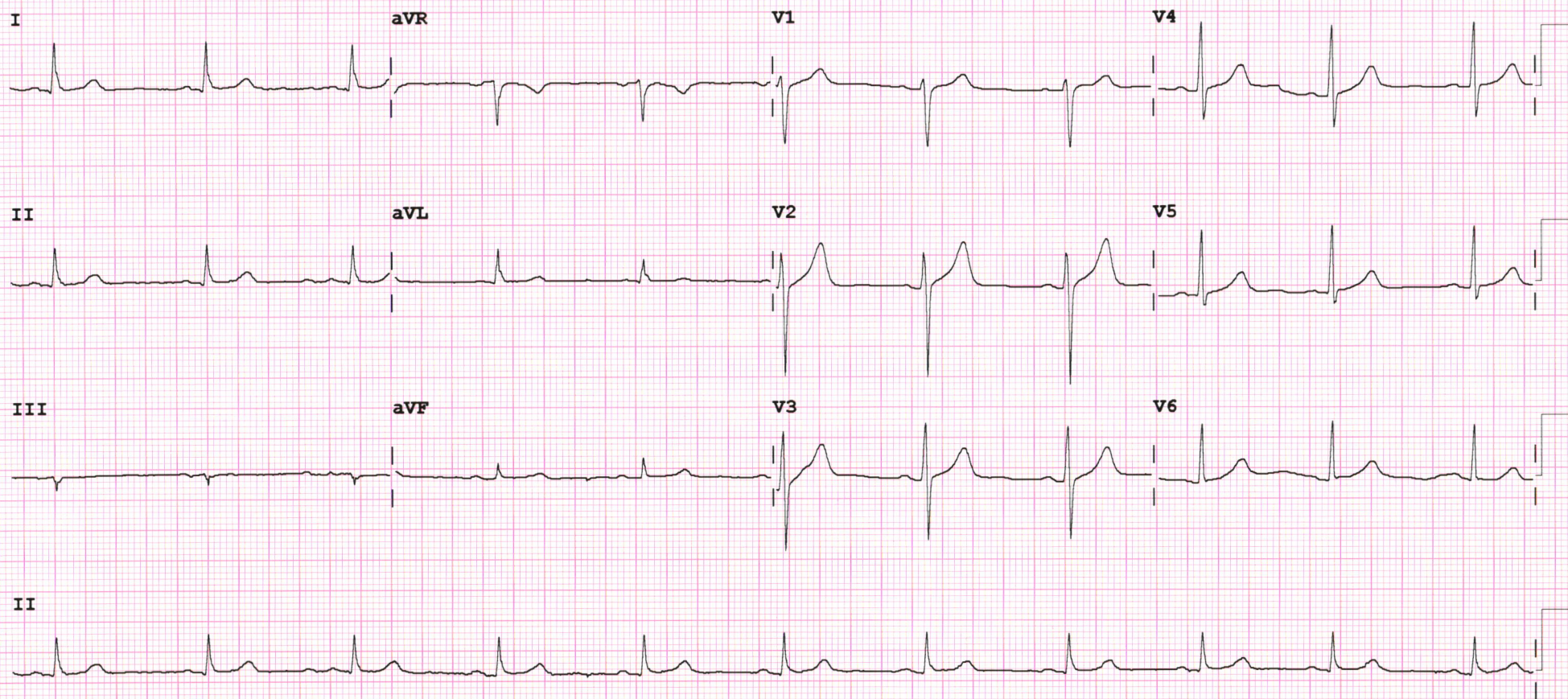
38 Years

Rate 65
PR 140
QRSD 82
QT 380
QTc 396

--AXIS--

P 39
QRS 18
T 37

12 Lead; Standard Placement



Device:

Speed: 25 mm/sec

Limb: 10 mm/mV

Chest: 10.0 mm/mV Elect. Off

F 50~ 0.50-150 Hz W

PH09

P?



Patient Name : Chirag Balvantrai Joshi

Sample No. : 20221008937



Patient ID : 20221005398

Visit No. : OPD20221015115

Age/Sex : 38y/Male

Coll. Date : 08/10/2022 09:55

Consultant : DR HIREN PATEL

S. Coll. Date : 08/10/2022 12:58

Ward : -


Report Date : 08/10/2022 16:32

CBC, ESR

Investigation	Result	Normal Value
Hemoglobin :	15 gm/dl	13.5 to 18.0 gm/dl
P.C.V. :	45.1 %	42.0 to 52.0 %
M.C.V. :	84.1 fL	78 to 100 fL
M.C.H. :	28 pg	27 to 31 pg
M.C.H.C. :	33.3 g/dl	32 to 36 g/dl
RDW :	12 %	11.5 to 14.0 %
RBC Count :	5.36 X 10 ⁶ / cumm	4.7 to 6.0 X 10 ⁶ / cumm
Polymorphs :	65 %	38 to 70 %
Lymphocytes :	31 %	15 to 48 %
Eosinophils :	2 %	0 to 6 %
Monocytes :	2 % [L]	3 to 11 %
Basophils :	0 %	0.0 to 1.0 %
Total :	100	< 100 > 100
WBC Count :	6500 /cmm	4000 to 10000 /cmm
Platelets Count :	314000 /cmm	1,50,000 to 4,50,000 /cmm
ESR - After One Hour :	8 mm/hr	1 to 13 mm/hr

Dr. Mehul Desai
M.B.D.C.P
Reg.No.G-9521



Patient Name : Chirag Balvantrai Joshi	Sample No. : 20221008937 
Patient ID : 20221005398	Visit No. : OPD20221015115
Age/Sex : 38y/Male	Coll. Date : 08/10/2022 09:55
Consultant : DR HIREN PATEL	S. Coll. Date : 08/10/2022 12:58
Ward : -	Report Date : 08/10/2022 16:32

Blood Group

Investigation	Result	Normal Value
BLOOD GROUP :		
ABO	O	
Rh	Positive	

FBS & PPBS

Investigation	Result	Normal Value
Blood Sugar (FBS) :	99 mg/dl	74 - 100 mg/dl
Urine Sugar (FUS) :	Nil	
Blood Sugar (PP2BS) :	78 mg/dl	70 to 120 mg/dl
Urine Sugar (PP2US) :	Nil	


HBA1C

Investigation	Result	Normal Value
Glycosylated Hb :	5.6 %	Near Normal Glycemia : 6 to 7 Excellent Control : 7 to 8 Good Control : 8 to 9 Fair Control : 9 to 10 Poor Control : > 10
Average Plasma Glucose of Last 3 Months :	114.02	



Dr. Mehul Desai
M.B.D.C.P
Reg.No.G-9521



Patient Name :	Chirag Balvantrai Joshi	Sample No. :	20221008937 
Patient ID :	20221005398	Visit No. :	OPD20221015115
Age/Sex :	38y/Male	Coll. Date :	08/10/2022 09:55
Consultant :	DR HIREN PATEL	S. Coll. Date :	08/10/2022 12:58
Ward :	-	Report Date :	08/10/2022 16:32

Lipid Profile


Investigation	Result	Normal Value
Sample :	Fasting	
Sample Type :	Normal	
Cholesterol (Chol) :	253 mg/dl [H]	Low risk : < 200 Moderate risk : 200 - 239 High risk : > or = 240
Triglyceride :	320 mg/dl [H]	Normal : < 200.0 High : 200 - 499 Very High : > or = 500
HDL Cholesterol :	33 mg/dl [L]	Low risk: >or = 60 mg/dL High risk : Up to 35 mg/dL
LDL :	156 mg/dl [N]	131.0 to 159.0(N) < 130.0(L) > 159.0(H)
VLDL :	64 mg/dl [H]	Up to 0 to 34 mg/dl
LDL/HDL Ratio :	4.73	Low risk : 0.5 to 3.0 Moderate risk : 3.0 to 6.0 Elevted level high > 6.0
Total Chol / HDL Ratio :	7.67	Low Risk : 3.3 to 4.4 Average Risk : 4.4 to 7.1 Moderate Risk : 7.1 to 11.0 High Risk : > 11.0
Total Lipids :	906 mg/dl [H]	400 to 700 mg/dl

Note :- Lipemic samples give high triglyceride value and falsely low LDL value.



Dr.Mehul Desai
M.B.D.C.P
Reg.No.G-9521



Patient Name :	Chirag Balvantrai Joshi	Sample No. :	20221008937 
Patient ID :	20221005398	Visit No. :	OPD20221015115
Age/Sex :	38y/Male	Coll. Date :	08/10/2022 09:55
Consultant :	DR HIREN PATEL	S. Coll. Date :	08/10/2022 12:58
Ward :	-	Report Date :	08/10/2022 16:32

LFT (Liver Function Test)

Investigation	Result	Normal Value
Total Bilirubin :	0.6 mg/dl	0.2 to 1.0 mg/dl
Direct Bilirubin :	0.1 mg/dl	0.0 to 0.2 mg/dl
Indirect Bilirubin :	0.5 mg/dl	0.0 to 0.8 mg/dl
AST (SGOT) :	38 U/L [H]	5 to 34 U/L
ALT (SGPT) :	54 U/L	0 to 55 U/L
Total Protein (TP) :	6.2 g/dL [L]	6.4 to 8.3, g/dl
Albumin (ALB) :	4 g/dl	3.5 to 5.2 g/dl
Globulin :	2.2 g/dl	2.3 to 3.5 g/dl
A/G Ratio :	1.82	
Alkaline Phosphatase (ALP) :	100 U/L	40 to 150 U/L
GAMMA GT. :	21 U/L	7 to 35 U/L



Dr. Mehul Desai
M.B.D.C.P
Reg.No.G-9521



Patient Name : Chirag Balvantrai Joshi

Sample No. : 20221008937



Patient ID : 20221005398

Visit No. : OPD20221015115

Age/Sex : 38y/Male

Coll. Date : 08/10/2022 09:55

Consultant : DR HIREN PATEL

S. Coll. Date : 08/10/2022 12:58

Ward : -

Report Date : 08/10/2022 16:32

RENAL FUNCTION TEST

Investigation	Result	Normal Value
Creatinine :	1 mg/dl	0.6 - 1.4 mg/dl
Urea :	23 mg/ dl	13 - 45 mg/dl
Uric Acid :	7.1 mg/dl	3.5 - 7.2 mg/dl
Calcium :	8.8 mg/dl	8.5 - 10.5
Phosphorus :	5 mg/dl	1.5 - 6.8

Dr.Mehul Desai
M.B.D.C.P
Reg.No.G-9521



Patient Name : Chirag Balvantrai Joshi

Sample No. : 20221008937



Patient ID : 20221005398

Visit No. : OPD20221015115

Age/Sex : 38y/Male

Coll. Date : 08/10/2022 09:55

Consultant : DR HIREN PATEL

S. Coll. Date : 08/10/2022 12:58

Ward : -

Report Date : 08/10/2022 16:32

Urine R/M

Investigation	Result	Normal Value
Quantity - :	20 ml	
Colour - :	Pale Yellow	
Reaction (pH) :	6.0	4.6-8.0
Turbidity :	Clear	
Deposit :	Absent	Absent
Sp.Gravity :	1.015	1.005-1.010
Protein :	Absent	Absent
Glucose :	Absent	Absent
Bile Salts :	Absent	Absent
Bile pigments :	Absent	Absent
Ketones :	Absent	Absent
Urobilinogen :	Absent	
Pus Cells :	0-1 /hpf	0-5/hpf
Red Blood Cells :	Absent /hpf	Absent
Epithelial Cells :	0-1 /hpf	

Dr.Mehul Desai
M.B.D.C.P
Reg.No.G-9521



TEST REPORT

Name : CHIRAG JOSHI	Acc. ID : 221019046	
Age/Sex : 38 Years / Male	Birthdate :	Regd. Dt : 08-Oct-2022 03:38 PM
Refd. By : SAVITA SUPERSPECIALITY HOSPITAL	Status : Final	Coll Dt. Tm. : 08-Oct-2022 03:00 PM
Sample : Serum (Blood in Plain)	PassportNo:	Recd. Dt. Tm. : 08-Oct-2022 03:38 PM
Client Details : SAVITA SUPERSPECIALITY HOSPITAL	Mobile :	Report Dt. Tm. : 08-Oct-2022 05:01 PM

IMMUNOLOGY

Test Name	Result	Unit	Biological Ref. Interval
-----------	--------	------	--------------------------

THYROID FUNCTION TEST

T3 (Triiodothyronine) <small>CHEMILUMINESCENT MICROPARTICLE IMMUNOASSAY</small>	1.17	ng/mL	0.97 - 1.69
T4 (Thyroxine) <small>CHEMILUMINESCENT MICROPARTICLE IMMUNOASSAY</small>	7.36	µg/dL	5.5 - 11.0
TSH <small>CHEMILUMINESCENT MICROPARTICLE IMMUNOASSAY</small>	1.100	µIU/ml	0.4 - 4.2

End Of Report -----

This is an Electronically Authenticated Report.

Viral
Dr. VIRAL A. PATEL
M. D. PATHOLOGY
GMC No. G-22658

Verified By
Auto

Dr. VIRAL A. PATEL
M. D. PATHOLOGY
GMC No. G-22658



2D-ECHOCARDIOGRAPHY AND COLOR DOPPLER REPORT

NAME: MR. CHIRAG B JOSHI

AGE/SEX: 38YRS/MALE

DATE : 08/10/2022

REF BY: DR HIREN PATEL

OBSERVATION:

- NORMAL LV SIZE AND NORMAL LV SYSTOLIC FUNCTION. LVEF = 60% (VISUAL).
- NO RWMA AT REST.
- TRIVIAL MR. NO MS.
- NO AR. NO AS.
- TRIVIAL TR. NO PAH.
- NORMAL LA.
- NORMAL SIZED LA, RA & RV WITH NORMAL RV SYSTOLIC FUNCTION.
- NORMAL SIZED MPA, RPA & LPA.
- INTACT IAS & IVS.
- NO E/O INTRACARDIAC CLOT/VEGETATION/PE.
- NORMAL IVC.
- NORMAL PERICARDIUM.

CONCLUSION: S/P PTCA

- NORMAL LV SIZE AND SYSTOLIC FUNCTION.
- NO RWMA AT REST.
- LVEF = 60% (VISUAL).



DR. NIRAV BHALANI
[CARDIOLOGIST]

DR. ARVIND SHARMA
[CARDIOLOGIST]

DR. CHIRAG SHETH
[CARDIOLOGIST]



Saturday, October 08, 2022

CHIRAG JOSHI

36 YEARS/MALE

ULTRASONOGRAPHY OF ABDOMEN AND PELVIS

Liver shows normal size and echogenicity. No mass lesion detected.
PV, CBD and intrahepatic biliary radicals shows no dilatation.

The gall bladder is distended and show normal gall bladder. There is no evidence of gallstones.

Spleen appears normal in size and echotexture. No evidence of focal lesion.
Pancreas appears normal in size and echotexture. No focal lesion.

Both kidneys show normal size, position and cortical echogenicity.
Right kidney measures 9.9 cm and Left kidney measures 10.4 cm.
A small exophytic cyst of size 2 x 3 cm is noted at lower pole of left kidney.
Corticomedullary differentiation is preserved bilaterally.
No calculus or hydronephrosis on either side.

The urinary bladder is distended and appears normal..
Prostate appears normal. (17 cc) No focal lesion.
No evidence of Lymphadenopathy or ascites seen.
No e/o dilated bowel loops seen.

CONCLUSION:

LEFT RENAL EXOPHYTIC CYST

DR. GANESH M SHIVANNA, M.D

CONSULTANT RADIOLOGIST



Saturday, October 08, 2022

CHIRAG JOSHI

36 YEARS/MALE

CHEST X RAY PA VIEW

Both the lung fields appear normal.

Both costophrenic angles appear clear.

Cardiac silhouette appear normal.

Both hila appears normal.

Mediastinum and aorta appear normal.

Bony thorax appears normal.

No evidence of free gas seen under dome of diaphragm.

COMMENTS:

- **NORMAL BOTH LUNG FIELDS.**
- **NORMAL CARDIAC SIZE.**

DR. GANESH M. SHIVANNA, M.D
CONSULTANT RADIOLOGIST