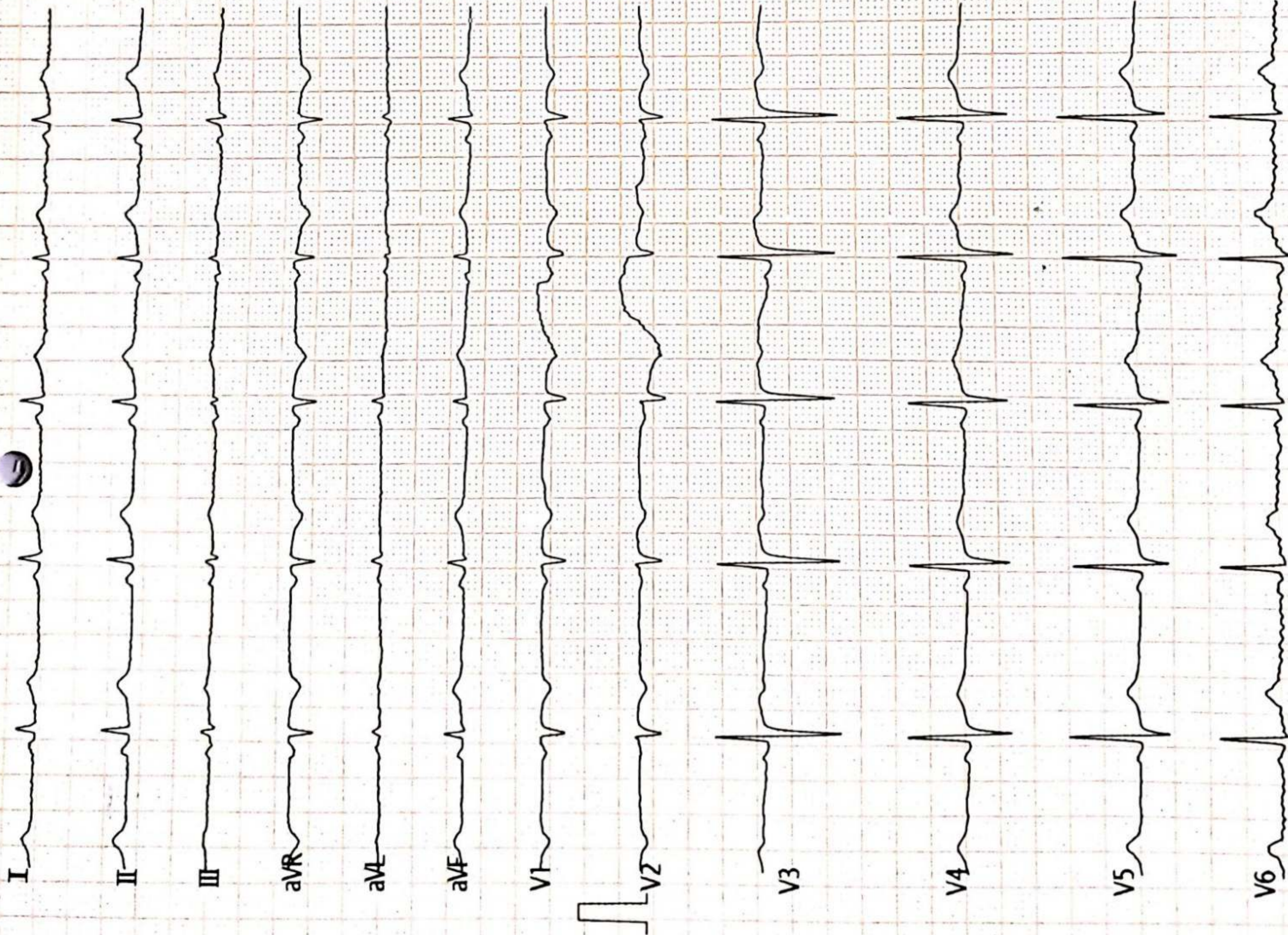


10mm/mV



<ECG Analysis Result>

Vent. Rate(BPM) : 67
 PR Int.(ms) : 126
 P/QRS/T Int.(ms) : 92 102 197
 QT/QTc Int.(ms) : 405 430
 P/QRS/T Axis(Deg.) : 56 47 58
 RV1/SV5 Amp.(mV) : 0.00 0.40
 RV5/SV1 Amp.(mV) : 1.00 0.29

*** Borderline Normal ECG ***

Normal
[Signature]

Dr. Sunil Suryawanshi

Note: Unconfirmed Report. Need to Review

Reg.No.2223

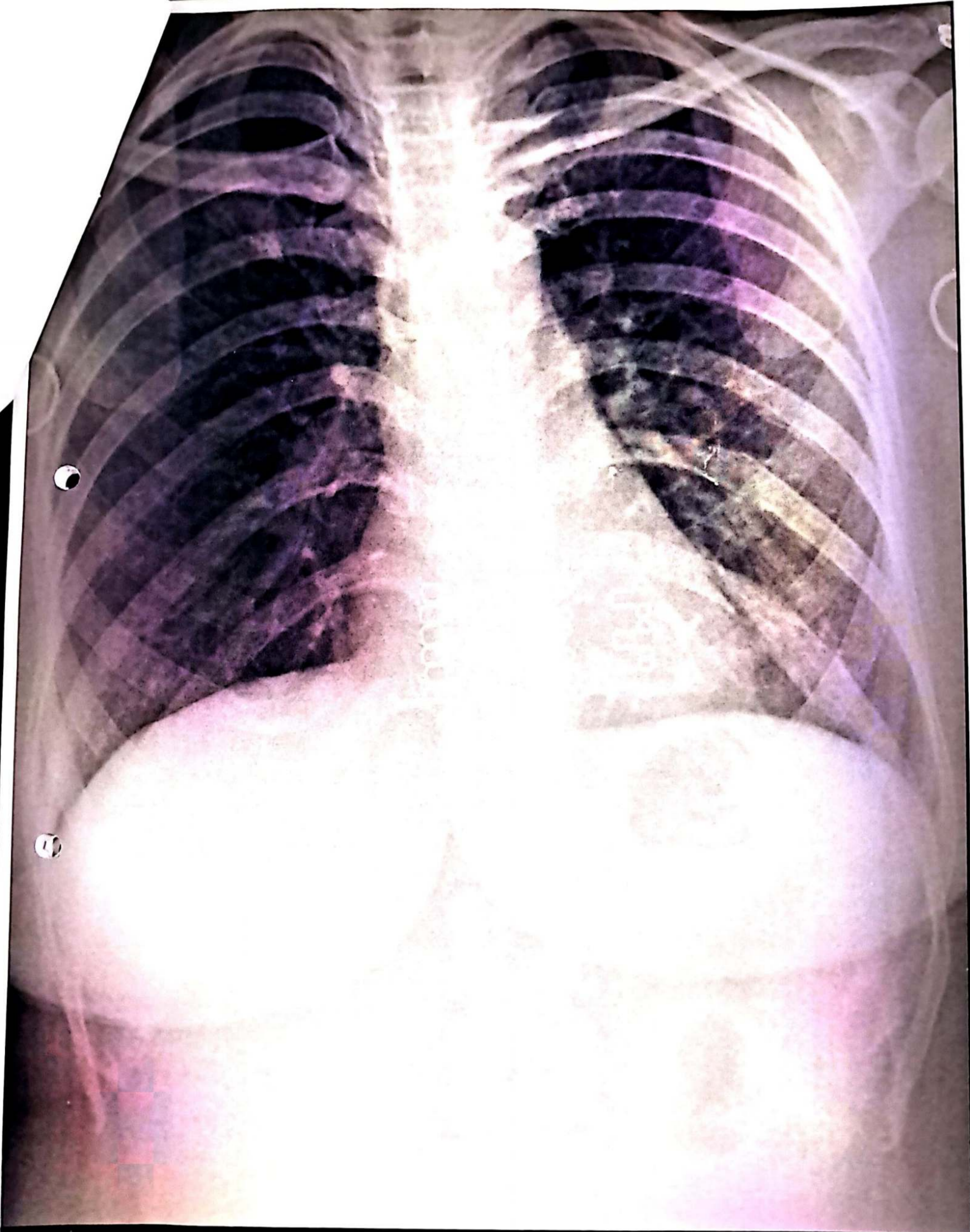
V2.35 Technician :

ST LEVEL(mV)

I	II	III	aVR	aVL	aVF
+0.00	+0.01	+0.01	-0.00	+0.00	+0.01
V1	V2	V3	V4	V5	V6
+0.00	+0.01	+0.05	+0.04	+0.02	+0.01

Abhaya





MONALI BORKAR 270110202308 CHEST PA 27-Nov-23

SUJAY HOSPITAL AND MATERNITY HOME, JALGAON

ANUSAYA Diagnostic Centre

Dhangar Building, Near India Garage, Jilha Peth, Jalgaon.
Tel. No. 0257-2239977

Dr. Vijay I. Naik

M.D. (Radiology)
Ex.A.Professor BJMC, Pune
Reg. No. 2002/08/2988

◆ Digital X-Ray ◆ Procedures ◆ Colour Doppler ◆ USG-Guided Intervention

Name : Monali Borkar
Ref. By : Dr sunil suryawanshi , MD

Date : 27-11-2023
Sex : F Age : 36 yrs

ULTRASONOGRAPHY OF ABDOMEN & PELVIS

The liver is normal in size & echotexture. There is no focal lesion seen. The intrahepatic biliary radicles, common duct and the portal vein are normal.

Gall bladder is well distended. No ER calculi or changes of cholecystitis seen.

Spleen is normal in size and shows normal echotexture. No focal lesions seen.

Pancreas reveals normal size, margins and echotexture. No focal lesions seen.

Both kidneys are normal in size, shape and position. No calculi or hydronephrosis seen on either side. The ureters are not dilated.

No obvious lymphadenopathy or ascites is seen. Aorta & IVC appears normal.

No obvious bowel wall thickening or mass seen in the abdomen. **RIF is clear.**


Urinary bladder is well distended and appears normal. No calculi or changes of cystitis seen. Both uvjunctions are clear.

Uterus is anteverted , normal in size & echotexture. No obvious focal lesions seen. Endometrial echo is 4.2 mm in thickness.

Both ovaries appears normal in size & echotexture. No obvious adnexal lesion.

IMPRSSION :-

➤ **NORMAL STUDY**

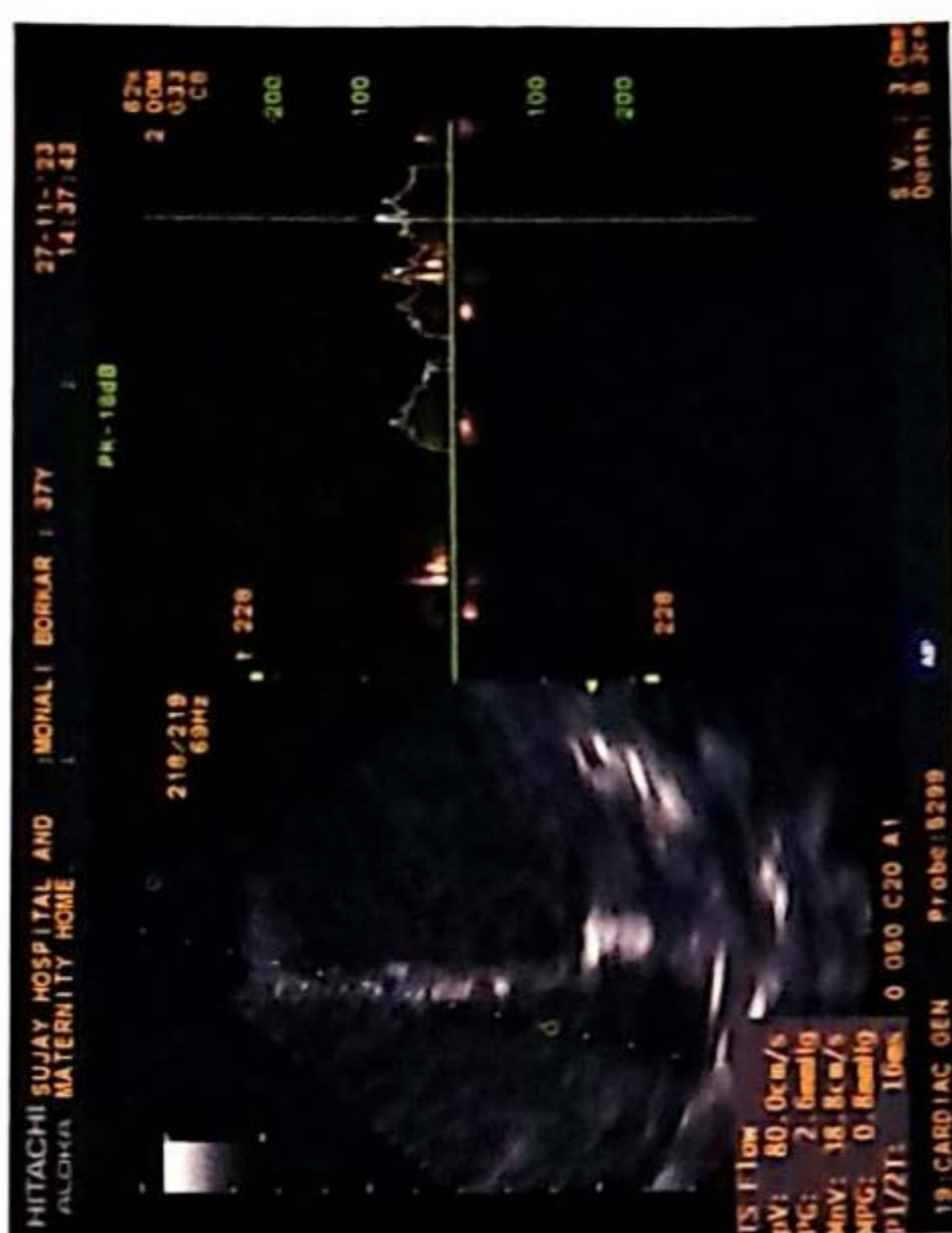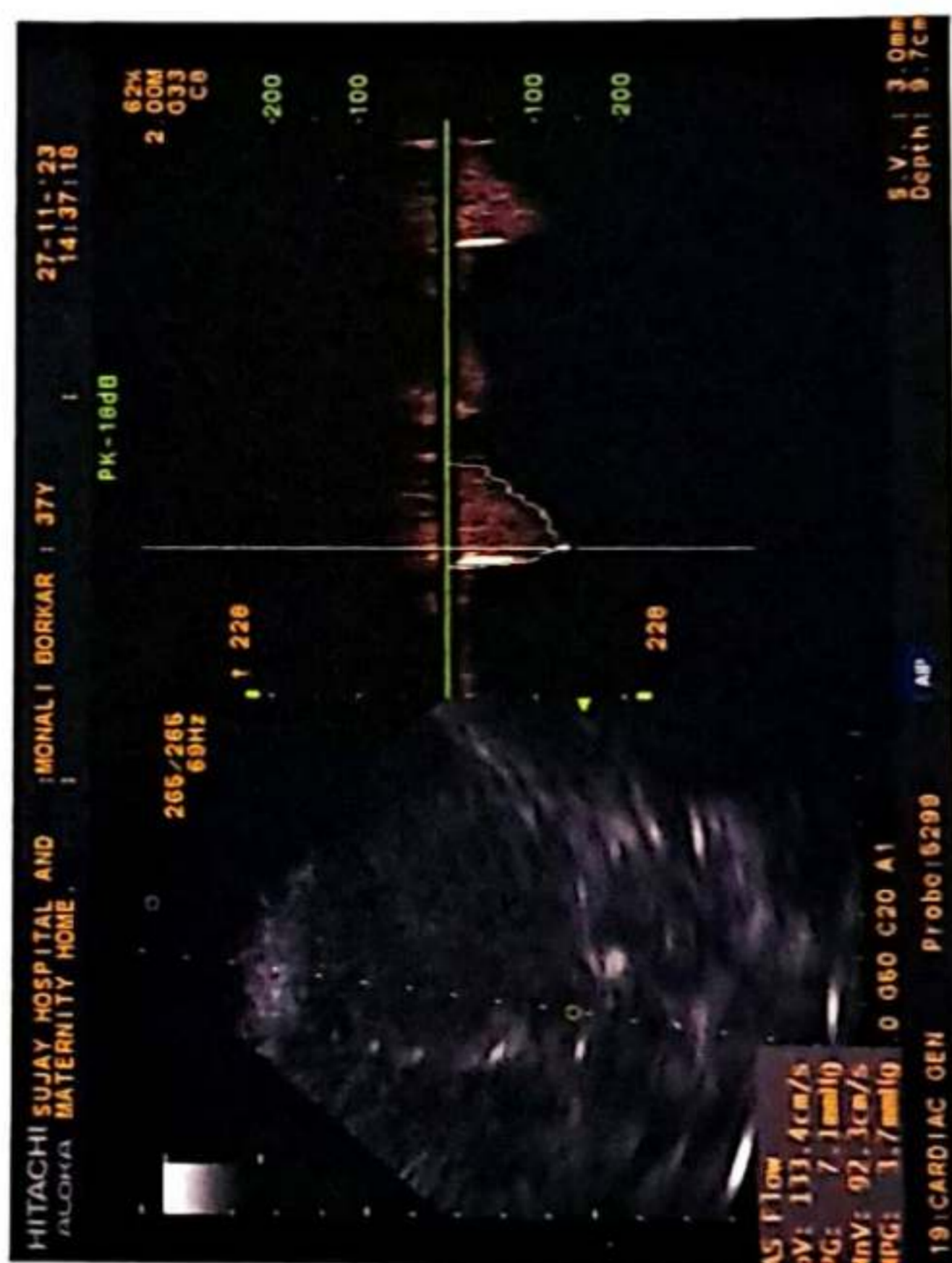
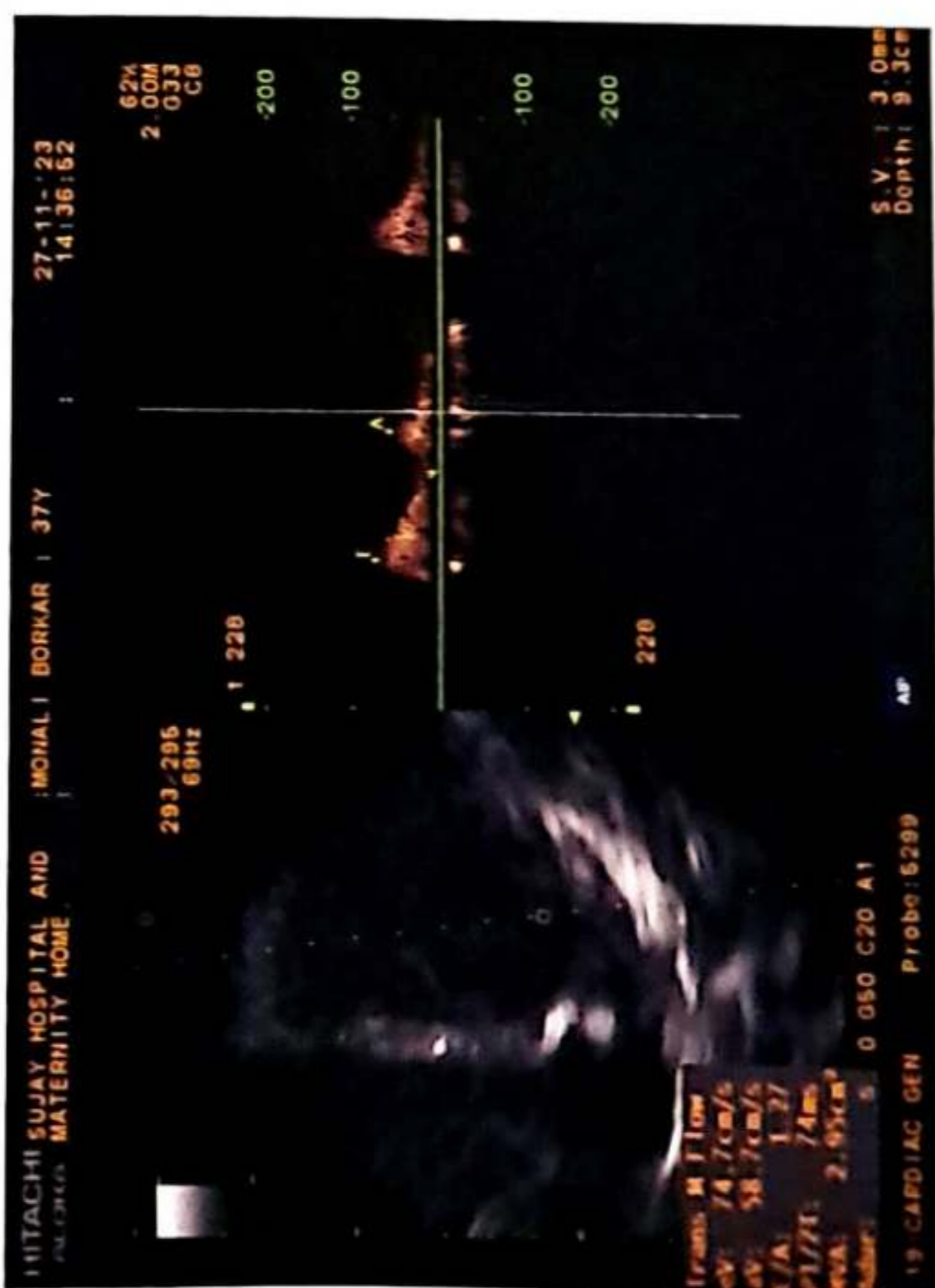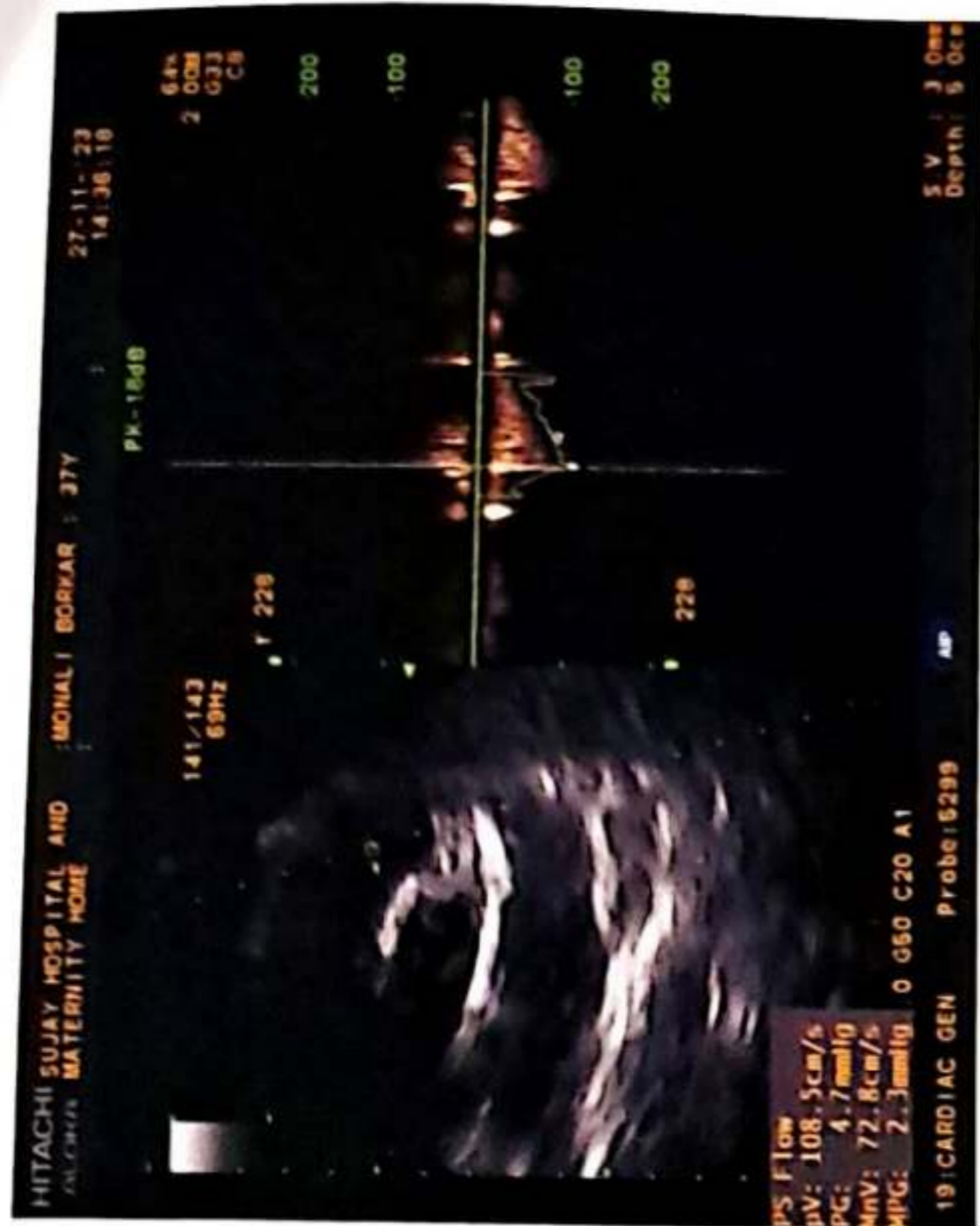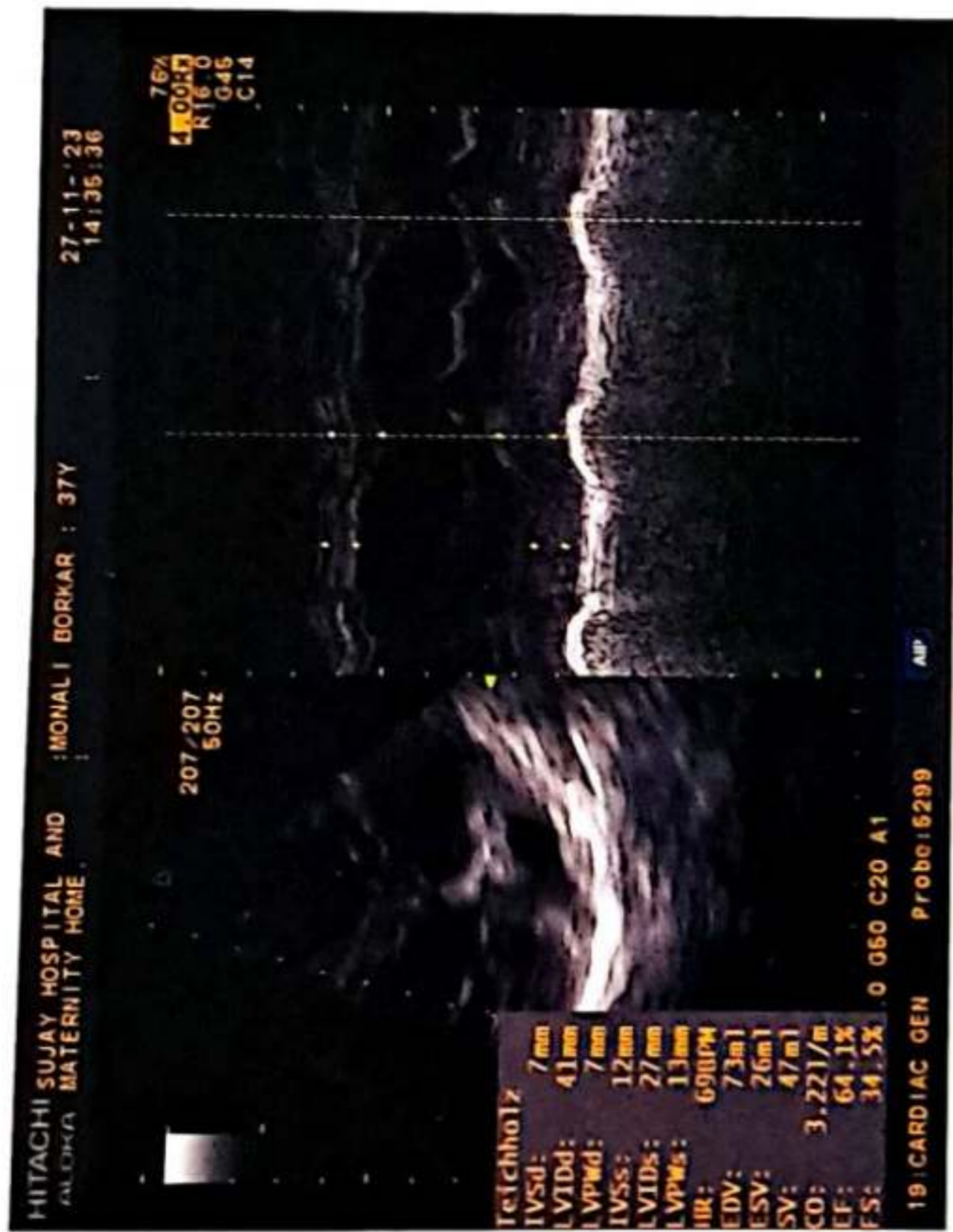
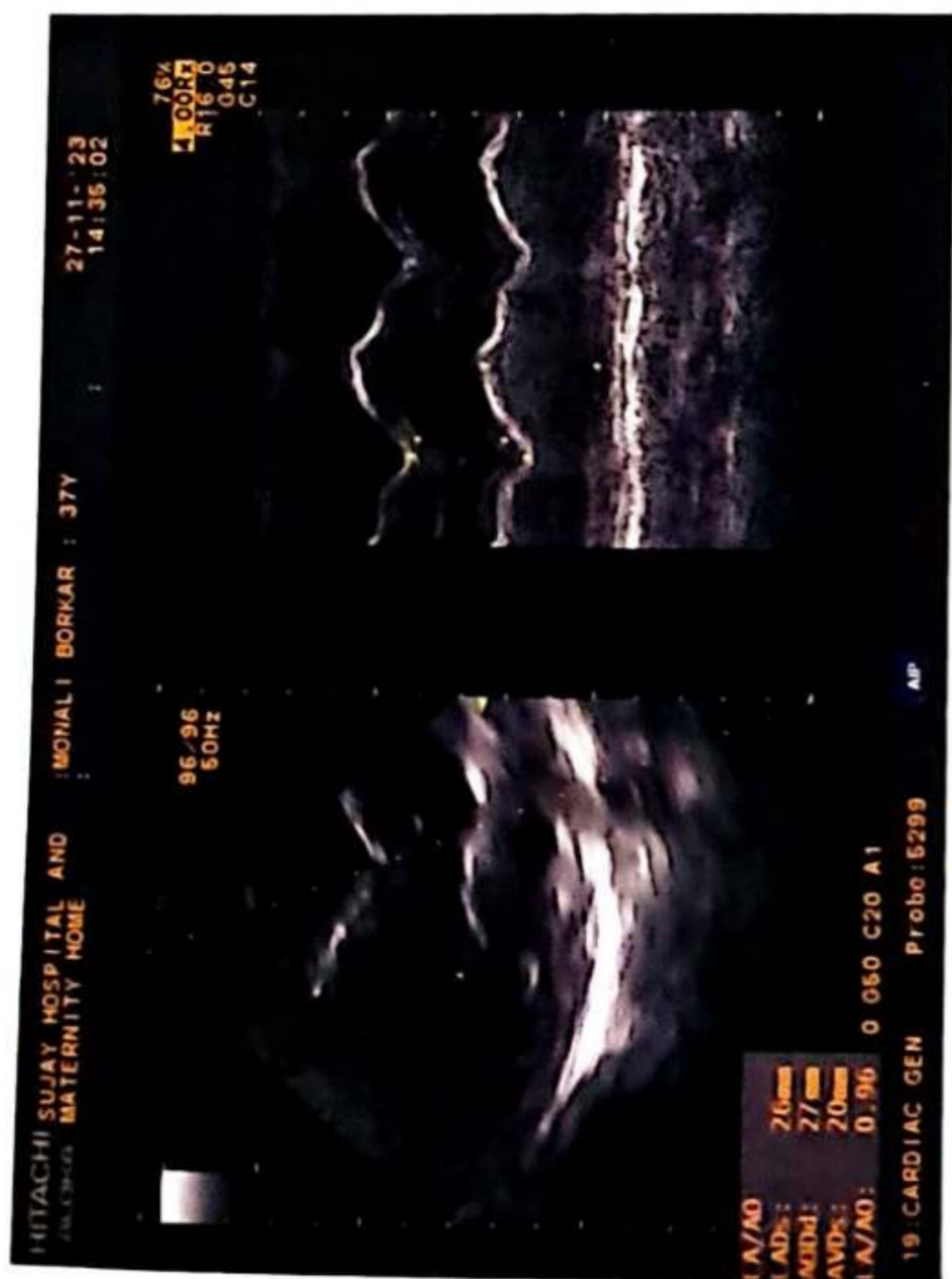


Dr VIJAY NAIK
M.D.(RADIOLOGY)

◆ कृपया परत येतांना हा रिपोर्ट सोबत आणावा.

◆ For any queries, please call 9175614167





डॉ. सौ. जयश्री सुर्यवंशी
एम.डी.
(स्त्रीरोग व प्रसूतीशास्त्र तज्ञ)
रजि.नं. 3712

डॉ. सुनिल सुर्यवंशी
एम.डी. (मेडीसीन) पुणे
कन्सल्टिंग फिजिशियन
रजि.नं. 2223

पत्ता : मेन टेलिफोन एक्सचेंज समोर, पारिख
पार्क जवळ, नविन बस स्टॅन्डच्या मागे,
जळगाव. फोन : (0257) 2227821

उपलब्ध सुविधा : • एक्स-रे • सोनोग्राफी • इकोकार्डिओग्राफी • मसज्ज ऑपरेशन थिएटर • कॉम्प्युटराईज्ड इ.सी.जी. • स्ट्रेस टेस्ट • पल्मोनरी फंक्शन टेस्ट

दि / / २०

Rx

X-RAY CHEST PA VIEW

NAME- MONALI BORKAR

AGE- 37 YRS FEMALE DATE-27.11.23

SOFT TISSUE AND SKELETON NORMAL.

BOTH HILA ARE NORMAL IN SIZE AND HAVE EQUAL DENSITY.

PROMINENT BRONCHOVASCULAR MARKINGS.

COSTOPHRENIC AND CARDIOPHRENIC ANGLES ARE CLEAR.

THE DOMES OF DIAPHRAGMS ARE NORMAL IN POSITION AND SHOW SMOOTH OUTLINE.

THE PLURAL SPACES ARE NORMAL.

IMPRESSION –

NORMAL XRAY CHEST .

परत येतांना कागद सोबत आणावा.

सौ. जयश्री सुर्यवंशी
एम.डी.
स्त्रीरोग व प्रसूतीशास्त्र तज्ञ
रजि.नं. 3712

डॉ. सुनिल सुर्यवंशी
एम.डी.(मेडीसीन) पुणे
कन्सल्टिंग फिजिशियन
रजि.नं. 2223

पत्ता : मेन टेलिफोन एक्सचेंज समोर, पारिख
पार्क जवळ, नविन बस स्टॅण्डच्या मागे,
जळगांव. फोन : (0257) 2227821

पलब्ध सुविधा : • एक्स-रे • सोनोग्राफी • इकोकार्डिओग्राफी • सुसज्ज ऑपरेशन थिएटर • कॉम्प्युटाइज्ड इ.सी.जी. • स्ट्रेस टेस्ट • पल्मोनरी फंक्शन टेस्ट

दि / / २०

Rx

2D – Echocardiograph

Name – MONALI BORKAR

Age- 37 Yrs FEMALE

Date – 27/11/2023

IMPRESSION –

NORMAL SIZE CARDIAC CHAMBER.

STRUCTURALLY NORMAL CARDIAC VALVE.

NORMAL LV SYSTOLIC FUNCTION, EF- 60 %.


NORMAL LV DIASTOLIC FUNCTION .

NO RWMA .

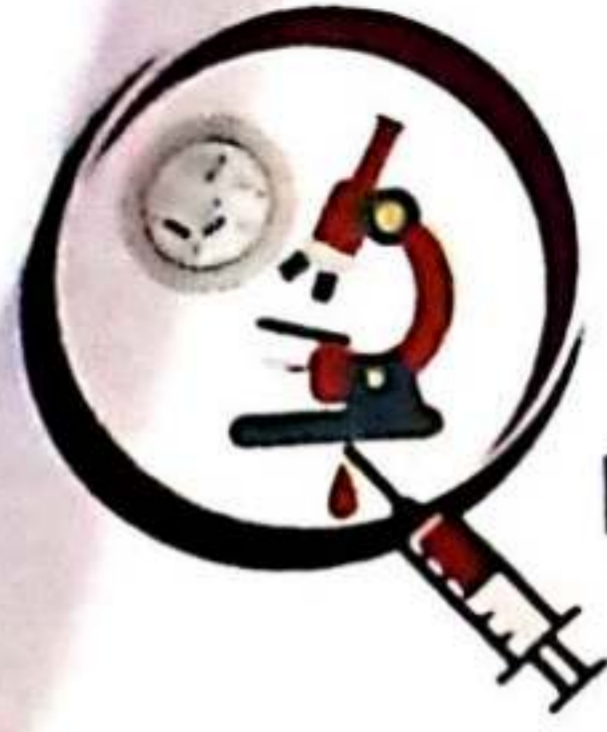NO CLOTS OR VEGETATION.

IAS AND IVS INTACT.

NORMAL PERICARDIUM.


Dr Sunil Suryawanshi
M D medicine.

परत येतांना कागद सोबत आणावा.



Manavata

Pathology & Microbiology Laboratory

Dr. Kailash B. Wagh
M.D. Microbiology D.C.P
Reg No. 2001/07/2704

REG NO. : 11-2023-OPD / 7
NAME : Mrs. MONALI BORKAR
REF BY : Dr . Sunil Suryavanshi (Insurance)
M.D.

AGE : 37 Years
SEX : Female
DATE : 27-Nov-2023

LOCATION :

HAEMOGRAM

TESTS	RESULTS	UNIT	REFERENCE RANGE
Haemoglobin	: 12.2	g/dl	11 - 18
WBC COUNT			
Total WBC Count	: 6400	/cmm	4000 - 11000
DIFFERENTIAL COUNT			
Neutrophil	: 65	%	40 - 74
Lymphocyte	: 29	%	15 - 45
Eosinophil	: 02	%	0 - 7
Monocyte	: 04	%	1 - 10
Basophil	: 00	%	0 - 1
RBC INDICES			
Hct	: 36.6	%	33 - 60
R.B.C. count	: 4.53	mil./cmm.	4.0 - 6.0
Mcv	: 83.1	fL	76 - 94
Mch	: 29.4	pg	25 - 33
Mchc	: 35.1	%	32 - 38
PLATELETS INDICES			
Plt Count	: 356000	/cmm	150000 - 450000
RBC Morphology	: Normocytic Normocytic		
WBC Studies	: Normal Morphology		
Platelet	: Adequate		
ESR	: 10	mm/hr	00 - 20

THANKS FOR REFERRAL



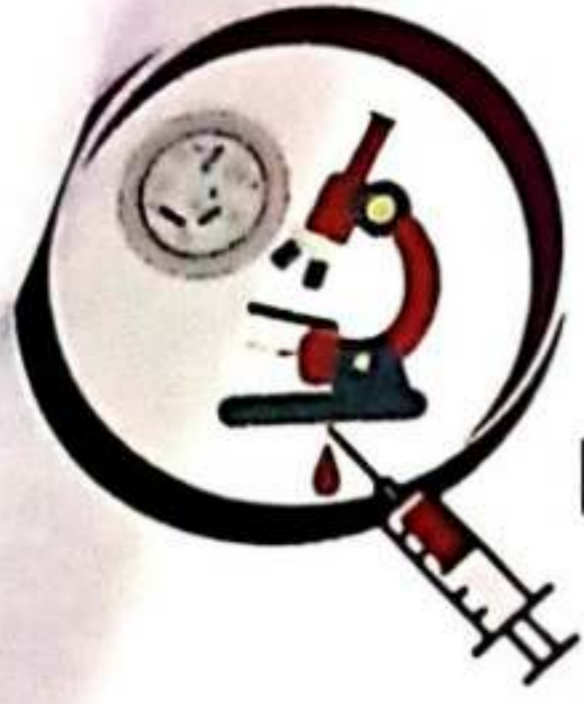KBW
Dr. Kailash B. Wagh
MD (Micro) DCP

Dr. Kailash B. Wagh
M.D. Microbiology D.C.P.
Reg. No. 2001/07/2704

98 Jilha Peth, Kantai Sabhagruh Road, Near Barde Medical, Jalgaon- 425001
0257-2970978, 2225322 9405887735



Scanned with OKEN Scanner



Manavata

Pathology & Microbiology Laboratory

Dr. Kailash B. Wagh
M.D. Microbiology D.C.P
Reg No. 2001/07/2704

REG NO. : 11-2023-OPD / 7
NAME : Mrs. MONALI BORKAR
REF BY : Dr . Sunil Suryavanshi (Insurance)
M.D.

AGE : 37 Years
SEX : Female
DATE : 27-Nov-2023

LOCATION :

BLOOD GROUP

<u>TESTS</u>	<u>RESULTS</u>	<u>UNIT</u>
BLOOD GROUP	: "O" Rh Positive	
NOTE	: Grouping and cross matching is compulsory before blood transfusion, as errors can occur due to irregular antibodies.	

HBA1C

<u>TESTS</u>	<u>RESULTS</u>	<u>UNIT</u>
HbA1C	: 4.8	%
AVERAGE BLOOD SUGAR (ABG)	: 91	mg/dl

Reference Range :

Below 6.0% - Normal Value
6.0% - 7.0% - Good Control
7.0% - 8.0% - Fair Control
8.0% - 10% - Unsatisfactory Control
Above 10% - Poor Control

Method : Fully Automated H.P.L.C. using Biorad Variant II Turbo, NGSP Certified.

Please correlate with clinical conditions.

THANKS FOR REFERRAL

KBW
Dr. Kailash B. Wagh
MD (Micro) DCP

Dr. Kailash B. Wagh
M.D. Microbiology D.C.P.
Reg. No. 2001/07/2704



98 Jilha Peth, Kantai Sabhagruh Road, Near Barde Medical, Jalgaon- 425001
☎ 0257-2970978, 2225322 ☎ 9405887735



Manavata

Pathology & Microbiology Laboratory

Dr. Kailash B. Wagh
M.D. Microbiology D.C.P
Reg No. 2001/07/2704

REG NO. : 11-2023-OPD / 7
NAME : Mrs. MONALI BORKAR
REF BY : Dr . Sunil Suryavanshi (Insurance)
M.D.

AGE : 37 Years
SEX : Female
DATE : 27-Nov-2023

LOCATION :

BLOOD SUGAR FASTING & POST-PRANDIAL

<u>TESTS</u>	<u>RESULTS</u>	<u>UNIT</u>	<u>REFERENCE RANGE</u>
BLOOD SUGAR FASTING	: 81	mg/dl	70 - 110
URINE SUGAR FASTING	: Nil		
BLOOD SUGAR PP	: 98	mg/dl	70 - 140
URINE SUGAR PP	: Nil		

LIVER FUNCTION TEST

<u>TESTS</u>	<u>RESULTS</u>	<u>UNIT</u>	<u>REFERENCE RANGE</u>
BILIRUBIN- TOTAL	: 0.73	mg/dl	0 - 1.0
BILIRUBIN- DIRECT	: 0.15	mg/dl	0 - 0.3
BILIRUBIN- INDIRECT	: 0.58	mg/dl	0.1 - 1.0
SGPT	: 21	IU/L	0 - 40
SGOT	: 36	IU/L	0 - 45
ALKALINE PHOSPHATASE	: 184	IU/L	25 - 350
TOTAL PROTIEN	: 6.12	gm/dl	6 - 8
ALBUMIN	: 3.86	gm/dl	3.5 - 5
GLOBULIN	: 2.26	gm/dl	2 - 3.5
A/G Ratio	: 2.01		2 - 2.5
GGTP	: 13	IU/l	0 - 25

Kaw

Dr. Kailash B. Wagh
MD (Micro) DCP

Dr. Kailash B. Wagh
M.D. Microbiology D.C.P.
Reg. No. 2001/07/2704



24 HOURS FOR REFERRAL

98 Jilha Peth, Kantai Sabhagruh Road, Near Barde Medical, Jalgaon- 425001
0257-2970978, 2225322 9405887735



Scanned with OKEN Scanner



Manavata

Pathology & Microbiology Laboratory

Dr. Kailash B. Wagh
M.D. Microbiology D.C.P
Reg No. 2001/07/2704

REG NO. : 11-2023-OPD / 7
NAME : Mrs. MONALI BORKAR
REF BY : Dr . Sunil Suryavanshi (Insurance)
M.D.

AGE : 37 Years
SEX : Female
DATE : 27-Nov-2023

LOCATION :

KIDNEY FUNCTION TEST

<u>TESTS</u>	<u>RESULTS</u>	<u>UNIT</u>	<u>REFERENCE RANGE</u>
BLOOD UREA NITROGEN	: 16	mg/dl	5 - 21
CREATININE	: 0.81	mg/dl	0.7 - 1.4
URIC ACID	: 2.78	mg/dl	2.6 - 6.0

LIPID PROFILE

<u>TESTS</u>	<u>RESULTS</u>	<u>UNIT</u>	<u>REFERENCE RANGE</u>
TOTAL CHOLESTEROL	: 168	mg/dl	140 - 250
TRIGLYCERIDES	: 56	mg/dl	40 - 140
HDL- CHOLESTEROL	: 42	mg/dl	32 - 90
LDL- CHOLESTEROL	: 114.8	mg/dl	80 - 150
VLDL-CHOLESTEROL	: 11.2	mg/dl	10 - 35
TOTAL CHO/HDL RATIO	: 4		0 - 5.1
LDL/HDL RATIO	: 2.73	mg/dl	0 - 3.5
NON HDL CHOLESTEROL	: 126	mg/dl	0 - 160

THANKS FOR REFERRAL

KBW
Dr. Kailash B. Wagh
MD (Micro) DCP
Dr. Kailash B. Wagh
M.D. Microbiology D.C.P.
Reg. No. 2001/07/2704



98 Jilha Peth, Kantai Sabhagruh Road, Near Barde Medical, Jalgaon- 425001
0257-2970978, 2225322 9405887735



Manavata

Pathology & Microbiology Laboratory

Dr. Kailash B. Wagh
M.D. Microbiology D.C.P
Reg No. 2001/07/2704

REG NO. : 11-2023-OPD / 7
NAME : Mrs. MONALI BORKAR
REF BY : Dr . Sunil Suryavanshi (Insurance)
M.D.

AGE : 37 Years
SEX : Female
DATE : 27-Nov-2023

LOCATION :

THYROID TEST

<u>TESTS</u>	<u>RESULTS</u>	<u>UNIT</u>	<u>REFERENCE RANGE</u>
T3	: 152	ng/ml	87 - 178
T4	: 9.42	µg/dl	6.06 - 12.23
ULTRA TSH	: 4.53	µIU/ml	0.34 - 5.6

NOTE : Test Done On Fully Automated Mindray CL 900i Hormone Assay BY CLIA

THANKS FOR REFERRAL

KBW
Dr. Kailash B. Wagh
MD (Micro) DCP

Dr. Kailash B. Wagh
M.D. Microbiology D.C.P.
Reg. No. 2001/07/2704



98 Jilha Peth, Kantai Sabhagruh Road, Near Barde Medical, Jalgaon- 425001
0257-2970978, 2225322 9405887735



Manavata

Pathology & Microbiology Laboratory

Dr. Kailash B. Wagh
M.D. Microbiology D.C.P
Reg No. 2001/07/2704

REG NO. : 11-2023-OPD / 7
NAME : Mrs. MONALI BORKAR
REF BY : Dr . Sunil Suryavanshi (Insurance)
M.D.

AGE : 37 Years
SEX : Female
DATE : 27-Nov-2023

LOCATION :

URINE ANALYSIS REPORT

<u>TESTS</u>	<u>RESULTS</u>	<u>UNIT</u>	<u>REFERENCE RANGE</u>
PHYSICAL EXAMINATION			
QUANTITY	: 10 ml		
COLOUR	: Pale Yellow		
APPEARANCE	: Clear		
DEPOSITS	: Absent		
SPECIFIC GRAVITY	: 1.026		1.002 - 1.030
REACTION (PH)	: Acidic		
CHEMICAL EXAMINATION			
PROTEINS	: Absent		
SUGAR	: Absent		
KETONE	: Absent		
BILE SALTS/BILE PIGMENTS	: Absent		
MICROSCOPIC EXAMINATION			
RBC	: Absent	/hpf	
PUS CELLS	: 2-3	/hpf	
EPITHELIAL CELLS	: Occasional	/hpf	
CASTS	: Absent		
CRYSTALS	: Absent		
AMORPHOUS DEPOSITS	: Absent		

THANKS FOR REFERRAL

KBW
Dr. Kailash B. Wagh
MD (Micro) DCP
Reg. No. 2001/07/2704
M.D. Microbiology D.C.P.
Dr. Kailash B. Wagh



98 Jilha Peth, Kantai Sabhagruh Road, Near Barde Medical, Jalgaon- 425001
☎ 0257-2970978, 2225322 ☎ 9405887735



Scanned with OKEN Scanner



ARYA

PATHOLOGY LABORATORY

Add.: "Near Telephone Office, Parik Park" JALGAON. Mob. 9881929722, 9096135952, 8855072749

Patient's Name : MONALI BORKAR

Age : 37 yrs Sex : FEMALE

Ref : Dr SUNIL SURYAWANSHI SIR MD

Date : 27/11/2023

PAP CYTOLOGY REPORT

PAP smears show clusters of superficial and intermediate cells with few parabasal, basal cells. Background shows few RBCs and inflammatory infiltrate of polymorphs, macrophages.

Negative for candida/intraepithelial lesion / malignancy.

IMPRESSION: SUGGESTIVE OF INFLAMMATORY SMEAR.

*** END OF REPORT ***

24 Hours Emergency Service


Dr. Vinod R. Mahajan
M.D. (Path.)
Consulting Pathologist

डॉ. सौ. जयश्री सुर्यवंशी
एम.डी.
(स्त्रीरोग व प्रसुतीशास्त्र तज्ञ)
रजि.नं. 3712

डॉ. सुनिल सुर्यवंशी
एम.डी.(मेडिसीन) पुणे
कन्सल्टिंग फिजिशियन
रजि.नं. 2223

पत्ता : मेन टेलिफोन एक्सचेंज समोर, पारिख
पार्क जवळ, नविन बस स्टॅन्डच्या मागे,
जळगांव. फोन : (0257) 2227821

उपलब्ध सुविधा : • एक्स-रे • सोनोग्राफी • इकोकार्डिओग्राफी • सुसज्ज ऑपरेशन थिएटर • कॉम्प्युटाइज्ड ड.सी.जी. • स्ट्रेस टेस्ट • पल्मोनरी फंक्शन टेस्ट

Rx

दि 27 / 11 / 20 23

PHYSICIAN CONSULTATION

MRS MONALI SACHIN BORKAR, 37 YRS FEMALE

NO CARDIORESPIRATORY COMPLAINTS.

K/C/O HYPOTHYROID UNDER RX

NOT A K/C/O HT, DM, IHD, BRONCHIAL ASTHAMA

NO ALLERGY TO ANY MEDICATIONS. NO ADDICTION.

P- 72/ MIN, BP-107/78 mmHg

RS/CVS/PA/CNS- NORMAL

DENTAL CONSULTATION- NORMAL

EYE CHECK UP- NORMAL


ENT CHECK UP- NORMAL.

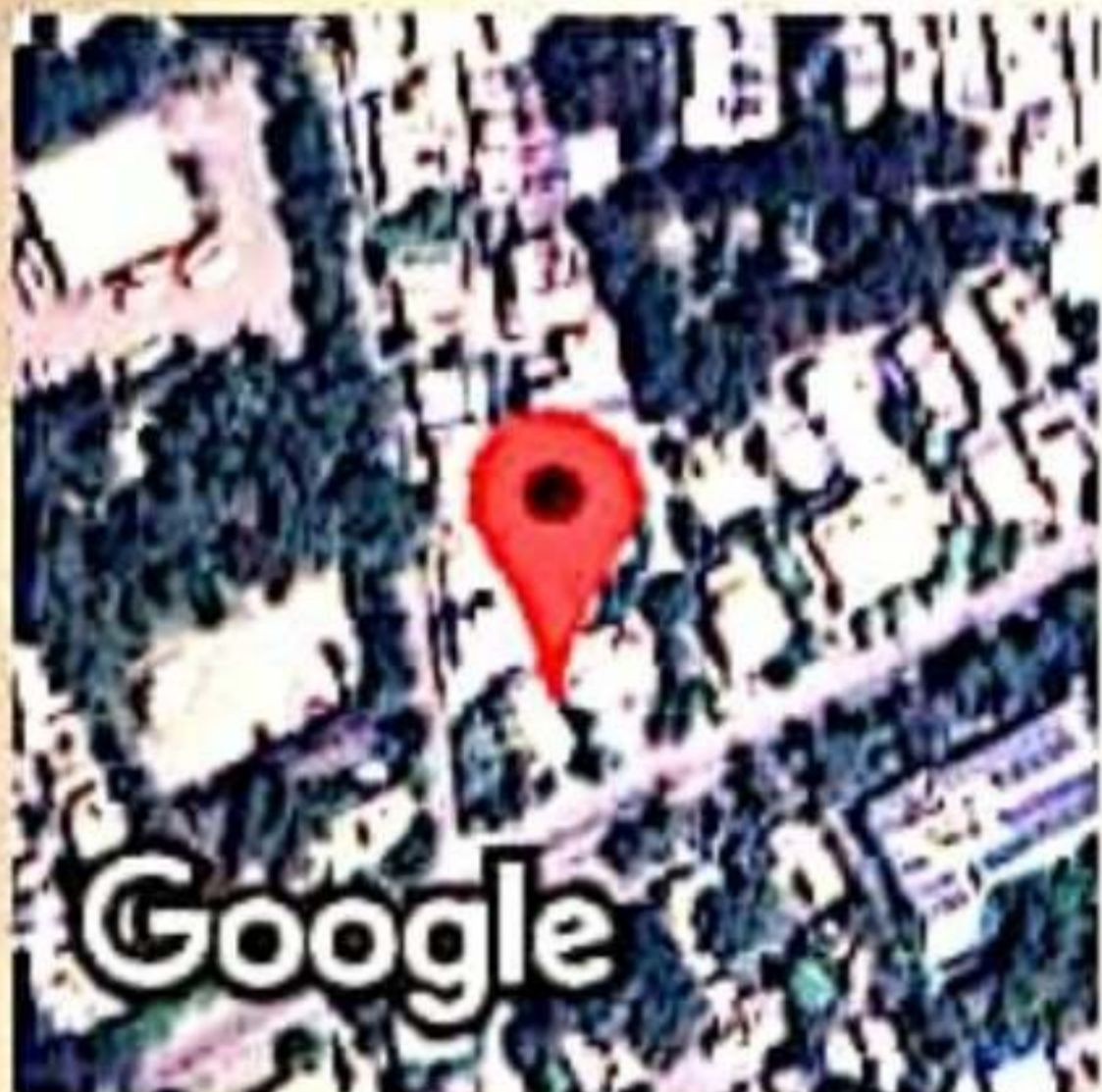DIET- BALANCED DIET

BMI- 24.8., NORMAL .

परत येतांना कागद सोबत आणावा.



 **GPS Map Camera**



Jalgaon, Maharashtra, India

**A4/1285, RR School Rd, Omkar Nagar, Sbi Colony, Jalgaon,
Maharashtra 425001, India**

Lat 21.006294°

Long 75.566374°

27/11/23 10:05 AM GMT +05:30

आधार कार्ड / YOUR AADHAR NO. :

8098 5860 3609

VID : 9136 3603 7780 7837

माझे आधार, माझी ओळख



भारत सरकार

Government of India



मोनली सचिन बोरकर

Monali Sachin Borkar

जन्म तारीख/DOB: 28/09/1986

महिला/ FEMALE

Issue Date: 17/01/2018

Download Date: 27/08/2021

8098 5860 3609

VID : 9136 3603 7780 7837

माझे आधार, माझी ओळख

Bank of Baroda

ECG
Bld, urine
Lx rx

Client Contact No:
Agent contact No:

9579212260

Name/नाव- Monali Sachin Bhalcar

Personal information (वैयक्तिक माहिती)

Age/ वय- 38 ³⁷ Date/जन्मतारीख

28/9/1986

Any habit/सवयी - NO -

Identification Mark:- - mole neck

Any disease like diabetes, blood pressure, /आजार डायबेटीज, ब्लड प्रेशर, ईतर - Thyroid :: 2015

Any surgery/ operation/ accident during last 5 years/मागच्या 5 वर्षांत एखादे ऑपरेश - NO Thyroid 50

Family history/कुटुंबाविषयी माहिती - 3

Father/वडील - Arun Bhanjari

Live/हयात ✓ Age/वय - 70 Disease/काही आजार - NO

Death/मृत - NO

Age When died/त्यावेळेस वय - Cause/कारण -

Mother/आई - Sindhu Bhanjari

Live/हयात ✓ Age/वय - 50 Cause/कारण -

Age When died/ त्यावेळेस वय - Cause/कारण -

Brother/भाऊ NO Age/वय -

Disease/ health/आजार/निरोग -

Sister/बहीण - ~~4~~ Age/वय No idea

Disease/health/आजार/निरोगी -

covid vaccine type

1 st dose ✓

2nd dose ✓

education - MBA (HR)

occupation -

married ✓

Signature: Monali Bhalcar

HOSPITAL USE ONLY

Height: 162

Weight: 65

Chest: 92

Abdomen: 86

Blood Pressure: 107 / 78 P. 72.

ENT
EYE
Dental

Diet = Low fat / low carb / high protein diet