

CLUMAX DIAGNOSTICS

--- A MEDALL COMPANY ---

Date 28-Dec-2021 8:11 AM

Customer Name : **MR.S HAMEED**DOB : **01 Aug 1966**Ref Dr Name : **MediWheel**Age : **55Y/MALE**Customer Id : **MED110831120**Visit ID : **421100662**

Email Id :

Phone No : **9632666984**Corp Name : **MediWheel**

Address :

Package Name : **Mediwheel Full Body Health Checkup Male Above 40***Complementary Breakfast*

S.No	Modality	Study	Accession No	Time	Seq	Signature
1	LAB	BLOOD UREA NITROGEN (BUN)				
2	LAB	CREATININE				
3	LAB	GLUCOSE - FASTING				
4	LAB	GLUCOSE - POSTPRANDIAL (2 HRS)				
5	LAB	GLYCOSYLATED HAEMOGLOBIN (HbA1c)				
6	LAB	URIC ACID				
7	LAB	LIPID PROFILE				
8	LAB	LIVER FUNCTION TEST (LFT)				
9	LAB	TOTAL PROSTATE SPECIFIC ANTIGEN - PSA				
10	LAB	THYROID PROFILE/ TFT(T3, T4, TSH)				
11	LAB	URINE GLUCOSE - FASTING				
12	LAB	URINE GLUCOSE - POSTPRANDIAL (2 Hrs)				
13	LAB	COMPLETE BLOOD COUNT WITH ESR				
14	LAB	STOOL ANALYSIS - ROUTINE				
15	LAB	URINE ROUTINE				
16	LAB	BUN/CREATININE RATIO				
17	LAB	BLOOD GROUP & RH TYPE				

18	OTHERS	Treadmill / 2D Echo ✓	IND128047914690			
19	OTHERS	physical examination	IND128047915279			
20	US	ULTRASOUND ABDOMEN	IND128047915292			
21	OTHERS	Dental Consultation	IND128047916289			
22	OTHERS	EYE CHECKUP	IND128047917756			
23	X-RAY	X RAY CHEST	IND128047918659			
24	ECG	ELECTROCARDIOGRAM ECG	IND128047918721			
25	OTHERS	Consultation Physician	IND128047918736			

Registered By
(PREETHA.R)

HT - 171
WT - 80.2
BP - 120/80
Pulse - 65
waist - 34
HIP - 40

Customer Name	MR.S HAMEED	Customer ID	MED110831120
Age & Gender	55Y/MALE	Visit Date	28/12/2021
Ref Doctor	MediWheel		

ABDOMINO-PELVIC ULTRASONOGRAPHY

LIVER is normal in shape, size and has uniform echopattern. No evidence of focal lesion or intrahepatic biliary ductal dilatation. Hepatic and portal vein radicals are normal.

GALL BLADDER shows normal shape and has clear contents. Gall bladder wall is of normal thickness. CBD is of normal calibre.

PANCREAS has normal shape, size and uniform echopattern. No evidence of ductal dilatation or calcification.

SPLEEN shows normal shape, size and echopattern. Spleen measures 8.9cms in long axis and 3.6cms in short axis. No demonstrable Para -aortic lymphadenopathy.

KIDNEYS move well with respiration and have normal shape, size and echopattern. Cortico- medullary differentiations are well madeout. No evidence of calculus or hydronephrosis.

The kidney measures as follows:

	Bipolar length (cms)	Parenchymal thickness (cms)
Right Kidney	9.1	1.2
Left Kidney	9.2	1.2

URINARY BLADDER shows normal shape and wall thickness. It has clear contents. No evidence of diverticula.
Prevoid: 420cc
Postvoid: 15cc


PROSTATE is mildly enlarged in size. It measures 3.8 x 3.6 x 3.6cms (Vol:26cc).

No evidence of ascites / pleural effusion.

IMPRESSION:

➤ **MILD PROSTATOMEGALY.**

DR. H.K. ANAND
CONSULTANT RADIOLOGISTS
MS/up


DR. MEERA S



Mr S Hameed
ID: MED110831120

Vital Signs™ 226 166 05

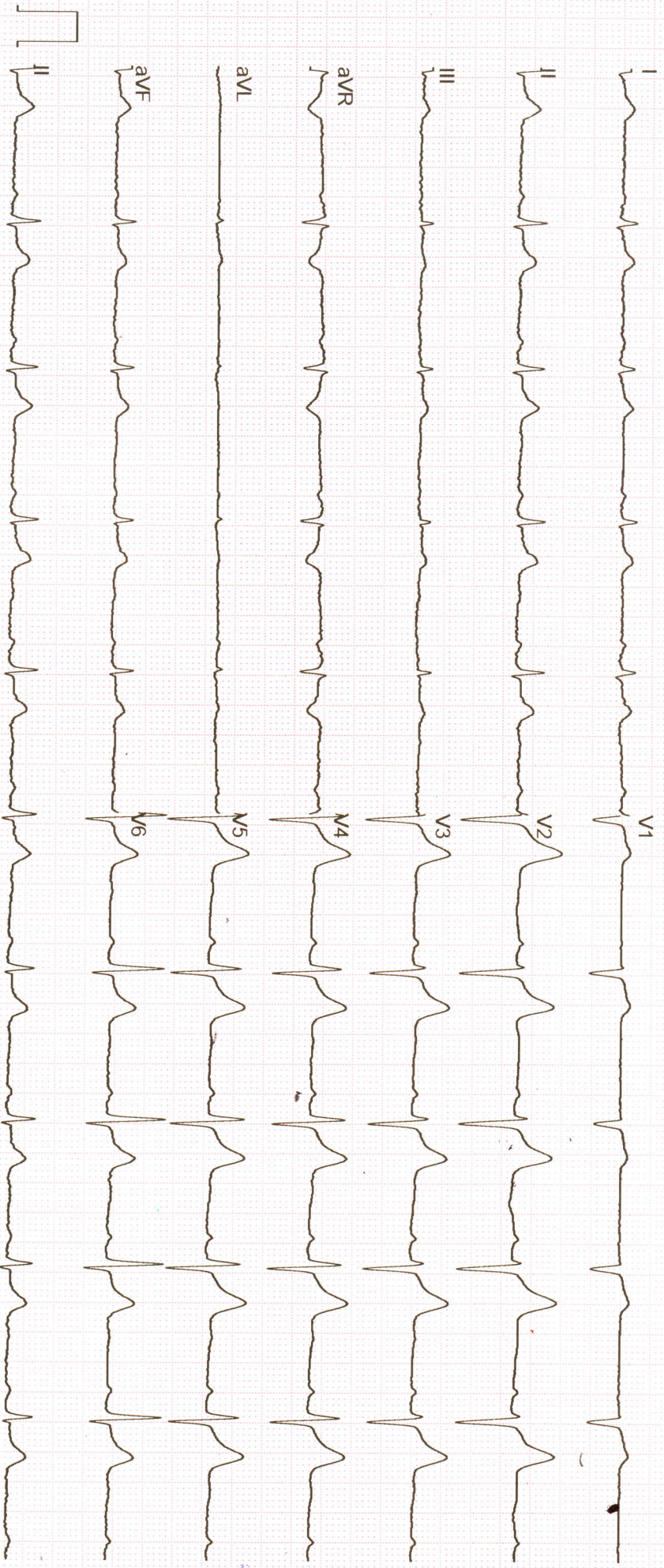
55 Years

Male

28.12.2021 9:49:33
CLUMAX DIAGNOSTICS
THIPPASANDRA
BANGALORE

QRS	82 ms
QT/QTcBaz	398 / 398 ms
PR	178 ms
P	62 ms
RR/PP	1000 / 1000 ms
P/QRS/T	48 / 73 / 60 degrees

Normal ECG
H



GE MAC2000 1.1 12SL™ V241

25 mm/s 10 mm/mV

ADS 0.56-20 Hz 50 Hz

2x5x6_25_R1

Unconfirmed

1/1

60 bpm
-- / -- mmHg

CE 0637

LOT D 641

SUSTANANKS

Name	S HAMEED	Customer ID	MED110831120
Age & Gender	55Y/M	Visit Date	Dec 28 2021 8:11AM
Ref Doctor	MediWheel		

X - RAY CHEST PA VIEW

Bilateral lung fields appear normal.

Cardiac size is within normal limits.

Bilateral hilar regions appear normal.

Bilateral domes of diaphragm and costophrenic angles are normal.

Visualised bones and soft tissues appear normal.

IMPRESSION:

No significant abnormality detected.

DR. H.K. ANAND

DR. SHWETHA S

DR. CHARUL


DR. APARNA

CONSULTANT RADIOLOGISTS



Customer Name	MR.S HAMEED	Customer ID	MED110831120
Age & Gender	55Y/MALE	Visit Date	28/12/2021
Ref Doctor	MediWheel		

2 D ECHOCARDIOGRAPHIC STUDY

M mode measurement:

AORTA		: 3.1cms
LEFT ATRIUM		: 3.6cms
AVS		: ----
LEFT VENTRICLE	(DIASTOLE)	: 4.4cms
	(SYSTOLE)	: 3.0cms
VENTRICULAR SEPTUM	(DIASTOLE)	: 0.9cms
	(SYSTOLE)	: 1.3cms
POSTERIOR WALL	(DIASTOLE)	: 0.9cms
	(SYSTOLE)	: 1.3cms
EDV		: 87ml
ESV		: 35ml
FRACTIONAL SHORTENING		: 32%
EJECTION FRACTION		: 60%
EPSS		: ---
RVID		: 2.0cms

DOPPLER MEASUREMENTS:

MITRAL VALVE	: 'E' 0.54 m/s	'A' 0.66 m/s	NO MR
AORTIC VALVE	: 1.38 m/s		NO AR
TRICUSPID VALVE	: 'E' 2.05 m/s	'A' - m/s	NO TR
PULMONARY VALVE	: 0.78 m/s		NO PR



Customer Name	MR.S HAMEED	Customer ID	MED110831120
Age & Gender	55Y/MALE	Visit Date	28/12/2021
Ref Doctor	MediWheel		

2D ECHOCARDIOGRAPHY FINDINGS:

Left ventricle : Normal size, Normal systolic function.
No regional wall motion abnormalities.

Left Atrium : Normal.

Right Ventricle : Normal.

Right Atrium : Normal.

Mitral valve : Normal, No mitral valve prolapsed.

Aortic valve : Normal, Trileaflet.

Tricuspid valve : Normal.

Pulmonary valve : Normal.

IAS : Intact.

IVS : Intact.

Pericardium : No pericardial effusion.

IMPRESSION:

- LV DIASTOLIC DYSFUNCTION.
- NORMAL SIZED CARDIAC CHAMBERS.
- NORMAL LV SYSTOLIC FUNCTION. EF: 60%.
- NO REGIONAL WALL MOTION ABNORMALITIES.
- NORMAL VALVES.
- NO CLOTS / PERICARDIAL EFFUSION / VEGETATION.

DR. K.S. SUBRAMANI. MBBS, MD, DM (CARDIOLOGY) FESC
SENIOR CONSULTANT INTERVENTIONAL CARDIOLOGIST

Kss/da

Note:

- * Report to be interpreted by qualified medical professional.
- * To be correlated with other clinical findings.
- * Parameters may be subjected to inter and intra observer variations.

SUBRAMANI.K.S.
MD, DM (CARDIOLOGY)
Consultant Cardiologist
KMC REG No : 46604
Clumax Diagnostics





ಶ್ರೀ ಪಾರ್ವತಿ ಆಪ್ಟಿಕ್ಸ್

SRI PARVATHI OPTICS

Multi Branded Opticals Store

Computerized Eye Testing & Spectacles Clinic

333.8th Main 5th Cross Near Cambridge & Miranda School HAL 3rd Stage
Behind Vishveshvariah Park New Thippasandra, Bangalore - 560075,
Email: parvathiopticals@gmail.com

Mahesh
Mob: 8618385220
9901569756

SPECTACLE PRESCRIPTION

Name: *Hameed S.*

No. **120**

Mobil No: *9632666984*

Date: *28/12/2021*

Age / Gender *55y/M*

Ref. No.

	RIGHT EYE				LEFT EYE			
	SPH	CYL	AXIS	VISION	SPH	CYL	AXIS	VISION
DISTANCE	<i>Plano</i>				<i>Plano</i>			
NEAR	<i>Add +2.50 B6</i>							

PD *62MM*

Advice to use glasses for:

DISTANCE FAR & NEAR READING COMPUTER PURPOSE

We Care Your Eyes

SRI PARVATHI OPTICS

NEW THIPPASANDRA