

Name : Mrs. YAMINI SHARMA

Age: 33 Y

UHID: CWAN.0000130293

Sex: F



OP Number: CWANOPV214197

Bill No : CWAN-OCR-47331

Date : 26.08.2023 09:46

Address : PUNE

Plan : ARCOFEMI MEDIWHEEL FEMALE AHC CREDIT PAN
INDIA OP AGREEMENT

Sno	Service Type/ServiceName	Department
1	ARCOFEMI - MEDIWHEEL - FULL BODY HEALTH ANNUAL PLUS CHECK - FEMALE - 2D ECHO - PAN INDIA - FY2324	
1	URINE GLUCOSE(FASTING)	
2	GAMMA GLUTAMYL TRANSFERASE (GGT)	
3	HbA1c, GLYCATED HEMOGLOBIN	
✓4	2 D ECHO	
5	LIVER FUNCTION TEST (LFT)	
6	X-RAY CHEST PA	
7	GLUCOSE, FASTING	
8	HEMOGRAM + PERIPHERAL SMEAR	
9	ENT CONSULTATION	
10	FITNESS BY GENERAL PHYSICIAN	
11	GYNAECOLOGY CONSULTATION	
12	DIET CONSULTATION	
13	COMPLETE URINE EXAMINATION	
14	URINE GLUCOSE(POST PRANDIAL)	
15	PERIPHERAL SMEAR	
✓16	ECG — <u>IN</u> 10:23 out 10:33	
17	BLOOD GROUP ABO AND RH FACTOR	
18	LIPID PROFILE	
19	BODY MASS INDEX (BMI)	
✓20	LBC PAP TEST- PAPSURE	
✓21	OPHTHAL BY GENERAL PHYSICIAN	
22	RENAL PROFILE/RENAL FUNCTION TEST (RFT/KFT)	
23	ULTRASOUND - WHOLE ABDOMEN	
24	THYROID PROFILE (TOTAL T3, TOTAL T4, TSH)	
✓25	DENTAL CONSULTATION	
26	GLUCOSE, POST PRANDIAL (PP), 2 HOURS (POST MEAL)	

dental

HT - 160 cm

wt - 62.5 kg.

BP - 90/60 mmHg.



Date : 26-08-2023

Department : GENERAL

MR NO : CWAN.0000130293

Doctor :

Name : Mrs. YAMINI SHARMA

Registration No :

Age/ Gender : 33 Y / Female

Qualification :

Consultation Timing: 09:45

Height : <i>160cm</i>	Weight : <i>62.5kg</i>	BMI :	Waist Circum :
Temp :	Pulse :	Resp :	B.P : <i>90/60</i>

General Examination / Allergies
History

F.H. - HNS,

Clinical Diagnosis & Management Plan

For AMC

*- Has back pain -
 O/E: Has tenderness in the
 Rt. area of the mid-back region
 CVS
 CVS
 Resp. was
 Abd. was*

Adv: Vit. D3 & B12 levels

DR. MUSHEVA BAHRAINWALA
 M.B.B.S
 Reg. No.: 47527
 Apollo Clinic Wanowrie
 NIBM Road, Kondhwa.

Follow up date:

Doctor Signature

AC1200 ST SHARMA, YAMINI 000130293, APOLLO CLINIC WANOWURIE

le, 33 Years (15.04.1990)

HR 62 bpm

WNL

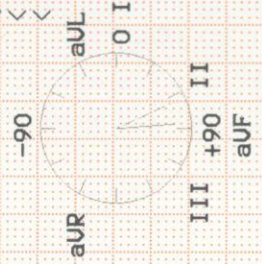
Measurement Results:

P : 98 ms
 TcB : 382 / 390 ms
 : 196 ms
 : 114 ms
 P : 958 / 900 ms
 S/T : 85 / 85 / 65 degrees
 QTcBD : 66 / 67 ms
 low : 1.3 mV
 : 8

Interpretation:

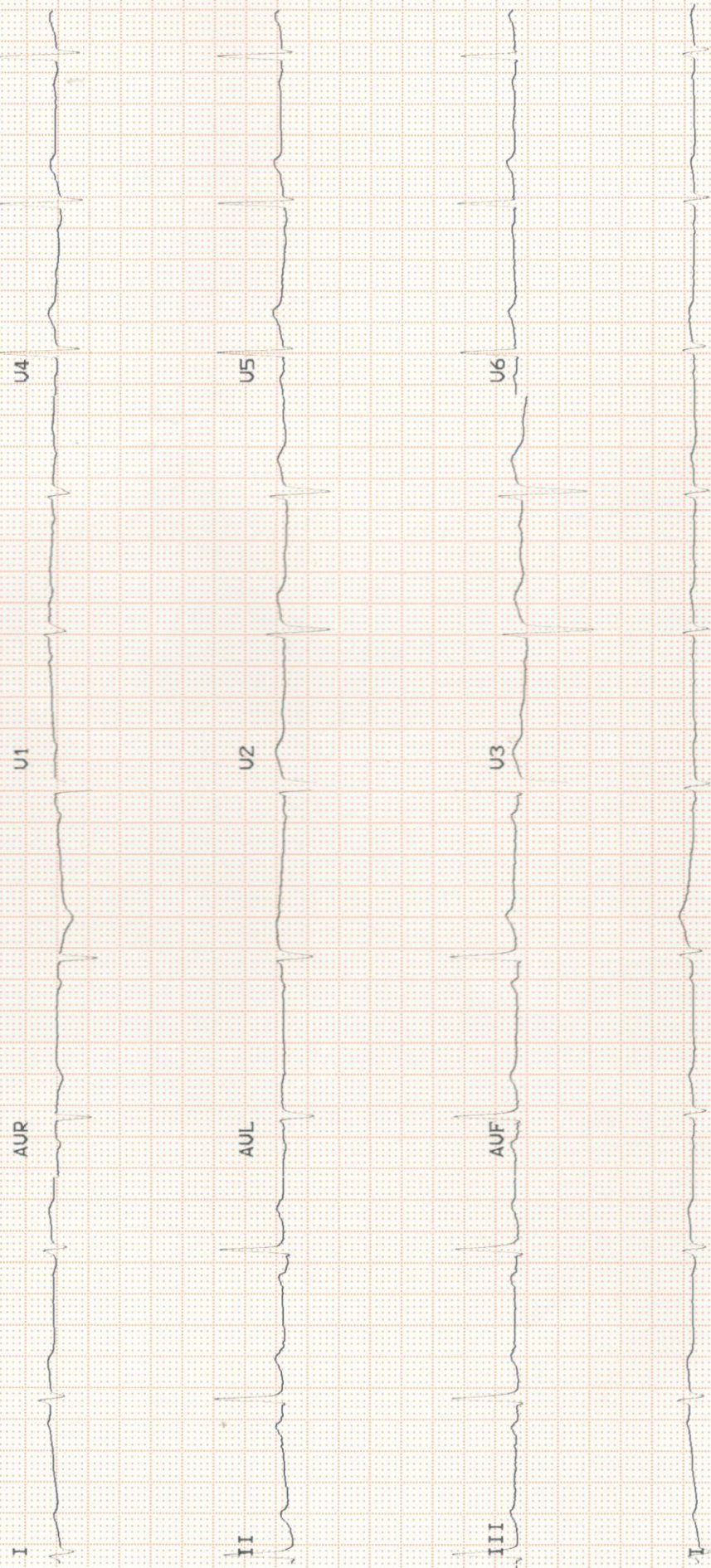
normal ECG

< P
 < T
 < QRS



DR. MUSHFIYA BAHRAINWALA
 M.B.B.S
 Reg. No.: 47527
 Apollo Clinic Wanowarie
 NIBM Road, Kondl.wa.

Unconfirmed report.



The Apollo Clinic

Wanowrie
Pune-411048

PATIENT NAME :- Mrs. Yamin, S.

DATE :- 26/8/22

AGE/SEX :- 33 / F

UHID :

EYE CHECK UP

COMPLETE

PREMEDICAL/OTHER

	RIGHT EYE	LEFT EYE
Far Vision	6/6 plus	6/6 plus
Near Vision	N/6 ✓	N/6 ✓
Anterior Segment Pupil	NORMAL ✓	NORMAL
Fundus	NORMAL ✓	NORMAL
Colour Vision	NORMAL ✓	NORMAL
Iop	NORMAL NA	NORMAL
Family History/Medical History	NA	

IMPRESSION :- Emmetropia

Advice :- Use computer glasses

[Signature]
Ophthalmologist



Apollo Health and Lifestyle Limited

(CIN - U85110TG2000PLC115819)

Regd. Office: 1-10-60/62, Ashoka Raghupathi Chambers, 5th Floor, Begumpet, Hyderabad, Telangana - 500 016.
Ph No: 040-4904 7777, Fax No: 4904 7744 | Email ID: enquiry@apollohl.com | www.apollohl.com

APOLLO CLINICS NETWORK MAHARASHTRA

Pune (Aundh | Kharadi | Nigdi Pradhikaran | Viman Nagar | Wanowrie)

Online appointments: www.apolloclinic.com

TO BOOK AN APPOINTMENT

1860 500 7788

Patient Name : Mrs. YAMINI SHARMA

Age : 33 Y F

UHID : CWAN.0000130293

OP Visit No : CWANOPV214197

Reported on : 26-08-2023 11:07

Printed on : 26-08-2023 11:07

Adm Consult Doctor :

Ref Doctor : SELF

DEPARTMENT OF RADIOLOGY

X-RAY CHEST PA

Both lung fields and hila are normal .

No obvious active pleuro-parenchymal lesion seen .

Both costophrenic and cardiophrenic angles are clear .

Both diaphragms are normal in position and contour .


Thoracic wall and soft tissues appear normal.

CONCLUSION :

No obvious abnormality seen.

Printed on:26-08-2023 11:07

---End of the Report---


Dr. SHAAZ AHMED KHAN
MBBS,DMRE
Radiology

Pending Test Form

I, Yamini Sharma visiting from _____
_____ Company for health check.

UHIP: - _____ Date: - ²⁵⁻⁸ 10-SEP-23

This is a consent form to inform you that I do not wish to do this test. ENT con, Gynaecology con

(PP) Post May, Sonography - I will do it after - 10-15 days

Or will be doing their test later on 9/10-SEP-23 - I have already done on it 10 days back

Signature: -  _____



2D ECHOCARDIOGRAPHY & COLOR DOPPLER STUDY

Name : MRS.YAMINI SHARMA Age/Sex : 33/F Date : 26/08/2023

2D Echo:-

Cardiac chamber dimensions –Normal

Wall motion abnormalities - no RWMA

LV systolic function - Normal, LVEF -60%

LV diastolic function – Diastolic flows are normal.

Cardiac valves -

Mitral valve –Mild mitral valve prolapse, trivial mitral regurgitation.

Aortic valve – Three thin leaflets, no aortic regurgitation, Aortic PG –5.2mm Hg

Tricuspid valve – Mild tricuspid regurgitation, No PAH, PASP by TR jet -25 mm Hg

Pulmonary valve - normal

Septae (IAS/IVS) – intact

Clot/vegetation/Pericardial effusion – No

Great Arteries (Aorta/pulmonary artery) - Normal

IVC - Normal

Measurements -

Aorta	LA	IVS	PWD	LVIDd	LVIDs	LVEF
26	29	09	09	39	22	60%

Conclusion:-

Normal chamber dimensions.

No RWMA, normal LV systolic function, LVEF – 60%

No LV Diastolic dysfunction.

Normal PA pressure.



Dr. Bhushan Bari
DNB Medicine, DNB Cardiology
Consultant and Interventional Cardiologist

Patient Name : Mrs.YAMINI SHARMA	Certificate No: M-163	Collected : 26/Aug/2023 09:53AM
Age/Gender : 33 Y 4 M 11 D/F		Received : 26/Aug/2023 12:13PM
UHID/MR No : CWAN.0000130293		Reported : 26/Aug/2023 01:09PM
Visit ID : CWANOPV214197		Status : Final Report
Ref Doctor : Dr.SELF		Sponsor Name : ARCOFEMI HEALTHCARE LIMITED
Emp/Auth/TPA ID : 186315		

DEPARTMENT OF BIOCHEMISTRY

ARCOFEMI - MEDIWHEEL - FULL BODY HEALTH ANNUAL PLUS CHECK - FEMALE - 2D ECHO - PAN INDIA - FY2324

Test Name	Result	Unit	Bio. Ref. Range	Method
GAMMA GLUTAMYL TRANSPEPTIDASE (GGT) , SERUM	17.50	U/L	<38	IFCC



SIN No:SE04463462

This test has been performed at Apollo Health and Lifestyle Ltd- Sadashiv Peth Pune, Diagnostics Lab

Patient Name : Mrs.YAMINI SHARMA	Certificate No: M-163	Collected : 26/Aug/2023 09:53AM
Age/Gender : 33 Y 4 M 11 D/F		Received : 26/Aug/2023 12:13PM
UHID/MR No : CWAN.0000130293		Reported : 26/Aug/2023 01:10PM
Visit ID : CWANOPV214197		Status : Final Report
Ref Doctor : Dr.SELF		Sponsor Name : ARCOFEMI HEALTHCARE LIMITED
Emp/Auth/TPA ID : 186315		

DEPARTMENT OF IMMUNOLOGY

ARCOFEMI - MEDIWHEEL - FULL BODY HEALTH ANNUAL PLUS CHECK - FEMALE - 2D ECHO - PAN INDIA - FY2324

Test Name	Result	Unit	Bio. Ref. Range	Method
-----------	--------	------	-----------------	--------

THYROID PROFILE TOTAL (T3, T4, TSH) , SERUM				
TRI-IODOTHYRONINE (T3, TOTAL)	0.91	ng/mL	0.64-1.52	CMIA
THYROXINE (T4, TOTAL)	7.48	µg/dL	4.87-11.72	CMIA
THYROID STIMULATING HORMONE (TSH)	1.770	µIU/mL	0.35-4.94	CMIA

Comment:

Note:

For pregnant females	Bio Ref Range for TSH in uIU/ml (As per American Thyroid Association)
First trimester	0.1 - 2.5
Second trimester	0.2 – 3.0
Third trimester	0.3 – 3.0

TSH is a glycoprotein hormone secreted by the anterior pituitary. TSH activates production of T3 (Triiodothyronine) and its prohormone T4 (Thyroxine). Increased blood level of T3 and T4 inhibit production of TSH.

TSH is elevated in primary hypothyroidism and will be low in primary hyperthyroidism. Elevated or low TSH in the context of normal free thyroxine is often referred to as sub-clinical hypo- or hyperthyroidism respectively.

Both T4 & T3 provides limited clinical information as both are highly bound to proteins in circulation and reflects mostly inactive hormone. Only a very small fraction of circulating hormone is free and biologically active.

Significant variations in TSH can occur with circadian rhythm, hormonal status, stress, sleep deprivation, medication & circulating antibodies.

TSH	T3	T4	FT4	Conditions
High	Low	Low	Low	Primary Hypothyroidism, Post Thyroidectomy, Chronic Autoimmune Thyroiditis
High	N	N	N	Subclinical Hypothyroidism, Autoimmune Thyroiditis, Insufficient Hormone Replacement Therapy.

Patient Name : Mrs.YAMINI SHARMA	Certificate No: M-160	Collected : 26/Aug/2023 09:53AM
Age/Gender : 33 Y 4 M 11 D/F		Received : 26/Aug/2023 12:13PM
UHID/MR No : CWAN.0000130293		Reported : 26/Aug/2023 01:10PM
Visit ID : CWANOPV214197		Status : Final Report
Ref Doctor : Dr.SELF		Sponsor Name : ARCOFEMI HEALTHCARE LIMITED
Emp/Auth/TPA ID : 186315		

DEPARTMENT OF IMMUNOLOGY

ARCOFEMI - MEDIWHEEL - FULL BODY HEALTH ANNUAL PLUS CHECK - FEMALE - 2D ECHO - PAN INDIA - FY2324

Test Name	Result	Unit	Bio. Ref. Range	Method
N/Low	Low	Low	Low	Secondary and Tertiary Hypothyroidism
Low	High	High	High	Primary Hyperthyroidism, Goitre, Thyroiditis, Drug effects, Early Pregnancy
Low	N	N	N	Subclinical Hyperthyroidism
Low	Low	Low	Low	Central Hypothyroidism, Treatment with Hyperthyroidism
Low	N	High	High	Thyroiditis, Interfering Antibodies
N/Low	High	N	N	T3 Thyrotoxicosis, Non thyroidal causes
High	High	High	High	Pituitary Adenoma; TSHoma/Thyrotropinoma



SIN No:SPL23121777

This test has been performed at Apollo Health and Lifestyle Ltd- Sadashiv Peth Pune, Diagnostics Lab

Patient Name	: Mrs.YAMINI SHARMA	Certificate No: M-	Collected	: 26/Aug/2023 09:53AM
Age/Gender	: 33 Y 4 M 11 D/F		Received	: 26/Aug/2023 05:05PM
UHID/MR No	: CWAN.0000130293		Reported	: 26/Aug/2023 06:02PM
Visit ID	: CWANOPV214197		Status	: Final Report
Ref Doctor	: Dr.SELF		Sponsor Name	: ARCOFEMI HEALTHCARE LIMITED
Emp/Auth/TPA ID	: 186315			

DEPARTMENT OF CLINICAL PATHOLOGY

ARCOFEMI - MEDIWHEEL - FULL BODY HEALTH ANNUAL PLUS CHECK - FEMALE - 2D ECHO - PAN INDIA - FY2324

Test Name	Result	Unit	Bio. Ref. Range	Method
-----------	--------	------	-----------------	--------

COMPLETE URINE EXAMINATION (CUE) , URINE

PHYSICAL EXAMINATION

COLOUR	PALE YELLOW		PALE YELLOW	Visual
TRANSPARENCY	CLEAR		CLEAR	Visual
pH	<5.5		5-7.5	DOUBLE INDICATOR
SP. GRAVITY	1.015		1.002-1.030	Bromothymol Blue

BIOCHEMICAL EXAMINATION

URINE PROTEIN	NEGATIVE		NEGATIVE	PROTEIN ERROR OF INDICATOR
GLUCOSE	NEGATIVE		NEGATIVE	GLUCOSE OXIDASE
URINE BILIRUBIN	NEGATIVE		NEGATIVE	AZO COUPLING REACTION
URINE KETONES (RANDOM)	NEGATIVE		NEGATIVE	SODIUM NITRO PRUSSIDE
UROBILINOGEN	NORMAL		NORMAL	MODIFIED EHRlich REACTION
BLOOD	NEGATIVE		NEGATIVE	Peroxidase
NITRITE	NEGATIVE		NEGATIVE	Diazotization
LEUCOCYTE ESTERASE	NEGATIVE		NEGATIVE	LEUCOCYTE ESTERASE

CENTRIFUGED SEDIMENT WET MOUNT AND MICROSCOPY

PUS CELLS	2 - 3	/hpf	0-5	Microscopy
EPITHELIAL CELLS	1 - 2	/hpf	<10	MICROSCOPY
RBC	NIL	/hpf	0-2	MICROSCOPY
CASTS	NIL		0-2 Hyaline Cast	MICROSCOPY
CRYSTALS	ABSENT		ABSENT	MICROSCOPY

Comment:

- Biochemical Examination of urine sample was performed by reflectance photometry and confirmed by alternative methods.
- The samples are assessed for integrity and adequacy before processing.



SIN No:UR2173153

This test has been performed at Apollo Health and Lifestyle Ltd- Sadashiv Peth Pune, Diagnostics Lab

Patient Name : Mrs.YAMINI SHARMA	Certificate No: M-10000000000000000000	Collected : 26/Aug/2023 09:53AM
Age/Gender : 33 Y 4 M 11 D/F		Received : 26/Aug/2023 05:05PM
UHID/MR No : CWAN.0000130293		Reported : 26/Aug/2023 06:02PM
Visit ID : CWANOPV214197		Status : Final Report
Ref Doctor : Dr.SELF		Sponsor Name : ARCOFEMI HEALTHCARE LIMITED
Emp/Auth/TPA ID : 186315		

DEPARTMENT OF CLINICAL PATHOLOGY

ARCOFEMI - MEDIWHEEL - FULL BODY HEALTH ANNUAL PLUS CHECK - FEMALE - 2D ECHO - PAN INDIA - FY2324

Test Name	Result	Unit	Bio. Ref. Range	Method
URINE GLUCOSE(FASTING)	NEGATIVE		NEGATIVE	Dipstick

*** End Of Report ***

Result/s to Follow:
LBC PAP TEST (PAPSURE)



Dr Sneha Shah
MBBS, MD (Pathology)
Consultant Pathologist



DR.Sanjay Ingle
M.B.B.S,M.D(Pathology)
Consultant Pathologist



SIN No:UF009359

This test has been performed at Apollo Health and Lifestyle Ltd- Sadashiv Peth Pune, Diagnostics Lab