




भारत सरकार  
GOVERNMENT OF INDIA



Varun Bhatia

1989-10-21

Male

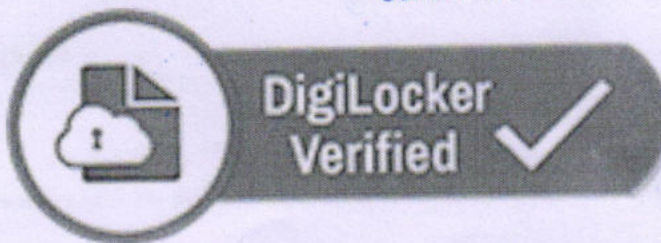XXXXXXXXX4725

*9/13/22  
for health check  
only*

Address:

S/O: Rakesh Bhatia plot-c s-1 shiva homes -  
E-7 extention arera colony Huzur - Bhopal -  
Madhya Pradesh 462016

*R*  
Dr. B. M. Agarwal  
MBBS, DCP  
Consultant Pathologist



आधार-आम आदमी का अधिकार



# दिवाकर डायग्नोस्टिक सेंटर


E-7/636, पंजाब नेशनल बैंक के पास, मैन रोड, अरेरा कॉलोनी भोपाल ( म.प्र. )  
फोन: 0755-2465288, 0755-3520545 मो: 9826340190

Pt.Name :-	Mr. Varun Bhatia
Age :-	32y/M
Refd. By :-	BOB
Lab.pNo.:-	232
Date :-	09/07/2022

## URINE ANALYSIS

<u>A. PHYSICALEXAMINATION</u>		<u>C. MICROSCOPIEXAMINATION</u>	
1. Colour	Yellow	Pus Cells	2-4/HPF
2. Appearance	Clear	R.B.C.	Nil
3. Specific Gravity	Q.N.S.	Epithelial Cell	1-2/HPF
<u>B. CHEMICAL EXAMINATION</u>		Cast	Nil
1.Reaction	Acidic	Crystals(Cal.Oxa)	Nil
2.Albumin	Absent	Bacteria	Nil
3.Sugar	Nil	Amorphous	Nil
4.Bile Salts	Absent	T. Vaginatis	Nil

URINE COTININE	Negative	By Card method
----------------	----------	----------------



  
Dr. B. M. Agarwal  
MBBS, DCP  
Consultant Pathologist  
Pathologist

All test have technical limitation. Collaborative clinic pathological interpretation is mandatory. In case of disparity test may be repeated immediately. Typographic mistakes should be get correct instantly. This report is not valid for medico legal purpose



# द्विवाकर डायग्नोस्टिक सेंटर

E-7/636, पंजाब नेशनल बैंक के पास, मैन रोड, अरेरा कॉलोनी भोपाल ( म.प्र. )  
फोन: 0755-2465288, 0755-3520545 मो: 9826340190

Pt.Name :-	Mr. Varun Bhatia
Age :-	32y/M
Refd. By :-	BOB
Lab.pNo.:-	232
Date :-	09/07/2022


## EXAMINATION OF BLOOD

TEST	RESULT	NORMAL VALUE
Haemoglobin	16.3mgs%	Female 12-16gms%, Male 14-18gms%
Red Cell count	5.2	4.5-5.6 million /cumm
Platelet Count	3.28	1.5-5.6 Lac/cumm
Leucocytes per.cu.mm	8500/cumm	5000-11000/cumm
Neutrophils	62%	50-70%
Lymphocytes	32%	20-40%
Eosinophils	04%	0-7%
Monocytes	02%	2-8%
PCV	41.0	37-47
MCV	82.6	76-96
MCH	31.5	27-32
MCHC	32.8	31-35
ESR	05	Male 0-9, Female 0-20mm/FHR
Blood Group	"AB" Positive	By slide Method
S.Bilirubin(Total)	0.88	0.2-1.0mg/dl
Direct	0.32	0.0-0.25mg/dl
Indirect	0.53	5-35U/L
SGOT	31.6	8-40U/L
SGPT	35.0	3-13 KA units
Alk Phosphatase	10.9	6.0-8.0mg%
S. Protein(Total)	7.2	3.7-5.3mg%
Albumin	4.1	1.5 to 3.5 mg%
Globulin	3.3	1.-2.0
AG Ratio	1.32	7-20 mg/dl
Blood Urea Nitrogen (BUN)	15.3	0.5-1.4mg/dl
S.Creatine	1.0	4.8 to 7.5 mg/dl
Uric Acid	6.4	8.5-10.5 gm/dl
Calcium	9.7	5-35 UL/dl
GGTP	33.1	Up to 150mg/dl
Random Blood Sugar	126.8	100-250 mg%
Total Serum Cholesterol	183.5	Up to 160 mg%
Serum Triglyceride	206.8	Up to 65 mg%
Serum Cholesterol HDL	51.6	Up to 125 mg%
Serum Cholesterol LDL	90.5	Up to 30 mg%
VLDL	41.3	Bellow 5
TC/HDL Ratio	3.42	Below - 6.0 % -Non Diabetic control
Glycosylated Hemoglobin HBA1c	5.5	6-7 % -Excellent control Above- 8 % -Poor control

Pathologist

Dr. B. M. Agarwal  
MBBS, DCP  
Consultant Pathologist

All test have technical limitation. Collaborative clinic pathological interpretation is mandatory. In case of disparity test may be repeated immediately. Typographical mistakes should be get correct instantly. This report is not valid for medico legal purpose.





# दिवकर डायग्नोस्टिक सेंटर

E-7/636, पंजाब नेशनल बैंक के पास, मैन रोड, अरेरा कॉलोनी भोपाल ( म.प्र. )  
फोन: 0755-2465288, 0755-3520545 मो: 9826340190

Pt.Name :-	Mr. Varun Bhatia
Age :-	32y/M
Refd. By :-	BOB
Lab.pNo.:-	232
Date :-	09/07/2022
Skigram	X Ray Chest PA View
Radiologist	Dr. B.M.Agarwal MD (Radiology)

## REPORT

Tricia Central

Thoracic cage normal

Both Lungs Field Clear.

Both hilers normal

Cardiac border normal

Both cp angles clear

Both domes and diaphragm normal

## IMPRESSION

\*\*\*\*\*

-NO CARDIO PULMONARY PATHOLOGY  
-COORELATE WITH CLINICAL FINDINGS.

*Dr. B. M. Agarwal*  
MD, Radiology  
Consultant Radiologist  
Radiologist






# दिवाकर डायग्नोस्टिक सेंटर

E-7/636, पंजाब नेशनल बैंक के पास, मैन रोड, अरेरा कॉलोनी भोपाल ( म.प्र. )  
फोन: 0755-2465288, 0755-3520545 मो: 9826340190

Pt.Name :-	Mr. Varun Bhatia
Age :-	32y/M
Refd. By :-	BOB
Lab.pNo.:-	232
Date :-	09/07/2022

## EXAMINATION OF BLOOD

<u>TEST</u>	<u>RESULT</u>	<u>NORMAL VALUE</u>
PSA	5.11 ng/ml.	0.21-6.77 ng/ml.

  
Dr. B. M. Agarwal  
MBBS, DCP  
Pathologist  
Consultant Pathologist

All test have technical limitation. Collaborative clinic pathological interpretation is mandatory. In case of disparity test may be repeated immediately. Typographic mistakes should be get correct instantly. This report is not valid for medico legal purpose





# दिवाकर डायग्नोस्टिक सेंटर

E-7/636, पंजाब नेशनल बैंक के पास, मैन रोड, अरेरा कॉलोनी भोपाल ( म.प्र. )

फोन: 0755-2465288, 0755-3520545 मो: 9826340190

Pt.Name :-	Mr. Varun Bhatia
Age :-	32y/M
Refd. By :-	BOB
Lab.pNo.:-	232
Date :-	09/07/2022

## EXAMINATION OF BLOOD

### Thyroid profile

<u>TEST</u>	<u>RESULT</u>	<u>NORMAL VALUE</u>
T3 - TOTAL	111.6	82-213 ng/dL
T4 - TOTAL	7.38	6.09-12.23 ug/dL
THYROID STIMULATING HORMONE (TSH)	3.45	0.45-4.25 ul/mL

#### Interpretation:

TSH Levels will be elevated in primary hypothyroidism, TSH levels will be low in Hyperthyroidism there is decreased production of thyroid hormones by the thyroid hence the person may experience symptoms such as weight gain, constipation, cold intolerance and fatigue. Iodine deficiency and Hashimoto thyroiditis is the most common cause of hypothyroidism It makes Thyroid stimulating hormone. If TSH levels are abnormally high it could mean you have an underactive thyroid or hypothyroidism.

  
Dr. B. M. Agarwal  
MBBS, DCP  
Consultant Pathologist

All test have technical limitation. Collaborative clinic pathological interpretation is mandatory. In case of disparity test may be repeated immediately. Typographic mistakes should be get correct instantly. This report is not valid for medico legal purpose

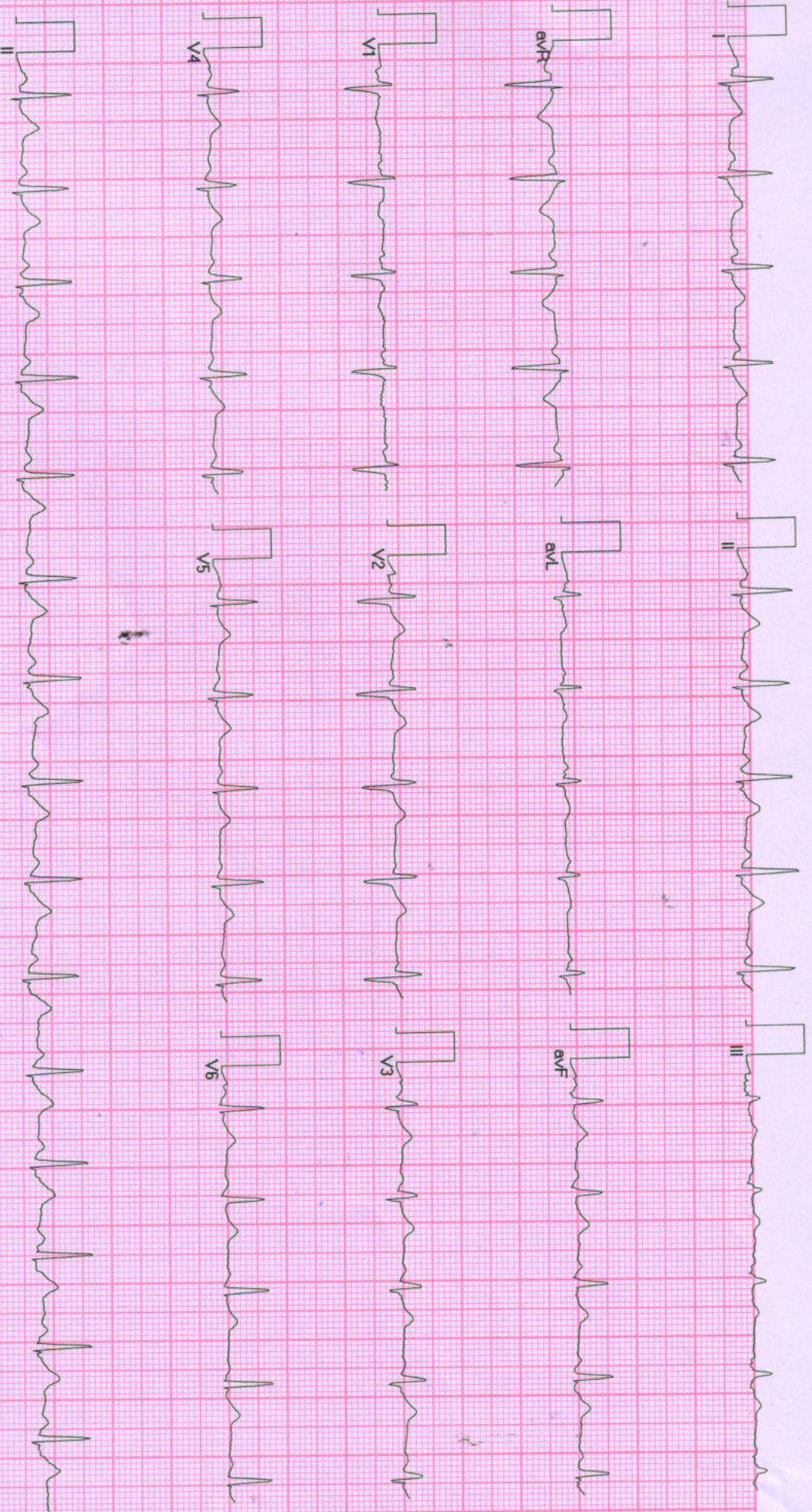


ECG



**Allengers Global Healthcare Pvt Ltd.**  
138 / MR. VARUN BHATIYA / 32 Yrs / M / 178Cms. / 99Kgs.  
Heart Rate : 90 bpm / Tested On : 09-Jul-22 13:41:41 / HF 0.05 Hz - LF 100 Hz / Notch 50 Hz / Sn 1.00 Cm/mV / Sw 25 mm/s  
/ Refd By.: BOB

BPL-DYNATrac



Allengers ECG (Pisces)(PIS213180317)





# डॉ. सविता क्लिनिक

34, भूतल, मोहिनी अदिति आर्केड, शाहपुरा मस्जिद के पास  
भरत नगर रोड, ई-7/194, अरेरा कॉलोनी, भोपाल - 462038

Mob. : 8989649694, 9516333619

Clinic Registration : CL/5392/Jun/2017

PNDT Registration : MPPCPNDT/BPL/2017/206



Name : Mrs. Varun Bhatia 32/male Age.....YRS./F

R/B Health check-up No.....Date 9.7.2022

## WHOLE ABDOMES ULTRASOUND REPORT

### Indication:

Liver appears normal in size and shape with normal outline. ~~Normal/~~ increased perenchymal echogenicity is noted. No E/O focal lesion/ IHBR dilatation is seen. Hepatic veins and portal veins appear normal. gr II  
Fatty liver

No E/O subdiaphragmatic Collection.

Gall Blader is physiologically well distended. No. E/O echogenic foci in GB lumen. GB wall is normal / ~~thickened~~. No E/O pericholecystic collection. Common duct reveals normal course and caliber.

Pancreas appear normal in size, shape and echo texture with smooth contour. No peripancreatic pathology seen. (~~Not seen due to gases~~)

Spleen is normal in size and echo texture.

IVC and aorta appear to be normal.

No evidence of lymphadenopathy is noted.

No evidence of free fluid is noted.

Right Kidney is normal in size. size, shape and position. Corticomedullary defferentiation (CMD) is well maintained. Normal cortical thickness is noted. No E/O hydronephrosis or calculus is noted.

PTO

Dr. P. Savita, MD

MBBS, MD (O&G) Reg. No. 9971

स्त्री रोग विशेषज्ञ

Dr. Jayant Yadav, MD

MBBS, MD (Radiologist) Reg. No. 4166



Left Kidney is normal in size, shape and position. CMD is well maintained. Normal cortical thickness is noted. No E/O hydronephrosis or calculus is noted.

Urinary Bladder is well distended (physiological). its contents are echo free. No E/O bladder wall thickening is noted. ~~Post void residue is insignificant.~~

Prostate is normal in size. Shape and echo texture with smooth outline. No E/O focal lesion is noted.


Uterus is ante/retroverted and normal in size, shape and echotexture with smooth outline. No E/O focal lesion is noted. Endometrial echo appear normal. Cervical and vaginal shadows appear normal.

Right Ovary appears enlarged / Normal in size, shape and echo texture.

Left Ovary appears enlarged / Normal in size, shape and echo texture.

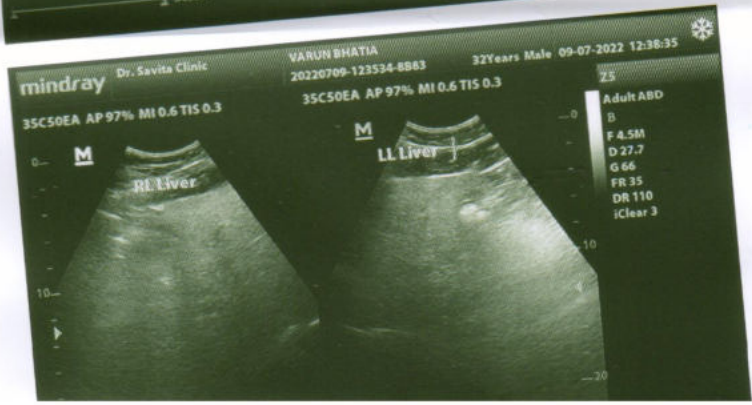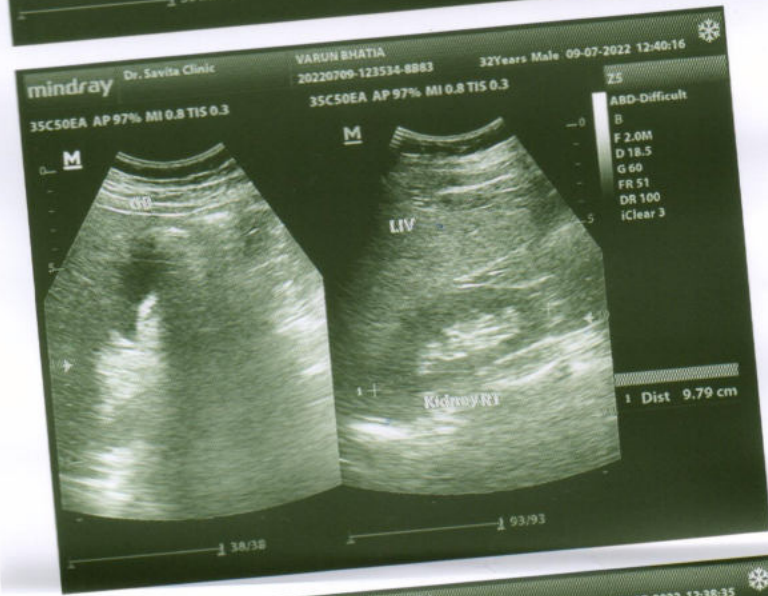
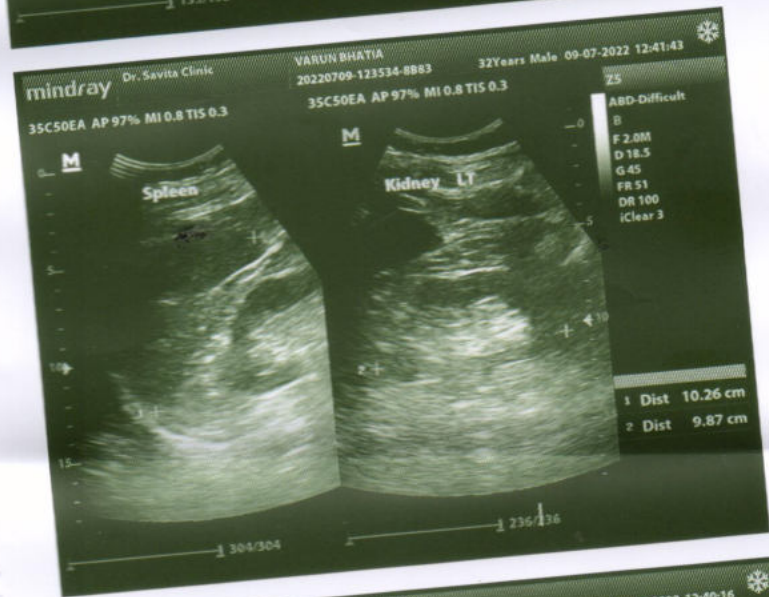
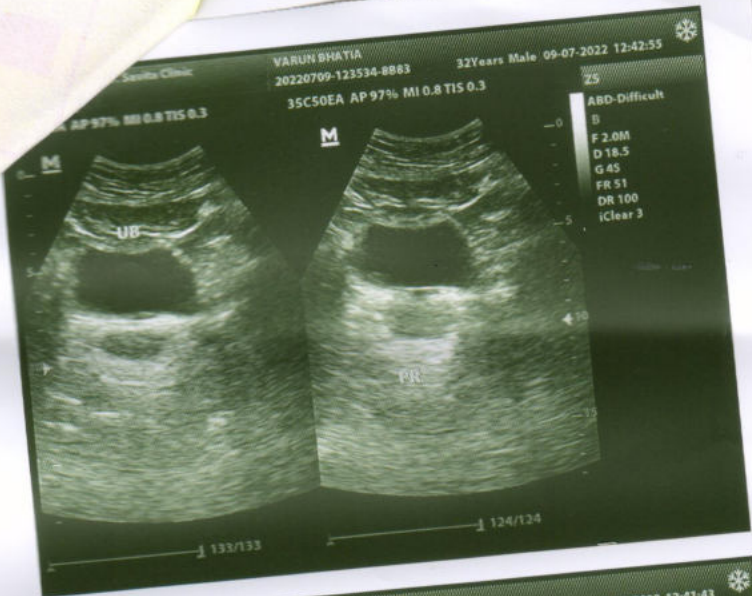
Impression : ~~Normal study~~ *gs II fatty liver.*

Advised clinical Correlation.



Dr. P. Savita, MD  
MBBS, MD (O&G) Reg. No. 9971  
स्त्री रोग विशेषज्ञ

Dr. Jayant Yadav, MD  
MBBS, MD (Radiologist) Reg. No. 4166  
रेडियोलॉजिस्ट



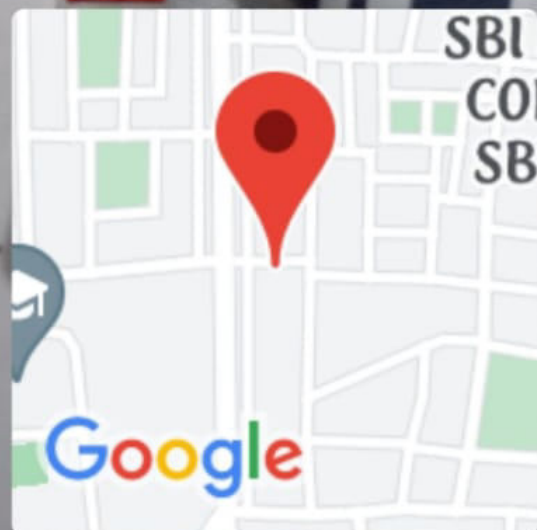


# Diagnostic Diagnostic Centre

पेथो | एक्स-रे | ई.सी.जी. | एको कार्डियो ग्राफी | सोनोग्राफी



GPS Map Camera



## Bhopal, Madhya Pradesh, India

Dr.Vikas Kumar Malviya E-7 Arera Colony, Near Campion School Bus Stop  
Infront Of Punjab National Bank Shahpura Branch, E-7, Arera Colony,  
Bhopal, Madhya Pradesh 462016, India

Lat 23.205891°

Long 77.431705°

09/07/22 01:16 PM

**Diwakar Diagnostic Centre**  
E-7/636, Arera Colony, Bhopal

657 / MR. VARUN BHATIA / 32 Yrs / M / 178 Cms / 99 Kg Date: 09-Jul-2022 Refd By : BOB

**Report :**

TEST OBJECTIVE	: ROUTINE CHECK UP
RISK FACTOR	: MALE
ACTIVITY	: MODERATE ACTIVE
OTHER INVESTIGATION	: ROUTINE BLOOD INVESTIGATION, USG, X RAY
REASON FOR TERMINATION	: FATIGUE
EXERCISE TOLERANCE	: AVERAGE
EXERCISE INDUCED ARRHYTHMIAS	: NO
HAEMODYNAMIC RESPONSE	: NORMAL
CHRONOTROPIC RESPONSE	: NORMAL
FINAL IMPRESSION	: STRESS TEST IS NEGATIVE FOR EXERCISE INDUCED ISCHAEMIC HEART DISEASE



Doctor : Cardiologist

657 / MR. VARUN BHATIA / 32 Yrs / M / 178 Cms / 99 Kg Date: 09-Jul-2022 Refd By : BOB

Stage	Time	Duration	Belt Speed (mph)	Elevation	METS	Rate	% THR Achieved	BP	RPP	PVC	Comments
Supine	00:16	0:01	00.0	00.0	01.0	100	53 %	130/80	130	00	
Standing	00:22	0:01	00.0	00.0	01.0	103	55 %	130/80	133	00	
HV	00:33	0:01	00.0	00.0	01.0	115	61 %	130/80	149	00	
Warm Up	00:36	0:03	01.7	10.0	01.1	115	61 %	130/80	149	00	
ExStart	00:39	0:06	01.7	10.0	01.1	115	61 %	130/80	149	00	
BRUCE Stage 1	03:39	3:00	01.7	10.0	04.7	136	72 %	130/80	176	00	
BRUCE Stage 2	06:39	3:00	02.5	12.0	07.1	153	81 %	140/90	214	00	
PeakEx	08:20	1:41	03.4	14.0	08.9	166	88 %	150/90	249	00	
Recovery	09:19	1:00	00.0	00.0	01.2	132	70 %	146/86	192	00	
Recovery	10:19	2:00	00.0	00.0	01.0	119	63 %	136/80	161	00	
Recovery	10:25	2:05	00.0	00.0	01.0	119	63 %	136/80	161	00	

**Findings :**

- Exercise Time : 07:42
- Max HR Attained : 166 bpm 88% of Target 188
- Max BP Attained : (Sys) 150/90
- Max Workload Attained : 8.9 Fair response to induced stress
- Test End Reasons : Fatigue

Doctor : Cardiologist



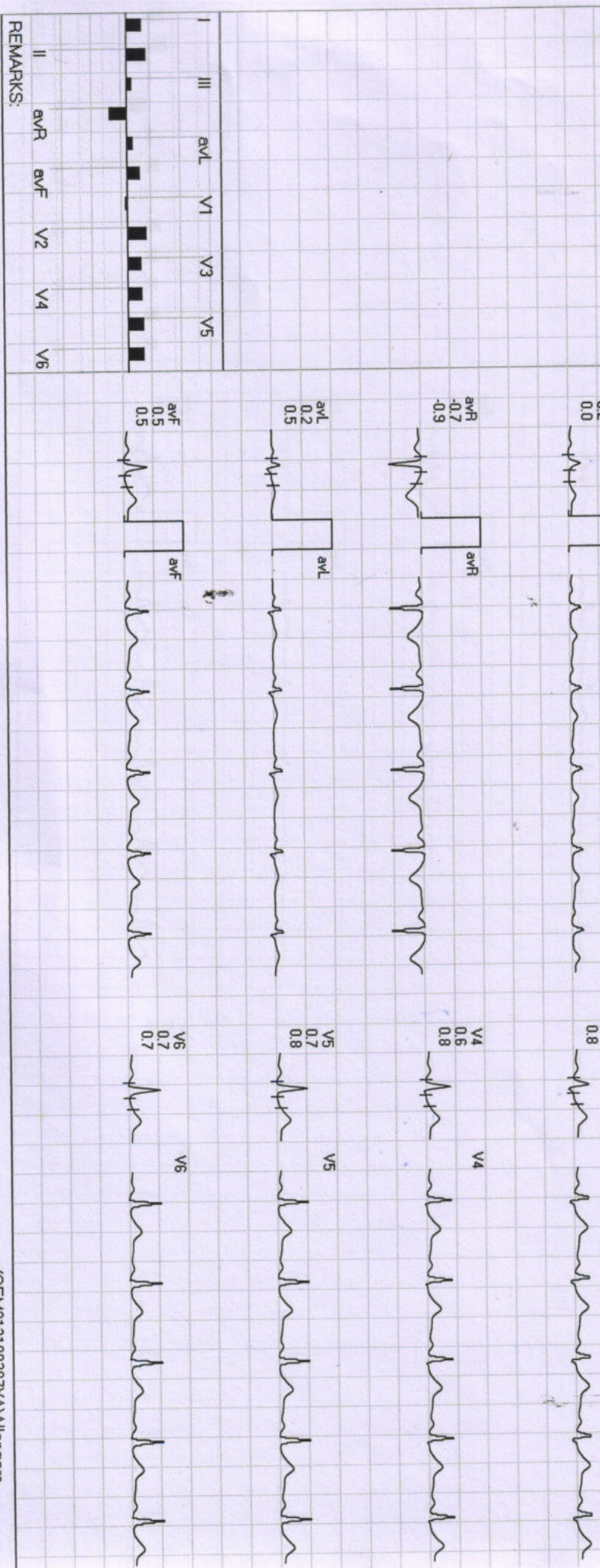
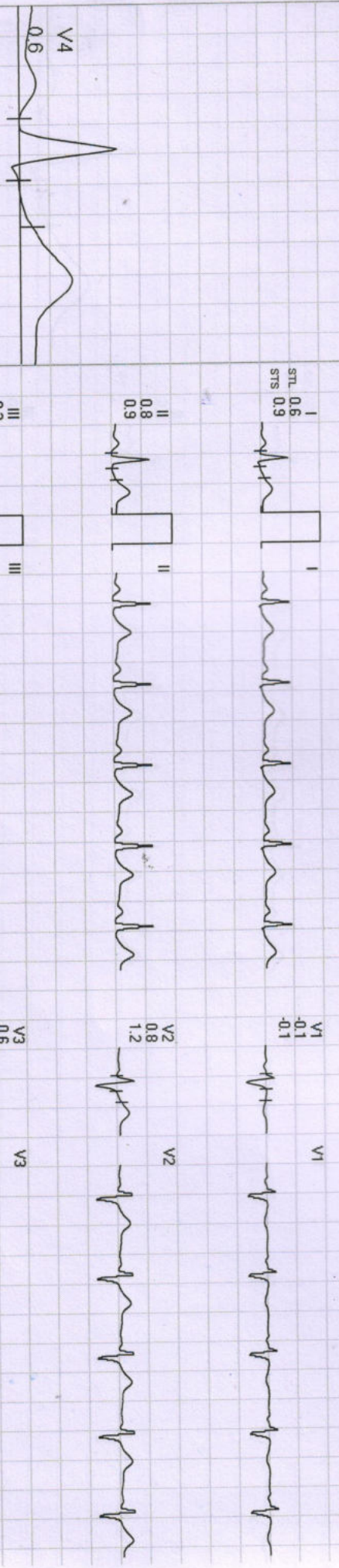
657/MR. VARUN BHATIA /32 Yrs /M /178 Cms /99 Kg /HR : 100

Date: 09-Jul-2022 01:42:29 PM METS: 1.0/100 bpm 53% of THR BP: 130/80 mmHg Raw ECG/BLC On/Naich On/HF 0.05 Hz/LF 20 Hz

ExTime: 00:15 0.0 mph, 0.0%

4X 80 mS Post J

25 mm/Sec. 1.0 Cm/mV



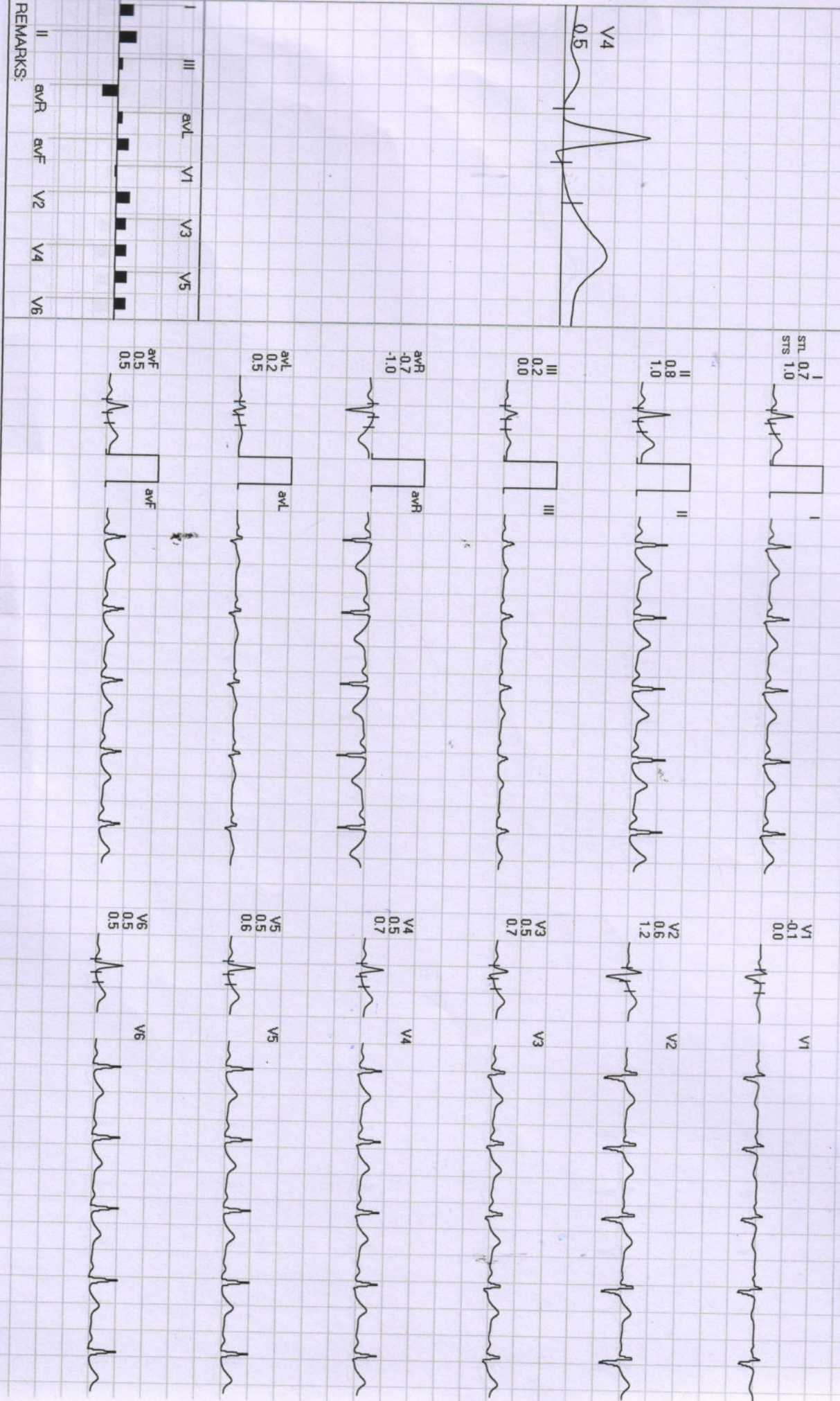
Date: 09-Jul-2022 01:42:29 PM METS: 1.0/ 103 bpm 54% of THR BP: 130/80 mmHg Raw ECG/ BLC On/ Notch On/ HF 0.05 Hz/ LF 20 Hz

ExTime: 00:21 0.0 mph, 0.0%

25 mm/Sec. 1.0 Cm/mV

4X

80 mS Post J



REMARKS:

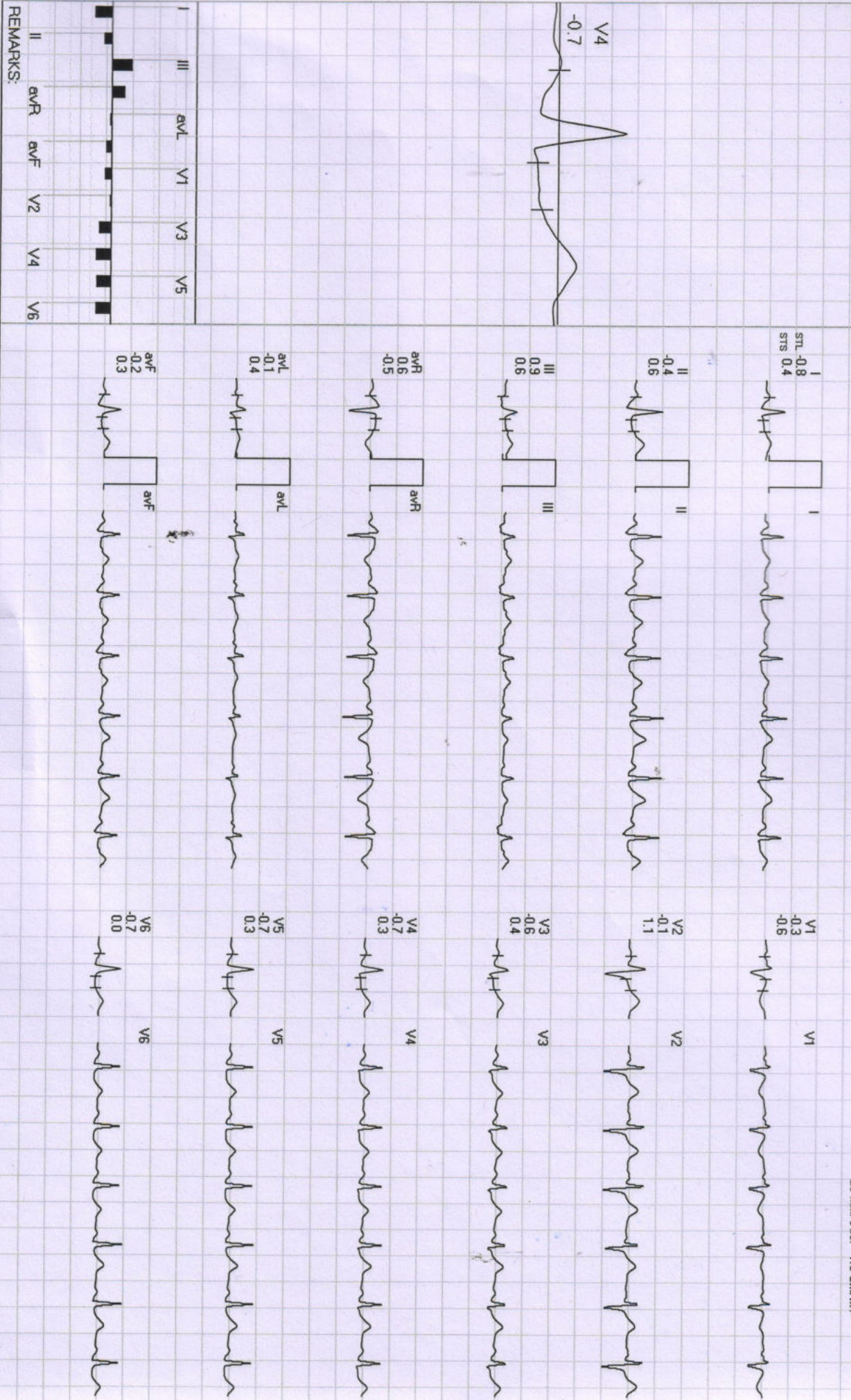

Date: 09-Jul-2022 01:42:29 PM

METS: 1.0/115 bpm 61% of THR BP: 130/80 mmHg Raw ECG/BLC On/ Notch On/ HF 0.05 Hz/LF 20 Hz

EXTime: 00:32 0.0 mph, 0.0%

4X 80 mS Post J

25 mm/Sec 1.0 Cm/mV



REMARKS:



657/MR. VARUN BHATTA /32 Yrs/M/178 Cms/99 Kg/HR: 115

Date: 09-Jul-2022 01:42:29 PM METS: 1.0/115 bpm 61% of THR BP: 130/80 mmHg Row ECG/BLC On/ Notch On/ HF 0.05 Hz/LF 20 Hz


EXTime: 00:35 1.0 mph, 0.0%

4X 90 MS Post J

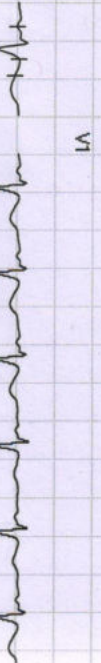25 mm/Sec. 1.0 Cm/mV




I  
STL -0.8  
STS 0.4



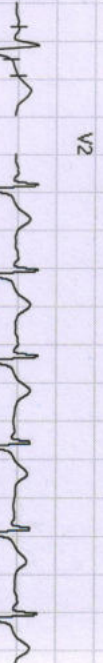V1  
-0.3  
-0.6



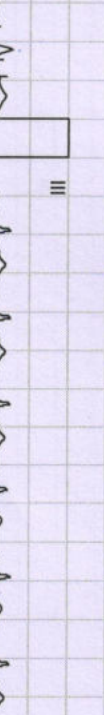II  
-0.4  
0.6



V2  
-0.1  
1.1




III  
0.9  
0.6



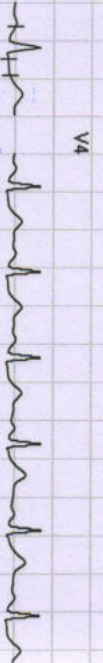
V3  
-0.6  
0.4




avR  
0.6  
-0.5



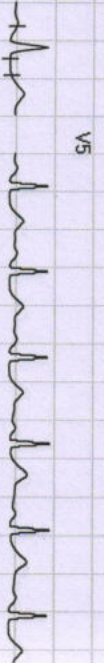
V4  
-0.7  
0.3




avL  
-0.1  
0.4




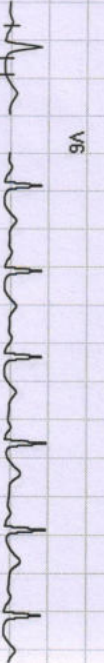
V5  
-0.7  
0.3



avF  
-0.2  
0.3



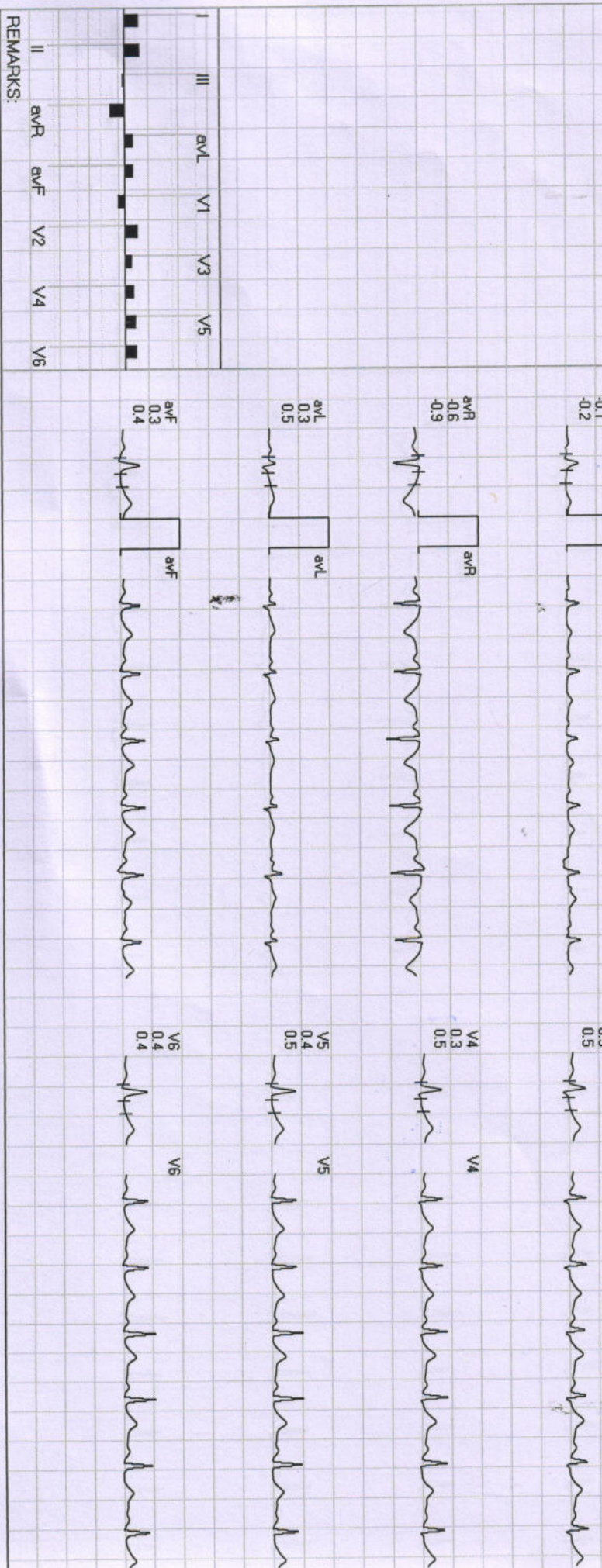
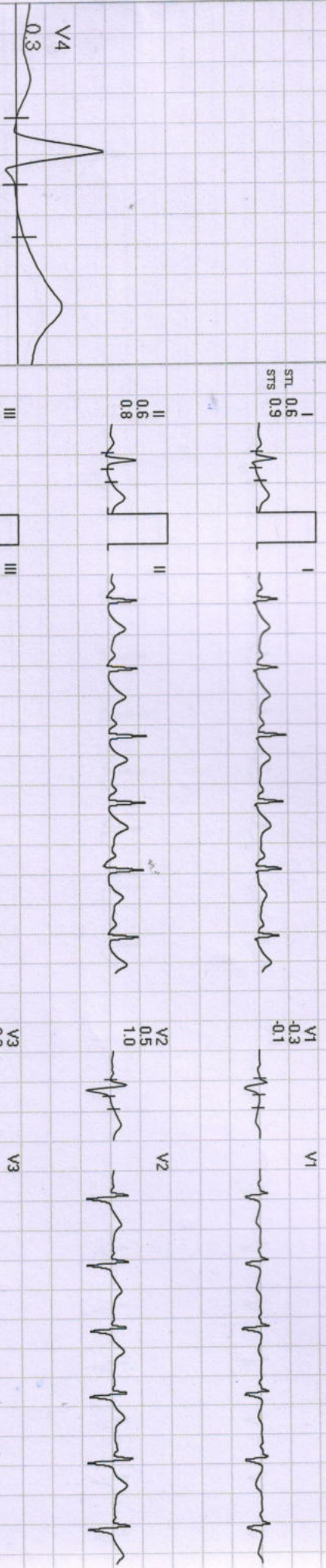
V6  
-0.7  
0.0



REMARKS:

4X 80 mS Post J

25 mm/Sec. 1.0 Cm/mV



REMARKS:



657 / MR. VARUN BHATIA / 32 Yrs / M / 178 Cms / 99 Kg / HR : 136

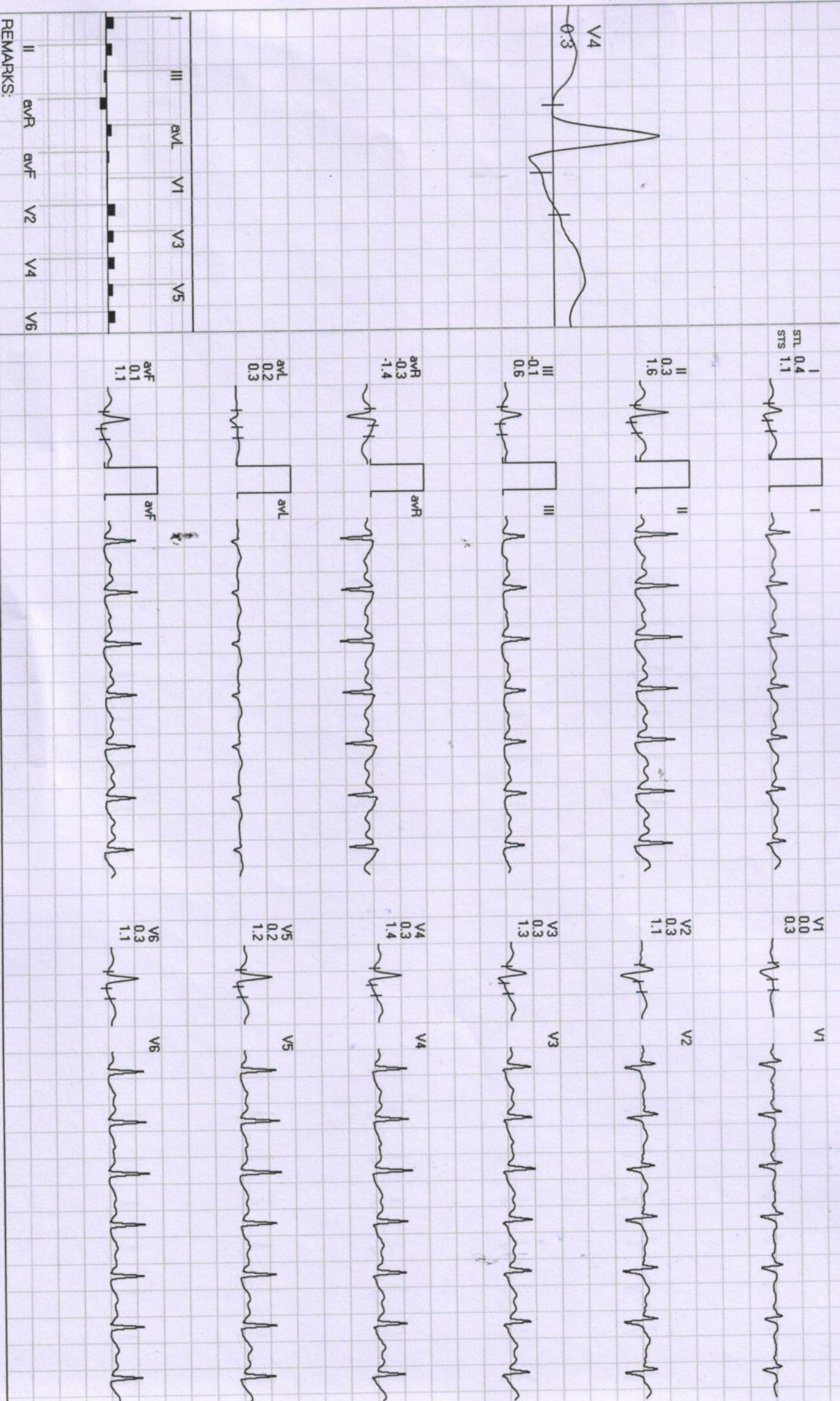
Date: 09-Jul-2022 01:42:29 PM

METS: 4.7 / 136 bpm 72% of THR BP: 130/80 mmHg Raw ECG/ BLC On/ Notch On/ HF 0.05 Hz/LF 20 Hz

EXTime: 03:00 1.7 mph, 10.0%

25 mm/Sec. 1.0 Cm/mV

4X 60 ms Post J



REMARKS:

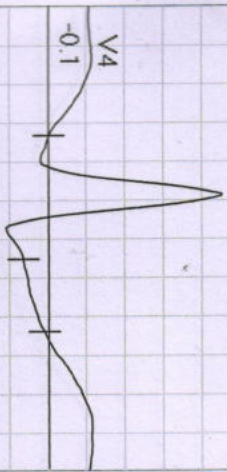


Date: 09-Jul-2022 01:42:29 PM METS: 7.1/153 bpm 81% of THR BP: 140/90 mmHg Raw ECG/BLCOn/Notch On/HF 0.05 Hz/LE 20 Hz

EXTime: 06:00 2.5 mph, 12.0%

4X 60 mS Post J

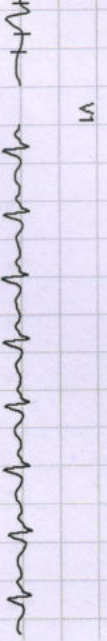
25 mm/Sec. 1.0 Cm/mV




I  
STL 0.6  
STS 1.2




V1  
-0.3  
-0.8



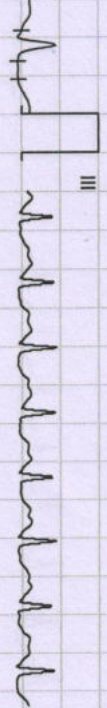
II  
0.2  
1.3




V2  
0.9  
1.9



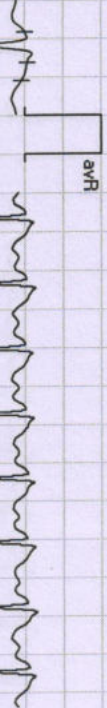
III  
-0.4  
0.1



V3  
-0.2  
1.1



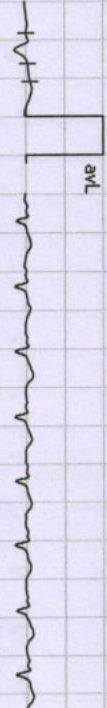avR  
-0.4  
-1.3



V4  
-0.1  
1.2



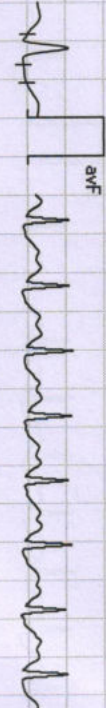avL  
0.5  
0.5



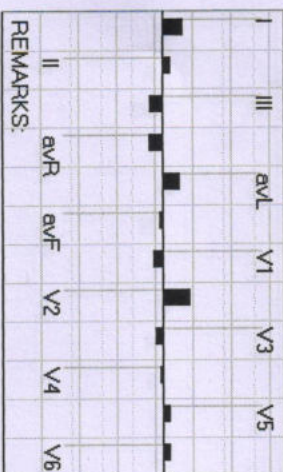
V5  
0.2  
1.4



avF  
-0.1  
0.7



V6  
0.2  
1.2



REMARKS:

657/MR. VARUN BHATIA /32 Yrs/M/178 Cms/99 Kg/HR: 166





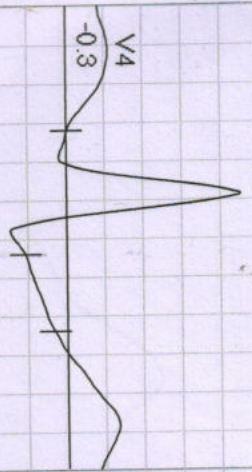
Date: 09-Jul-2022 01:42:29 PM

METS: 8.9/166 bpm 88% of THR BP: 150/90 mmHg Raw ECG/ BLC On/ Notch On/ HF 0.05 Hz/LF 20 Hz

EXTime: 07:41 3.4 mph, 14.0%

4X 60 mS Post J

25 mm/Sec. 1.0 Cm/mV



I	III	aVL	V1	V3	V5
II	aVR	aVF	V2	V4	V6

REMARKS:



657/MR. VARUN BHATTIA /32 Yrs/M/178 Cms/99 Kg/HR : 132

Date: 09-Jul-2022 01:42:29 PM

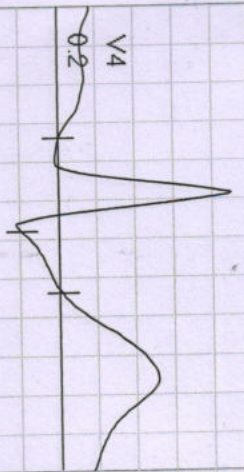



METS: 1.1/132 bpm 70% of THR BP: 146/86 mmHg

Raw ECG/ BLC On/ Notch On/ HF 0.05 Hz/LF 20 Hz

EXTime: 07:41 0.0 mph, 0.0%

25 mm/Sec. 1.0 Cm/mV

4X 60 ms Post J



I	III	aVL	V1	V3	V5
II	aVR	aVF	V2	V4	V6

REMARKS:

657/MR. VARUN BHATIA /32 Yrs/M/178 Cms/99 Kg/HR: 119

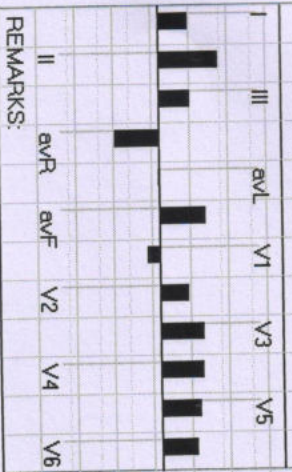





Date: 09-Jul-2022 01:42:29 PM

METS: 1.0/ 119 bpm 63% of THR

BP: 136/80 mmHg Raw ECG/ BLC On/ Notch On/ HF 0.05 Hz/ LF 20 Hz

EXTime: 07:41 0.0 mph, 0.0%  
25 mm/Sec. 1.0 Cm/mV

4X 80 ms Post J



REMARKS: