



**Bank of Baroda** *r. B. M. Ag*  
**Bank of Baroda** **MBI**  
**Consultant Pathologist**


नाम **सुश्री अर्पणा शर्मा**  
Name **Miss Arpana Sharma**

कर्मचारी कूट क्र. **159097**

E.C. No. : *Arpana Sharma*  
*30-12-2021*

जारीकर्ता प्राधिकारी  
Issuing Authority

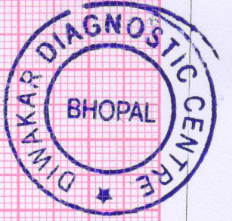
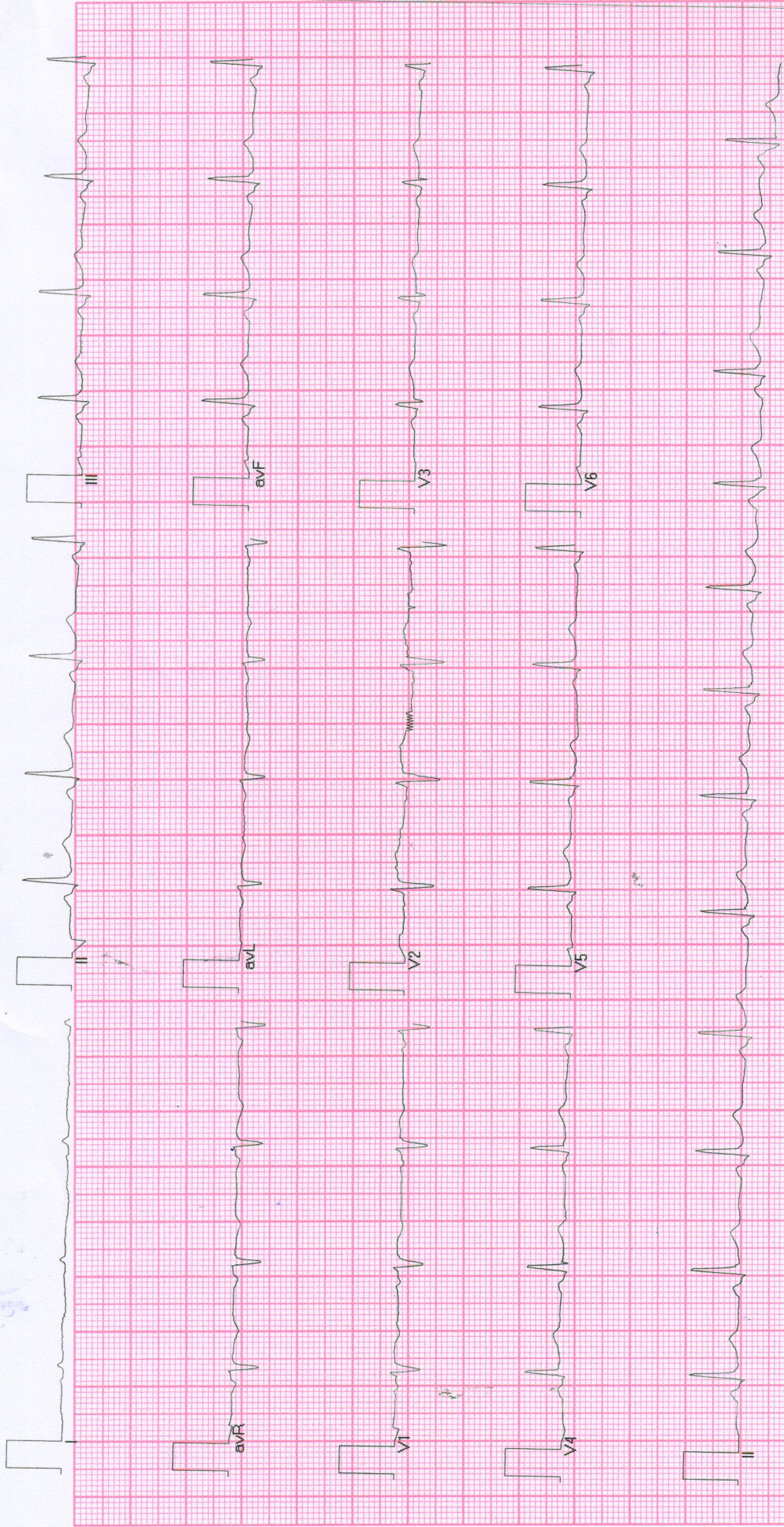
धारक के हस्ताक्षर  
Signature of Holder



*r. B. M. Ag*  
*MBI*  
*Consultant Pathologist*

Allengers Global Healthcare Pvt Ltd.,  
15 / Miss Arpana Sharma / 47 Yrs / M / 160Cms / 70Kgs.  
Heart Rate : 75 bpm / Tested On : 30-Dec-21 10:21:01 / HF 0.05 Hz - LF 100 Hz / Notch 50 Hz / Sn 1.00 Cm/mV / Sw 25 mm/s

# ECG



Allengers ECG (Pisces)(PI213180317)

*Deepa Sharma*  
30-12-2021



# द्विवाकर डायग्नोस्टिक सेंटर

E-7/636, पंजाब नेशनल बैंक के पास, मैन रोड, अरेरा कॉलोनी भोपाल ( म.प्र. )

फोन: 0755-2465288, 0755-3520545 मो: 9826340190

Pt.Name :-	Miss. Arpana Sharma
Age :-	47y/F
Refd. By :-	BOB
Lab.pNo.:-	271
Date :-	30/12/2021

## EXAMINATION OF BLOOD

TEST	RESULT	NORMAL VALUE
Haemoglobin	13.2mgs%	Female 12-16gms%, Male 14-18gms%
Red Cell count	4.9	4.5-5.6 million /cumm
Platelet Count	2.06	1.5-5.6 Lac/cumm
Leucocytes per.cu.mm	7900/cumm	5000-11000/cumm
Neutrophils	57%	50-70%
Lymphocytes	33%	20-40%
Eosinophils	06%	0-7%
Monocytes	04%	2-8%
PCV	38.9	37-47
MCV	78.6	76-96
MCH	30.2	27-32
MCHC	32.6	31-35
ESR	11	Male 0-9, Female 0-20mm/FHR
Blood Group	"B" Positive	By Slide Method
S.Bilirubin(Total)	0.82	0.2-1.0mg/dl
Direct	0.30	0.0-0.25mg/dl
Indirect	0.52	
SGOT	28.6	5-35U/L
SGPT	32.0	8-40U/L
Alk Phosphatase	8.5	3-13 KA units
S. Protein(Total)	7.0	6.0-8.0mg%
Albumin	4.0	3.7-5.3mg%
Globulin	3.0	1.5 to 3.5 mg%
AG Ratio	1.23	1-2.0
Blood Urea Nitrogen (BUN)	12.0	7-20 mg/dl
S.Creatine	1.1	0.5-1.4mg/dl
S. Uric Acid	4.9	3.5-7.5mg%
Calcium	8.8	8.5-10.5 gm/dl
GGTP	32.0	5-35 UL/dl
HbsAg	Negative	By card method
HIV I&II	Negative	By elisa method
Fasting Blood Sugar	89.3	70 to 110mg/dl
Post Prandial Blood Sugar	132.8	Up to 140mg/dl
Total Serum Cholesterol	163.1	100-250 mg%
Serum Triglyceride	128.5	Up to 160 mg%
Serum Cholesterol HDL	46.0	Up to 65 mg%
Serum Cholesterol LDL	91.4	Up to 125 mg%
VLDL	25.7	Up to 30 mg%
TC/HDL Ratio	3.50	Bellow 5
Glycosylated Hemoglobin HBA1c	5.7	Below - 6.0 % -Non Diabetic control 6-7 % -Excellent control Above- 8 % -Poor control



Dr. B. M. Agarwal  
MBBS, DCP  
Consultant Pathologist

All test have technical limitation. Collaborative clinic pathological interpretation is mandatory. In case of disparity test may be repeated immediately. Technical mistakes should be reported instantly. This report is valid for 30 days.



# दिवाकर डायग्नोस्टिक सेंटर


E-7/636, पंजाब नेशनल बैंक के पास, मैन रोड, अरेरा कॉलोनी भोपाल ( म.प्र. )  
फोन: 0755-2465288, 0755-3520545 मो: 9826340190

Pt.Name :-	Miss. Arpana Sharma
Age :-	47y/F
Refd. By :-	BOB
Lab.pNo.:-	271
Date :-	30/12/2021

## URINE ANALYSIS

<u>A. PHYSICALEXAMINATION</u>		<u>C. MICROSCOPIEXAMINATION</u>	
1. Colour	Yellow	Pus Cells	3-4/HPF
2. Appearance	Clear	R.B.C.	Nil
3. Specific Gravity	Q.N.S.	Epithelial Cell	occ/HPF
<u>B. CHEMICAL EXAMINATION</u>		Cast	Nil
1.Reaction	Acidic	Crystals(Cal.Oxa)	Nil
2.Albumin	Absent	Bacteria	Nil
3.Sugar	Nil	Amorphous	Nil
4.Bile Salts	Absent	T. Vaginitis	Nil

URINE COTININE	Negative	By Card method
----------------	----------	----------------



Dr. B. M. Agarwal  
MBBS, DCP  
Consultant Pathologist

All test have technical limitation. Collaborative clinic pathological interpretation is mandatory. In case of disparity test may be repeated immediately. Typographical mistakes should be get correct instantly. This report is not valid for medico legal purpose



# दिवकर डायग्नोस्टिक सेंटर

E-7/636, पंजाब नेशनल बैंक के पास, मैन रोड, अरेरा कॉलोनी भोपाल ( म.प्र. )

फोन: 0755-2465288, 0755-3520545 मो: 9826340190

Pt.Name :-	Miss. Arpana Sharma
Age :-	47y/F
Refd. By :-	BOB
Lab.pNo.:-	271
Date :-	30/12/2021
Skigram	X Ray Chest PA View
Radiologist	Dr. B.M.Agarwal MD (Radiology)

## REPORT

Tricia Central

Thoracic cage normal

Both Lungs Field Clear.

Both hilers normal

Cardiac border normal

Both cp angles clear

Both domes and diaphragm normal

## IMPRESSION

\*\*\*\*\*

-NO CARDIO PULMONARY PATHOLOGY

-COORELATE WITH CLINICAL FINDINGS.



*B.M.Agarwal*  
Dr. B. M. Agarwal  
MD, Radiology  
Consultant Radiologist  
Radiologist



# द्विवाकर डायग्नोस्टिक सेंटर

E-7/636, पंजाब नेशनल बैंक के पास, मैन रोड, अरेरा कॉलोनी भोपाल ( म.प्र. )

फोन: 0755-2465288, 0755-3520545 मो: 9826340190

Pt.Name :-	Miss. Arpana Sharma
Age :-	47y/F
Refd. By :-	BOB
Lab.pNo.:-	271
Date :-	30/12/2021

## EXAMINATION OF BLOOD

### Thyroid profile

<u>TEST</u>	<u>RESULT</u>	<u>NORMAL VALUE</u>
T3 - TOTAL	103.5	82-213 ng/dL
T4 - TOTAL	7.12	6.09-12.23 ug/dL
THYROID STIMULATING HORMONE (TSH)	2.09	0.45-4.25 ul/mL

#### Interpretation:

TSH Levels will be elevated in primary hypothyroidism, TSH levels will be low in Hyperthyroidism there is decreased production of thyroid hormones by the thyroid hence the person may experience symptoms such as weight gain, constipation, cold intolerance and fatigue. Iodine deficiency and Hashimoto thyroiditis is the most common cause of hypothyroidism It makes Thyroid stimulating hormone. If TSH levels are abnormally high it could mean you have an underactive thyroid or hypothyroidism.



*Dr. B. M. Agarwal*  
MBBS, DCP  
Consultant Pathologist

All test have technical limitation. Collaborative clinic pathological interpretation is mandatory. In case of disparity test may be repeated immediately. Typographic mistakes should be get correct instantly. This report is not valid for medico legal purpose



# डॉ. सविता क्लिनिक

34, भूतल, मोहिनी अदिति आर्केड, शाहपुरा मस्जिद के पास  
भरत नगर रोड, ई-7/194, अरेरा कॉलोनी, भोपाल - 462038

Mob. : 8989649694, 9516333619

Clinic Registration : CL/5392/Jun/2017

PNDT Registration : MPPCPNDT/BPL/2017/206



Name : Mrs. Arpana Sharma Age 47 YRS./F  
R/B Diwakar Lab. No. \_\_\_\_\_ Date 30/12/2021

## WHOLE ABDOMES ULTRASOUND REPORT

Indication: Health check-up.

Liver appears normal in size and shape with normal outline. Normal/  
increased perenchymal echogenicity is noted. No E/O focal lesion/ IHBR  
dilatation is seen. Hepatic veins and portal veins appear normal.

No E/O subdiaphragmatic Collection.

Gall Bladder is physiologically well distended. No. E/O echogenic foci in GB  
lumen. GB wall is normal / thickened. No E/O pericholecystic collection.  
Common duct reveals normal course and caliber.

Pancreas appear normal in size, shape and echo texture with smooth  
contour. No peripancreatic pathology seen. (Not seen due to gases)

Spleen is normal in size and echo texture.

IVC and aorta appear to be normal.

No evidence of lymphadenopathy is noted.

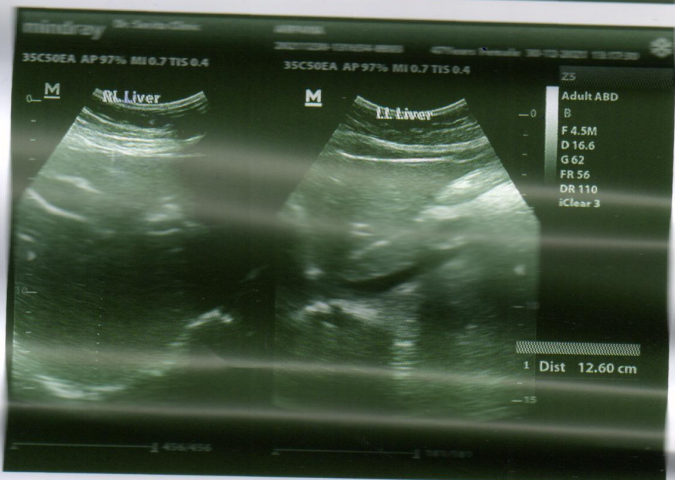
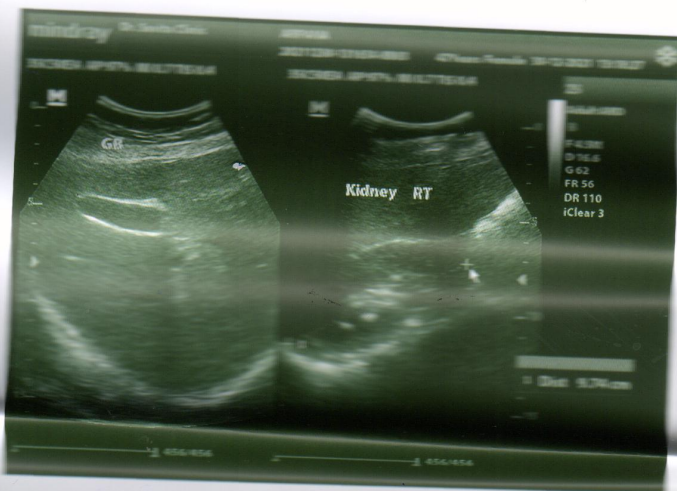
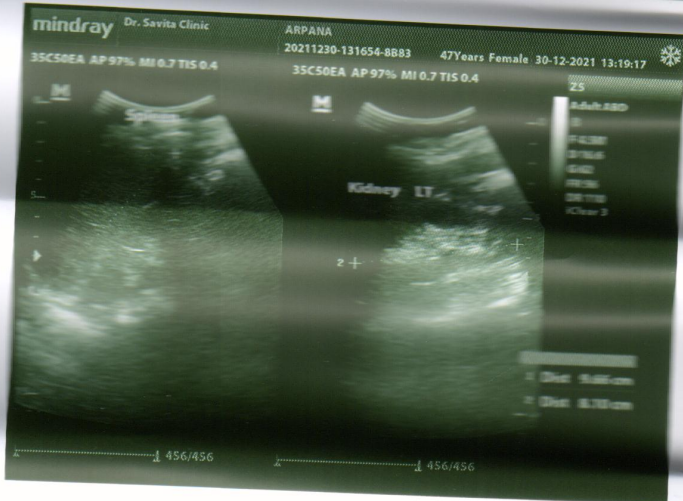
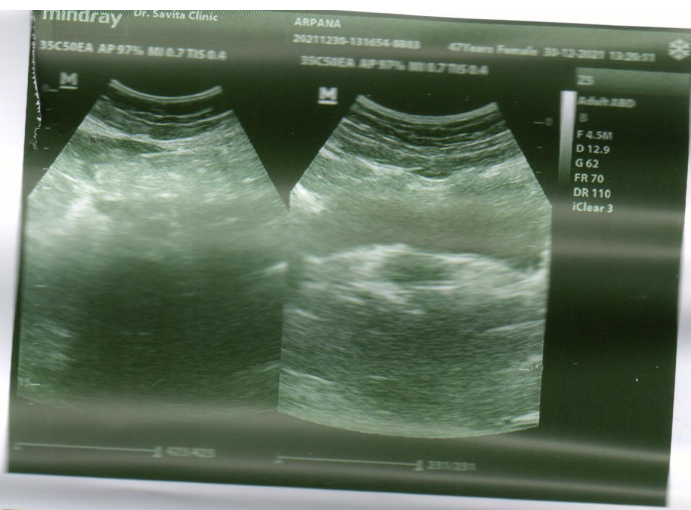
No evidence of free fluid is noted.

Right Kidney is normal in size, size, shape and position. Corticomedullary  
differentiation (CMD) is well maintained. Normal cortical thickness is  
noted. No E/O hydronephrosis or calculus is noted.

PTO

Dr. P. Savita, MD  
MBBS, MD (O&G) Reg. No. 9971  
स्त्री रोग विशेषज्ञ

Dr. Jayant Yadav, MD  
MBBS, MD (Radiologist) Reg. No. 4166  
रेडियोलॉजिस्ट





**Left Kidney** is normal in size, shape and position. CMD is well maintained. Normal cortical thickness is noted. No E/O hydronephrosis or calculus is noted.

**Urinary Bladder** is well distended (physiological). its contents are echo free. No E/O bladder wall thickening is noted. ~~Post void residue is insignificant.~~

**Prostate** is normal in size. Shape and echo texture with smooth outline. No E/O focal lesion is noted.

**Uterus** is ante/ retro verted and normal in size, shape and echotexture with smooth outline. No E/O focal lesion is noted. Endometrial echo appear normal. Cervical and vaginal shadows appear normal.

**Right Ovary** appears enlarged / Normal in size, shape and echo texture.

**Left Ovary** appears enlarged / Normal in size, shape and echo texture.

**Impression : Normal study.**

**Advised clinical Correlation.**

**Dr. P. Savita, MD**  
MBBS, MD (O&G) Reg. No. 9971  
स्त्री रोग विशेषज्ञ



**Dr. Jayant Yadav, MD**  
MBBS, MD (Radiologist) Reg. No. 4166  
रेडियोलॉजिस्ट

**Diwakar Diagnostic Centre**  
E-7/636, Near Punjab National Bank Bhopal(M.P.)

60 / MRS. ARPANA SHARMA / 47 Yrs / F / 160 Cms / 70 Kg Date: 30-Dec-2021

**Report**

(GEM213180307)(R)Allengers



**Report :**

TEST OBJECTIVE : ROUTINE CHECK UP  
RISK FACTOR : AGE  
ACTIVITY : MODERATE ACTIVE  
OTHER INVESTIGATION : ROUTINE BLOOD INVESTIGATION, X RAY, USG  
REASON FOR TERMINATION : FATIGUE, HEART RATE ACHIEVED  
EXERCISE TOLERANCE : AVERAGE  
EXERCISE INDUCED ARRHYTHMIAS : NO  
HAEMODYNAMIC RESPONSE : NORMAL  
CHRONOTROPIC RESPONSE : NORMAL  
FINAL IMPRESSION : STRESS TEST IS NEGATIVE FOR EXERCISE INDUCED ISCHAEMIC HEART DISEASE

*Arpana Sharma*  
T.T.C.  
30-12-2021



Doctor : CARDIOLOGIST



60 / MRS. ARPANA SHARMA / 47 Yrs / F / 160 Cms / 70 Kg Date: 30-Dec-2021

Stage	Time	Duration	Belt Speed (mph)	Elevation	METS	Rate	% THR Achieved	BP	RPP	PVC	Comments
Supine	00:12	0:01	00.0	00.0	01.0	68	39 %	---/---	000	00	
Standing	00:20	0:01	00.0	00.0	01.0	66	38 %	---/---	000	00	
HV	00:26	0:01	00.0	00.0	01.0	66	38 %	---/---	000	00	
Warm Up	01:03	0:01	01.0	00.0	01.0	91	53 %	---/---	000	00	
ExStart	01:13	0:06	01.7	10.0	01.1	93	54 %	---/---	000	00	
BRUCE Stage 1	04:13	3:00	01.7	10.0	04.7	147	85 %	130/80	191	00	
PeakEx	05:10	0:57	02.5	12.0	05.5	155	90 %	130/80	201	00	
Recovery	06:09	1:00	01.1	00.0	01.0	135	78 %	130/80	175	00	
Recovery	07:09	2:00	00.0	00.0	01.0	87	50 %	130/80	113	00	
Recovery	07:45	2:35	00.0	00.0	01.0	79	46 %	120/80	094	00	

**Findings :**

Exercise Time : 03:58  
 Max HR Attained : 155 bpm 90% of Target 173  
 Max BP Attained : (Sys) 130/80  
 Max Workload Attained : 5.5 Fair response to induced stress  
 Max ST Dep Lead & Value Max ST Dep Lead & Value  
 Test End Reasons : Fatigue, Heart Rate Achieved

Doctor : CARDIOLOGIST

MRS. ARPANA SHARMA / 47 Yrs / F / 160 Cms / 70 Kg / HR : 68

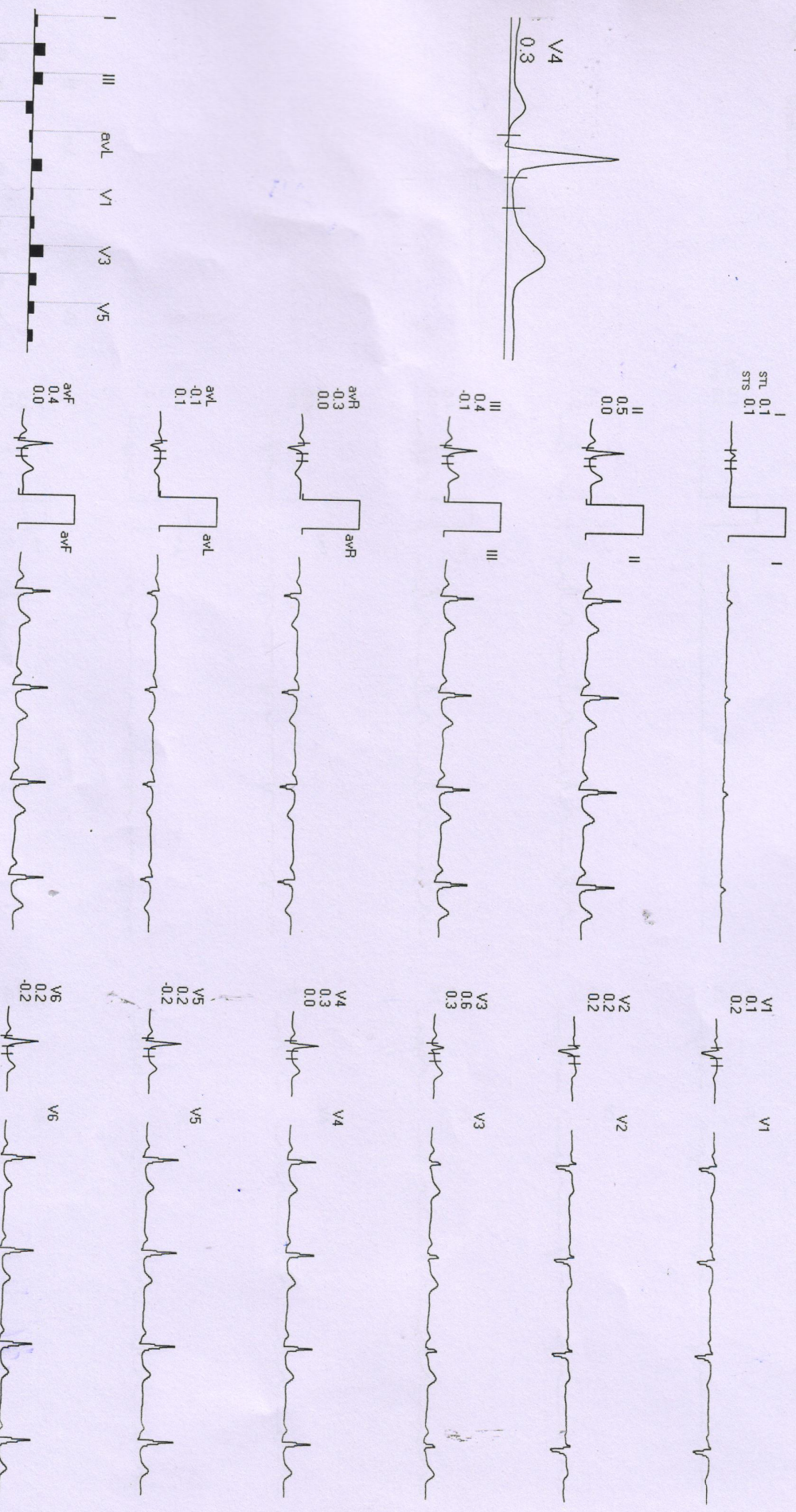
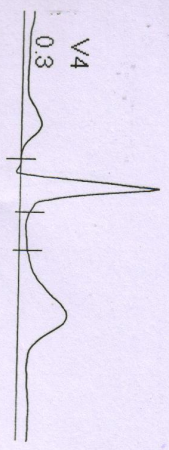
SUPINE



Date: 30-Dec-2021 10:22:18 AM METS: 1.0/68 bpm 33% of THR BP: 120/80 mmHg Raw ECG/ BLC On/ Notch On/ HF 0.05 Hz/LF 20 Hz

ExTime: 00:11 0.0 mph, 0.0%  
25 mm/Sec. 1.0 Cm/mV

4X 80 ms Post J



REMARKS:

01/MRS. ARPANA SHARMA / 47 Yrs / F / 160 Cms / 70 Kg / HR : 66

STANDING

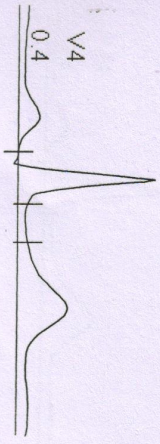


Date: 30-Dec-2021 10:22:18 AM


METS: 1.0/ 66 bpm 38% of THR BP: 120/80 mmHg Raw ECG/ BLC On/ Notch On/ HF 0.05 Hz/ LF 20 Hz

EXTime: 00:19 0.0 mph, 0.0%  
25 mm/Sec 1.0 Cm/mV

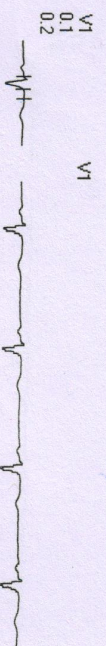4X 80 ms Post J



I  
STL 0.1  
STS 0.0



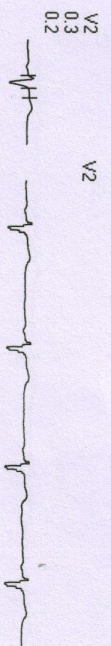V1  
0.1  
0.2



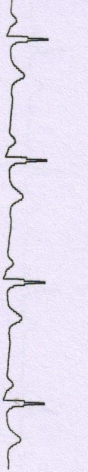II  
0.5  
0.0



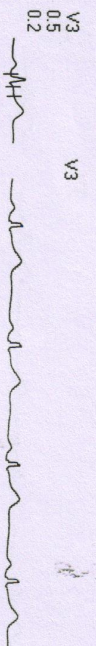V2  
0.3  
0.2



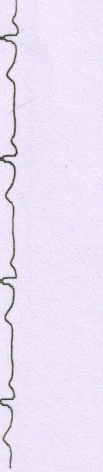III  
0.4  
-0.1



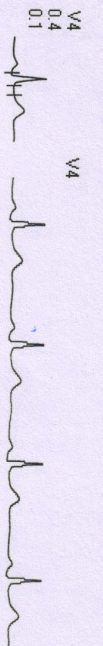V3  
0.5  
0.2



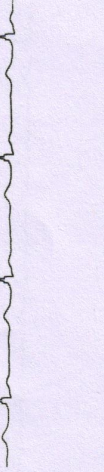aVR  
-0.3  
0.0



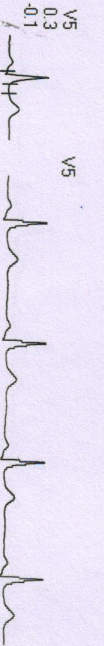
V4  
0.4  
0.1



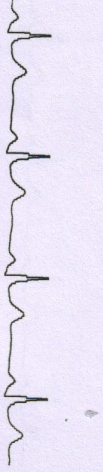
aVL  
-0.1  
0.1



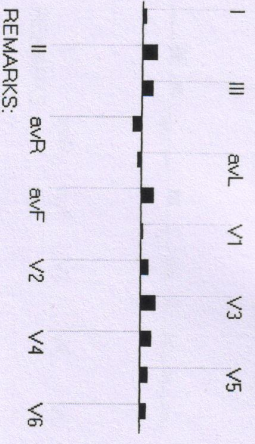
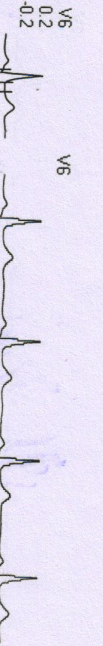V5  
0.3  
-0.1



aVF  
0.4  
-0.1



V6  
0.2  
-0.2



REMARKS:

MRS. ARPANA SHARMA / 47 Yrs / F / 160 Cms / 70 Kg / HR : 66

Date: 30-Dec-2021 10:22:18 AM

METS: 1.0 / 66 bpm 38% of THR BP: 120/80 mmHg

Raw ECG/ BLC On/ Notch On/ HF 0.05 Hz/LF 20 Hz

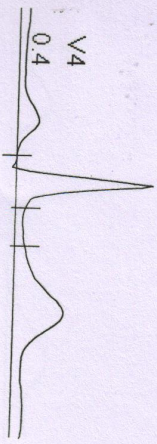
4X

80 ms Post J

HV



EXTime: 00:25 0.0 mph, 0.0%  
25 mm/Sec. 1.0 Cm/mV



STL 0.1  
STS 0.0



V1  
0.1  
0.1  
0.2



II  
0.5  
0.0



V2  
0.3  
0.2  
0.2



III  
0.4  
0.4  
-0.1



V3  
0.5  
0.5  
0.2



aVR  
-0.3  
0.0



V4  
0.4  
0.4  
0.1



aVL  
-0.1  
0.1



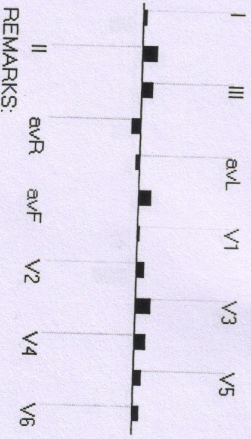
V5  
0.3  
0.3  
-0.1



aVF  
0.4  
-0.1



V6  
0.2  
0.2  
-0.2



REMARKS:


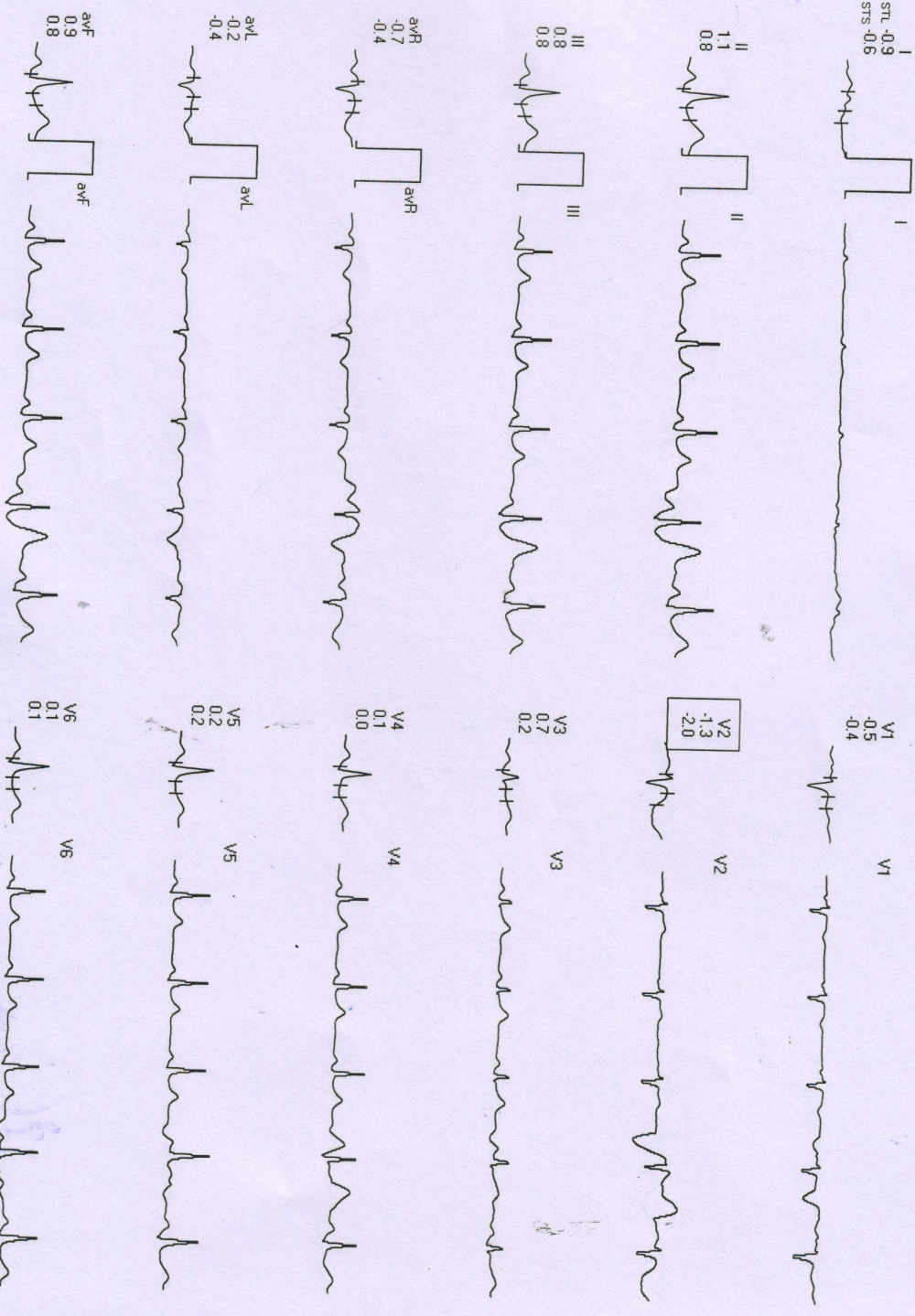
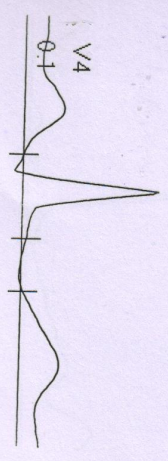
MRS. ARPANA SHARMA / 47 Yrs / F / 160 Cms / 70 Kg / HR . 91

Date: 30-Dec-2021 10:22:18 AM METS: 1.0/ 91 bpm 52% of THR BP: 120/80 mmHg Raw ECG/ BLC On/ Notch On/ HF 0.05 Hz/LF 20 Hz  
4X 80 ms Post J

WARM UP



ExTime: 01:02 1.0 mph, 0.0%  
25 mm/Sec. 1.0 Cm/mV



REMARKS:

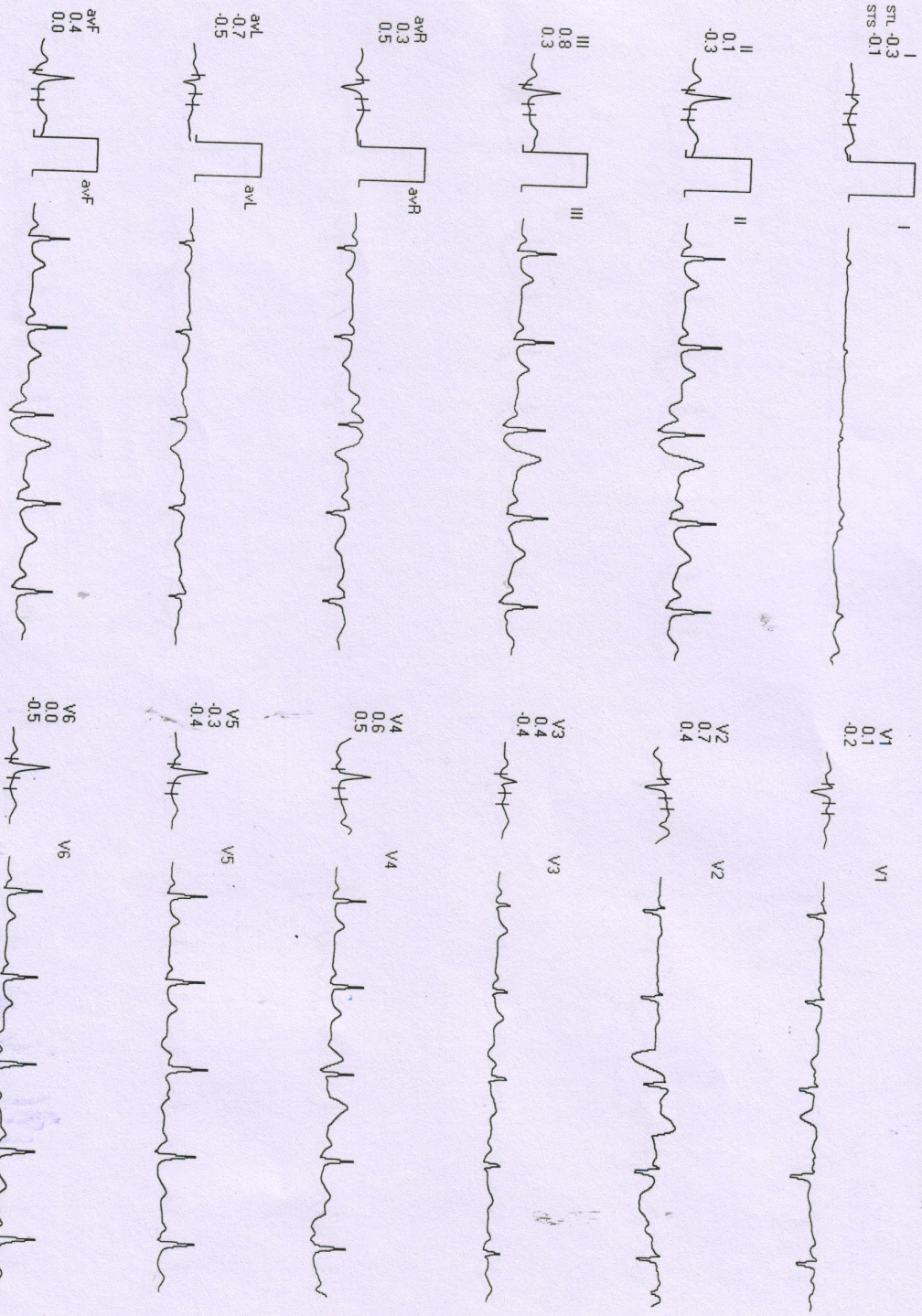
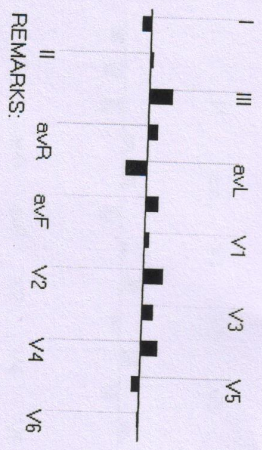
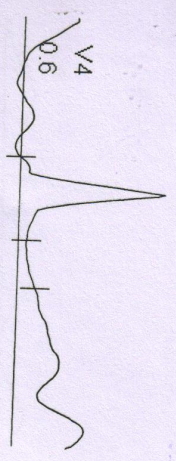
MRS. ARPANA SHARMA / 47 Yrs / F / 160 Cms / 70 Kg / HR . 91

Date: 30-Dec-2021 10:22:18 AM METS: 1.0/ 91 bpm 52% of THR BP: 120/80 mmHg Raw ECG/ BLC On/ Notch On/ HF 0.05 Hz/LF 20 Hz  
 4X 80 ms Post J

ExStt



ExTime: 00:00 0.0 mph, 0.0%  
 25 mm/Sec. 1.0 Cm/mV



REMARKS:



DOB / MRS. ARPANA SHARMA / 47 Yrs / F / 160 Cms / 70 Kg / HR : 147

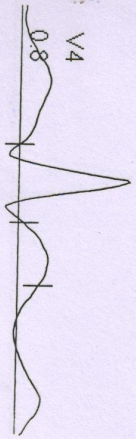
BRUCE : Stage 1 ( 03:00 )




Date: 30-Dec-2021 10:22:18 AM  
4X 60 ms Post J

METS: 4.7 / 147 bpm 84% of THR BP: 130/80 mmHg Raw ECG/ BLC On/ Natch On/ HF 0.05 Hz/LF 20 Hz


ExTime: 03:00 1.7 mph, 10.0%  
25 mm/Sec 1.0 Cm/mV




I  
STL -0.5  
STS -0.3



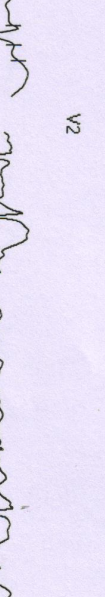V1  
0.1  
0.1  
0.8



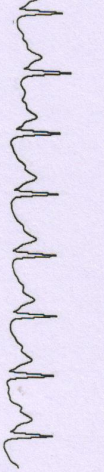
II  
-0.8  
0.1



V2  
0.8  
0.8  
1.2




III  
-0.8  
0.0



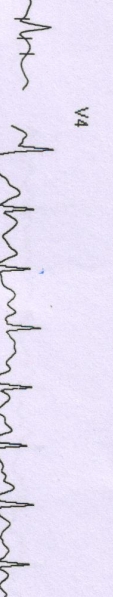
V3  
-0.3  
0.8  
0.8



aVR  
0.4  
0.4  
-0.1




V4  
0.8  
0.8  
0.6



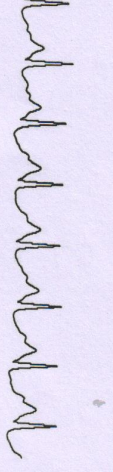
aVL  
0.4  
0.4  
0.0



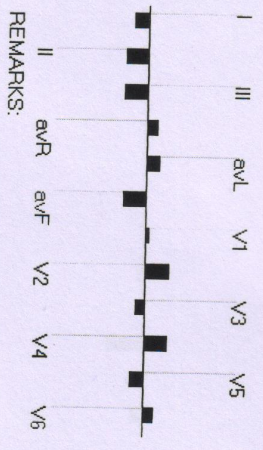
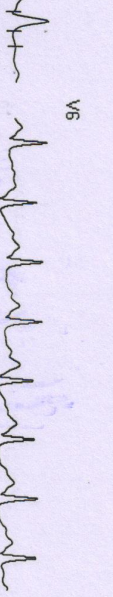
V5  
-0.5  
-0.2



aVF  
-0.8  
0.1



V6  
0.4  
0.4  
0.4



REMARKS:

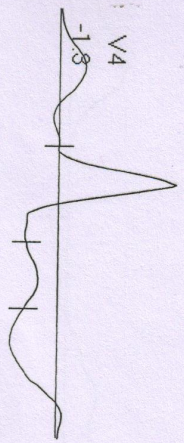
O/MRS. ARPANA SHARMA / 47 Yrs / F / 160 Cms / 70 Kg / HR : 165

Date: 30-Dec-2021 10:22:18 AM METS: 5.5 / 155 bpm 89% of THR BP: 130/80 mmHg Raw ECG/ BLC On/ Notch On/ HF 0.05 Hz/LF 20 Hz  
 4X 60 ms Post J

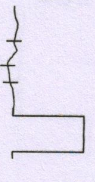
PeakEx




ExTime: 03:57 2.5 mph, 12.0%  
 25 mm/Sec. 1.0 Cm/mV



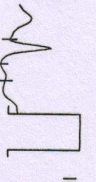STL -0.4  
 STS 0.7




V1  
 0.1  
 0.2



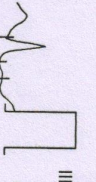
II  
 -0.5  
 1.0




V2  
 -0.2  
 -1.0



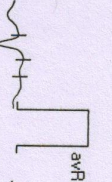
III  
 -0.5  
 0.7




V3  
 -0.1  
 1.1



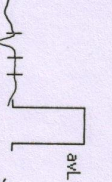
avR  
 0.3  
 -0.7



V4  
 -1.3  
 -0.3



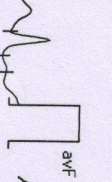
avL  
 0.2  
 -0.1



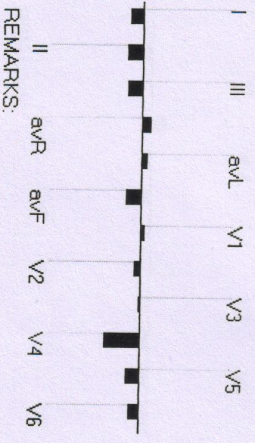
V5  
 -0.5  
 0.5



avF  
 -0.5  
 0.8



V6  
 -0.4  
 0.4



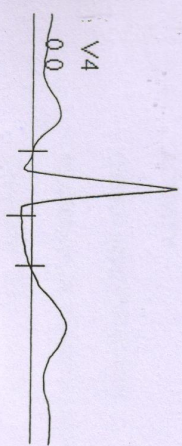
REMARKS:



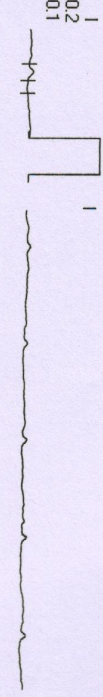
01/MRS. ARPANA SHARMA / 47 Yrs / F / 160 Cms / 70 Kg / HR . 87

Date: 30-Dec-2021 10:22:18 AM METS: 1.0/ 87 bpm 50% of THR BP: — / — mmHg Raw ECG/BLC On/ Notch On/ HF 0.05 Hz/LF 20 Hz  
 4X 80 ms Post J

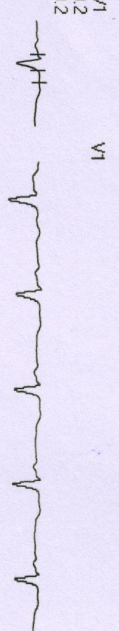
EXTime: 03:57 0.0 mph, 0.0%  
 25 mm/Sec. 1.0 Cm/mV



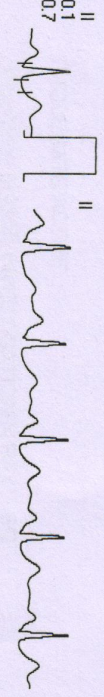
STL -0.2  
 STS -0.1




V1  
 0.2  
 0.2



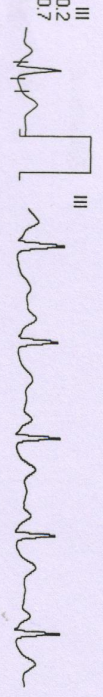
II  
 0.1  
 0.7




V2  
 1.1  
 0.6



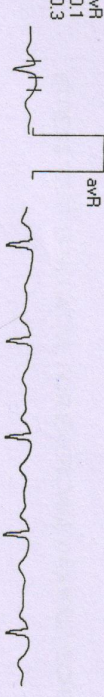III  
 0.2  
 0.7



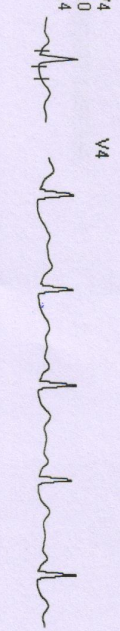
V3  
 0.5  
 1.0



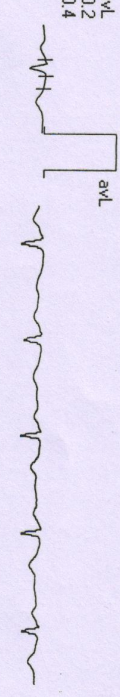avR  
 0.1  
 -0.3



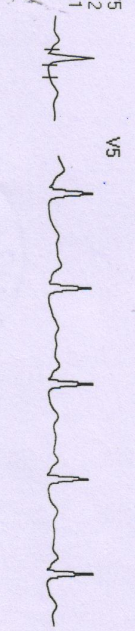
V4  
 0.0  
 0.4



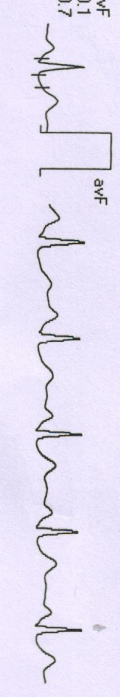
avL  
 -0.2  
 -0.4



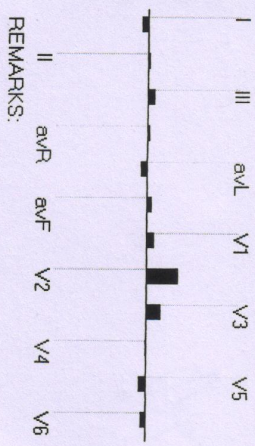
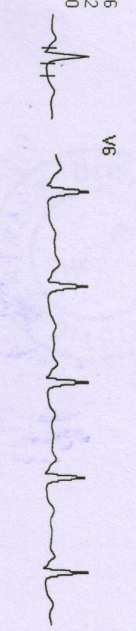
V5  
 -0.2  
 0.1



avF  
 0.1  
 0.7



V6  
 -0.2  
 0.0



REMARKS:

XTOIN

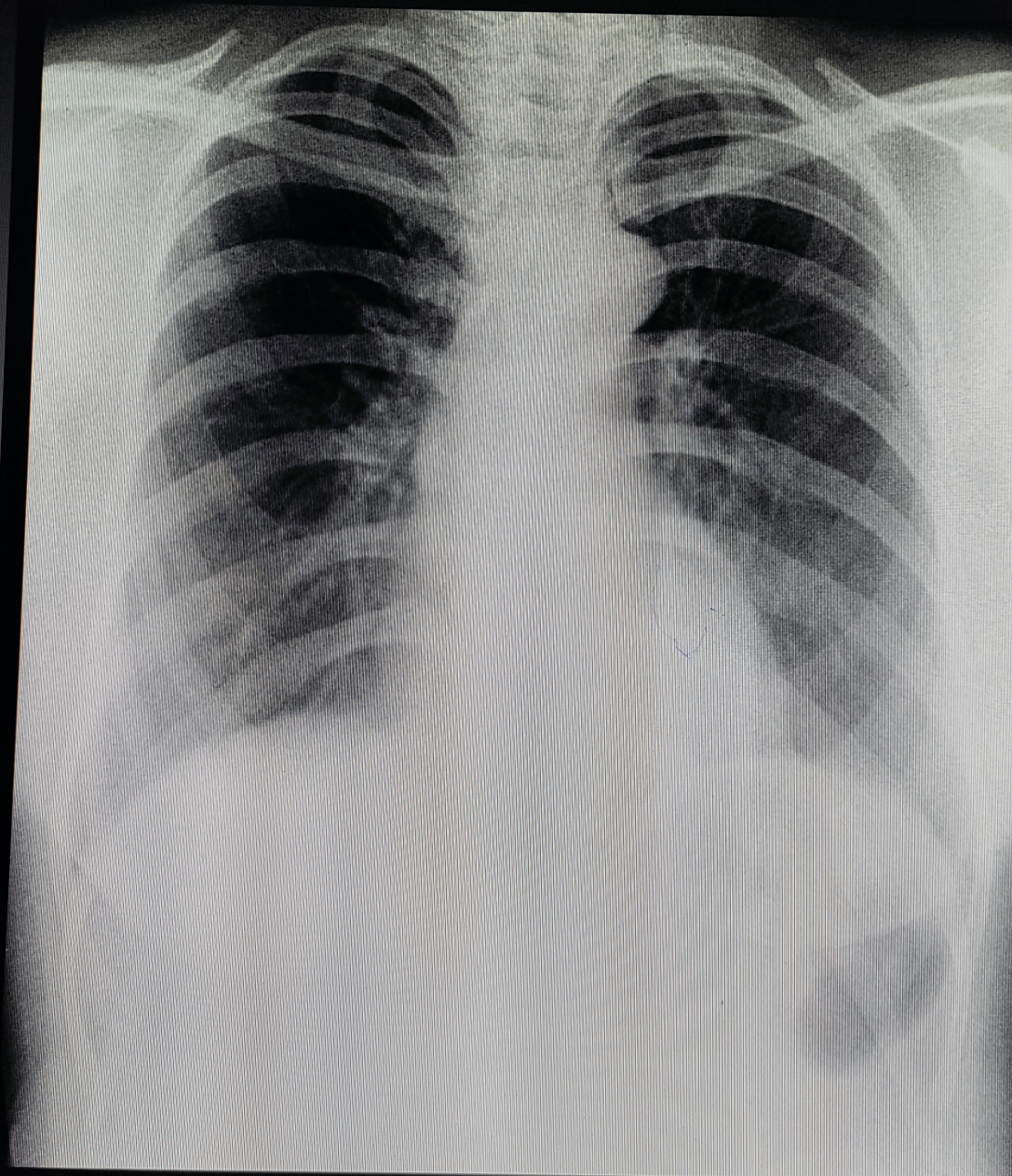
TRAIT

ICOM

e

t

e



MS APARNA SHARMA 47Y 704 CHEST,FRN P->A 30-DEct-21  
DIWAKAR DIAGNOSTIC CENTRE , ARERA COLONY ,BHOPAL

Shot on OnePlus

By 🧐

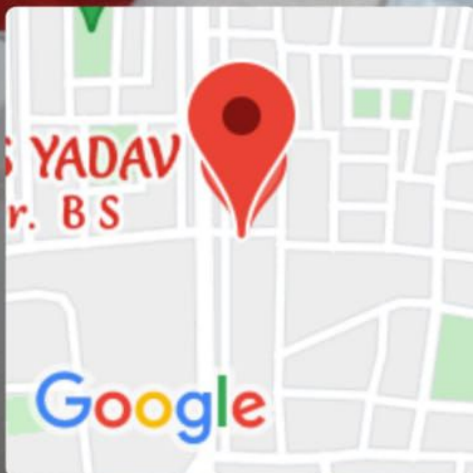


# Diwakar Diagnostic Centre

टी.ऍम.टी. | एक्स-रे | ई.सी.जी. | एको कार्डियो ग्राफी | सोनोग्राफी



GPS Map Camera



**Bhopal, Madhya Pradesh, India**

636, Campion School Rd, E-7, Arera Colony, Bhopal, Madhya

Pradesh 462016, India

Lat 23.205917°

Long 77.431603°

30/12/21 10:31 AM