



# YASHFEEN CARDIAC HOSPITAL

CH22043481 28/01/2023  
SMITA JITESHBHAI PATE  
38/F  
Bardoli, Bardoli 7600707155

Chief Complaint :



*Pravesh Chaudhary*

Medical History : ~~DM / HT / Asthama / Allergy / Heart / Thyroid / .....~~

Ocular History :

Visual Acuity : *6/6 C 6/6 /ms*

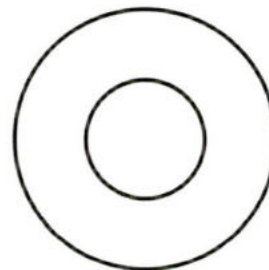
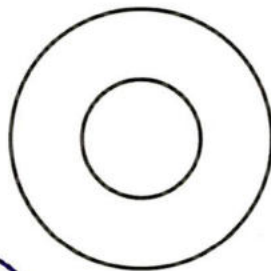
NAME	/
28_JAN_2023	PM 12:49
NO. 6168	
SN: 4771998	
REF. DATA	
VD: 12.00	CYL: MIX
<R> S C A	
- 2.50 - 2.00 72	
- 2.50 - 2.00 72	
- 2.50 - 2.00 72	
- 2.50 - 2.00 72	
S. E. - 3.50	
<L> S C A	
- 0.25 - 2.25 78	
- 0.25 - 2.25 78	
- 0.25 - 2.25 78	
- 0.25 - 2.25 78	
S. E. - 1.50	

OP :

<i>Ch glasses</i>	RIGHT EYE (PH.....)				LEFT I
	Sph.	Cyl.	Axis	V/A	Sph.
Distance					
Near					

Distance/Reading/Bi-Focal/Progressive/Separate Glasses

Sle :



*Rx*  
*Pravesh Chaudhary*

*6/6*



*my*

*↑*



# YASHFEEN CARDIAC HOSPITAL<sup>TM</sup>

MANAGED BY :- YASHFEEN FOUNDATION

VIRAVAL, NAVSARI. 396 445. PHONE : (H) (02637) 235725

Website : www.yashfeenhospital.in E-mail : info@yashfeenhospital.in



(Regd. No. E / 1390 / Navsari)

## 2D ECHO CARDIOGRAPHY COLOUR DOPPLER REPORT

Patient Name & No	: SMITA JITESHBHAI PATEL CH22043481	Age/Sex	UHID :	: 6765
Doctor	: Mohil Nagad	38/ F	No :	: 6925
Referred By	:		Date :	: 28/01/2023

### M-Mode findings

LVIDd : 40mm  
 LVIDs : 28mm  
 IVSd : 10mm  
 PWd : 10mm  
 EF : 60%  
 Aorta : 22mm  
 LA : 35mm

### 2D Imaging

Aortic Valve : Trileaflet, Normal  
 Mitral Valve : Thin, Pliable, Normal Mobility, Mild AML Prolapse, Mild MR.  
 Tricuspid Valve : Trivial TR, RVSP: 20+ RAP  
 Pulmonary Valve : Normal

=> : All cardiac chambers are normal sized.  
 => : No regional wall motion abnormality.  
 => : Normal LV systolic function.  
 => : Normal LV diastolic function.  
 => : IAS/IVS intact.  
 => : No obvious clots/ vegetations/ or effusion.  
 => : IVC Normal size.

### Doppler Findings

=> : No MS/Mild MR, No TS/Trivial TR, No AS/AR & No PS/PR  
 Mitral inflow Pattern : E > A  
 Tissue Doppler Findings : E' > A'

Impression : MVP, Normal LVEF:60%, No RWMA, Mild MR.



Report Prepared By

**DR. MOHIL NAGAD**  
 M.D. Medicine, Interne Cardiology  
 Senior Consultant- Interventional Cardiology  
 Regd. Invasive Cardiologist  
 YASHFEEN HOSPITAL, NAVSARI

# YASHFEEN IMAGING & RADIOLOGY DEPARTMENT

MANAGED BY :- YASHFEEN FOUNDATION

VIRAVAL, NAVSARI. 396 445. PHONE : (H) (02637) 235725

Website : [www.yashfeenhospital.in](http://www.yashfeenhospital.in) E-mail : [info@yashfeenhospital.in](mailto:info@yashfeenhospital.in)

Name	SMITA JITESHBHAI PATEL	Age	38Y/F
Ref by Dr	Self	Date	28/01/2023

## USG ABDOMEN & PELVIS (SCREENING) (TVS)

**Liver** appears normal in size & shape with normal echopattern.  
No e/o focal or diffuse lesion. IHBR appear normal.  
PV and CBD appear normal.

**Gall bladder** appears distended & normal in shape & size. No e/o calculus or mass seen.  
Walls appear normal.

**Pancreas** appears normal in size and echogenicity. No e/o focal or diffuse lesion.

**Spleen** appears normal in size and shows normal echopattern. No e/o focal lesion.

**Both Kidneys** appear normal in size and echopattern. CM Differentiation is preserved.  
No e/o calculus or hydronephrosis on either side.  
Perirenal spaces appear normal on either side.  
Suprarenal regions appear normal on either side. No e/o mass lesion.

**Bladder** is empty (due to non-compliance of patient). Adv: Follow up USG with normally distended bladder.

**Uterus** appears anteverted, normal in size & shows 6 x 6 mm in size heterogeneously hypo echoic rounded lesion involving posterior wall.  
Endometrial cavity is empty. ET- 5 mm.

**Both ovaries** appear normal in size & echopattern.  
No e/o adnexal mass on either side.

RIF region appears normal.

No e/o ascites.

### IMPRESSION:

**Uterine fibroid**



Dr. DHARMESH DESAI  
(M.D. Radiology)

Reg. No. G - 45284  
Dr. Dharmesh Desai  
YASHFEEN GROUP OF HOSPITAL

Please contact immediately for any typographical error.

This is only professional opinion, not a final diagnosis. Kindly correlate clinically. Not valid for medicolegal purpose.

# YASHFEEN IMAGING & RADIOLOGY DEPARTMENT

MANAGED BY :- YASHFEEN FOUNDATION

VIRAVAL, NAVSARI. 396 445. PHONE : (H) (02637) 235725

Website : [www.yashfeenhospital.in](http://www.yashfeenhospital.in) E-mail : [info@yashfeenhospital.in](mailto:info@yashfeenhospital.in)

Patient's Name:	SMITA J. PATEL	Age & Sex:	38Yrs/F
Ref. by Dr.	Self	Date:	28-01-2023

## X RAY CHEST (PA VIEW)

Both lung fields appear normal.

Both hila appear normal.

Both CP angles appear clear.

Cardiac size appears within normal limit.

Both domes of diaphragm appear normal.

Bony thoracic cage appears normal.

### IMPRESSION:

- Normal X-ray chest (PA view).



  
Dr. DHARMESH DESAI  
(M.D. Radiology)  
Reg. No. G - 45284

YASHFEEN GROUP OF HOSPITAL

Please contact immediately for any typographical error.

This is only professional opinion, not a final diagnosis. Kindly correlate clinically. Not valid for medicolegal purpose.



# YASHFEEN CARDIAC HOSPITAL™

At. & Po. Viraval, Navsari. 396 445. Phone (H) (02637) 235725

Website : [www.yashfeenhospital.in](http://www.yashfeenhospital.in) E-mail : [info@yashfeenhospital.in](mailto:info@yashfeenhospital.in)  
(For Laboratory Reports Only)



Patient Name : SMITA JITESHBHAI PATEL  
Ref By Dr. : -  
Sample Time : 28/01/2023 10:04 No : 12

Age : 38 Years Sex : F  
Area : Bardoli Date : 28/01/2023  
Time : 12:19PM

## ROUTINE URINE ANALYSIS

Test	Findings	UOM	Normal Range
<b>PHYSICAL EXAMINATION</b>			
Quantity	-	-	
Colour	YELLOW	-	
Appearance	CLEAR	-	
Reaction	ACIDIC	-	
Sp. Gravity	1.005	-	
<b>CHEMICAL EXAMINATION</b>			
U.Albumin	NIL	-	
Sugar	NIL	-	
Acetone	NIL	-	
Bile Salt	NIL	-	
Bile Pigment	NIL	-	
Occult Blood	NIL	-	
<b>MICROSCOPIC EXAMINATION</b>			
Pus Cells	<u>2-3</u>	/hpf	
Epithelial cells	1-2	/hpf	
Red cells	ABSENT	/hpf	
Casts	-	/hpf	
Crystals	<u>AMORPHOUS SEEN</u>	/hpf	
Others	<u>BACTERIA {FEW} SEEN</u>	/hpf	



*P. Chaudhari*  
Dr. PIYUSH B. CHAUDHARI  
M.D. Medicine  
Reg. No. G-21518

Remarks

Designed By : Sarita Infotech Pvt. Ltd., Navsari

Yashfeen Cardiac Hospital

*P. Patel*  
signature

Thanks for Reference

Technician



# YASHFEEN CARDIAC HOSPITAL™

At. & Po. Viraval, Navsari. 396 445. Phone (H) (02637) 235725

Website : [www.yashfeenhospital.in](http://www.yashfeenhospital.in) E-mail : [info@yashfeenhospital.in](mailto:info@yashfeenhospital.in)  
(For Laboratory Reports Only)



Patient Name : SMITA JITESHBHAI PATEL

Ref By Dr. : -

Sample Time : 28/01/2023 10:03 No : 12

Age : 38 Years Sex : F

Area : Bardoli

Date : 28/01/2023

Time : 12:19PM

## GGT TEST REPORT

Test	Findings	UOM	Normal Range
SERUM GGT	25	U/L	10-71 U/L



*f. Chaudh*  
Dr. PIYUSH B. CHAUDHARI  
M. D. Medicine  
Reg. No. G-21518

Remarks

Designed By : Sarita Infotech Pvt. Ltd., Navsari

Yashfeen Cardiac Hospital

*Retn*  
signature

*Thanks for Reference*

Technician



# YASHFEEN CARDIAC HOSPITAL™

At. & Po. Viraval, Navsari. 396 445. Phone (H) (02637) 235725

Website : www.yashfeenhospital.in E-mail : info@yashfeenhospital.in

(For Laboratory Reports Only)



Patient Name : SMITA JITESHBHAI PATEL

Age : 38 Years Sex : F

Ref By Dr. : -

Area : Bardoli Date : 28/01/2023

Sample Time : 28/01/2023 10:03 No : 12

Time : 12:19PM

## THYROID FUNCTION TEST REPORT

Test	Findings	UOM	Normal Range
T3 (TRIODOXYRINE)	1.47	ng/ml	NEWBORNS:0.73-2.88 6DAYS-3MONTHS:0.80-2.75 4-12MONTHS:0.86-2.65 1-6YEARS:0.92-2.48 7-11YEARS:0.93-2.31 12-20YEARS:0.91-2.18 ADULT:0.80-2.00
T4(THYROXINE)	9.43	µg/dl	NEWBORNS:5.04-18.5, 6DAYS-3MONTHS:5.41-17.0, 4-12 MONTHS:5.67-16.0, 1-6YEARS:5.95-14.7, 7-11 YEARS:5.99-13.8, 12-20 YEARS:5.91-13.2, ADULTS:5.10-14.1
TSH	1.56	µIU/ml	NEWBORNS:0.70-15.2, 6DAYS-3MONTHS:0.72-11.0, 4-12MONTHS:0.73-8.35, 1-6YEARS:0.70-5.97, 7-11YEARS:0.60-4.84, 12-20YEARS:0.51-4.30, ADULTS:0.27-4.20

### TECHNIQUE

ELECTROCHEMILUMINESCEN  
CE



*P. Chaudhari*  
Dr. PIYUSH B. CHAUDHARI  
M. D. Medicine  
Reg. No. G-21518

Remarks

Designed By : Samir A. Chaudhari Pvt. Ltd., Navsari

Yashfeen Cardiac Hospital

*[Signature]*  
signature

Thanks for Reference

Technician



# YASHFEEN CARDIAC HOSPITAL™

At. & Po. Viraval, Navsari. 396 445. Phone (H) (02637) 235725

Website : [www.yashfeenhospital.in](http://www.yashfeenhospital.in) E-mail : [info@yashfeenhospital.in](mailto:info@yashfeenhospital.in)  
(For Laboratory Reports Only)



Patient Name : SMITA JITESHBHAI PATEL

Age : 38 Years Sex : F

Ref By Dr. : -

Area : Bardoli

Date : 28/01/2023

Sample Time : 28/01/2023 10:03 No : 12

Time : 12:19PM

## LIVER FUNCTION TEST REPORT

Test	Findings	UOM	Normal Range
TOTAL BILIRUBIN	0.5	mg/dL	0-1.0
DIRECT BILIRUBIN	0.2	mg/dL	0-0.8
INDIRECT BILIRUBIN	<b>0.3</b>	mg/dL	0-0.2
SGPT	10.0	U/L	Below 40.0
S.ALKALINE PHOSPHATASE	64.8	U/L	CH . 170.0-515.0 A. 37.0-147.0
TOTAL PROTEIN	7.0	g/dl	6.0-8.0
ALBUMIN	4.9	g/dl	3.0-5.0
GLOBULIN	<b>2.1</b>	g/dl	3.0-3.5
A/G	2.3	g/dl	
SGOT	10.4	U/L	Below 40.0



*P. Chaudhari*  
Dr. PIYUSH B. CHAUDHARI  
M.D. Medicine  
Reg. No. G-21518

Remarks

Designed By : Sarita Infotech Pvt. Ltd., Navsari

Yashfeen Cardiac Hospital

*[Signature]*  
signature

*Thanks for Reference*

Technician





# YASHFEEN CARDIAC HOSPITAL™

At. & Po. Viraval, Navsari. 396 445. Phone (H) (02637) 235725

Website : [www.yashfeenhospital.in](http://www.yashfeenhospital.in) E-mail : [info@yashfeenhospital.in](mailto:info@yashfeenhospital.in)  
(For Laboratory Reports Only)



Patient Name : SMITA JITESHBHAI PATEL  
Ref By Dr. : -  
Sample Time : 28/01/2023 10:03 No : 12

Age : 38 Years Sex : F  
Area : Bardoli Date : 28/01/2023  
Time : 12:19PM

## LIPID PROFILE TEST REPORT

Test	Findings	UOM	Normal Range
S.CHOLESTEROL	171.0	mg/dL	<200:Desirable, 200-239:Borderline High, >=240:High
HDL CHOLESTEROL	49.6	mg/dL	<40:Low(High Risk), >=60:High(Low Risk)
LDL CHOLESTEROL	<u>123.5</u>	mg/dL	<100: Optimal, 100-129: Nearoptimal/ Aboveoptimal, 130-159:BorderlineHigh,160-189:High,>=190:Very High
VLDL CHOLESTEROL	14.5	mg/dL	UPTO 40
S.TRIGLYCERIDES	72.3	mg/dL	<150:Normal, 150-199:Borderline High, 200-499:High, >=500:Very High
CHOL/ HDL RATIO	3.5	mg/dL	LESS THAN 5
LDL/ HDL RATIO	2.5	mg/dL	LESS THAN 5



*P. Chaudhari*  
Dr. PIYUSH B. CHAUDHARI  
M. D. Medicine  
Reg. No. G-21518

Remarks

Designed By : Sarita InfoTech Pvt. Ltd., Navsari

Yashfeen Cardiac Hospital

*[Signature]*

signature

*Thanks for Reference*

Technician



# YASHFEEN CARDIAC HOSPITAL™

At. & Po. Viraval, Navsari. 396 445. Phone (H) (02637) 235725

Website : [www.yashfeenhospital.in](http://www.yashfeenhospital.in) E-mail : [info@yashfeenhospital.in](mailto:info@yashfeenhospital.in)  
(For Laboratory Reports Only)



Patient Name : SMITA JITESHBHAI PATEL  
Ref By Dr. : -  
Sample Time : 28/01/2023 10:03 No : 12

Age : 38 Years Sex : F  
Area : Bardoli Date : 28/01/2023  
Time : 12:19PM

## BIOCHEMICAL TEST REPORT

Test	Findings	UOM	Normal Range
S.CREATININE	<u>0.5</u>	mg/dL	M .0.9-1.4 , F. 0.8-1.2
S.URIC ACID	4.3	mg/dL	Male:3.5-7.2, Female:2.6-6.0
BLOOD UREA NITROGEN	6.9	mg/dL	4.7-23.0



*P. Chaudhari*  
Dr. PIYUSH B. CHAUDHARI  
M.D. Medicine  
Reg. No. G-21518

Remarks

Designed By : Sarita Infotech Pvt. Ltd., Navsari

Yashfeen Cardiac Hospital

*[Signature]*  
signature

*Thanks for Reference*

Technician



# YASHFEEN CARDIAC HOSPITAL™

At. & Po. Viraval, Navsari. 396 445. Phone (H) (02637) 235725

Website : [www.yashfeenhospital.in](http://www.yashfeenhospital.in) E-mail : [info@yashfeenhospital.in](mailto:info@yashfeenhospital.in)  
(For Laboratory Reports Only)



Patient Name : SMITA JITESHBHAI PATEL

Age : 38 Years Sex : F

Ref By Dr. : -

Area : Bardoli

Date : 28/01/2023

Sample Time : 28/01/2023 10:03 No : 12

Time : 12:18PM

## HAEMOGLOBIN A1 C ESTIMATION

Test	Findings	UOM	Normal Range
Hb A1C	5.9	%	>8 :Action Suggested, 7-8 :Good Control, <7 :Goal, 6-7 :Near Normal Glycemia, <6 :Non-diabetic Level
<b>Technique</b> METHOD - HPLC			
Mean Blood Glucose	121.4	mg/dL	



*P. Chaudhari*  
Dr. PIYUSH B. CHAUDHARI  
M.D. Medicine  
Reg. No. G-21518

Remarks

Designed By : Sarita Infotech Pvt. Ltd., Navsari

Yashfeen Cardiac Hospital

*Retu*  
signature

*Thanks for Reference*

Technician



# YASHFEEN CARDIAC HOSPITAL™

At. & Po. Viraval, Navsari. 396 445. Phone (H) (02637) 235725

Website : [www.yashfeenhospital.in](http://www.yashfeenhospital.in) E-mail : [info@yashfeenhospital.in](mailto:info@yashfeenhospital.in)  
(For Laboratory Reports Only)



Patient Name : SMITA JITESHBHAI PATEL

Age : 38 Years Sex : F

Ref By Dr. : -

Area : Bardoli Date : 28/01/2023

Sample Time : 28/01/2023 10:03 No : 12

Time : 12:50PM

## BLOOD SUGAR TEST REPORT

Test	Findings	UOM	Normal Range
FASTING BLOOD SUGAR	94.7	mg/dL	70-110
FASTING URINE SUGAR	NIL	-	NIL
POSTPANDRIAL BLOOD SUGAR	72.0	mg/dL	70-140
POSTPANDRIAL URINE SUGAR	NIL	-	NIL

Remarks

Designed by Parita Intellim Pvt. Ltd., Navsari

Yashfeen Cardiac Hospital

*P. Chaudhari*  
Dr. PIYUSH B. CHAUDHARI  
M.D. Medicine  
Reg. No. G-21518

*Abhinav*  
signature  
Technician

Thanks for Reference



# YASHFEEN CARDIAC HOSPITAL™

At. & Po. Viraval, Navsari. 396 445. Phone (H) (02637) 235725

Website : www.yashfeenhospital.in E-mail : info@yashfeenhospital.in

(For Laboratory Reports Only)



Patient Name : SMITA JITESHBHAI PATEL

Age : 38 Years Sex : F

Ref By Dr. : -

Area : Bardoli Date : 28/01/2023

Sample Time : 28/01/2023 09:14 No : 12

Time : 12:18PM

## HAEMOGRAM

Test	Findings	UOM	Normal Range
HAEMOGLOBIN	14.2	gm/dl	M-13.5-17.0 F-11.5-15.5
<b>HAEMOGRAM</b>			
RED BLOOD CELL	5.27	10 <sup>6</sup> /μL	3.76 - 5.70
TOTAL LEUCOCYTE COUNT	7800	cells/cumm	4,000-11,000
<b>Differential Count</b>			
Neutrophil	60	%	40-75
Lymphocytes	35	%	20-40
Eosinophil	1	%	1-6
Monocytes	4	%	2-10
Basophils	0	%	0-0
PLATELET COUNT	323000	lacs/cumm	1.5-5.5 Lacs
<b>RBC INDICES</b>			
P.C.V.	43.5	%	M-40-56% F-37-47%
M.C.V.	82.5	cu/microns	76-94
M.C.H.	<b>26.9</b>	pg	27-30
M.C.H.C.	32.5	-	30-35
BLOOD GROUP	" A "	-	-
RH FACTOR	POSITIVE	-	-
E.S.R.(1 hour)	8	mm/hr.	M-5-10, F-5-20

Remarks

Designed By: Sarita Infotech Pvt. Ltd., Navsari

*p. chauhan*  
Dr. PIYUSH B. CHAUDHARI  
M.D. Medicine  
Reg. No. G-21518

*Signature*  
signature

Technician

SMITABEN ,

ID:

DOB:

..

Female ,Unknown

Med.:

Location:

Referring Physician:

Notes:

26-01-2023 22:58:09

Vent. Rate:	70 BPM
PR int:	121 ms
QRS dur:	75 ms
QT/QTc:	339/359 ms
P-R-T axes:	26 42 50
Avg. RR:	857 ms
QTcB:	366 ms
QTcF:	356 ms

SINUS RHYTHM  
 NONSPECIFIC T-WAVE ABNORMALITY  
 BORDERLINE ECG  
 INTERPRETATION BASED ON A DEFAULT AGE OF 40 YEARS

UNCONFIRMED REPORT

Reviewed by:

Dr. PIYUSH B. CHAUDHARI

M.D. Medicine

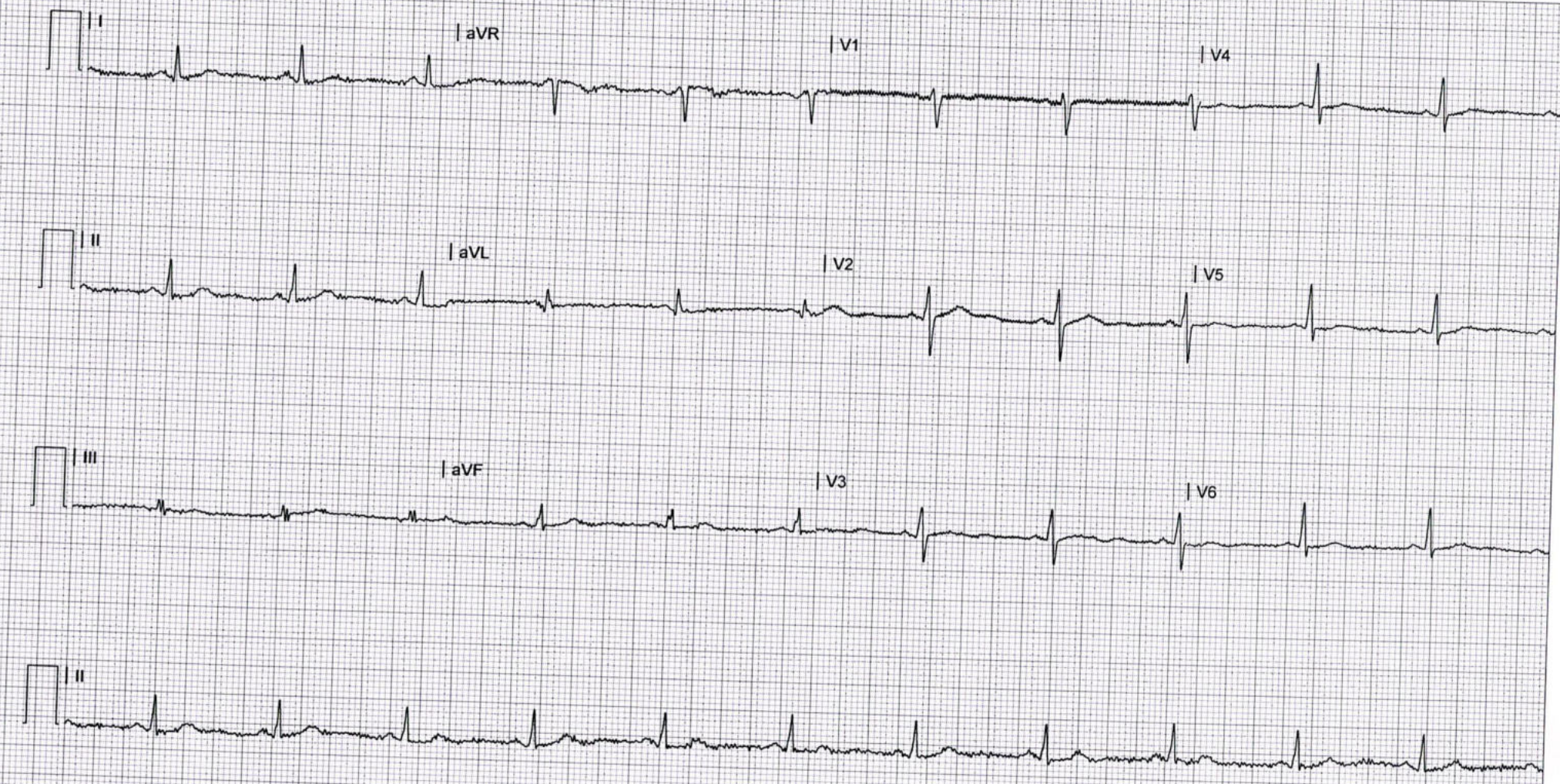
Reg. No. G-21513

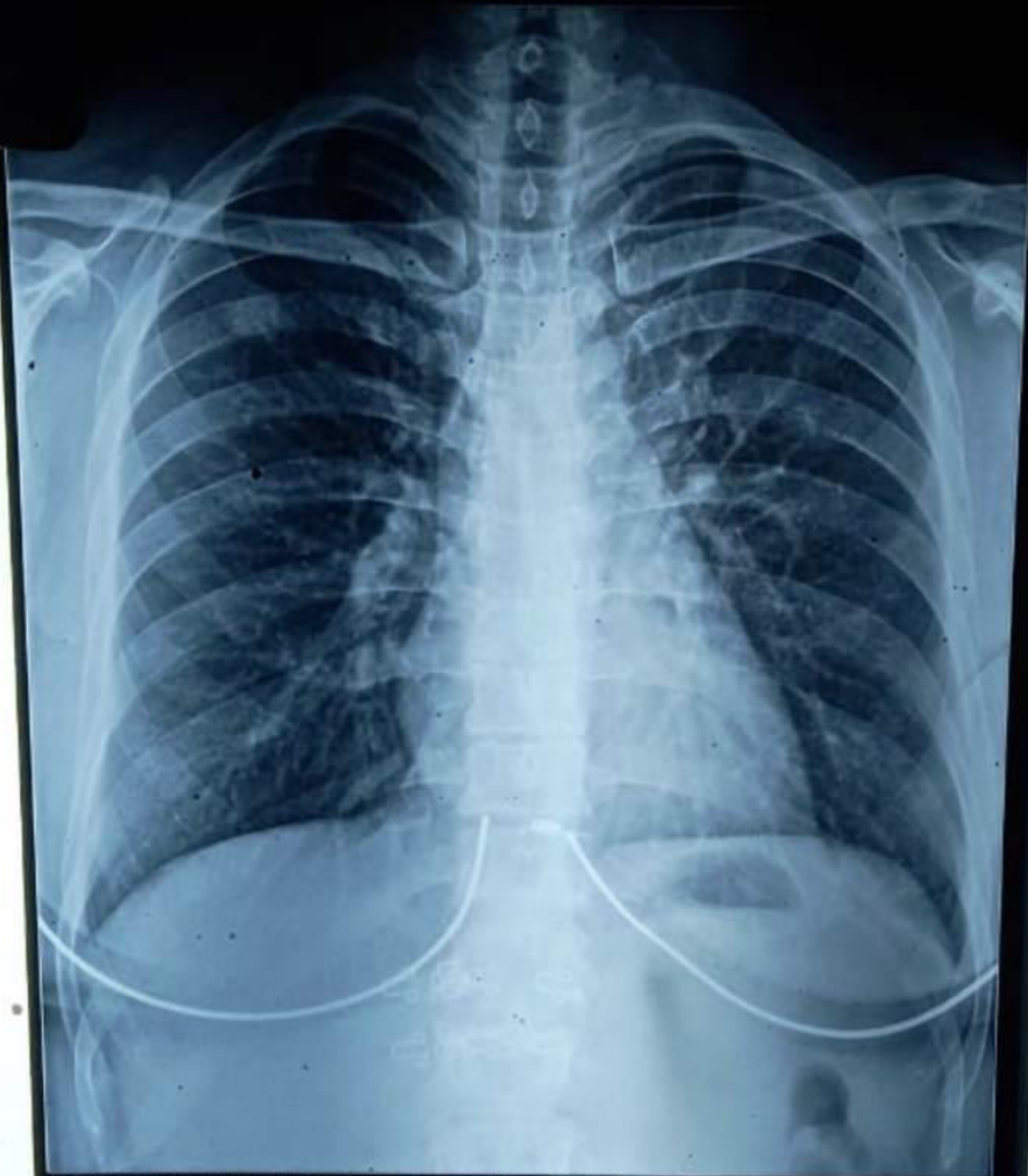
Signed by:

Date:



*Smita J. Patel 38/F*





CH22043481 SMITA J PATEL 38/Y 2801231830 CHEST PA 28-01  
YASHFEEN GROUP OF HOSPITALS NAVSARI PH:9924047789