



PARKLINE DIAGNOSTICS PVT. LTD.

L.G. 3, 4 & 5, Bhuvana Towers, S.D. Road, Secunderabad - 500 003.

Tel : +91 40-2784 5852, 6649 1787, 7995421787, 7093445852, Fax : +91 40 2784 7864

Email parklinediagnostics@gmail.com www.parklinediagnostics.com



NABL Accredited
Certificate No.MC-2566

MEDICAL EXAMINATION REPORT

Name	MS. Chakka Kalyani		Date :	19/03/2022
Company	Clo: mediawheel		Reg. No. :	1888503
Contact No.	8074997868		Sex	<input checked="" type="checkbox"/> F Age : <input type="checkbox"/> 50
Type	Pre-Emp		Emp. No.:	Spouse
	Overseas		Height	155 cm
	Annual	<input checked="" type="checkbox"/>	Weight	78 kgs
Remarks	<p>TMT Intermediate probability of Coronary Artery Disease.</p> <p>Advice CAG for further follow up & management.</p> <p>Mammography: Soft tissue opacities found in both breasts c BI-RADS - II</p> <p>Advice to Follow up c USG Breast.</p>			
			<p>DR. PRIYANKA SANNIDHI MBBS Reg. No. 11351</p>	
Fitness Status	Medically Fit / Unfit		Physician's Signature	


COMPREHENSIVE MEDICAL EXAMINATION REPORT

NAME Ms. CHAKKA KALYANI

AGE 50 yrs Female

MARITAL STATUS Married CHILDREN : M F

IDENTIFICATION (IF ANY) A mole on (Rt) eye ball.



PAST HISTORY

Any family H/o : High Blood Pressure, Heart Disease, Tuberculosis, Diabetes, Asthma, Cancer

father

Any personal H/o Major illness like : Typhoid.....NIL.....Jaundice.....1985.....Etc.

Any H/o STD.....Skin infection.....NIL.....

H/o Blood Transfusion.....NIL.....Recent Vaccination.....COVID 2020 ✓

H/o Epilepsy.....Giddiness.....NIL.....

H/o Surgery.....Hysterectomy 2018.....Fracture in the past.....NIL.....

Any Personal H/O.

High Blood Pressure, Heart Disease Tuberculosis, Diabetes, Asthma, Cancer

Drug Abuse, Drug Allergy, Micturition, Bowels, Alcohol, Smoking, Sleep, MC, Wt. Loss/Wt. Gain

Present illness / Medication

GENERAL EXAMINATION

Conjunctiva :

Skin :

Ears :

Nose :

Throat & Oral Cavity :

None

Bone, Joints :

Nutritional Status :

Lymph Nodes :

Edema Feet :

Varicose Veins :

(N)
Well Nourished
NPD
NIL
NIL

Distant Vision : Near Vision :

Right Eye: 6/18 +2.00 sph 6/6

With glasses / Without glasses

left Eye : 6/18 +2.00 sph 6/6

with glasses / without glasses

Colour Vision : BE normal

Right Ear

Hearing :

(N)

Rinee's Test ;

Weber Test :

Discharge :

NIL

NIL

Right Eye: ^{N10} Add +2.00 sph N6

With glasses / Without glasses

left Eye : N10 Add +2.00 sph N6

with glasses / without glasses

Ophthalmologist's Signature

DR. KATTA
M.B.B.S., D.O., F.R.F
16261 (AMC)

Left Ear

(N)

SYSTEMIC EXAMINATION

Pulse : 80 bpm

B.P. : 110/80 mmHg

Lungs : A. Shape of Chest R/L symmetrical
B. Breath Sounds R/L - clear ⊕
C. Adventitious Sounds NO

Heart : A. Sounds S1 S2 ⊕
B. Murmurs no murmurs

Abdomen : A. Liver NPD
B. Spleen NPD
C. Piles NIL
D. Any Lump NIL

Nervous System

A. Higher Function :
B. Cranial Nerves :
C. Sensory System :
D. Motor System :
E. Jerks :
] (N)

General : A. Hernia
B. Hydrocele
C. Varicocele] NAD

Breast : Rt _____ Lt. _____

CANDIDATE'S DECLARATION

I hereby solemnly declare that I am not suffering from Asthma, Hypertension, Diabetes, Occult Psychological disorders or any other ailment which can be suppressed without my voluntary declaration.

Date :

C. K. Rajani
Signature

Place :

Note : General Physical Examination and Investigation included in the health check-up Have certain limitations and may not be able to detect all latent and asymptomatic diseases. Any new symptoms developing after the health check-up or persisting thereafter should be brought to the attention of the treating physician.



Phone: 27844043
66339096

SECUNDERABAD DENTAL HOSPITAL

CENTRE FOR ADVANCED DENTAL CARE

19/3/22

ORAL & MAXILLOFACIAL SURGEONS

Dr. Kazim Himathi M.D.S.

Dr. Gautam Dendukuri

FDSRCS (Eng), FFDRCS (Ire),
FFDRCS (OMFS),(Ire)

PROSTHODONTIST

Dr. Chandrakanth Reddy M.D.S.

ENDODONTIST

Dr. Ram Narayan Reddy M.D.S.

ORTHODONTIST

Dr. Rajesh Reddy M.D.S., M.Orth RCS.

Dr. Sudeep Bhalerao M.D.S.

PERIODONTIST

Dr. Veerendranath Reddy M.D.S.

PEDODONTIST

Dr. Soumya M.D.S.

Mounika M.D.S.

DENTAL SURGEONS

Dr. N. Jagadish Rao B.D.S.

Dr. Baisakhi Saha B.D.S.

Mrs. Chakka Kalyani
50y/F

Patient complains of pain in the left
lower back tooth region since
the past 1 week.

O/E,

1. Dental Caries at 33
2. Deep dental Caries at 35
3. Missing at 36 37.

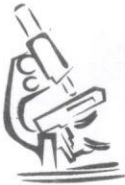Treatment plan

1. Adv. x-ray at 35 33
2. Adv. RPD/Implant at 36 37



1-2-261/4-6, S.D. Road, Opp. Minerva Complex, Secunderabad - 500 003.

Visit us at : www.secdental.com



PARKLINE DIAGNOSTICS PVT. LTD.

L.G. 3, 4 & 5, Bhuvana Towers, S.D. Road, Secunderabad - 500 003. Tel : +91 40-2784 5852, 6649 1787, 7995421787,
7093445852, Fax : +91 40 2784 7864 Email parklinediagnostics@gmail.com www.parklinediagnostics.com



NABL Accredited
Certificate No.MC-2566

ENT CONSULTATION

S.No.	Emp.No.	Date
Name 'Chakka Kalyani'	Age 50 Yrs	Sex M/F

EARS :

Right

Left

EAC	:	patent. no Cerumen.	- do
TM	:	Intact, pearly white.	- do
TFT	:	Cone of light (+) Rinne's +ve Weber's - central	Rinne's +ve

NOSE

: Septum: (N)sto (L), Bil. T'symmetry (N) pros (N) no tend.

THROAT

: Oropharynx: (N) Bil. v.c'ss (N) moving bil
Aerobically

NECK

: (N)

IMPRESSION:

Ear T. Dnos to (L)

Dr. D. Hanu Krishna Reddy
MS (ENT)
Head & Neck Surgeon
Reg. No: 88379



PARKLINE DIAGNOSTICS PVT. LTD.

L.G. 3, 4 & 5, Bhuvana Towers, Sarojini Devi Road, Secunderabad - 500 003 Tel. +91 40-2784 5852
6649 1787 Fax : +91 40 2784 7864 Email : parklinediagnostics@gmail.com www.parklinediagnostics.com



NABL Accredited
Certificate No. MC-2566

TEST REPORT

Mrs. Karlyani C
50 yrs.

19.3.22

- Hysterectomy
- AUB
- 5 gm

Bowel - constipation
urine - (N) + Regular
W.D - NIL

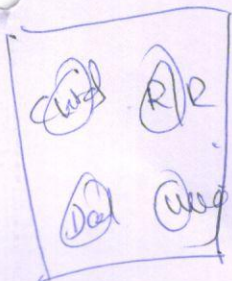P/A Obesity +
Breast - NAD

Adv

- Weight Management -

Diet - Management

Exercise -



Skel - H-D

- 0 - Const'ment

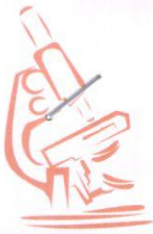feb

Dr. JAMUNA DEVI. G
MBBS, DGO, LL.B, (LL.M)
Regd.No. 9207, A.P. Medical Council
Obstetrician & Gynaecologist

The Test marked with*are not accredited by NABL

Lab Timings (Weekdays) : 7.00 am to 8.30 pm
Sundays & Holidays : 7.00 am to 1.00 pm

Radiologists Timings (Weekdays) : 7.30 am to 1.30 pm
& 5.30 pm to 7.45 pm
Sundays & Holidays : 7.30 am to 9.30 am



PARKLINE DIAGNOSTICS PVT. LTD.

L.G 3, 4 & 5, Bhuvana Towers, Sarojini Devi Road, Secunderabad - 500 003.
Tel. +91 40 2784 5852, 6649 1787, 77995421787, 7093445852, Fax : + 91 40 2784 7864
Email : parklinediagnostics@gmail.com, www.parklinediagnostics.com



TEST REPORT

Name	: Ms . CHAKKA KALYANI [SPOUSE]	TID	: UMR0746890
Age / Gender	: 50 Years / Female	Registered on	: 19-Mar-2022 07:56 AM
Ref.By	: Medi Wheel	Reported On	: 19-Mar-2022 01:47 PM
Req. No	: BIL1888543		

ABDOMINO-PELVIC ULTRASONOGRAPHY

LIVER is normal shape, size (12.6 cms) and has uniform echopattern.
No evidence of focal lesion or intrahepatic biliary ductal dilatation.
Hepatic and portal vein radicals are normal.

GALL BLADDER shows normal shape and has clear contents.
Gall bladder wall is of normal thickness.
CBD is of normal calibre.

PANCREAS has normal shape, size and uniform echopattern.
No evidence of ductal dilatation or calcification.

SPLEEN shows normal shape, size and echopattern.

KIDNEYS move well with respiration and have normal shape, size and echopattern.
Cortico- medullary differentiations are well made out.
No evidence of calculus or hydronephrosis.
Right kidney measures: 10.2 x 4.4 cms, Left kidney measures: 9.2 x 4.3 cms.

URINARY BLADDER shows normal shape and wall thickness.
It has clear contents. No evidence of diverticula.

UTERUS status post hysterectomy.

OVARIES are not visualized.

No evidence of free fluid in the abdomen and pelvis.

IMPRESSION:

* **No sonographic abnormality detected.**

Suggested clinical correlation and follow up

Per *Ar*
Dr. Abid Yazden
Consultant Radiologist

The Test marked with*are not accredited by NABL

Lab Timings (Weekdays) : 7.00 am to 8.30 pm
Sundays & Holidays : 7.00 am to 1.00 pm

Radiologists Timings (Weekdays) : 7.30 am to 1.30 pm
& 5.30 pm to 7.45 pm
Sundays & Holidays : 7.30 am to 9.30 am



PARKLINE DIAGNOSTICS PVT. LTD.

L.G 3, 4 & 5, Bhuvana Towers, Sarojini Devi Road, Secunderabad - 500 003.
Tel. +91 40 2784 5852, 6649 1787, 77995421787, 7093445852, Fax : + 91 40 2784 7864
Email : parklinediagnostics@gmail.com, www.parklinediagnostics.com



NABL Accredited
Certificate No.: MC-2566

TEST REPORT

Name : Ms . CHAKKA KALYANI [SPOUSE]
Age / Gender : 50 Years / Female
Ref.By : Medi Wheel
Req. No : BIL1888543

TID : UMR0746890
Registered on : 19-Mar-2022 07:56 AM
Reported On : 19-Mar-2022 01:07 PM

DEPARTMENT OF ULTRASOUND Mammography

Bilateral CC and MLO views done.

Fairly well defined soft tissue opacities are noted in upper and outer quadrants of both breast.

Rest of Both breasts show normal fibro-glandular parenchyma.

No dominant mass /pleomorphic micro calcifications /skin thickening /
Nipple retraction on either side.

No architectural distortion.


No evidence of duct dilatation.

No axillary lymphadenopathy.

IMPRESSION : Fairly well defined soft tissue opacities are noted in upper and outer quadrants of both breasts - BIRADS- II

Advised : USG Breast.

Note: Please bring previous reports on next visit.


Dr. PRAJAKTA SUKHADEVE
DNB RADIOLOGY
Reg. No. 88493

The Test marked with*are not accredited by NABL

Lab Timings (Weekdays) : 7.00 am to 8.30 pm
Sundays & Holidays : 7.00 am to 1.00 pm

Radiologists Timings (Weekdays) : 7.30 am to 1.30 pm
& 5.30 pm to 7.45 pm
Sundays & Holidays : 7.30 am to 9.30 am

PARKLINE DIAGNOSTICS PVT. LTD.

L.G 3, 4 & 5, Bhuvana Towers, Sarojini Devi Road, Secunderabad - 500 003.
Tel. +91 40 2784 5852, 6649 1787, 77995421787, 7093445852, Fax : + 91 40 2784 7864
Email : parklinediagnostics@gmail.com, www.parklinediagnostics.com



NABL Accredited
Certificate No.: MC-2566

TEST REPORT

Name : Ms . CHAKKA KALYANI [SPOUSE]
Age / Gender : 50 Years / Female
Ref.By : Medi Wheel
Req. No : BIL1888543

TID : UMR0746890
Registered on : 19-Mar-2022 07:56 AM
Reported On : 19-Mar-2022 01:07 PM

BIRADS ASSESSMENT CATEGORIES

- 0 - Needs additional imaging.
- 1 - Negative - There is nothing the comment on.
- 2 - Benign finding.
- 3 - Probably benign finding - followup after 3 months suggested.
- 4 - Suspicious abnormality. Biopsy should be considered
[4A - Low suspicion ,4B - Intermediate suspicion, 4C- Moderate concern]
- 5 - Highly suggestive of malignancy.
- 6 - Known biopsy proven malignancy.

The Test marked with*are not accredited by NABL

Lab Timings (Weekdays) : 7.00 am to 8.30 pm
Sundays & Holidays : 7.00 am to 1.00 pm

Radiologists Timings (Weekdays) : 7.30 am to 1.30 pm
& 5.30 pm to 7.45 pm
Sundays & Holidays : 7.30 am to 9.30 am



PARKLINE DIAGNOSTICS PVT. LTD.

L.G. 3, 4 & 5, Bhuvana Towers, Sarojini Devi Road, Secunderabad - 500 003 Tel. +91 40-2784 5852
6649 1787 Fax : +91 40 2784 7864 Email : parklinediagnostics@gmail.com www.parklinediagnostics.com



NABL Accredited
Certificate No. MC-2566

TEST REPORT

Name : Ms . CHAKKA KALYANI [SPOUSE]
Age / Gender : 50 Years / Female
Ref.By : Medi Wheel
Req. No : BIL1888543

TID : UMR0746890
Registered on : 19-Mar-2022 07:56 AM
Reported On : 19-Mar-2022 11:10 AM

X-RAY CHEST PA VIEW

Lung fields are clear.

Cardia is normal.


Hila are normal.

C P angles are free.

Bony cage is normal.

Soft tissues are normal.

IMPRESSION : NORMAL CHEST X-RAY


Dr. D.J. MOHAN
MD DMRD
(Reg No. 8995)
Consultant Radiologist

The Test marked with*are not accredited by NABL

Lab Timings (Weekdays) : 7.00 am to 8.30 pm
Sundays & Holidays : 7.00 am to 1.00 pm

Radiologists Timings (Weekdays) : 7.30 am to 1.30 pm
& 5.30 pm to 7.45 pm
Sundays & Holidays : 7.30 am to 9.30 am

ID: 1888543

19-03-2022 08:24:52 AM

CARDIART

MS.CHAKKA KALYANI

Female 50Years

HR : 53 bpm
P : 106 ms
PR : 149 ms
QRS : 81 ms
QT/QTc : 436/411 ms
P/QRS/T : 34/4/-15 °
RV5/SV1 : 1.125/1.090 mV

Diagnosis Information:
Sinus Bradycardia
Poor R Wave Progression(V2,V4)

NSR
WNL
Dr. NAVEEN KUMAR .C
M.D., D.M.
Consultant Cardiologist
Reg. No. 52291

Report Confirmed by:

REAL TIME ECG REPORT
PATIENT SUMMARY REPORT

KLINE DIAGNOSTICS PVT.LTD

: 1888543
E : MS CHAKKA KA;YANI
/ SEX : 50 / FEMALE

HEIGHT (cm) : 155
WEIGHT (kg) : 78
PROTOCOL : MODIFIED BRUCE

REF. BY : MEDIWHEEL
DONE BY : DR NAVEEN KUMAR C
TECHNICIAN : G.M.SURESH

2022, 14:04:

PREVIOUS HISTORY :

INDICATION :

OBJECT OF TEST : Routine Check Up.

CLINICAL FACTOR : None.

ACTIVITY : Very Active.

REASON FOR INVESTIGATION : ECG

REASON FOR TERMINATION : Dyspnea.

EXERCISE TOLERANCE : Moderate (< 10 METS).

EXERCISE INDUCED ARRHYTHMIAS : No.

ABNORMAL RESPONSE : Normal.

NORMAL RESPONSE : Normal.

IMPRESSION :

COMMENTS : *Intermediate probability of CAD*

Adv - CAG

Dr. NAVEEN KUMAR .C
M.D., D.M.
Consultant Cardiologist
Reg. No. 52291

Confirmed By :

Signature

v/Sec

Tested On 19-03-2022, 14:04:19

BPL DYNATRAC

