

Patient Name : Miss. TERANCHIA C Age : 35 Y/F
UHID : CANN.0000224001 OP Visit No : CANNOPV359534
Conducted By: : Dr. RAKESH P GOPAL Conducted Date : 30-06-2023 13:31
Referred By : SELF

2D-ECHO WITH COLOUR DOPPLER

Dimensions:

Ao (ed)	2.6 CM
LA (es)	2.8 CM
RVID(ed)	1.4 CM
LVID (ed)	3.9 CM
LVID (es)	2.6 CM
IVS (Ed)	0.7/1.2 CM
LVPW (Ed)	0.6/1.0 CM
EF	69.00%
%Fs	39.00%
MITRAL VALVE :	NORMAL
AML	NORMAL
PML	NORMAL
AORTIC VALVE	NORMAL
TRICUSPID VALVE	NORMAL
RIGHT VENTRICLE	NORMAL

Patient Name : Miss. TERANCHIA C Age : 35 Y/F
UHID : CANN.000224001 OP Visit No : CANNOPV359534
Conducted By: : Dr. RAKESH P GOPAL Conducted Date : 30-06-2023 13:31
Referred By : SELF

INTER ATRIAL SEPTUM INTACT

INTER VENTRICULAR SEPTUM INTACT

AORTA NORMAL

RIGHT ATRIUM NORMAL

LEFT ATRIUM NORMAL

Pulmonary Valve NORMAL

PERICARDIUM NORMAL

LEFT VENTRICLE:

NO REGIONAL WALL MOTION ABNORMALITY

NORMAL LEFT VENTRICULAR SYSTOLIC FUNCTION

COLOUR AND DOPPLER STUDIES

E/A-E: 0.8m/sec A: 0.6m/sec

VELOCITY ACROSS THE PULMONIC VALVE 0.9m/sec

VELOCITY ACROSS THE AV 1.2m/sec

TR VELOCITY 0.6m/sec

Patient Name	: Miss. TERANCHIA C	Age	: 35 Y/F
UHID	: CANN.0000224001	OP Visit No	: CANNOPV359534
Conducted By:	: Dr. RAKESH P GOPAL	Conducted Date	: 30-06-2023 13:31
Referred By	: SELF		

IMPRESSION

NORMAL CHAMBER DIMENSION
NO REGIONAL WALL MOTION ABNORMALITY
NORMAL LV SYSTOLIC FUNCTION (EF 69 %)
STRUCTURALLY VALVES ARE NORMAL
TRIVIAL MITRAL REGURGITATION
TRIVIAL TRICUSPID REGURGITATION
NO PAH / CLOT / PE

Rakesh Gopal

Dr. RAKESH P
GOPAL

Patient Name : Miss. TERANCHIA C
UHID : CANN.0000224001
Conducted By: :
Referred By : SELF

Age : 35 Y/F
OP Visit No : CANNOPV359534
Conducted Date :

Patient Name : Miss. TERANCHIA C
UHID : CANN.0000224001
Conducted By :
Referred By : SELF

Age : 35 Y/F
OP Visit No : CANNOPV359534
Conducted Date :

Patient Name : Miss. TERANCHIA C

Age/Gender : 35 Y/F

UHID/MR No. : CANN.0000224001

OP Visit No : CANNOPV359534

Sample Collected on :

Reported on : 29-06-2023 18:28

LRN# : RAD2033717

Specimen :

Ref Doctor : SELF

Emp/Auth/TPA ID : 75729

DEPARTMENT OF RADIOLOGY

ULTRASOUND - WHOLE ABDOMEN

Liver shows uniform echopattern with no evidence of focal or diffuse pathology.
Intra and extra hepatic biliary passages are not dilated.

Gall bladder appears normal with no evidence of calculus.
Wall thickness appear normal.

Pancreas and spleen appear normal.
Spleen measures 6.7 cms.

Portal and splenic veins appear normal.
No evidence of ascites or lymphadenopathy.

Diaphragmatic movements are satisfactory.
There is no evidence of sub diaphragmatic pathology or pleural effusion.

Right kidney measures 10.6 x 4.5 cms.
Left kidney measures 10.8 x 4.2 cms.
Both kidneys show normal echopattern with no evidence of calculi or calyceal dilatation.

Uterus measures 8.3 x 3.0 cms and shows normal endometrial and myometrial echoes.
The endometrial thickness 5.4 mm.
Right ovary measures 2.4 x 1.9 cms.

Patient Name : Miss. TERANCHIA C

Age/Gender : 35 Y/F

Left ovary measures 2.2 x 1.2 cms.

Both ovaries are normal in size and echotexture.

No mass lesion seen in the pelvis.

Bladder is normal in contour.

IMPRESSION:

*NO SIGNIFICANT ABNORMALITY DETECTED.

Dr. PRAVEENA SHEKAR T
MBBS, DMRD, FAGE
Radiology

Patient Name : Miss. TERANCHIA C

Age/Gender : 35 Y/F

UHID/MR No. : CANN.0000224001

OP Visit No : CANNOPV359534

Sample Collected on :

Reported on : 29-06-2023 17:11

LRN# : RAD2033717

Specimen :

Ref Doctor : SELF

Emp/Auth/TPA ID : 75729

DEPARTMENT OF RADIOLOGY

X-RAY CHEST PA

Lung fields are clear.

Cardio thoracic ratio is normal.

Apices, costo and cardiophrenic angles are free.

Cardio vascular shadow and hila show no abnormal feature.

Bony thorax shows no significant abnormality.

Domes of diaphragm are well delineated.

IMPRESSION:

***NO SIGNIFICANT ABNORMALITY DETECTED.**

DR.P.V MITHILA MBBS MD RD

ENT Check up

Teranchia

35/F

29/6/23

Height:	Weight:	BMI:	Waist Circum:
Temp:	Pulse:	Resp:	B.P:

General Examination / Allergies
History

No complaints

o/e - Pharyngitis (granular)

Ear | WNL.
Nose

Inf: GERD



Follow up date:

Doctor Signature & Stamp

Convenient & reliable. Complete diagnostic services for the entire family. All under one roof.

Name: Mrs Tenanchia C
 Occupation:
 Age: 35 Sex: Male Female
 Address:
 Ph:

Date: 29/6/23 Reg. No.: 224001
 Ref. Physician:
 Copies to:

REPORT ON OPHTHALMIC EXAMINATION

History:

Existing glasses user past 7 years.

Present Complaint:

Comfortable with present glasses

ON EXAMINATION:

	RE	LE
Ocular Movements :	<u>Full</u>	<u>Full</u>
Anterior Segment :	<u>Full</u>	
Intra-Ocular-Pressure :		
Visual Acuity: D.V. :	<u>N</u>	<u>N</u>
Without Glass :		
With Glass :	<u>6/12</u>	<u>6/9</u>
N.V. :		
Visual Fields :	<u>N6</u>	<u>N6</u>
Fundus :		
Impression :	<u>Full</u>	<u>Full</u>
Advice :		
Colour Vision :	<u>N</u>	<u>N</u>

 **बैंक ऑफ़ बड़ोदा**
Bank of Baroda

नाम
Name

टेरन्चीया सी
Teranchia C

E.C. No. 178275


जारीकर्ता प्राधिकारी
Issuing Authority


J. Teranchia
एकर के हस्ताक्षर
Signature of Holder

J. Teranchia

CANN- 2244001
OCL- 932283

Fwd: Health Check up Booking Confirmed Request(bobE40903),Package Code-PKG10000317, Beneficiary Code-75729

Teranchia C <teranchia.1411@gmail.com>

Thu 6/29/2023 8:05 AM

To:Annanagar Apolloclinic <annanagar@apolloclinic.com>

----- Forwarded message -----

From: **Mediwheel** <wellness@mediwheel.in>

Date: Mon, 19 Jun, 2023, 18:24

Subject: Health Check up Booking Confirmed Request(bobE40903),Package Code-PKG10000317, Beneficiary Code-75729

To: <teranchia.1411@gmail.com>Cc: <customercare@mediwheel.in>**011-41195959****[Email:wellness@mediwheel.in](mailto:wellness@mediwheel.in)**Dear **MS. C TERANCHIA**,

Please find the confirmation for following request.

Booking Date : 17-06-2023

Package Name : Arcofemi MediWheel Full Body Health Annual Plus Check Female 2D
: ECHO (Metro)

Name of Diagnostic/Hospital : Apollo Medical Centre

Address of Diagnostic/Hospital : 30, F- Block, 2nd Avenue, Anna Nagar East - 600012

Contact Details : 7358392880 // 7305702537

City : Chennai

State : Tamil Nadu

Pincode : 600012

Appointment Date : 29-06-2023

Confirmation Status : Confirmed

Preferred Time : 08:00:AM

Comment : APPOINTMENT TIME 9:00AM

Instructions to undergo Health Check:

1. Please ensure you are on complete fasting for 10-To-12-Hours prior to check.
2. During fasting time do not take any kind of medication, alcohol, cigarettes, tobacco or any other liquids (except Water) in the morning.

3. Bring urine sample in a container if possible (containers are available at the Health Check centre).
4. Please bring all your medical prescriptions and previous health medical records with you.
5. Kindly inform the health check reception in case if you have a history of diabetes and cardiac problems.

For Women:

1. Pregnant Women or those suspecting are advised not to undergo any X-Ray test.
2. It is advisable not to undergo any Health Check during menstrual cycle.

Request you to reach half an hour before the scheduled time.

In case of further assistance, Please reach out to Team Mediwheel.

© 2023-2024, Arcofemi Healthcare Limited.

Personal Details

UHID: 01668FGP6MD0QC7
PatientID: 224001 RMC
Name: MS TERANCHIA C
Age: 35
Gender: Female
Mobile: 1236547890

Pre-Existing Medical Conditions

Symptoms

Vitals

Measurements

HR : 68 BPM
PR: 135 ms
PD: 107 ms
QRS: 79 ms
QRS Axis: 63 deg
QT/QTc: 376/401 ms

Interpretation

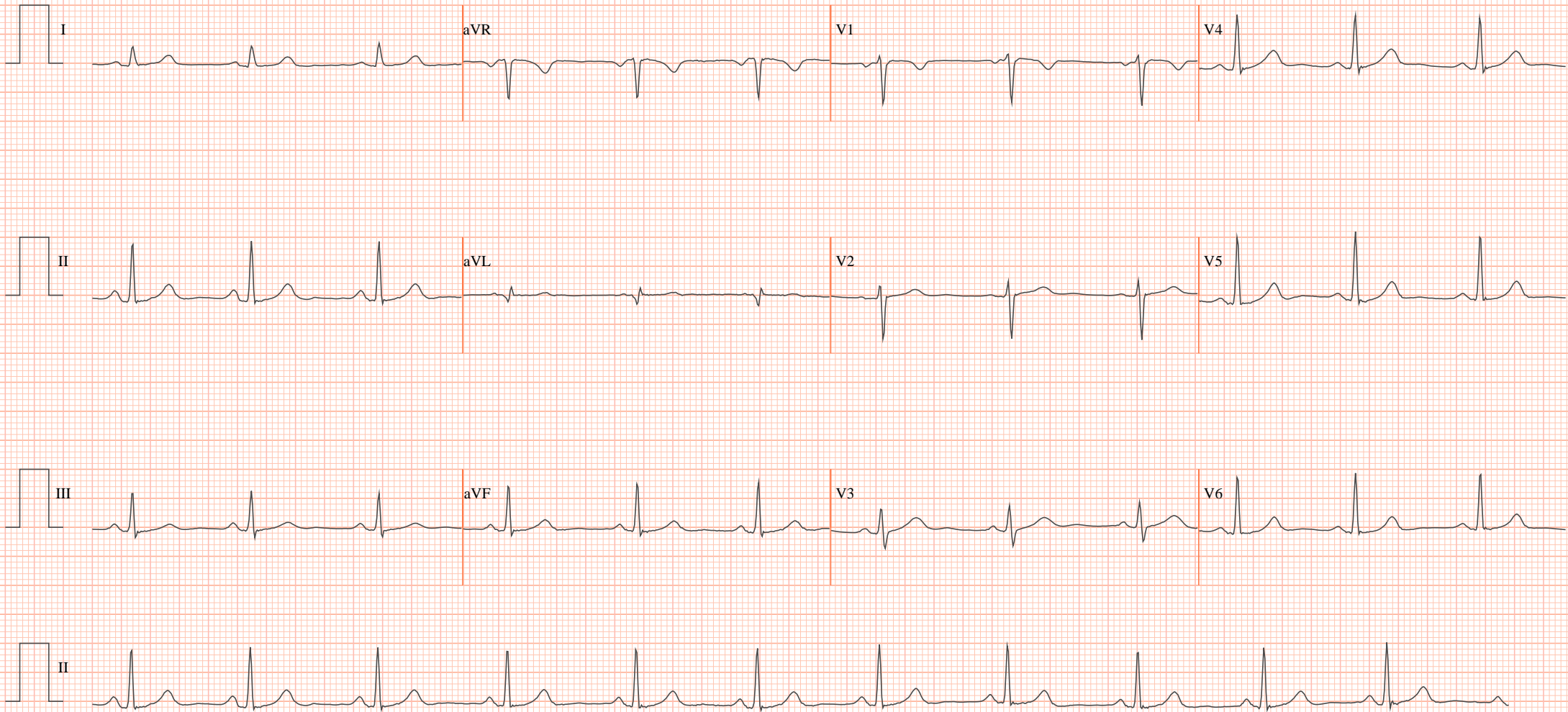
Sinus Rhythm Regular
Normal Axis
No Significant ST-T changes

Authorized by

Yogesh

Dr. Yogesh Kothari
MD, DNB, FESC, FEP
Reg No- KMC 44065

This trace is generated by **KardioScreen**; Cloud-Connected, Portable, Digital, 6-12 Lead Scalable ECG Platform from **IMEDRIX**



Speed: 25 mm/sec F: 0.05 - 40 Hz Limb: 10 mm/mV Chest: 10 mm/mV

Patient Name	: Miss. TERANCHIA C	Age	: 35 Y/F
UHID	: CANN.0000224001	OP Visit No	: CANNOPV359534
Reported By:	: Dr. ANUSHA ARUMUGAM	Conducted Date	: 29-06-2023 14:10
Referred By	: SELF		

ECG REPORT

Observation :-

- 1. Normal Sinus Rhythm.**
- 2. Heart rate is 68 beats per minutes.**

Impression:

NORMAL RESTING ECG.

----- END OF THE REPORT -----

Dr. YOGESH KOTHARI