



Sree Labs

LABS & X-RAY
(A Unit of Vijay Hospital)



NAME : Mr. T MALLIKARJUNA
AGE/SEX : 30/MALE
REF BY : WELLNESS MEDIWHEEL

DATE: 23.10.2021

SEROLOGY

BLOOD GROUP : "B"
RH- TYPING : POSITIVE

Poorana Priya P

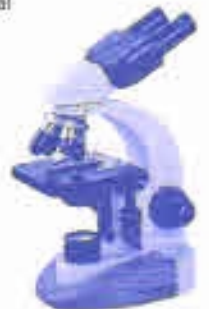DR. P. POORANA PRIYA, MD. (PATH)

PATHOLOGIST



[Signature]
LAB TECHNICIAN

- NOTES :
1. The values are provided as a guidance for medical professionals only.
 2. The values will vary from one laboratory to another.
 3. If there are any changes, new values will be printed below the patient results.
 4. Laboratory values depends on the age sex and time of collecting the samples and may vary accordingly.
 5. Laboratory reports should not be interpreted in isolation. They should always be correlated with clinical findings and other medical.





NAME : Mr. T MALLIKARJUNA

DATE: 23.10.2021

AGE/SEX : 30/MALE

REF BY : WELLNESS MEDIWHEEL

HAEMATOLOGY

HEMOGLOBIN : 13.2 gms % (12.5-16.0)

TOTAL WBC COUNT : 6700 Cells/cumm (4000-11000)

TOTAL RBC COUNT : 5.1 Million cells/cumm (4.0-6.5)

DIFFERENTIAL COUNT

POLYMORPHS : 66% (45-70)

LYMPHOCYTE : 32 % (25-45)

EOSINOPHILS : 02 % (02-06)

P.V : 35 % (35-45)

MCV : 86fl (70-90)

MCH : 30pg (28-45)

MCHC : 27 % (25-35)

PLATELET COUNT : 3.3 lakh cells/cumm (1.5-4.5)

ESR

30MINUTES : 06mm (05-20)

60MINUTES : 12mm (10-20)

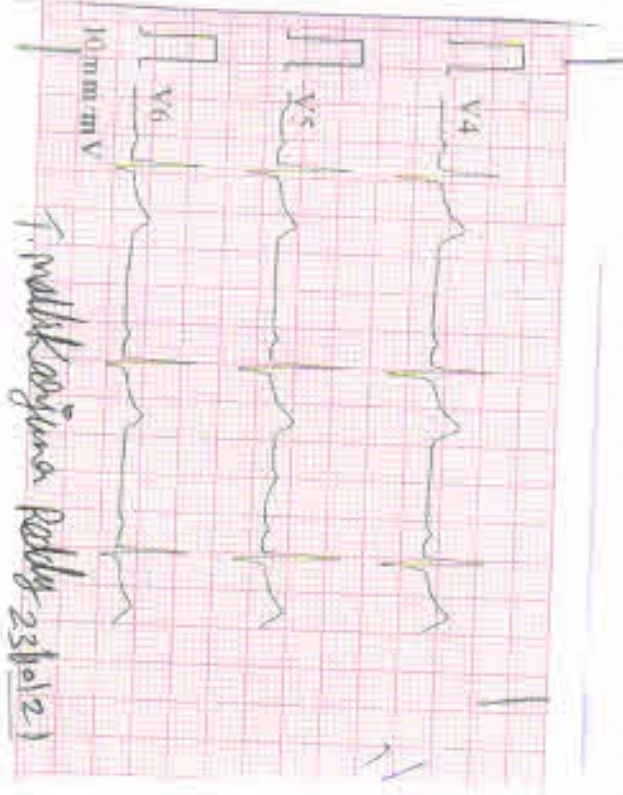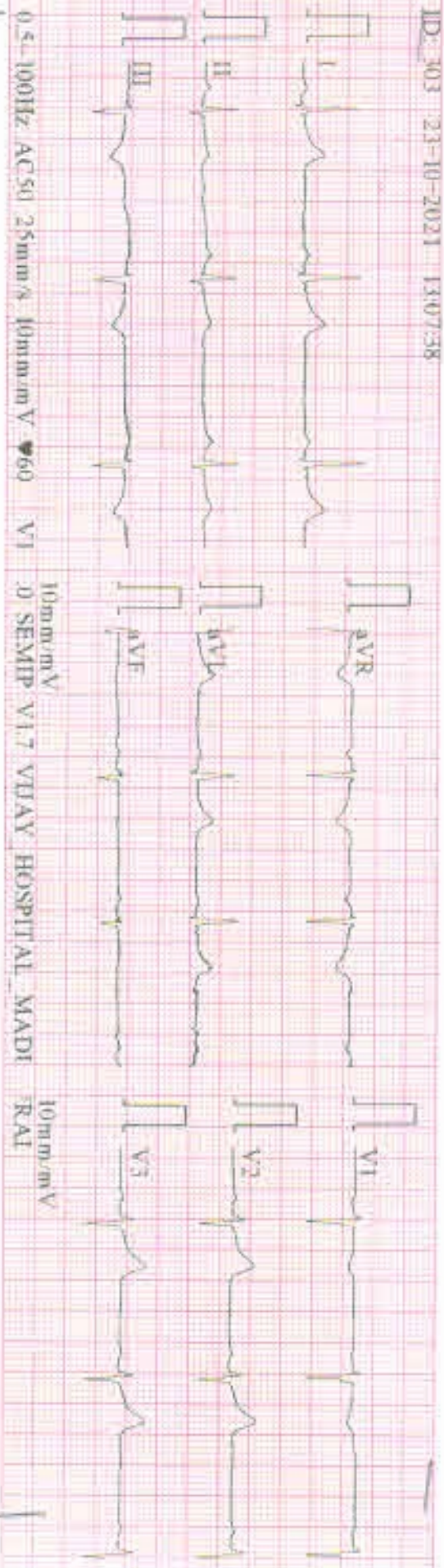
Poorana Priya
DR. P. POORANA PRIYA MD, (PADI)
PATHOLOGIST



LAB TECHNICIAN

- NOTES : 1. The values are provided as a guidance for medical professionals only.
2. Laboratory reports should not be interpreted in isolation. They should always be correlated with clinical findings and other medical.





Mallikarjuna Reddy 23/10/21

normal

Dr. N. CHAKRAVARTHI
 MBBS, PG-CC (Cardiology)
 J. No: 60286
 J. No: 50074B
 VEYPATTY, TPK
 JRAI - 625 005

name: Mallikarjuna Reddy
 age: 30
 Date: 23/10/2021
 ECG



ಭಾರತ ಸರ್ಕಾರ
GOVERNMENT OF INDIA





ಆ ವ್ಯಕ್ತಿಯವರ ರಿಡಿ
 T. Madhukumar Reddy
 ಸಂಖ್ಯೆ / Number : ಆ ವ್ಯಕ್ತಿಯ ರಿಡಿ
 ಸಂಖ್ಯೆ ಕಾರ್ಡ್ / Card no. (Date : 1991)
 ಸಂಖ್ಯೆ / No.

5412 5535 1862

ಆಧಾರ್ - ತ್ರೀನಾಮಾನ್ಯನ ಆಧಿಕಾರ

T. Madhukumar Reddy
23/10/21





NAME : Mr. T MALLIKARJUNA

DATE: 23.10.2021

AGE/SEX : 30/MALE

REF BY : WELLNESS MEDIWHEEL

RFT

SR. URIC ACID : 4.1 mg/dl (3.5-5.0)

BLOOD UREA NITROGEN : 11 mg/dl (9-20)

SR. CREATININE : 0.7 mg/dl (0.6-1.3)

BUN/CRE RATIO : 15.7 : 1

LIVER FUNCTION TEST

SR.BILIRUBIN (Total) : 0.8 mg/dl (0.3-1.0)

SR.BILIRUBIN (Direct) : 0.5 mg/dl (0.2-0.8)

SR.BILIRUBIN (Indirect) : 0.3 mg/dl (0.2-0.6)

SR.SGOT : 20 IU/L (5.0-40)

SR.SGPT : 25 IU/L (5.0-40)

AST/ALT RATIO : 0.8 : 1

SR.ALKALINE PHOSPHATASE : 7* IU/L (60-170)

SR.TOTAL PROTEIN : 7.1 g/dl (6.0-8.0)

SR.ALBUMIN : 4.9 g/dl (3.7-5.3)

SR.GLOBULIN : 2.3 g/dl (2.3-3.6)

ALB/GLO RATIO : 2.1 : 1

Poorana Priya P

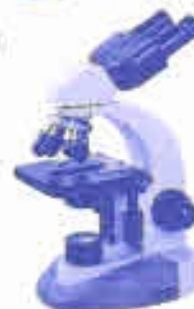DR. P. POORANA PRIYA, MD. (PATH)

PATHOLOGIST



LAB TECHNICIAN

NOTES : 1. The values are provided as a guidance for medical professionals only.
2. Laboratory reports should not be interpreted in isolation. They should always be correlated with clinical





NAME : Mr. T MALLIKARJUNA
AGE/SEX : 30/MALE
REF BY : WELLNESS MEDIWHEEL

DATE: 23.10.2021

URINE ANALYSIS

COLOUR : Straw Yellow
TRANSPARENCY : Crystal Clear
ALBUMIN : Nil
SUGAR : Nil
PH : 6.0
SPECIFIC GRAVITY : 1.012
KETONE : Negative
UROBILINOGEN : Negative
BILE SALT : Negative
BILEPIGMENT : Negative
DEPOSIT : 2-4 Pus Cells / Hpf
: 3-6 Epithelial Cells / Hpf
: No RBC'S & No Cast & No Crystals are seen

Pooja Priya P

DR P POORANA PRIYA MD (PATH)

PATHOLOGIST



LAB TECHNICIAN

- NOTES : 1. The values are provided as a guidance for medical professionals only.
2. Laboratory reports should not be interpreted in isolation. They should always be correlated with clinical findings and other medical.





Sree Labs

LABS & X-RAY

(A Unit of Vijay Hospital)

NAME : Mr. T MALLIKARJUNA

DATE: 23.10.2021

AGE/SEX : 30/MALE

REF BY : WELLNESS MEDIWHEEL

SUGAR (F) : 99 mg/dl (70-110) *

SUGAR (PP) : 129 mg/dl (100-140)

LIPIDS PROFILE

T.CHOLESTEROL : 179 mg/dl (150.0-220.0)

TRIGLYCERIDES : 136 mg/dl (200)

HDL : 52 mg/dl (54)

LDL : 100 mg/dl (160)

VLDL : 27 mg/dl (44)

LDL/HDL RATIO : 1.9 : 1

CHO/HDL RATIO : 3.4 : 1

HBA1C:

TEST VALUE : 4.8 %

REFERENCE VALUE : 4 - 6 %

6.0 -7.0 : GOOD CONTROL

7.1 -8.0 : FAIR CONTROL

8.1 -9.0 : POOR CONTROL

MORE THAN 10 : VERY POOR CONTROL


DR P POORANA PRIYA MD.,(PATH)
PATHOLOGIST



LAB TECHNICIAN

NOTES : 1. The values are provided as a guidance for medical professionals only.
2. Laboratory reports should not be interpreted in isolation. They should always be correlated with clinical





NAME : Mr. T MALLIKARJUNA (30Yrs/M)

DATE: 23.10.2021

REF BY : WELLNESS MEDIWHEEL

TEST ASKED : T3-T4-TSH

TEST NAME	TECHNOLOGY	VALUE	UNITS	REF. RANGE
TOTAL TRIIODOTHYRONINE (T3)	C.L.I.A	102.7	ng/dl	60-200
TOTAL THYROXINE (T4)	C.L.I.A	7.9	ug/dl	4.5-12.0
THYROID STIMULATING HORMONE (TSH)	C.L.I.A	2.19	uiU/ml	0.30-5.5

Comments : SUGGESTING THYRONORMALCY

Please correlate with clinical conditions.

Technology :

T3 – COMPETITIVE CHEMI LUMINESCENT IMMUNO ASSAY

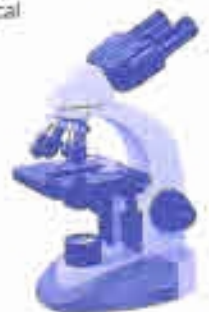T4 – COMPETITIVE CHEMI LUMINESCENT IMMUNO ASSAY

TSH – ULTRA SENSITIVE SANDWICH CHEMI LUMINESCENT IMMUNO ASSAY



LAB TECHNICIAN

- NOTES :
1. The values are provided as a guidance for medical professionals only.
 2. The values will vary from one laboratory to another.
 3. If there are any changes, new values will be printed below the patient results.
 4. Laboratory values depends on the age sex and time of collecting the samples and may vary accordingly.
 5. Laboratory reports should not be interpreted in isolation. They should always be correlated with clinical findings and other medical.



Name : Mr. T MALLIKARJUNA (30/M)

DATE : 23.10.2021

Ref By Dr : WELLNESS MEDIWHEEL

ABDOMEN & PELVIS

LIVER : Liver appears normal in size and echotexture. No focal lesion seen. Portal vein appears normal in diameter. Intra hepatic and extra hepatic biliary passages are not dilated.

GALL BLADDER : GB is Normal in size, with no evidence of calculus. Wall thickness appears Normal.

SPLEEN AND PANCREAS : Spleen and pancreas appear normal.

FREE FLUID : There is no evidence of ascites or para aortic lymphadenopathy. There is no evidence of pleural effusion on both sides.

KIDNEYS : Right Kidney measures 9.5 X 4.6 cms.

Left Kidney measures 10.0 X 5.1 cms.

Both Kidneys appear normal in size.

There is no evidence of calculus.

BLADDER : Urinary bladder is Normal.

RIF : There is no evidence of formed mass lesion or thickened appendix.

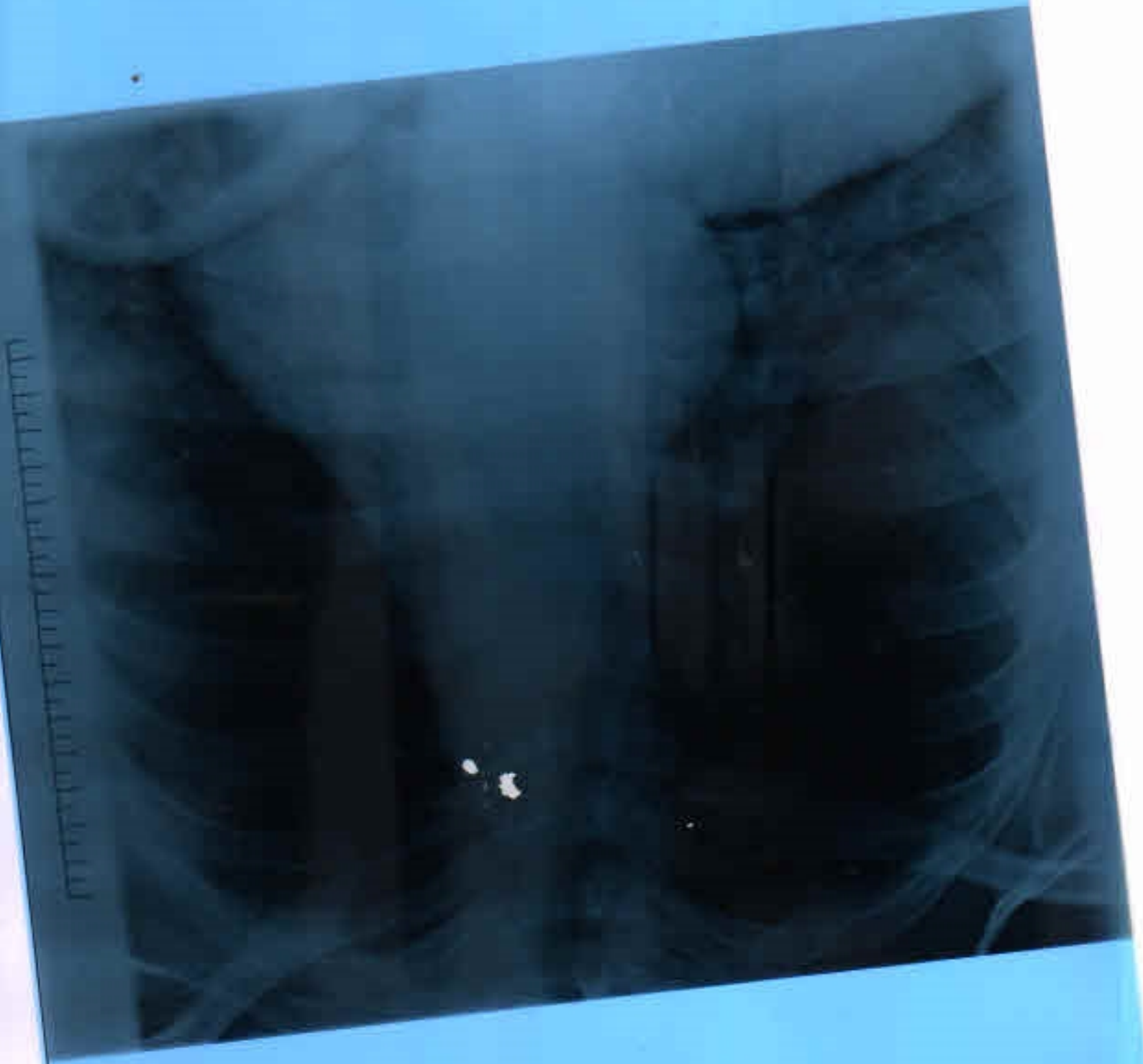
IMPRESSION :

ULTRA SOUND OF ABDOMEN & PELVIS REVEALS NORMAL STUDY



Dr. VIJAYCHAKRAVARTHY
MBBS, PG DD (Diabetology)
Reg. No: 60286
L.I.C. No: 500748
95, HARVEYPATTY, TPK,
MADURAI - 625 005

10/23/2021 10:37 AM



CHEST PA

VIJAY NURSING HOME, MADURAI
MALLIGARJUNA
10/23/2021
Acq Tm: 10:37 AM