

medlinwael.

"DR. PLUS HEALTH CARE CENTRE"
NATHAN HEIGHTS, B-WING,
42, MUMBAI CENTRAL (EAST)

[Signature]
DR. HARI CHHABLANI
M.B.B.S. (RESPIRATORY MEDICINE) PGDIPHM, PGDMLS,
FELLOW INTENSIVE CARE
MMC REG. NO. - 91702

(37/M)

2

REPUBLIC OF INDIA
CENTRAL BUREAU OF MOTOR VEHICLES LICENSING

DRIVER'S STATE MOTOR DRIVING LICENCE

DL No MH01 20030010222 DOB: 25-02-2003
Valid Till: 24-02-2023 (NT)

FORM 7
RULE 16 (2)

AUTHORISATION TO DRIVE FOLLOWING CLASS
OF VEHICLES THROUGHOUT INDIA

COV	DOI
MCWG	25-02-2003
LMV	25-02-2003

DOB: 02-10-1984 BG: B+

Name: SWANAND NARAVANE
S/DAY of AJIT NARAVANE
Add: BLOCK NO-5, MEHTA COTTAGE
PLOT NO-41, DR M B RAUT RD,
SHIVAJI PARK DADAR MUMBAI
PIN: 400028

Signature & ID of Issuing Authority: *[Signature]* MH01 2014209

[Signature]
Signature/Thumb Impression of Holder

meelinwael.

DR. PLUS HEALTHCARE CENTRE
NATHAN HEIGHTS, B-WING,
42, MUMBAI CENTRAL (EAST)

[Signature]
DR. HARI CHHABLANI
M.B.B.S. (RESPIRATORY MEDICINE) PGDIPHI, PGDMLS,
FELLOW INTENSIVE CARE
MMC REG. NO. - 91702

(37/M)


REPUBLIC OF INDIA
MAHARASHTRA STATE MOTOR DRIVING LICENCE

DL No. MH01 20030010222 DOI: 25-02-2003
Valid Till: 24-02-2023 (NT)

DLD 02-01-2014

FORM 7
RULE 16 (2)

AUTHORISATION TO DRIVE FOLLOWING CLASS
OF VEHICLES THROUGHOUT INDIA



COV	DOI
MCWG	25-02-2003
LMV	25-02-2003



DOB: 02-10-1984 BG: B+

Name: SWANAND NARAVANE
S/DAY of AJIT NARAVANE
Add: BLOCK NO-5, MEHTA COTTAGE
PLOT NO-41, DR M B RAUT RD,
SHIVAJI PARK DADAR MUMBAI
PIN: 400028

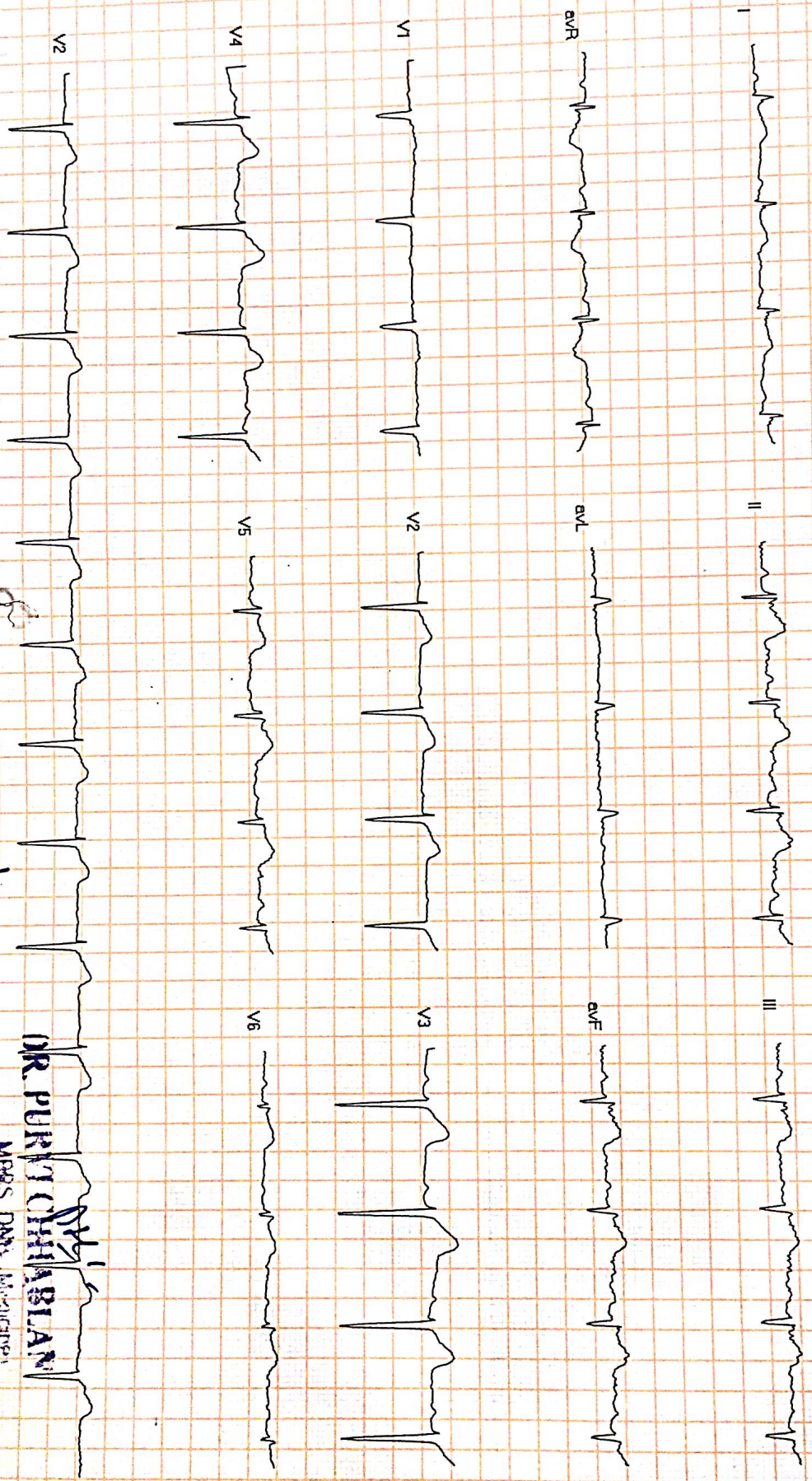
Signature & ID of Issuing Authority: *[Signature]* MH01 2014209

[Signature]
Signature/Thumb Impression of Holder

ECG

DR PLUS HEALTHCARE CENTRE - MUMBAI CENTRAL

201 / SWANAND NARAYANE / 37 Yrs / M
Heart Rate : 82 bpm / Tested On : 27-Mar-22 09:13:53 / HF 0.05 Hz - LF 100 Hz / Notch 50 Hz / Sn 1.00 Cm/mV / Sw 25 mm/s



DR PURY CHIMBIAN
MBBS, DNB, MRCGP
Consultant Physician And Intensivist
Reported By: Dr. P. D. CHIMBIAN



Dr-Plus Healthcare Centre

NATHANI HEIGHTS, B-Wing, Shop No. 42, Ground Floor, Opp. Mumbai Central Station (East), Mumbai - 400 008.

Full Name

SWANAND NARAVANE

37/M

27/03/2022

Life to be assured:

	Type of Test	Actual Reading	Normal Range
1	Fasting Blood Sugar	89.4	70-100 mg%
2	PPBS	116.8	110 TO 140 mg%
3	Total Cholesterol	170.3	120-200 mg%
4	VERY LOW DENSITY LEVEL(VLDL)	20.2	10-30 mg/dl
5	High Density Lipid (HDL)	49.0	40-60 mg%
6	Low Density Lipid (LDL)	99.1	<u>Upto 150</u>
7	S. Triglycerides	111.5	50-150 mg%
8	CHOL/HDL	3.4	Upto 5
9	HDL/LDL	0.4	
10	S. Creatinine	0.7	0.5-1.2 mg%
11	Blood Urea Nitrogen (BUN)	13.5	7-21 mg%
12	BUN/CREAT RATIO	19	
13	S. Proteins	7.0	6.0-7.9 mg%
14	(a) Albumin	4.0	3.5-5.5 mg%
15	(b) Globulin	3.0	2.0-3.5 mg%
16	A/G RATIO	1.3	
17	S. Bilirubin	0.9	0.3-1.3mg%
18	(a) Direct	0.6	0.0-0.8 mg%
19	(b) Indirect	0.3	0.0-0.5 mg%
20	SGOT (AST)	25.6	05-34 IU
21	SGPT (ALT)	34.5	05-40 IU
22	GGTP (GGT)	39.6	05-50 IU
23	SGOT/SGPT	0.7	
24	HBA1C	5.54	UPTO 6.5
25	S. Alkaline Phosphatase	96	30-115 IU
26	T3	125.3	80-180ng/dl
27	T4	6.84	4.6-12 ug/dl
28	TSH	3.01	0.4-4.0 mIU/L
29	SERUM URIC ACID	5.45	2.5-7.2mg/dl
30	URINE SUGAR PP	ABSENT	
31	URINE SUGAR FASTING	ABSENT	
32	BLOOD GROUP	" B POSITIVE "	

DR. RAKESH PATKAR
M.D. N.B. (Pathology)
Reg. No. 2013/05/1660



Dr-Plus Healthcare Centre

NATHANI HEIGHTS, B-Wing, Shop No. 42, Ground Floor, Opp. Mumbai Central Station (East), Mumbai - 400 008.

SWANAND NARAVANE

37/M

DATE:27/03/2022

Full Name of life to be assured:

HAEMOGRAM

Normal Range

1.	Red Blood Cell Count	4.8	[M : 4.5 - 5.6 / F : 3.5 - 5.5/cu.mm]
2.	Hb%	15.3	[M: 14-18 / F : 11-16%]
3.	Hematocrit	47.6	[M : 40-53 / F : 30-47 %]
4.	Indices:		
(a)	MCV(Mean Corpuscular Volume)	87.6	[79-101 cu.mi.]
(b)	MCH(Mean Corpuscular Hb)	31.2	[27-32 pg]
(c)	MCHC(Mean Corpuscular Hb Concentration)	34.5	[32-38%]
5.	Morphology		
	Macrocytes :	--	Microcytes: -- Hypochromia: --
	Piokilocytosis:	--	Anisocytosis: --
6.	Target cells:	--	
	Spherocytes:	--	Elliptocytes: --
7.	TOTALW.B.C.Count	6,800	{4000-11000/cu.mm}
Differential Count0			
a)	Neutrophils :	60	[45 -70%] c) Eosinophils: 01 [01 - 06%]
b)	Lymphocytes :	30	[20 - 45%] d) Monocytes: 06 [00 - 08%]
e)	Basophils :	00	[00 - 01%]
8.	Platelets :3.02	1.5-4.5 Lacks/cu.mm	
9.	Erythrocyte Sedimentation Rate:12	20 mm at end of 1 hour	Method : Westergrens

ROUTINE URINE EXAMINATION (RUA)

1. Physical Examination:

(i)	Colour:	YELLOW	(ii)	Sediment:	CLEAR
(iii)	Transparency:	ABSENT	(iv)	Reaction:	ACIDIC
(v)	Specific gravity	1.015			

2. Chemical Examination:

(i)	Protein :	ABSENT	(ii)	Sugar:	ABSENT
(iii)	Bile salt:	ABSENT	(iv)	Bile pigment:	ABSENT

3. Microscopic Examination:

(i)	Red Blood Cells:	ABSENT	(ii)	Epithelial Cells:	ABSENT
(iii)	Crystals:	ABSENT	(iv)	Pus Cells:	04 TO 05/HPF
(v)	Casts:	ABSENT	(vi)	Deposits:	ABSENT
(vii)	Bacteria's :	ABSENT			

DR. FRESH PATKAR
M.D. N.B. (Paediatrics)
Reg. No. 2019/05/1660



Patient's Name : SWANAND NARAVANE

Report Date : 27/03/2022

Referred By : SELF

Age : 37 Years

Sex : MALE

X- RAY CHEST

BOTH THE LUNG FIELED ARE CLEAR.

THE HILAR SHADOWS APPEAR NORMAL.

THE COSTO-PHRENIC ANGELS ARE CLEAR.

THE CARDIAC SHADOWS APPEAR NORMAL.

THE TRACHEAL IS CENTRAL IN POSITION.

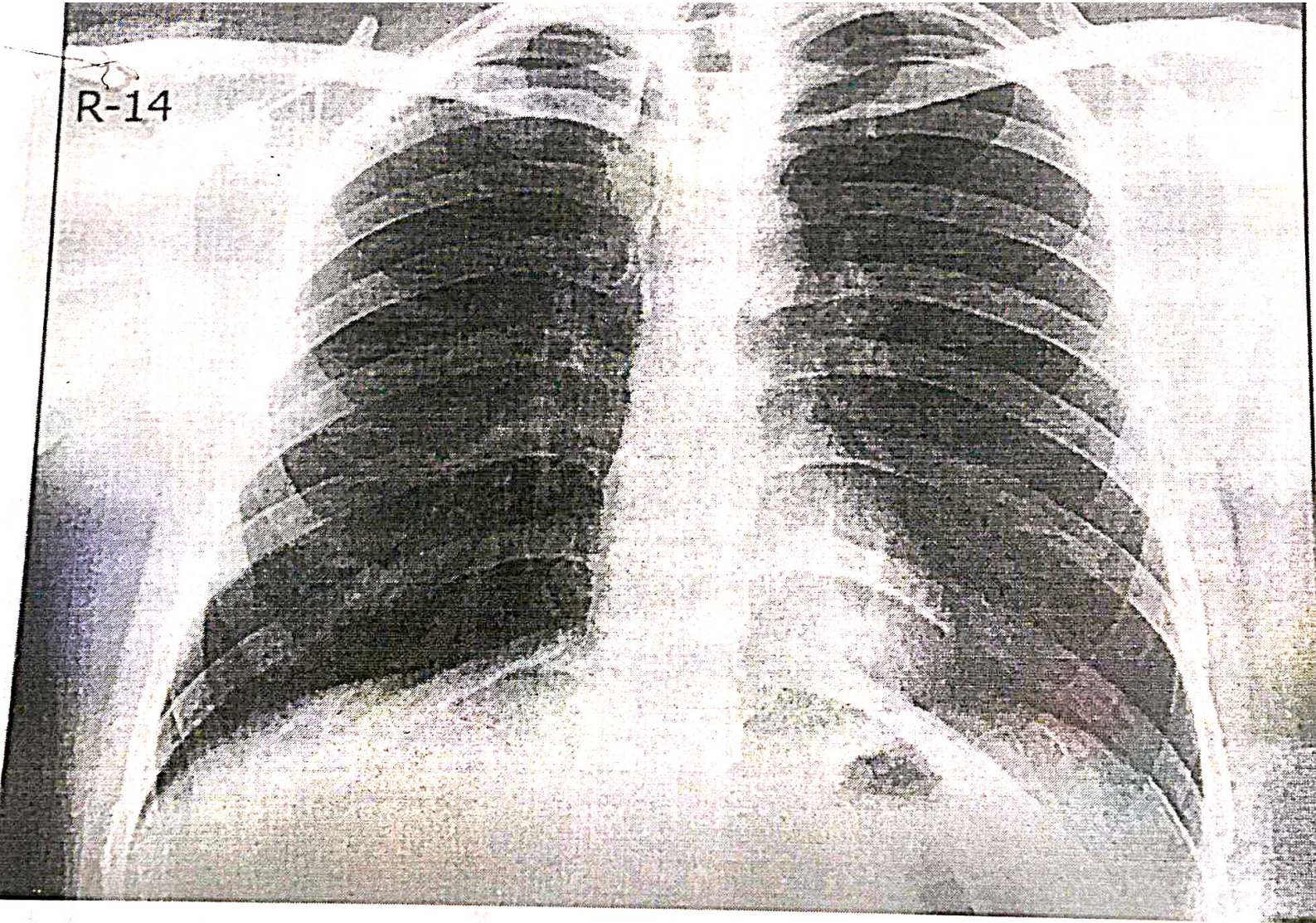
THE BONY CAGE APPEARS NORMAL.


DR. A. J. MAZUMDAR

MD. DMRE, MDRD

DR. PLUS HEALTHCARE CENTRE
NATHANI HEIGHTS', B-WING,
42, MUMBAI CENTRAL (EAST)

R-14





Dr-Plus Healthcare Centre

NATHANI HEIGHTS, B-Wing, Shop No. 42, Ground Floor, Opp. Mumbai Central Station (East), Mumbai - 400 008.

Patient Name	:	SWANAND NARAVANE	Sex:	MALE
Doctor's Name	:	DR. H. CHHABLANI	Age:	37 YEARS
Date	:	27/03/2022		

ULTRASONOGRAPHY OF THE ABDOMEN AND THE PELVIS:

The relevant sonographic findings include the following:

HEPATOBIILIARY APPARATUS

The liver is normal in size and echogenicity. No obvious focal parenchymal lesion is seen. Extrahepatic biliary radicals are not dilated.

The portal vein and the common bile duct are normal.

GALL BLADDER

The gall bladder is adequately distended. The wall thickness is normal.

No echogenic contents are noted in its lumen. There is no pericholecystic collection noted.

PANCREAS

The pancreas shows normal echogenicity and size. No focal or diffuse lesions are noted.

No evidence of calcification is noted.

SPLEEN

The spleen appears normal in size and echogenicity. No focal or diffuse lesions are noted.

No evidence of calcification is noted.

KIDNEYS

Right Kidney measure: 10.1 x 4.5 cm, Left kidney measure: 10.5 x 4.2 cm

Both the kidneys appear normal in size, shape and echogenicity. Both the pelvicalyceal system is normal and both corticomedullary differentiations are well maintained. There is no obvious focal or diffuse lesion noted. No evidence of any calculus seen in either kidney.

PROSTATE

The Prostate appears normal and shows a normal echogenicity.

URINARY BLADDER

The urinary bladder shows anechoic contents. Its wall thickness appears normal.

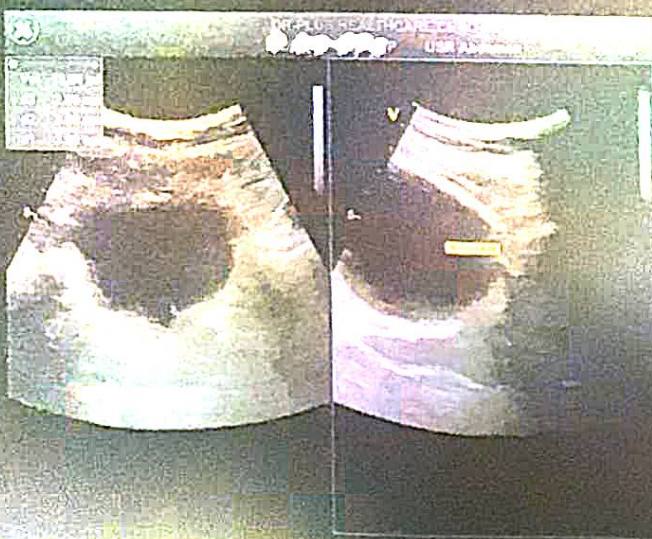
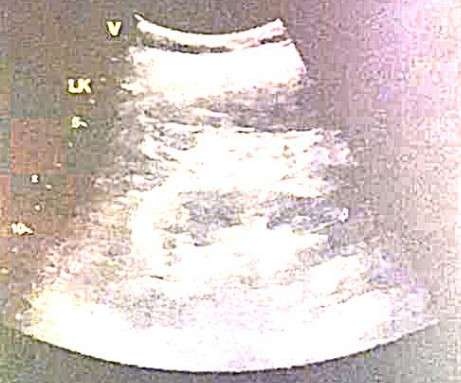
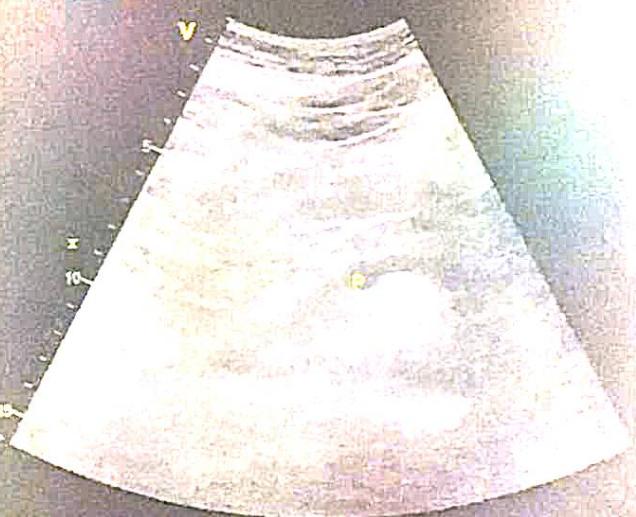
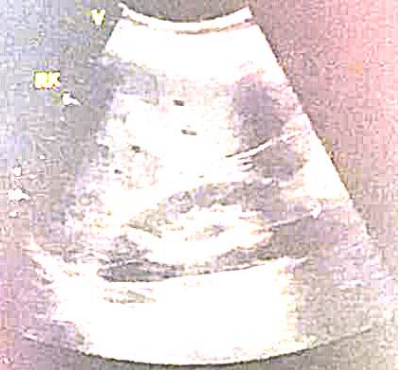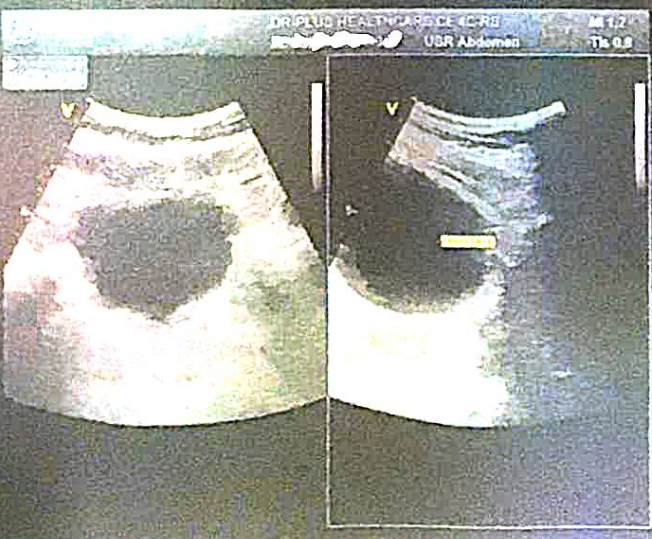
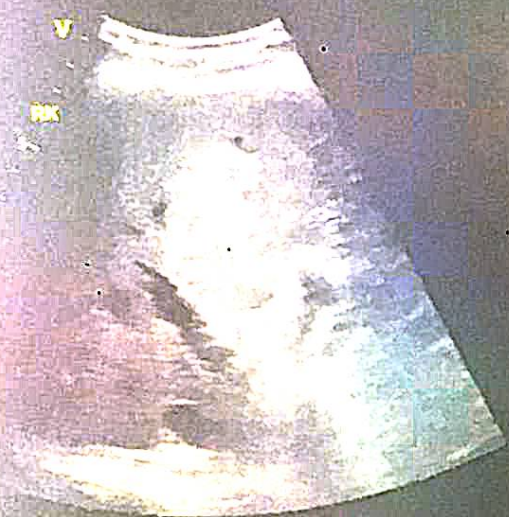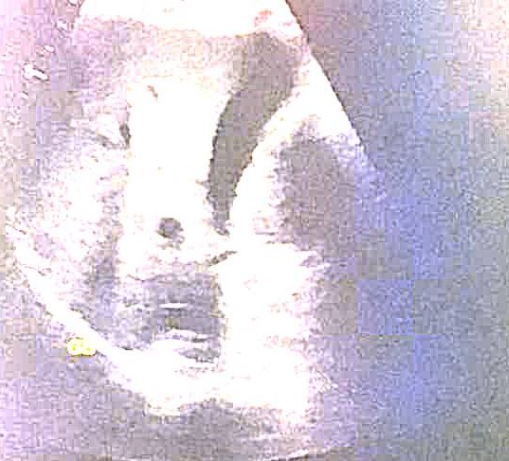No evidence of calcification is seen.

There is no obvious evidence of abdominal or pelvic lymphadenopathy or ascites noted.

IMPRESSION: No significant abnormality is detected.

Dr. Parag Jhaveri
MBBS (BOM), DMRE (BOM)
Radio-Sonologist

DR. PLUS HEALTHCARE CENTRE
NATHANI HEIGHTS, B-WING,
42, MUMBAI CENTRAL (EAST)





NAME : SWANAND NARAVANE

37/M

DATE:27/03/2022

REF BY : DR. HARI CHHABLANI

2D-ECHO. AND COLOR DOPPLER REPORT

- NORMAL CARDIAC VALVES WITH TRIVIAL TR.
- NORMAL CARDIAC CHAMBERS
- NO E/O REGIONAL WALL MOTION ABNORMALITY. WITH NORMAL LVEF OF 62 %.
- NO E/O PULMONARY HYPERTENSION .PASP 30 mmHg by TR jet.
- NO E/O LEFT VENTRICULAR HYPERTROPHY.
- NO E/O DIASTOLIC DYSFUNCTION.
- NO E/O PERICARDIAL EFFUSION.
- NO E/O INTRACARDIAC CLOT OR VEGETATION
- INTACT IAS / IVS

- CONVENTIONL DOPPLER :

E TO A RATIO IS MORE THAN ONE IN LV INFLOW.

THERE IS NO GRADIENT ACROSS AV, LVOT OR RVOT

PASP FROM TR JET IS 30 mm OF Hg.

- COLOUR DOPPLER:

TRIVIAL TR

EF Slope	99	mm/sec		
Opening Amplitude	16			
Posterior leaflet				
E.P.S.S	02	mm		
Mitral valve prolapse				
Vegetations				
TRICUSPID VALVE	OBSERVED	NORMAL VALUES		
PULMONARY VALVE	OBSERVED	NORMAL VALUES		
EF Slope				
'A' Wave				
Midsystolic notch				
Flutter				
Other Findings				
AORTIC VALVE	OBSERVED	NORMAL VALUES		
Cuspal opening	16	mm		
Closure line	Central			
Eccentricity index	1			
Other Findings				
DIMENSIONS	OBSERVED	NORMAL VALUES		
1. Lvd (Diastolic)	45	26-52		
2. Lvd (Systolic)	30	24-42mm		
3. RVD (Diastolic)	19	7-23mm		
4. IVST (Diastolic)	09	6-11mm		
5. IVST (Systolic)	15			
6. LVPWT (Diastolic)	08	6-11mm		
7. LVPWT (Systolic)	16			
8. Aortic root	25	22-37mm		
9. left Atrium	35	19-40mm		
	STRUCTURE	REGURG GRADING	VELOCITY m/sec	STENOSIS GRADIENT mm/Hg
			Max mean	Peak mean
MITRAL VALVE	NORMAL	0/3	/	/
TRICUSPID VALVE	NORMAL	TRIVIAL	/	/
PULMONARY VALVE	NORMAL	0/4	/	/
AORTIC VALVE	NORMAL	0/4	/	/

DR.P.H.CHHABLANI
M.B.B.S, DNB (MEDICINE)
CONSULTANT PHYSICIAN AND CARDIOLOGIST.

DR. PURVI CHHABLANI
M.B.B.S, DNB (Medicine)
Consultant Physician And Intensive
Reg No. 77005



Dr. Hari Chhablani

Cardiometabolic Physician & Intensivist
M.B.B.S., F.C.C.P. (RESP. MED.), PGDHHM,
PGDMLS, FELLOW INTENSIVE CARE MED.

ATTACHED TO: Wockhardt Hospital, Saifee Hospital, Apollo Spectra Hospital

PHYSICIAN REPORT
NATHANI HEIGHTS, B-Wing, Shop No. 42, Ground Floor, Opp. Mumbai Central Station (East),
Mumbai - 400 008. • Cell : 98206 46163 • E : drharichhablani@gmail.com

DATE : 27/03/2022

NAME : SWANAND NARAVANE

37/M

PRESENTING COMPLAINS : K/C/O DEPRESSION SINCE TWO YEARS.

TREATMENT : PAXIDEP CR-25, OLET 1.25 .

PAST HISTORY :NIL

FAMILY HISTORY: NOT SIGNIFICANT

HABITS : EX- SMOKER.

DENTAL EXAMINATION: NAD

HT:- 177 CM. WT.- 106 Kg. BMI. 33

P: 82/MIN ., REGULAR

BP: 110/70

RS: CLEAR CVS: S1,S2 REGULAR

PA: SOFT

CNS: CLINICALLY NAD

EYE EXAMINATION : NEAR VISION -B/E N6 , DISTANT VISION -BE-- 6/6 , COLOUR VISION - NORMAL

LABS: ATTACHED

ECG: WNL

CHEST X-RAY :WNL

SONOGRAPHY : ATTACHED

2-D-ECHO : WNL

ADVICE :REFER TO PSYCHIATRIST .


DR.HARI CHHABLANI

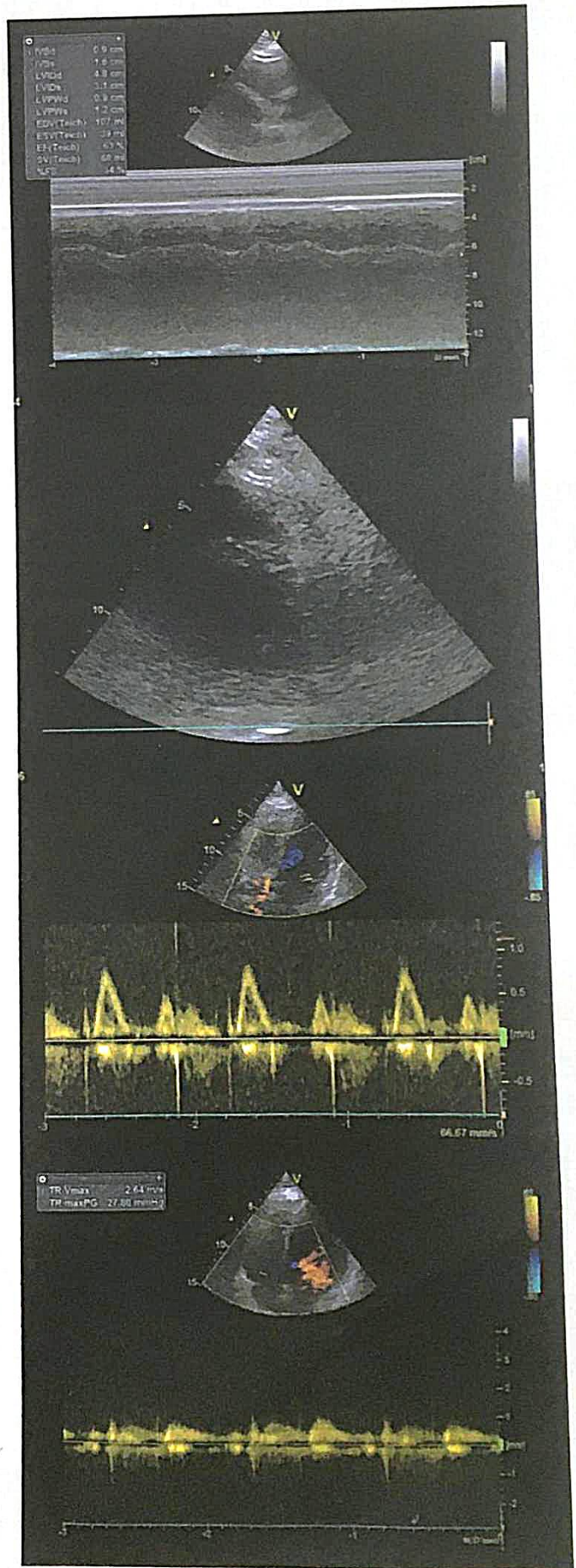
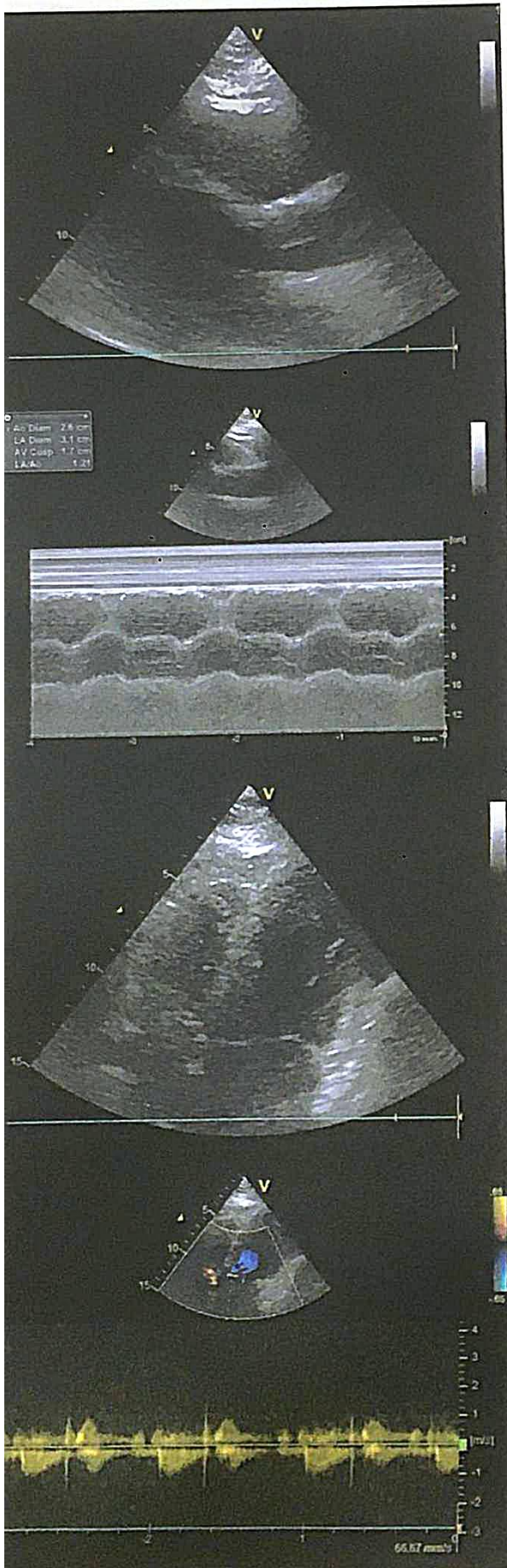
DR. HARI CHHABLANI
M.B.B.S. (RESP. MEDICINE) PGDHHM, PGDMLS
FELLOW INTENSIVE CARE
MMC REG. NO. - 91702



me **SWANAND NARAVANE**

Sex **Male**

e 37

Date **27/03/2022**





Mumbai, Maharashtra, India
 Shop No 65, Nathani Heights, Marzban Parsi Colony, Dalal Estate, Mumbai Central, Mumbai, Maharashtra 400008, India
 Lat 18.968745°
 Long 72.819962°
 27/03/22 10:44 AM