

HEALTH CHECKUP REPORT

Patient Name: PRIYANKA MADDALA

Age/Gender: 28/F

Reg. No: 380061

Package: BOB

DATE: 18/08/2022

COMPLAINTS (IF ANY):

- Lymphadenitis may 2022 completed
- Back pain
- Occasionally Gastric

STORY OF HEALTH STATUS: No

PRESENT MEDICATIONS: No

HYPERSENSITIVITY TO ANY DRUG: No

PERSONAL HISTORY:

- | | | | | | |
|---------------|---|----------|-----------------------------|---|-----|
| - Bowel | : | Regular | Diet | : | Veg |
| - Micturition | : | Normal | Habits | : | No |
| - Sleep | : | Adequate | Physical Activity/Exercise: | : | No |
| - Appetite | : | Adequate | | | |

HISTORY OF ILLNESS (WITH PAST MEDICATIONS): No

FAMILY HISTORY: No

VITAL SIGNS:

- | | | | |
|------------|---------|---------|------------|
| - Height : | 145cms | Pulse : | 98/min. |
| - Weight : | 62.5Kgs | B.P.: | 118/68mmHg |

PHYSICIAN CONSULTATION:

1) Clinical Impression

- Microphonic anemia

2) Recommendations

- 1 hours walk daily
- Healthy life style

OPHTHALMO CONSULTATION:

RE

Best corrected visual acuity

6/6

LE

6/6

(Dr. Rashmi chovatia)

DENTAL CONSULTATION:

Adv:

- Cleaning

(Dr. Parvin Chandarana)

Please take regular medicine as prescribed by the Doctor. (If given)

FOR OFFICE USE ONLY

FOR OFFICE USE ONLY

Patient ID 316039
 Patient Name Mrs. PRIYANKA SANTHOSHA MADDALA
 Gender/Age Female/28
 Ref Doctor

Dt: 18/08/2022

Rx	Drug Name	Generic Name	Morning	Afternoon	Evening	Night	Duration
Tab.	OROFER - XT oral	FE ASCORBATE + FOLIC ACID	0	1	0	0	3 Month(s)

Dr. Foram Pampaniya



Priyanka

→ 2848 / P/L, LSCS.
 for screening.

Dr. Mona Naman Shah

M.B.B.S, M.D. (Obstetrics & Gynecology)

Fellowship Gynec Oncology (CMC Vellore)

Reg. No. : G-20407

Mobile : +91-98795 05063

Email : mona.shah@cimshospital.org

16/8/22

FOR OPD CONSULTATION ONLY

→ M/H 29/7/22
 LMP - Reg / MF / PL
 NOT on any
 contraception.

→ O/E NO pain / LN

B/L Breast (W)

- P/A Soft

PLS Gx
 vagina / (W)

Plv uter
 (W)
 FA FU

→ FH
 No malignancy

- H/O TB
 Completed AKI
 (5/22)

→ USA - A / (W)

B/L mammo. Plan

- Plv C
 PAP Repeat

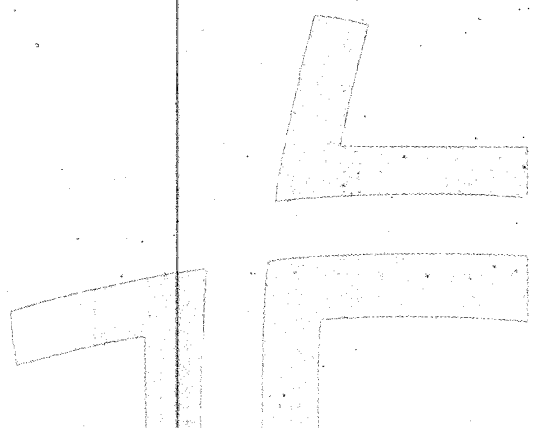
(PTO)

Reg. No : CIMS/A/2022/380061	VisitNo : HC/180822/8 [HCV]
Patient Name : Mrs. PRIYANKA SANTHOSHA MADDALA	Age(Y-M-D)/Sex : 28 Y 2 M 25 D. / Female
Referring Doctor : Dr. CIMS DOCTOR	Doctor
Ward/Room :	Bed

ORD/180822/430 Lab No : 2022124705 LSN : 909753 (Whole Blood) Sample Quality : Normal
 Collection Time : 18/08/2022 9:47:01 Arrival : 18/08/2022 9:58:42 Validation Time : 18/08/2022 12:00:43PM

	<u>Result</u>	<u>Unit</u>	<u>Reference Range</u>
HbA1c (Glycosylated Haemoglobin)			
TEST			
HbA1c (Glyoco Hb) (Immuno Turbidimetric)	5.58	%	4.8-5.9% Normal 5.9-7.0% Good diabetic control 7.0-10.0% Fair diabetic control >10.0% Poor diabetic control
Mean Plasma Glucose	121.3	mg/dL	80 - 140 mg/dL

FOR PATHOLOGY REPORTS ONLY




Dr. Shreya Patel
MD(Path)
Consultant Pathologist

Dr. Manisha Shah
MD (Path & Bact)
Consultant Pathologist
Reg. No. : G-15496

Dr. Jitendra Nayak
MD (Path)
Consultant Pathologist
Reg. No. : G-14786

Print By : ankita.raibut





Reg. No : CIMS/A/2022/380061	VisitNo : HC/180822/8 [HCV]
Patient Name : Mrs. PRIYANKA SANTHOSHA MADDALA	Age(Y-M-D)/Sex : 28 Y 2 M 25 D. / Female
Referring Doctor : Dr. CIMS DOCTOR	Doctor :
Ward/Room :	Bed :

ORD/180822/430 Lab No : 2022124705 LSN : 909753 (Whole Blood) Sample Quality : Normal
 Collection Time : 18/08/2022 9:47:01 Arrival : 18/08/2022 9:58:42 Validation Time: 18/08/2022 12:00:43PM

FOR PATHOLOGY REPORTS ON

15

Sh

Dr. Shreya Patel
MD(Path)
Consultant Pathologist

Dr. Manisha Shah
MD (Path & Bact)
Consultant Pathologist
Reg. No. : G-15496

Dr. Jitendra Nayak
MD (Path)
Consultant Pathologist
Reg. No. : G-14786

Print By: ankita.raiput




Reg. No : CIMS/A/2022/380061	Visit No : HC/180822/8 [HCV]
Patient Name : Mrs. PRIYANKA SANTHOSHA MADDALA	Age(Y-M-D)/Sex : 28 Y 2 M 25 D. / Female
Referring Doctor : Dr. CIMS DOCTOR	Doctor
Ward/Room :	Bed

ORD/180822/430 Lab No : 2022124705 LSN : 909753 (Whole Blood) Sample Quality : Normal
 Collection Time : 18/08/2022 9:47:01 Arrival : 18/08/2022 9:58:42 Validation Time: 18/08/2022 12:49:32PM

	Result	Unit	Reference Range
CBC With ESR			
TOTAL COUNT			
Hemoglobin <i>(SLS Hemoglobin Detection method)</i>	10.3	g/dl	12.5 - 16.0 g/dl
Total RBC Count <i>(Hydro Dynamic Focusing Method)</i>	4.58	mill/Cmm	4.2 - 5.4 mill/Cmm
HCT <i>(Hydro Dynamic Focusing Method)</i>	33.8	%	37 - 47 %
Total WBC Count <i>(Flow Cytometry)</i>	10290	/Cmm	4000 - 10500 /Cmm
Platelet Count <i>(Hydro Dynamic Focusing Method)</i>	404000	/Cmm	150000 - 450000 /Cmm
DIFFERENTIAL COUNT (by Flow Cytometry)			
Polymorphs	61	%	40 - 70 %
Lymphocytes	32	%	22 - 45 %
Eosinophils	02	%	01 - 04 %
Monocytes	05	%	01 - 06 %
Basophils	00	%	00 - 01 %
Immature Granulocytes	00	%	0 - 2 %
Smear Study	RBCs shows Anisocytosis(+), Microcytosis(+), Hypochromia(+). Platelets are adequate in number. Malarial Parasites are not seen. No Premature cells are seen.		
BLOOD INDICES (by Calculated Method)			
M.C.V	73.8	fl	78 - 100 fl
M.C.H	22.5	pg	27 - 31 pg
M.C.H.C.	30.5	gm/dl	32 - 36 gm/dl
RDW-CV	15.6	%	11.5 - 14.0 %

ESR (Red Cell Aggregation)



Kazumi Gondalia

**Dr. Kazumi Gondalia
M.D. (Path)
Consultant Pathologist
Reg. No. : G-21729**

Dr. Manisha Shah
MD (Path & Bact)
Consultant Pathologist
Reg. No. : G-15496

Dr. Jitendra Nayak
MD (Path)
Consultant Pathologist
Reg. No. : G-14786

Print By : ankita.raibut





Reg. No : CIMS/A/2022/380061	VisitNo : HC/180822/8 [HCV]
Patient Name : Mrs. PRIYANKA SANTHOSHA MADDALA	Age(Y-M-D)/Sex : 28 Y 2 M 25 D. / Female
Referring Doctor : Dr. CIMS DOCTOR	Doctor
Ward/Room :	Bed

ORD/180822/430 Lab No : 2022124705 LSN : 909753 (Whole Blood) Sample Quality : Normal
 Collection Time : 18/08/2022 9:47:01 Arrival : 18/08/2022 9:58:42 Validation Time: 18/08/2022 12:49:32PM

FOR PATHOLOGY REPORTS ONLY

After One Hour 47 mm 0 - 12 mm

Blood Group Rh
 ABO "B"
 Rh POSITIVE

*** END OF REPORT ***

L
R

Kazumi Gondalia

**Dr. Kazumi Gondalia
 M.D. (Path)
 Consultant Pathologist
 Reg. No. : G-21729**

Dr. Manisha Shah
 MD (Path & Bact)
 Consultant Pathologist
 Reg. No. : G-15496

Dr. Jitendra Nayak
 MD (Path)
 Consultant Pathologist
 Reg. No. : G-14786

Print By : ankita.raibout





**Marengo CIMS
Hospital**

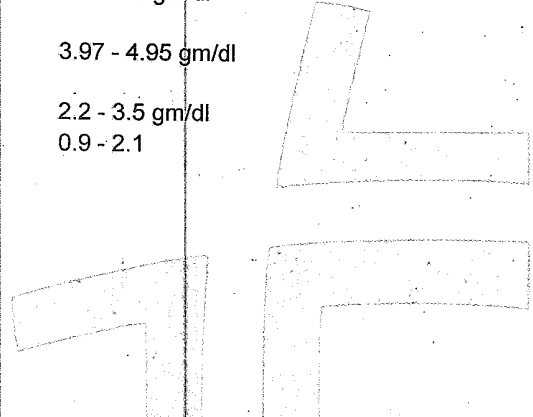
cims.org

Rég. No : CIMS/A/2022/380061	VisitNo : HC/180822/8 [HCV]
Patient Name : Mrs. PRIYANKA SANTHOSHA MADDALA	Age(Y-M-D)/Sex : 28 Y 2 M 25 D. / Female
Referring Doctor : Dr. CIMS DOCTOR	Doctor :
Ward/Room :	Bed :

ORD/180822/430 Lab No : 2022124706 LSN : 909753 (SERUM)	Sample Quality : Normal
Collection Time : 18/08/2022 9:47:01 Arrival : 18/08/2022 9:58:42	Validation Time : 18/08/2022 11:19:23AM

Liver Function Test

	Result	Unit	Reference Range
Alkaline Phosphatase (PNPP, AMP Buffer Method, Colorimetric)	82.6	U/L	35 - 104 U/L
Billirubin			
Total Billirubin (Diazospecial Iazonium Iron with Blank)	0.21	mg/dL	0.0 - 1.0 mg/dL
Direct Billirubin (Diazospecial Iazonium Iron with Blank)	0.09	mg/dL	0.0 - 0.2 mg/dL
Indirect Billirubin (Calculated from Total and Direct Billirubin)	0.12	mg/dL	0.0 - 0.8 mg/dL
SGPT (ALT) (IFCC without pyridoxal phosphate)	11.1	U/L	0 - 33 U/L
SGOT (AST) (IFCC without pyridoxal 5 phosphate)	14.7	U/L	0 - 32 U/L
Total Protein			
Total Proteins (Biuret Method)	8.33	gm/dl	6.4 - 8.3 gm/dl
Albumin (Bromocresol Green Colorimetric)	4.69	gm/dl	3.97 - 4.95 gm/dl
Globulin	3.64	gm/dl	2.2 - 3.5 gm/dl
A/G Ratio	1.29		0.9 - 2.1



Sh

Dr. Shreya Patel
MD(Path)
Consultant Pathologist

FOR PATHOLOGY REPORTS

Dr. Manisha Shah
MD (Path & Bact)
Consultant Pathologist
Reg. No. : G-15496

Dr. Jitendra Nayak
MD (Path)
Consultant Pathologist
Reg. No. : G-14786

Print By : ankita.raiput





**Marengo CIMS
Hospital**

cims.org

Reg. No : CIMS/A/2022/380061	VisitNo : HC/180822/8 [HCV]
Patient Name : Mrs. PRIYANKA SANTHOSHA MADDALA	Age(Y-M-D)/Sex : 28 Y 2 M 25 D. / Female
Referring Doctor : Dr. CIMS DOCTOR	Doctor :
Ward/Room :	Bed :

ORD/180822/430 Lab No : 2022124706 LSN : 909753 (SERUM) Sample Quality : Normal
 Collection Time : 18/08/2022 9:47:01 Arrival : 18/08/2022 9:58:42 Validation Time : 18/08/2022 11:19:22AM

FOR PATHOLOGY REPORTS ONLINE

	Result	Unit	Reference Range
Creatinine (Buffered Jaffe Reaction Kinetic Compensated)	0.7	mg/dL	0.5 - 0.9 mg/dL
Estimated GFR	117.11	mL/min/1.73m ²	72 - 110 mL/min/1.73m ²
Fasting Glucose (Hexokinase)	97	mg/dL	70 - 100 mg/dL
Thyroid Function Test			
TOTAL T3 (T3) * (Electrochemiluminescence Assay)	0.91	ng/ml	0.846 - 2.02 ng/ml
TOTAL T4 (T4) * (Electrochemiluminescence Assay)	4.55	µgm/dl	5.13 - 14.06 µgm/dl
TSH (Electrochemiluminescence Assay)	2.1	µIU/ml	0.27- 4.20 µIU/ml
Uric Acid (Uricase Colorimetric Enzymatic)	4.27	mg/dL	2.4 - 5.7 mg/dL

*** END OF REPORT ***

L
T

Dr. Shreya Patel
MD(Path)
Consultant Pathologist

Dr. Manisha Shah
MD (Path & Bact)
Consultant Pathologist
Reg. No. : G-15496

Dr. Jitendra Nayak
MD (Path)
Consultant Pathologist
Reg. No. : G-14786

Print By : ankita.raiput





**Marengo CIMS
Hospital**

cims.org

Reg. No : CIMS/A/2022/380061	VisitNo : HC/180822/8 [HCV]
Patient Name : Mrs. PRIYANKA SANTHOSHA MADDALA	Age(Y-M-D)/Sex : 28 Y 2 M 25 D. / Female
Referring Doctor : Dr. CIMS DOCTOR	Doctor :
Ward/Room :	Bed :


ORD/180822/430 Lab No : 2022124707 LSN : 909753 (SERUM) Sample Quality : Normal
 Collection Time : 18/08/2022 9:47:01 Arrival : 18/08/2022 9:58:42 Validation Time : 18/08/2022 11:21:14AM

FOR PATHOLOGY REPORTS ONLY

	<u>Result</u>	<u>Unit</u>	<u>Reference Range</u>
BUN * (Ureas with UV)	7.4	mg/dL	6 - 20 mg/dL

*** END OF REPORT ***

15


 Dr. Shreya Patel
 MD(Path)
 Consultant Pathologist

Dr. Manisha Shah
 MD (Path & Bact)
 Consultant Pathologist
 Reg. No. : G-15496

Dr. Jitendra Nayak
 MD (Path)
 Consultant Pathologist
 Reg. No. : G-14786

Print By : ankita rainut

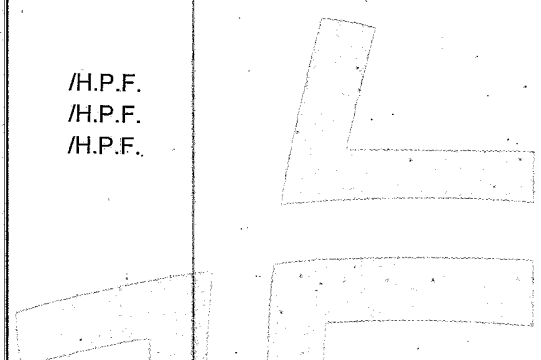




Reg. No : CIMS/A/2022/380061	VisitNo : HC/180822/8 [HCV]
Patient Name : Mrs. PRIYANKA SANTHOSHA MADDALA	Age(Y-M-D)/Sex : 28 Y 2 M 25 D. / Female
Referring Doctor : Dr. CIMS DOCTOR	Doctor
Ward/Room :	Bed

ORD/180822/430 Lab No : 2022124765 LSN : 909753 (Urine) Sample Quality : Normal
 Collection Time : 18/08/2022 11:00:18 Arrival : 18/08/2022 11:17:18 Validation Time : 18/08/2022 12:00:32PM

	Result	Unit	Reference Range
Urine R & M			
PHYSICAL EXAMINATION			
Quantity	20 cc		
Colour	Pale Yellow		
Transperancy	Clear		
Reaction	5.0		
(QDS-10 Strip)			
Sp. Gravity	1.020		1.005 - 1.035
(QDS-10 Strip)			
CHEMICAL EXAMINATION			
U. Albumin	Nil		
(QDS-10 Strip/Manual)			
U. Glucose	Nil		
(QDS-10 Strip/Manual)			
U. Acetone	Absent		
(QDS-10 Strip/Manual)			
BS/BP	Absent		
(QDS-10 Strip/Manual)			
MICROSCOPIC EXAMINATION			
Pus Cell	Occasional	/H.P.F.	/H.P.F.
Red Blood Cell	Nil	/H.P.F.	/H.P.F.
Epithelial Cell	1-2	/H.P.F.	/H.P.F.
Cast	Not Seen		
Crystals	Not Seen		
amorphous	Absent		
monilia	Absent		
*** END OF REPORT ***			



Sh

Dr. Shreya Patel
MD(Path)
Consultant Pathologist

FOR PATHOLOGY REPORTS ONLY

Dr. Manisha Shah
MD (Path & Bact)
Consultant Pathologist
Reg. No. : G-15496

Dr. Jitendra Nayak
MD (Path)
Consultant Pathologist
Reg. No. : G-14786

Print By : ankita rainut






Reg. No : CIMS/A/2022/380061	VisitNo : HC/180822/8 [HCV]
Patient Name : Mrs. PRIYANKA SANTHOSHA MADDALA	Age(Y-M-D)/Sex : 28 Y 2 M 25 D. / Female
Referring Doctor : Dr. CIMS DOCTOR	Doctor :
Ward/Room :	Bed :

ORD/180822/430 Lab No : 2022124706 LSN : 909753 (SERUM) Sample Quality : Normal
 Collection : 18/08/2022 9:47:01AM Arrival: 18/08/2022 10:12:41 Validation Time: 18/08/2022 11:15:21

<u>Lipid Profile (With Direct LDL)</u>	<u>Result</u>	<u>Unit</u>	<u>Reference Range</u>
Cholesterol (Enzymatic/Colorimetric, Cholesterol Oxidas, Esterase, Peroxidase Gen. 2)	: 147.5	mg/dL	Less than 160 mg/dl Excellent Less than 200 mg/dl Desirable 200-239 mg/dl Borderline High 240 mg/dl & over High
Triglyceride (Enzymatic Colorimetric without Glycerol Blank without Serum Blank)	: 77.9	mg/dL	Less than 150 mg/dl Normal 150 - 199 mg/dl Borderline High 200-499 mg/dl High 500 mg/dl or greater Very High
H.L Cholesterol (Direct Mearuse Homogenous Technique Modified Enzymatic Colorimetric Gen. 3)	: 44.5	mg/dL	Less than 40 mg/dl Low 60 mg/dl or above Excellent
L.D.L Cholesterol (DIRECT) (Homogenous Enzymatic colorimetric Assay)	: 98.4	mg/dL	Less than 80 mg/dl Excellent Less than 100 mg/dl Optimal 100 - 129 mg/dl Near or above optimal 130 - 159 mg/dl Borderline High 160 - 189 mg/dl High 190 mg/dl & above Very High
VLDL Cholesterol (Calculated)	: 15.58	mg/dL	15 - 30 mg%
Cholesterol/HDL Ratio (Calculated)	: 3.31		Normal upto 4.5
LDL/HDL Ratio (Calculated)	: 2.21		Less than 3.5

Remarks :


Dr. Shreya Patel
 MD(Path)
 Consultant Pathologist

FOR PATHOLOGY REPORTS






Reg. No : CIMS/A/2022/380061	VisitNo : HC/180822/8 [HCV]
Patient Name : Mrs. PRIYANKA SANTHOSHA MADDALA	Age(Y-M-D)/Sex : 28 Y 2 M 25 D. / Female
Referring Doctor : Dr. CIMS DOCTOR	Doctor :
Ward/Room :	Bed :

ORD/180822/430 Lab No: 2022124706 LSN :909753 (SERUM) Sample Quality : Normal
 Collection : 18/08/2022 9:47:01AM Arrival: 18/08/2022 10:12:41 Validation Time 18/08/2022 11:15:21

*** END OF REPORT ***

FOR PATHOLOGY REPORTS ONLY

430


Dr. Shreya Patel
 MD(Path)
 Consultant Pathologist

Dr. Manisha Shah
 MD (Path & Bact)
 Consultant Pathologist
 Reg. No. : G-15496

Dr. Jitendra Nayak
 MD (Path)
 Print By: ankita.rajput
 Consultant Pathologist
 Reg. No. : G-14786

Print Date/Time: 18/08/2022 1:23:59PM

Page 2 of 2





MARENGO ASIA NETWORK HOSPITAL



Certificate No. MC-3949



www.cims.org



CIMS Hospital

Name : Mrs. PRIYANKA
SANTHOSHA MADDALA
Reg No : CIMS/A/2022/380061
DoB /Sex: 24/05/1994 / Female

ECHO Report

Patient Details

Patient ID 316039
Name Mrs. PRIYANKA SANTHOSHA MADDALA
Age 28 Years
Gender Female
Blood Group
Referral Doctor

Dt : 18/08/2022

ECHO Identification Detail

Doctor Incharge Dr. MILAN CHAG

Clinical Status Of Patient

ECHO Code RP

Finding Description

1. Normal LV size and contractility, No LVH, No RWMA, No LV-clot, 2D-LVEF: 60%.
2. Normal sized LA, RA, RV, PA and aorta, Normal RV systolic function.
3. All cardiac valves are structurally normal.
4. Trivial MR, Trivial TR, Trivial PR, No AR.
5. Normal LV diastolic function.
6. No PAH.
7. Normal pericardium.
8. No coarctation of aorta.

Dr. MILAN CHAG

FOR ECHO / TMT REPORTS ONLY

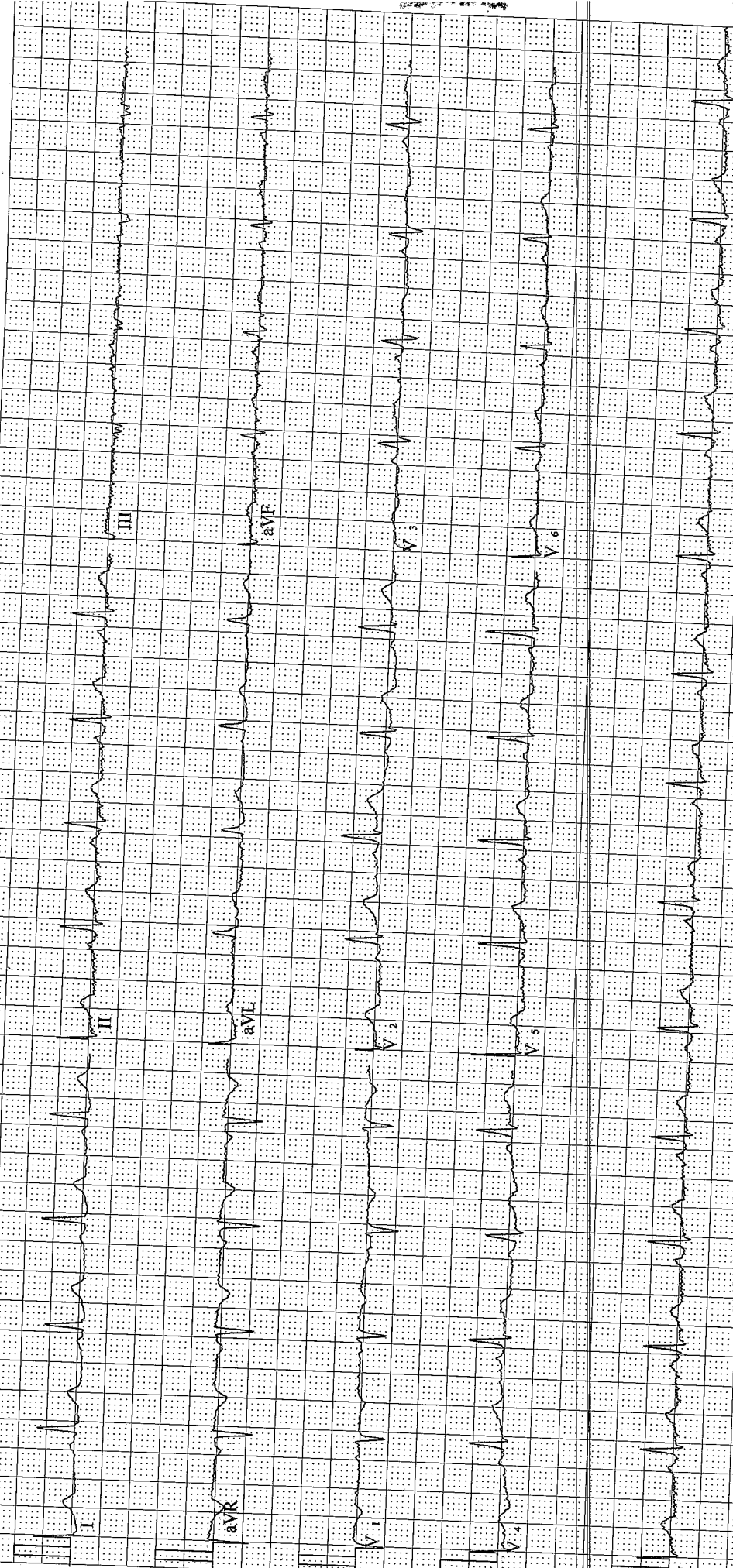
Name : Mrs. PRIYANKA MADDALA

Sex : Female

Age : 28

Date : 8-18-2022

10mm/mV 25mm/s



Frequency :	1000 Hz	PR Interval :	101 ms
Sample Time :	16 s	QT Interval :	388 ms
Heart Rate :	78 bpm	QTc Interval :	442 ms
P Duration :	75 ms	P Axis :	45.1°
QRS Duration :	103 ms	QRS Axis :	14.8°
T Duration :	255 ms	T Axis :	38.7°

Encounter No :
Name : Mrs. PRIYANKA
 SANTHOSHA MADDALA
Reg No : CIMS/A/2022/380061
DoB /Sex : 24/05/1994 / Female

NSR (02/02)

Physician Signature:

Patient's Name :PRIYANKA S MADDALA
Reg. No. (IP/OP):HC-380061
Referred By Dr. :CIMS

Age, Sex :28Y/F
Date :18/08/2022

USG OF ABDOMEN & PELVIS

LIVER: Liver is enlarged with increased parenchymal echogenicity. Right lobe measured 16.7cm in craniocaudal length. No evidence of focal SOL or dilatation of IHBR seen. Porta hepatis appear normal.

GALLBLADDER: Gallbladder appeared normal. No calculus or mass lesion seen.

PANCREAS: Visualised pancreas appeared normal in size and echotexture. No focal lesion, mass or pancreatitis.

SPLEEN: Spleen appears normal in size and echotexture.

PARAAORTIC REGION: Aorta grossly appeared normal. No paraaortic lymphnodes seen.

KIDNEYS: Both kidneys appear normal in size, shape and in position. Cortex and collecting system of both kidneys appeared normal. No evidence of calculus or obstructive uropathy on either side. Right kidney: 96x36mm. Left kidney: 90x43mm.

URINARY BLADDER: Bladder appeared normal. No calculus or mass lesion is seen.

UTERUS: Uterus appears normal in size and measures 74x50x35mm. Uterus shows homogenous endometrial and myometrial echotexture. Endometrial thickness appears normal and measures 4mm. No fibroid or GS seen.

OVARIES: Both ovaries appear normal. No adnexal mass lesion seen on either side.

No evidence of free fluid or collection is seen in peritoneal spaces.
Normal small bowel peristalsis noted.

COMMENTS: Appearance suggests,

- Mild hepatomegaly with fatty changes (Grade-I).

Kindly correlate clinically.

DR KIRTAN SHAH M.D., RADIODIAG. CONS. RADIOLOGIST	DR DEEPA SHAH M.D., D.M.R.E CONS. RADIOLOGIST	DR UMA MEHTA D.M.R.D. F.R.C.R CONS. RADIOLOGIST	DR NIMISH SHARMA D.M.R.D. (D.N.B.) CONS. RADIOLOGIST	DR RAVINA CHAUHAN M.D. RADIODIAG. CONS. RADIOLOGIST	DR YASH PATEL M.D., D.N.B. CONS. RADIOLOGIST
---	---	---	--	---	--

Note: This is only a radiological impression and not the final diagnosis. All diagnostic modalities have their own limitations. Therefore radiological modality report should be interpreted in correlation with clinical and pathological findings.



FOR RADIOLOGY REPORTS ONLY

Patient's Name :PRIYANKA S MADDALA
Reg. No. (IP/OP):HC-380061
Referred By Dr. :CIMS

Age, Sex :28Y/F
Date :18/08/2022

Plain Skiagram of Chest PA Standing View:
(Serial No-4401)

Both lung fields appear normal.

No evidence of collapse or consolidation in either lung field.
No evidence of pleural effusion or pneumothorax is seen on either side.

Mediastinal shadow appears normal.

Heart size and aorta appear normal.

Domes of diaphragm appear normal.

Bones under view appears normal.

Kindly correlate clinically.

DR KIRTAN SHAH M.D. RADIODIAG. CONS. RADIOLOGIST	DR DEEPA SHAH M.D., D.M.R.E CONS. RADIOLOGIST	DR UMA MEHTA D.M.R.D. F.R.C.R CONS. RADIOLOGIST	DR NIMISH SHARMA D.M.R.D. (D.N.B.) CONS. RADIOLOGIST	DR RAVINA CHAUHAN M.D. RADIODIAG. CONS. RADIOLOGIST	DR YASH PATEL M.D., D.N.B. CONS. RADIOLOGIST
--	---	---	--	---	--

Note: This is only a radiological impression and not the final diagnosis. All diagnostic modalities have their own limitations. Therefore radiological modality report should be interpreted in correlation with clinical and pathological findings.



FOR RADIOLOGY REPORTS ONLY