

DEPARTMENT OF RADIOLOGY X-RAY OF CHEST (PA) VIEW

MR. NO- FSIN.0000000

SEX-FEMALE

NAME: -SUKLA BISWAS

EXAMINATION DATE-01/02/2022

AGE-41 YRS

REPORT DATE-01/02/2022

REF DR:- SELF

FINDINGS:

- Bilateral accentuated pulmonary vascular marking noted.
- Both hila appear normal.
- CTR within normal limit.
- Tracheal shadow is in the midline.
- Bilateral CP angle are clear
- No definite bone fracture is noted.

Impression:- Bilateral pulmonary vascular congestion.

llb

DR.ARNAB MANDAL

MD, Physician, PGDUS (Delhi) CEPT-USG (WBUHS KOLKATA)
Fellow of Jefferson Ultrasound Radiology and Education Institute
Philadelphia Ex-Radiology Resident (S.E.Railway)

Regd.No:72022(WBMC)



Patient Name: Mrs. SUKLA BISWAS 41/F

Resting ECG Report

February 01, 2022

QT / QTc : 0.332 / 0.381 Sec

PR Interval: 0.15 sec

RR Interval: 0.76 sec

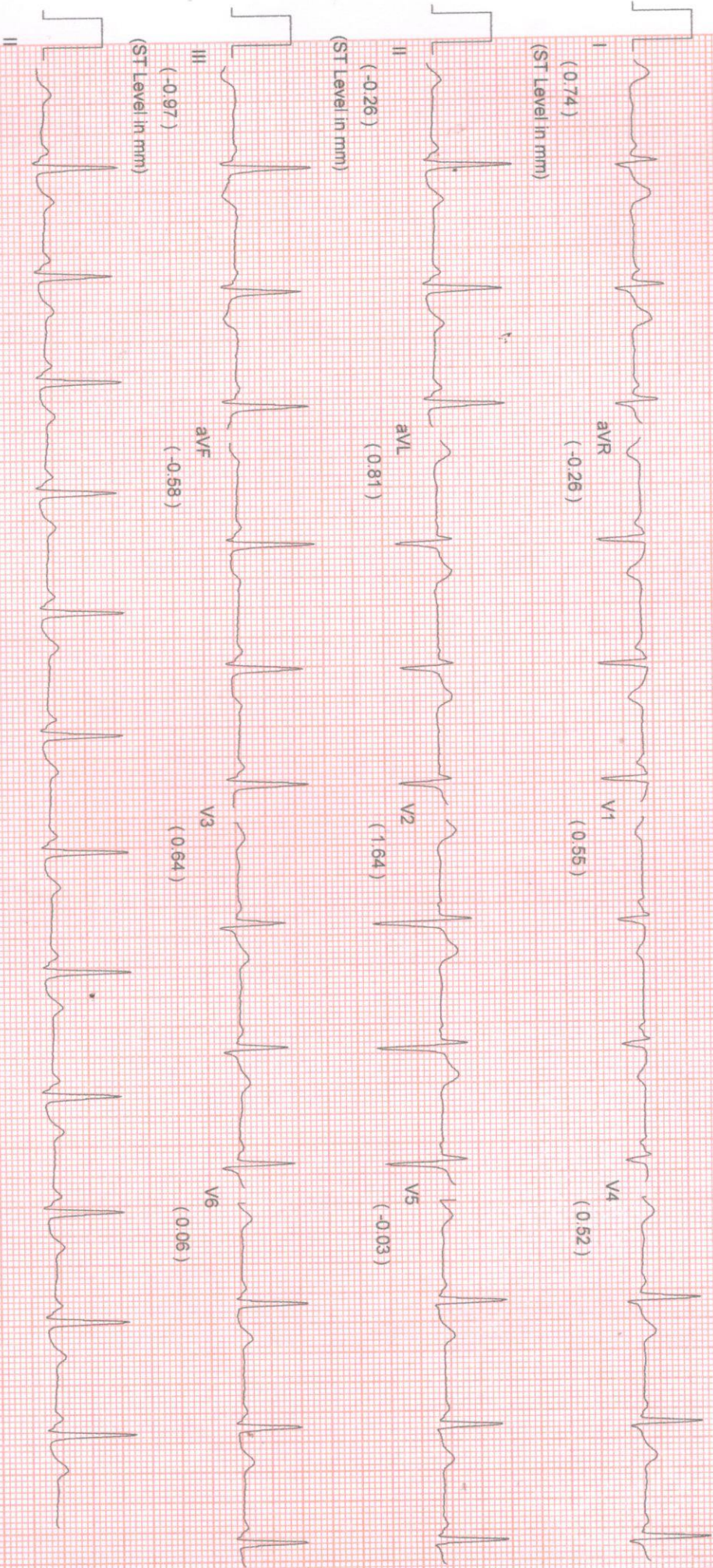
HR : 79 bpm

BP : 120 / 70 mmHg

Time: 13.02.19

P-QRS-T Axis (58)-(61)-(25) deg

QRS Duration : 0.076 Sec



Comments :-

Sukla Biswas.

NAME: MS.SUKLA BISWAS	MR NO: FSIN-0000	DATE : 01.02.2022
AGE: 41YRS.	SEX:FEMALE	REF BY: SELF(CORPORATE)

ECG REPORT

HR : 79 b/min

AXIS : NORMAL

RHYTHM : SINUS

PR INTERVAL : 0.15 sec


QT INTERVAL : 0.381 sec

QRS DURATION : 0.076 sec

T-WAVE : NORMAL.

IMPRESSION:

- RESTING ECG IS WITHIN NORMAL LIMITS.


Dr. SIDDHARTHA KUNDU
MBBS (Cal), PGDCC, CCEBDM
Clinical Cardiologist
Ex Sr Resident, Cardiology Dept
B.R Singh Hospital, Eastern Railway



NAME: MS.SUKLA BISWAS	AGE: 41YRS	SEX:FEMALE
REF BY: SELF(CORPORATE)	MR NO:FSIN-0000	DATE: 01/02/2022

ULTRASOUND OF WHOLE ABDOMEN

LIVER: Liver is Enlarged in size (**16.19cm**) shape, outline and echotexture. No focal area of alterea echogenicity is noted. The porta hepatis is normal. The common bile duct measures **4mm** in diameter. The portal vein measures **10mm** at porta.

GALL BLADDER: Gall bladder is distended .Wall is normal limits. No calculus or mass is seen within the gall bladder.

SPLEEN: It is normal in size (**9.87cm**), Shape, Outline and echotexture. No parenchymal lesion is noted.

PANCREAS: It is normal in size, Shape, Outline and echotexture. Pancreatic duct is not dilated.

RIGHT KIDNEY: kidney are normal in position, size, shape, outline and echotexture. The cortico medullary differentiation is maintained. No calculus or hydronephrosis is seen.

RIGHT KIDNEY: measures – (**10.19cm**).

LEFT KIDNEY: kidney are normal in position, size, shape, outline and echotexture. The cortico medullary differentiation is maintained. No calculus or hydronephrosis is seen.

LEFT KIDNEY: measures –(**10.24cm**).

URINARY BLADDER: It is well distended with normal wall thickness. No calculus or mass is seen within the urinary bladder.

UTERUS : It is **bulky** in size (**10.85cm**),shape and echotexture. It is anteverted. No SOL is seen in the myometrium. Uterine cavity is empty. Uterus measures- **4.76cm**

Endometrial thickness is normal measures- **0.77cm**


RIGHT OVARY- They are normal in size, shape ,outline and echotexture. measures-(**3.36cmX2.35cm**).

LEFT OVARY- They are normal in size, shape ,outline and echotexture. measures-(**2.15cmX1.42cm**).

NAME: MS.SUKLA BISWAS	AGE: 41YRS	SEX:FEMALE
REF BY: SELF(CORPORATE)	MR NO:FSIN-0000	DATE: 01/02/2022

IMPRESSION:

- MILD FATTY CHANGES IN LIVER.
- HEPATOSPLENOMEGALY.



A.K.ROY

M.B.B.S, Dip BMSc, DTM&H (Cal)

Certificate on CEBT Abdomino Pelvic, USG(WBHSU)

