

SIGNATURE HOSPITAL

SEC 310 GURURAM

PATIENT INFORMATION

ID: 23980 CASE: -

NAME: -

AGE: -

HEIGHT: -cms WEIGHT: -kg

DOCTOR: DR. CMO

REF: -

DATE/TIME: 10/12/2022 09:34:09

ECG SETTINGS

PRINTING MODE: AUTO 3\*1

GAIN/mm/mV: 10

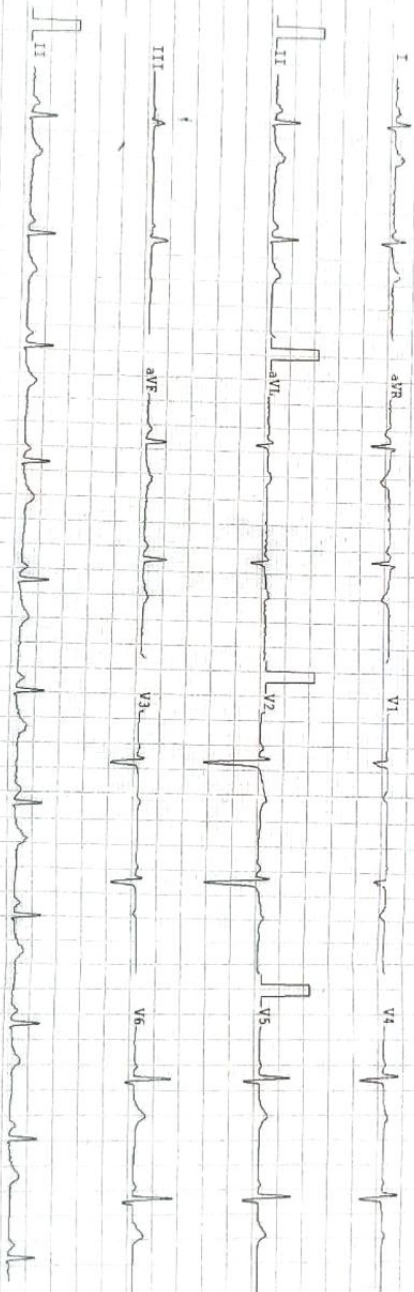
SPEED/mm/Sec: 25

PAPER/B2: 0.05 \* 35

NOTCH/BLC: ON/ON

RHYTHM LEAD: II

ALLENGERS PISCES (VER-5.02)



OBSERVATIONS

HEART RATE: 63 bpm

R-R: 941 ms

P-R: 116 ms

P-DUR: 92 ms

QRS: 84 ms

T-DUR: 202ms

ST-DUR: 134 ms

QT: 420 ms

QTc: 425 ms

P-AXIS: 51°

R-AXIS: 74°

T-AXIS: 37°

ST-AXIS: 166°

INTERPRETATION

SINUS RHYTHM

POSSIBLE ANTERIOR IN

REMARKS: -



Patient Name : Mrs. SARITA	UHID : 17280
Age / Gender : 30 Years 2 Months 13Days / Female	IPNO :
Referred By : Dr. CMO	Registered : 10/12/2022/ 9.40 AM
Req.No : 22243578	Sample Collection Dt & Tm : 10/12/2022/ 10.12 AM
Sample ID : 2246795	Sample Receiving Dt & Tm : 10/12/2022/ 10:13 AM
Patient Type : OPD	Report Released on : 10/12/2022/ 11.31 AM
Bed No :	

**HEMATOLOGY**

**Complete Blood Count -CBC(HB\TLC\PCV\RBC\Platelet)**


TEST NAME	RESULT	UNITS	REFERENCE INTERVAL	BIOLOGICAL SPECIMEN TYPE
Hemoglobin (Hb) (Colorimetry)	13.4	gm/dl	11.5 - 15.0	WHOLE BLOOD
TLC (Electrical Impedence)	5250	cell/cumm	4500 - 11000	EDTA WHOLE
<b><u>DIFFERENTIAL COUNT</u></b>				
Neutrophils (Flow Cytometry)	53	%	40 - 75	EDTA WHOLE
Lymphocytes (Flow Cytometry)	36	%	20 - 45	EDTA WHOLE
Monocytes (Flow Cytometry)	07	%	1 - 10	EDTA WHOLE
Eosinophil (Flow Cytometry)	04	%	1 - 6	EDTA WHOLE
Basophil	00	%	0 - 1	
RBC (Electrical Impedence)	4.8	millions/cumm	4.2 - 5.4	EDTA WHOLE

-\*\*\*\* End of Report \*\*\*\*-

Lab Technician

Dr.NishaTiwari  
(MD.Microbiology)

  
Dr. Neha Gupta  
MBBS,MD(Pathology)  
(Consultant Pathologist)

  
Dr. Shreya Pradhan  
MBBS,MD(Microbiology)  
(Consultant Microbiologist)

(This is only professional opinion and not the diagnosis. Please correlate clinically)

Sector 37-D, BPTP, Dwarka Express Way, Gurugram, Hry.,

Ph.: 0124-6034444, 8526000000, E-mail : signaturehospital@gmail.com, Web.: www.thesignaturehealthcare.com

**PARK GROUP OF HOSPITAL : ★ West Delhi ★ South Delhi ★ Gurugram ★ Faridabad ★ Panipat ★ Karnal**

Patient Name : Mrs. SARITA	UHID : 17280
Age / Gender : 30 Years 2 Months 13Days / Female	IPNO :
Referred By : Dr. CMO	Registered : 10/12/2022/ 9.40 AM
Req.No : 22243578	Sample Collection Dt & Tm : 10/12/2022/ 10.12 AM
Sample ID : 2246795	Sample Receiving Dt & Tm : 10/12/2022/ 10:13 AM
Patient Type : OPD	Report Released on : 10/12/2022/ 11.31 AM
Bed No :	

**HEMATOLOGY**


PCV (Electrical Impedence Calculation)	44.4	%	36 - 46	EDTA WHOLE
MCV (Electrical Impedence Calculation)	90.8	fl	76 - 96	EDTA WHOLE
MCH (Electrical Impedence Calculation)	27.4	pg	27 - 34	EDTA WHOLE
MCHC (Electrical Impedence Calculation)	30.2	gm/dl	30 - 36	EDTA WHOLE
RDW	13.6	%	11 - 16	
PLATELETE COUNT (Electrical Impedence)	265	1000/microLit	150 - 450	EDTA WHOLE

-\*\*\*\* End of Report \*\*\*\*-

Lab Technician

Dr.NishaTiwari  
(MD.Microbiology)

  
**Dr. Neha Gupta**  
 MBBS,MD(Pathology)  
 (Consultant Pathologist)

  
**Dr. Shreya Pradhan**  
 MBBS,MD(Microbiology)  
 (Consultant Microbiologist)

Page 2 of 2

(This is only professional opinion and not the diagnosis. Please correlate clinically)

Sector 37-D, BPTP, Dwarka Express Way, Gurugram, Hry.,

Ph.: 0124-6034444, 8526000000, E-mail : signaturehospital@gmail.com, Web.: www.thesignaturehealthcare.com

**PARK GROUP OF HOSPITAL : ★ West Delhi ★ South Delhi ★ Gurugram ★ Faridabad ★ Panipat ★ Karnal**



Patient Name : Mrs. SARITA	UHID : 17280
Age / Gender : 30 Years 2 Months 13Days / Female	IPNO :
Referred By : Dr. CMO	Registered : 10/12/2022/ 9.40 AM
Req.No : 22243578	Sample Collection Dt & Tm : 10/12/2022/ 10.12 AM
Sample ID : 2246795	Sample Receiving Dt & Tm : 10/12/2022/ 10:13 AM
Patient Type : OPD	Report Released on : 12/12/2022/ 10.44 AM
Bed No :	

**SEROLOGY/IMMUNOLOGY**

**Thyroid Profile**

TEST NAME	RESULT	UNITS	BIOLOGICAL REFERENCE INTERVAL	SPECIMEN TYPE
TEST METHOD				
Triiodothyronine (T3)	1.24	ng/ml	0.60 - 1.81	SERUM
Thyroxine (T4) CLIA	7.7	ug/dL	5.01 - 12.45	
TSH ( Thyroid Stimulating Hormone ) CLIA	3.76	uIU/ml	0.55 - 5.55	

**Remarks :**


(1) 4.2 to 15 IU/mL - Correlate clinically as physiological and other factors may falsely elevate TSH level. (2) TSH Values may be transiently altered because of non thyroidal illness. (3) Some drugs may decrease TSH values, e.g., L-dopa, Glucocorticoids. (4) Some drugs may increase TSH values, e.g., Iodine, Lithium, Amiodarone. Abbreviations.

-\*\*\*\* End of Report \*\*\*\*-

Lab Technician

Dr.NishaTiwari  
(MD.Microbiology)

  
 Dr. Neha Gupta  
 MBBS,MD(Pathology)  
 (Consultant Pathologist)

  
 Dr. Shreya Pradhan  
 MBBS,MD(Microbiology)  
 (Consultant Microbiologist)

(This is only professional opinion and not the diagnosis. Please correlate clinically)

Sector 37-D, BPTP, Dwarka Express Way, Gurugram, Hry.,

Ph.: 0124-6034444, 8526000000, E-mail : signaturehospital@gmail.com, Web.: www.thesignaturehealthcare.com

**PARK GROUP OF HOSPITAL : ★ West Delhi ★ South Delhi ★ Gurugram ★ Faridabad ★ Panipat ★ Karnal**

Patient Name : Mrs. SARITA	UHID : 17280
Age / Gender : 30 Years 2 Months 13Days / Female	IPNO :
Referred By : Dr. CMO	Registered : 10/12/2022/ 9.40 AM
Req.No : 22243578	Sample Collection Dt & Tm : 10/12/2022/ 10.12 AM
Sample ID : 2246795	Sample Receiving Dt & Tm : 10/12/2022/ 10:13 AM
Patient Type : OPD	Report Released on : 10/12/2022/ 11.57 AM
Bed No :	

**BIOCHEMISTRY**

**Blood Sugar Fasting**

TEST NAME	RESULT	UNITS	BIOLOGICAL REFERENCE INTERVAL	SPECIMEN TYPE
TEST METHOD				
BLOOD SUGAR FASTING (God- Trinders)	91	mg/dl	75 - 115	Flouride Plasma

Increased In:

Diabetes Mellitus  
 Stress ( e.g. emotion, burns, shock, anesthesia)  
 Acute Pancreatitis  
 Chronic Pancreatitis  
 Wernicke encephalopathy ( Vitamin B1 deficiency)  
 Effect of drugs (e.g. corticosterogens, alcohol, phenytoin, thiazides)

Decreased in :


Pancreatitis disorders  
 Extrapancreatic tumors  
 Endocrine disorders  
 Malnutrition  
 Hypothalamic lesions  
 Alcoholism  
 Endocrine Disorders

-\*\*\*\* End of Report \*\*\*\*-

Lab Technician

Dr.NishaTiwari  
(MD.Microbiology)

  
**The Signature**  
 Dr. Neha Gupta L  
 MBBS,MD(Pathology)  
 (Consultant Pathologist)

  
 Dr. Shreya Pradhan  
 MBBS,MD(Microbiology)  
 (Consultant Microbiologist)

(This is only professional opinion and not the diagnosis. Please correlate clinically)

Sector 37-D, BPTP, Dwarka Express Way, Gurugram, Hry.,

Ph.: 0124-6034444, 8526000000, E-mail : signaturehospital@gmail.com, Web.: www.thesignaturehealthcare.com

**PARK GROUP OF HOSPITAL : ★ West Delhi ★ South Delhi ★ Gurugram ★ Faridabad ★ Panipat ★ Karnal**

Patient Name : Mrs. SARITA	UHID : 17280
Age / Gender : 30 Years 2 Months 13Days / Female	IPNO :
Referred By : Dr. CMO	Registered : 10/12/2022/ 9.40 AM
Req.No : 22243578	Sample Collection Dt & Tm : 10/12/2022/ 10.12 AM
Sample ID : 2246795	Sample Receiving Dt & Tm : 10/12/2022/ 10:13 AM
Patient Type : OPD	Report Released on : 10/12/2022/ 11.32 AM
Bed No :	

**BIOCHEMISTRY**

**Lipid Profile**


TEST NAME	RESULT	UNITS	BIOLOGICAL REFERENCE INTERVAL	SPECIMEN TYPE
TEST METHOD				
<b>LIPID PROFILE</b>				
CHOLESTROL (CHOD-TRINDER)	207	mg/dl	00 - 200	SERUM
TRIGLYCERIDES (GPO-Trinders)	156	mg/dl	35 - 170	SERUM
HDL- CHOL (Direct Method/ Enzymatic Colorometric)	57	mg/dl	40 - 60	SERUM
VLDL-CHOL CALCULATED	31.2	mg/dl	10 - 40	
LDL-CHOLESTROL	118.8	mg/dl	0 - 130	
LDL/HDL RATIO	2.08		0-3	
CHOLESTROL/HDL RATIO	3.63			

\*\*\*\* End of Report \*\*\*\*

Lab Technician

Dr.NishaTiwari  
(MD.Microbiology)

  
**The Signature**  
 Dr. Nisha Gupta  
 MBBS,MD(Pathology)  
 (Consultant Pathologist)

  
 Dr. Shreya Pradhan  
 MBBS,MD(Microbiology)  
 (Consultant Microbiologist)

Page 1 of 2

(This is only professional opinion and not the diagnosis. Please correlate clinically)

Sector 37-D, BPTP, Dwarka Express Way, Gurugram, Hry.,

Ph.: 0124-6034444, 8526000000, E-mail : signaturehospital@gmail.com, Web.: www.thesignaturehealthcare.com

**PARK GROUP OF HOSPITAL : ★ West Delhi ★ South Delhi ★ Gurugram ★ Faridabad ★ Panipat ★ Karnal**



The Signature  
ADVANCED SUPER SPECIALITY  
H O S P I T A L

---



(This is only professional opinion and not the diagnosis. Please correlate clinically)

Sector 37-D, BPTP, Dwarka Express Way, Gurugram, Hry.,

Ph.: 0124-6034444, 8526000000, E-mail : signaturehospital@gmail.com, Web.: www.thesignaturehealthcare.com  
**PARK GROUP OF HOSPITAL : ★ West Delhi ★ South Delhi ★ Gurugram ★ Faridabad ★ Panipat ★ Karnal**



Patient Name : Mrs. SARITA	UHID : 17280
Age / Gender : 30 Years 2 Months 13Days / Female	IPNO :
Referred By : Dr. CMO	Registered : 10/12/2022/ 9.40 AM
Req.No : 22243578	Sample Collection Dt & Tm : 10/12/2022/ 10.12 AM
Sample ID : 2246795	Sample Receiving Dt & Tm : 10/12/2022/ 10:13 AM
Patient Type : OPD	Report Released on : 10/12/2022/ 11.56 AM
Bed No :	

**BIOCHEMISTRY**

**Renal Profile**


TEST NAME	RESULT	UNITS	BIOLOGICAL REFERENCE INTERVAL	SPECIMEN TYPE
TEST METHOD				
BLOOD UREA (Urease UV/GLDH)	29	mg/dl	13 - 45	SERUM
SERUM CREATININE (Jaffe Rate)	0.9	mg/dl	0.6 - 1.2	SERUM
URIC ACID (Enzymatic/Uricase)	2.3	mg/dl	2.5 - 6.8	SERUM
<b><u>ELECTROLYTES</u></b>				
SODIUM (ISE-Indirect)	141	mmol/L	132 - 150	SERUM
POTASSIUM (ISE-Indirect)	3.8	mmol/L	3.5 - 5.5	SERUM

-\*\*\*\* End of Report \*\*\*\*-

Lab Technician

Dr.NishaTiwari  
(MD.Microbiology)

  
**The Signature**  
 HOSPITAL  
 Dr. Neha Gupta  
 MBBS,MD(Pathology)  
 (Consultant Pathologist)

  
 Dr. Shreya Pradhan  
 MBBS,MD(Microbiology)  
 (Consultant Microbiologist)

(This is only professional opinion and not the diagnosis. Please correlate clinically)

Sector 37-D, BPTP, Dwarka Express Way, Gurugram, Hry.,

Ph.: 0124-6034444, 8526000000, E-mail : signaturehospital@gmail.com, Web.: www.thesignaturehealthcare.com

**PARK GROUP OF HOSPITAL : ★ West Delhi ★ South Delhi ★ Gurugram ★ Faridabad ★ Panipat ★ Karnal**



Patient Name : Mrs. SARITA	UHID : 17280
Age / Gender : 30 Years 2 Months 13Days / Female	IPNO :
Referred By : Dr. CMO	Registered : 10/12/2022/ 9.40 AM
Req.No : 22243578	Sample Collection Dt & Tm : 10/12/2022/ 10.12 AM
Sample ID : 2246795	Sample Receiving Dt & Tm : 10/12/2022/ 10:13 AM
Patient Type : OPD	Report Released on : 10/12/2022/ 11.56 AM
Bed No :	

**BIOCHEMISTRY**

**PROTEINS**


TOTAL PROTEIN (Biuret)	6.7	g/dl	6.0 - 8.3	SERUM
ALBUMIN (BCG- DYE)	3.4	g/dl	3.2 - 5.0	SERUM
GLOBULIN Calculated	3.3	gm/dl	1.5 - 3.6	
A/G RATIO Calculated	1.03		0.9 - 2.0	

-\*\*\*\* End of Report \*\*\*\*-

Lab Technician

Dr.NishaTiwari  
(MD.Microbiology)

  
  
 Dr.Nisha Gupta  
 MBBS,MD(Pathology)  
 (Consultant Pathologist)

  
 Dr. Shreya Pradhan  
 MBBS,MD(Microbiology)  
 (Consultant Microbiologist)

(This is only professional opinion and not the diagnosis. Please correlate clinically)

Sector 37-D, BPTP, Dwarka Express Way, Gurugram, Hry.,

Ph.: 0124-6034444, 8526000000, E-mail : signaturehospital@gmail.com, Web.: www.thesignaturehealthcare.com

**PARK GROUP OF HOSPITAL : ★ West Delhi ★ South Delhi ★ Gurugram ★ Faridabad ★ Panipat ★ Karnal**

Patient Name : Mrs. SARITA	UHID : 17280
Age / Gender : 30 Years 2 Months 13Days / Female	IPNO :
Referred By : Dr. CMO	Registered : 10/12/2022/ 9.40 AM
Req.No : 22243578	Sample Collection Dt & Tm : 10/12/2022/ 10.12 AM
Sample ID : 2246795	Sample Receiving Dt & Tm : 10/12/2022/ 10:13 AM
Patient Type : OPD	Report Released on : 10/12/2022/ 11.33 AM
Bed No :	

**BIOCHEMISTRY**

**Liver Function Test Profile**


TEST NAME	RESULT	UNITS	BIOLOGICAL REFERENCE INTERVAL	SPECIMEN TYPE
TEST METHOD				
<b><u>BILIRUBIN TOTAL AND DIRECT</u></b>				
BILIRUBIN TOTAL (Diazonium Salt)	0.5	mg/dl	0.1 - 1.2	SERUM
BILIRUBIN DIRECT (Diazonium Salt)	0.2	mg/dl	00 - 0.3	SERUM
BILIRUBIN INDIRECT (CALCULATED)	0.3	md/dl	0 - 0.9	
SGOT/AST (UV-KINETIC)	19	U/I	0 - 45	SERUM
SGPT/ALT (UV-KINETIC)	09	U/I	0 - 45	SERUM
ALKALINE PHOSPHATASE (ALP) (Kinetic)	115	U/I	39 - 118	SERUM

-\*\*\*\* End of Report \*\*\*\*-

Lab Technician

Dr.NishaTiwari  
(MD.Microbiology)

  
**The Signature**  
 HOSPITAL  
 Dr. Nisha Gupta  
 MBBS,MD(Pathology)  
 (Consultant Pathologist)

  
 Dr. Shreya Pradhan  
 MBBS,MD(Microbiology)  
 (Consultant Microbiologist)

Page 1 of 2

(This is only professional opinion and not the diagnosis. Please correlate clinically)

Sector 37-D, BPTP, Dwarka Express Way, Gurugram, Hry.,

Ph.: 0124-6034444, 8526000000, E-mail : signaturehospital@gmail.com, Web.: www.thesignaturehealthcare.com

**PARK GROUP OF HOSPITAL : ★ West Delhi ★ South Delhi ★ Gurugram ★ Faridabad ★ Panipat ★ Karnal**

  
**The Signature**  
ADVANCED SUPER SPECIALITY  
HOSPITAL



Patient Name : Mrs. SARITA  
Age / Gender : 30 Years 2 Months 13Days / Female  
Referred By : Dr. CMO  
Req.No : 22243578  
Sample ID : 2246795  
Patient Type : OPD  
Bed No :  
UHID : 17280  
IPNO :  
Registered : 10/12/2022/ 9.40 AM  
Sample Collection Dt & Tm : 10/12/2022/ 10.12 AM  
Sample Receiving Dt & Tm : 10/12/2022/ 10:13 AM  
Report Released on : 10/12/2022/ 11.33 AM

**BIOCHEMISTRY**

**PROTEINS**


TOTAL PROTEIN (Biuret)	6.7	g/dl	6.0 - 8.3	SERUM
ALBUMIN (BCG- DYE)	3.4	g/dl	3.2 - 5.0	SERUM
GLOBULIN Calculated	3.3	gm/dl	1.5 - 3.6	
A/G RATIO Calculated	1.03		0.9 - 2.0	

\*\*\*\* End of Report \*\*\*\*

Lab Technician

Dr.NishaTiwari  
(MD.Microbiology)

  
The Signature  
Dr. Nisha Gupta  
MBBS,MD(Pathology)  
(Consultant Pathologist)

  
Dr. Shreya Pradhan  
MBBS,MD(Microbiology)  
(Consultant Microbiologist)

Page 2 of 2

(This is only professional opinion and not the diagnosis. Please correlate clinically)

Sector 37-D, BPTP, Dwarka Express Way, Gurugram, Hry.,

Ph.: 0124-6034444, 8526000000, E-mail : signaturehospital@gmail.com, Web.: www.thesignaturehealthcare.com

PARK GROUP OF HOSPITAL : ★ West Delhi ★ South Delhi ★ Gurugram ★ Faridabad ★ Panipat ★ Karnal



Patient Name : Mrs. SARITA	UHID : 17280
Age / Gender : 30 Years 2 Months 13Days / Female	IPNO :
Referred By : Dr. CMO	Registered : 10/12/2022/ 9.40 AM
Req.No : 22243578	Sample Collection Dt & Tm : 10/12/2022/ 10.12 AM
Sample ID : 2246795	Sample Receiving Dt & Tm : 10/12/2022/ 10:13 AM
Patient Type : OPD	Report Released on : 10/12/2022/ 11.46 AM
Bed No :	

**BIOCHEMISTRY**

**Blood Group And Rh Factor**


TEST NAME	RESULT	UNITS	BIOLOGICAL REFERENCE INTERVAL	SPECIMEN TYPE
TEST METHOD				
BLOOD GROUP(ABORh)	"O" POSITIVE			

-\*\*\*\* End of Report \*\*\*\*-

Lab Technician

Dr.NishaTiwari  
(MD.Microbiology)

  
**The Signature**  
 Dr. Neha Gupta  
 MBBS,MD(Pathology)  
 (Consultant Pathologist)

  
 Dr. Shreya Pradhan  
 MBBS,MD(Microbiology)  
 (Consultant Microbiologist)

(This is only professional opinion and not the diagnosis. Please correlate clinically)

Sector 37-D, BPTP, Dwarka Express Way, Gurugram, Hry.,

Ph.: 0124-6034444, 8526000000, E-mail : signaturehospital@gmail.com, Web.: www.thesignaturehealthcare.com

**PARK GROUP OF HOSPITAL : ★ West Delhi ★ South Delhi ★ Gurugram ★ Faridabad ★ Panipat ★ Karnal**

Patient Name : Mrs. SARITA	UHID : 17280
Age / Gender : 30 Years 2 Months 13Days / Female	IPNO :
Referred By : Dr. CMO	Registered : 10/12/2022/ 9.40 AM
Req.No : 22243578	Sample Collection Dt & Tm : 10/12/2022/ 10.12 AM
Sample ID : 2246795	Sample Receiving Dt & Tm : 10/12/2022/ 10:13 AM
Patient Type : OPD	Report Released on : 11/12/2022 / 10.19 AM
Bed No :	

**BIOCHEMISTRY**

**Glycosylated Haemoglobin**


TEST NAME	RESULT	UNITS	BIOLOGICAL
TEST METHOD			REFERENCE INTERVAL    SPECIMEN TYPE
HbA1C (GLYCOSYLATED HEMOGLOBIN)	5.4	%	4.6 - 6.2


Metabolically Healthy Patients 4.5 6.0  
 Good Control 6.1 6.5  
 Fair Control 6.6 7.0  
 Poor Control > 7.0

-\*\*\* End of Report \*\*\*-

Lab Technician

Dr.NishaTiwari  
(MD.Microbiology)

  
 The Signature Hospital  
 Dr. Nisha Gupta  
 MBBS,MD(Pathology)  
 (Consultant Pathologist)

  
 Dr. Shreya Pradhan  
 MBBS,MD(Microbiology)  
 (Consultant Microbiologist)

(This is only professional opinion and not the diagnosis. Please correlate clinically)

Sector 37-D, BPTP, Dwarka Express Way, Gurugram, Hry.,

Ph.: 0124-6034444, 8526000000, E-mail : signaturehospital@gmail.com, Web.: www.thesignaturehealthcare.com

**PARK GROUP OF HOSPITAL : ★ West Delhi ★ South Delhi ★ Gurugram ★ Faridabad ★ Panipat ★ Karnal**

Patient Name : Mrs. SARITA	UHID : 17280
Age / Gender : 30 Years 2 Months 13Days / Female	IPNO :
Referred By : Dr. CMO	Registered : 10/12/2022/ 9.40 AM
Req.No : 22243578	Sample Collection Dt & Tm : 10/12/2022/ 10.12 AM
Sample ID : 2246795	Sample Receiving Dt & Tm : 10/12/2022/ 10:13 AM
Patient Type : OPD	Report Released on : 11/12/2022/ 10.19 AM
Bed No :	

**BIOCHEMISTRY**

**Glycosylated Haemoglobin**

TEST NAME	RESULT	UNITS	BIOLOGICAL
TEST METHOD			REFERENCE INTERVAL    SPECIMEN TYPE
HbA1C (GLYCOSYLATED HEMOGLOBIN)	5.4	%	4.6 - 6.2


Metabolically Healthy Patients 4.5 6.0  
 Good Control 6.1 6.5  
 Fair Control 6.6 7.0  
 Poor Control > 7.0

-\*\*\*\* End of Report \*\*\*\*-

Lab Technician

Dr.NishaTiwari  
(MD.Microbiology)

  
**The Signature**  
 ADVANCED SUPER SPECIALITY  
**Dr.Nisha Gupta**  
 MBBS,MD(Pathology)  
 (Consultant Pathologist)

  
**Dr. Shreya Pradhan**  
 MBBS,MD(Microbiology)  
 (Consultant Microbiologist)

(This is only professional opinion and not the diagnosis. Please correlate clinically)

Sector 37-D, BPTP, Dwarka Express Way, Gurugram, Hry.,

Ph.: 0124-6034444, 8526000000, E-mail : signaturehospital@gmail.com, Web.: www.thesignaturehealthcare.com

**PARK GROUP OF HOSPITAL : ★ West Delhi ★ South Delhi ★ Gurugram ★ Faridabad ★ Panipat ★ Karnal**



Patient Name : Mrs. SARITA	UHID : 17280
Age / Gender : 30 Years 2 Months 13Days / Female	IPNO :
Referred By : Dr. CMO	Registered : 10/12/2022/ 9.40 AM
Req.No : 22243578	Sample Collection Dt & Tm : 10/12/2022/ 10.12 AM
Sample ID : 2246795	Sample Receiving Dt & Tm : 10/12/2022/ 10:13 AM
Patient Type : OPD	Report Released on : 10/12/2022/ 11.40 AM
Bed No :	

**CLINICAL PATHOLOGY**


**Urine Routine And Microscopy.**


TEST NAME	RESULT	UNITS	BIOLOGICAL
TEST METHOD			REFERENCE INTERVAL SPECIMEN TYPE
QUANTITY	30 ML		
COLOUR	PALE YELLOW		
TURBIDITY	CLEAR		
SPECIFIC GRAVITY (Bromthymol Blue)	1.010		1.003-1.030 Urine
PH (Chromatography)	6.0		4.7-7.0 Urine

-\*\*\*\* End of Report \*\*\*\*-

Lab Technician

Dr.NishaTiwari  
(MD.Microbiology)

  
 Dr. Nisha Gupta  
 MBBS, MD(Pathology)  
 (Consultant Pathologist)

  
 Dr. Shreya Pradhan  
 MBBS, MD(Microbiology)  
 (Consultant Microbiologist)

(This is only professional opinion and not the diagnosis. Please correlate clinically)

Sector 37-D, BPTP, Dwarka Express Way, Gurugram, Hry.,

Patient Name : Mrs. SARITA	UHID : 17280
Age / Gender : 30 Years 2 Months 13Days / Female	IPNO :
Referred By : Dr. CMO	Registered : 10/12/2022/ 9.40 AM
Req.No : 22243578	Sample Collection Dt & Tm : 10/12/2022/ 10.12 AM
Sample ID : 2246795	Sample Receiving Dt & Tm : 10/12/2022/ 10:13 AM
Patient Type : OPD	Report Released on : 10/12/2022/ 11.40 AM
Bed No :	

**CLINICAL PATHOLOGY**

**CHEMICAL EXAMINATION**


UROBILINOGEN (Ehrlich's Aldehyde Reaction)	NORMAL	NORMAL	Urine
PROTEIN	NIL	NIL	
BLOOD	NIL	NIL	
KETONE (Sodium Nitroprusside)	NIL	NIL	Urine
BILIRUBIN (Diazonium Salt)	NIL	NIL	SERUM
GLUCOSE (Benedict's Test)	NIL	NIL	Urine
NITRITE	NEGATIVE		

-\*\*\*\* End of Report \*\*\*\*-

Lab Technician

Dr.NishaTiwari  
(MD.Microbiology)

  
**The Signature**  
 Dr. Nisha Gupta  
 MBBS,MD(Pathology)  
 (Consultant Pathologist)

  
 Dr. Shreya Pradhan  
 MBBS,MD(Microbiology)  
 (Consultant Microbiologist)

(This is only professional opinion and not the diagnosis. Please correlate clinically)

Sector 37-D, BPTP, Dwarka Express Way, Gurugram, Hry.,

Ph.: 0124-6034444, 8526000000, E-mail : signaturehospital@gmail.com, Web.: www.thesignaturehealthcare.com

**PARK GROUP OF HOSPITAL : ★ West Delhi ★ South Delhi ★ Gurugram ★ Faridabad ★ Panipat ★ Karnal**

Patient Name : Mrs. SARITA	UHID : 17280
Age / Gender : 30 Years 2 Months 13Days / Female	IPNO :
Referred By : Dr. CMO	Registered : 10/12/2022/ 9.40 AM
Req.No : 22243578	Sample Collection Dt & Tm : 10/12/2022/ 10.12 AM
Sample ID : 2246795	Sample Receiving Dt & Tm : 10/12/2022/ 10:13 AM
Patient Type : OPD	Report Released on : 10/12/2022/ 11.40 AM
Bed No :	

**CLINICAL PATHOLOGY**

**MICROSCOPIC EXAMINATION - URINE**

PUS CELLS (Microscopic)	1-2	/HPF	0 - 3	Urine
RBC- Urine (Per Oxidase Reaction)	NIL	/HPF	NIL	Urine
EPITHELIAL CELLS	0-1	/HPF	0 - 5	
CAST	NIL		NIL	
CRYSTALS	NIL		NIL	
BACTERIA	NIL			
OTHERS	NIL			

COMMENTS: Actual numerical values for WBCs, RBCs and Epithelial cells are not defined and must be correlated clinically.

Test Methods: Reagent strip analysis and urine sediment microscopy.


Reagent strip / chemical analysis are based on: pH-Double Indicator principle; Specific gravity Ion exchange method; Glucose Glucose oxidase-peroxidase/Benedicts; Protein Acid-base indicator/Sulfosalicylic acid; Urobilinogen Coupling reaction/Ehrlichsreaction, Bilirubin Coupling reaction, Ketones Nitroprusside method/Rotheras test.

-\*\*\*\* End of Report \*\*\*\*-

Lab Technician

Dr.NishaTiwari  
(MD.Microbiology)

  
**The Signature**  
 ADVANCED SUPER SPECIALITY  
 HOSPITAL  
 Dr. Neha Gupta  
 MBBS,MD(Pathology)  
 (Consultant Pathologist)

  
 Dr. Shreya Pradhan  
 MBBS,MD(Microbiology)  
 (Consultant Microbiologist)

(This is only professional opinion and not the diagnosis. Please correlate clinically)

Sector 37-D, BPTP, Dwarka Express Way, Gurugram, Hry.,

Ph.: 0124-6034444, 8526000000, E-mail : signaturehospital@gmail.com, Web.: www.thesignaturehealthcare.com

**PARK GROUP OF HOSPITAL : ★ West Delhi ★ South Delhi ★ Gurugram ★ Faridabad ★ Panipat ★ Karnal**



**TRANSTHORACIC ECHO- DOPPLER REPORT**

<b>NAME</b> - MRS SARITA	<b>AGE/SEX</b> -30/F
<b>MR. NO.</b> -17280	<b>DATE</b> - 10/12/2022

**M-MODE / 2-D DESCRIPTION**

- ❖ **Left Ventricle:** No regional wall motion abnormality. LVEF ~ 60 %.
- ❖ **Left Atrium:** Normal.
- ❖ **Right atrium:** It is Normal Sized.
- ❖ **Right ventricle:** It is Normal Sized. RV Systolic Function is Normal.
- ❖ **Aortic valve:** Aortic Cusps are Normal.
- ❖ **Mitral valve:** It Appears Normal.
- ❖ **Tricuspid valve:** It Appears Normal.
- ❖ **Pulmonic valve:** It Appears Normal.
- ❖ **Main pulmonary artery & its branches:** Appear Normal.
- ❖ **Pericardium:** No Pericardial Effusion Seen
- ❖ **Inter atrial septum:** It is Intact.
- ❖ **Inter ventricular septum:** It is Intact.
- ❖ **IVC:** It is Normal in Size, collapsing & Respiratory Variability.
- ❖ **Clot / Vegetation:** No Intracardiac Clot, Vegetation.

**Measurements (mm):**

<b>LEFT HEART</b>			<b>RIGHT HEART</b>		
	<u>Observed values</u> (mm)	Normal values		<u>Observed values</u> (mm)	Normal values
Aortic root	29	20-36 (22mm/M <sup>2</sup> )	IVC size	-	17-21mm
Aortic valve opening		15-26 (mm/M <sup>2</sup> )	IVC respiratory variability		>50%
LA size	30	19-40 (mm/M <sup>2</sup> )	RA size	-	<18cm <sup>2</sup>
LA volume index (ml/M <sup>2</sup> )		<34 ml/M <sup>2</sup>		-	
LVID(D)	55	(ED=37-56)	RV basal		24-42mm
LVID(S)	45		RV mid cavity	-	20-35mm
IVS(D)	9	(ED=6-12)	RV longitudinal	-	56-86mm
			RVOT proximal	-	18-33mm
PW(D)	11	(ED=5-10)	TAPSE	-	>15mm
			RV free wall thickness	-	<5mm
LVEF(%)	60 %	55%-70%	RVEF		>44%

(This is only professional opinion and not the diagnosis. Please correlate clinically)

Sector 37-D, BPTP, Dwarka Express Way, Gurugram, Hry.,

Doppler velocities (cm/sec)


Aortic valve		Pulmonary valve	
Max/ Vel	119	Max velocity	116
Max/ PG		Max PG	
Mitral valve		Tricuspid valve	
E	65	Max Velocity	
A	63	PASP	-
DT	-	E/E' (>6)	-
E/A	-	S' Velocity (>10cm2/sec)	-

Regurgitation

MR		TR	
Severity	Nil	Severity	Nil
AR		PR	
Severity	Nil	Severity	Nil

Final Interpretation:

- No regional wall motion abnormality. LVEF ~ 60 %.
- Normal Cardiac Chamber Dimension.
- No MR, No AR, No TR.
- Normal MIP,
- No Vegetation, Pericardial Effusion.

  
**Dr. AJAY DUA**  
 DNB (Medicine), DNB (Cardiology)  
 Sr. Consultant Interventional Cardiology

(This is only professional opinion and not the diagnosis. Please correlate clinically)

Sector 37-D, BPTP, Dwarka Express Way, Gurugram, Hry.,

Ph.: 0124-6034444, 8526000000, E-mail : signaturehospital@gmail.com, Web.: www.thesignaturehealthcare.com  
**PARK GROUP OF HOSPITAL : ★ West Delhi ★ South Delhi ★ Gurugram ★ Faridabad ★ Panipat ★ Karnal**

PATIENT NAME : <b>Mrs. SARITA</b>	MR NO : <b>17280</b>
BILL NO : <b>22243578</b>	BILL DATE/TIME : <b>10/12/2022 9.40 AM</b>
AGE/SEX : <b>30 YEARS 2 MONTHS 13DAYS /</b>	SAMPLE DATE/TIME : <b>10/12/2022 10.55 AM</b>
TYPE : <b>OPD</b>	REPORTING DATE/TIME : <b>14/12/2022 5.29 PM</b>
DOCTOR NAME : <b>Dr. CMO</b>	APPROVED DATE/TIME :
	PRINT DATE/TIME : <b>14/12/2022 5.29 PM</b>
	MOBILE NO : <b>8860152729</b>

**DEPARTMENT OF X-RAY**

**X-RAY CHEST.**

**X-RAY CHEST**

Lung fields are clear.

Bilateral hilar shadows are normal.

Mediastinum and domes are normal.

Costophrenic angles appear sharp.

Cardiac silhouette appears normal.

No obvious rib fracture seen.

*Adv: Clinical and lab data correlation.*

**Dr. Guru**  
Senior Consultant  
Diagnostic & Interventional Radiology



(This is only professional opinion and not the diagnosis. Please correlate clinically)

Sector 37-D, BPTP, Dwarka Express Way, Gurugram, Hry.,

Ph.: 0124-6034444, 8526000000, E-mail : signaturehospital@gmail.com, Web.: www.thesignaturehealthcare.com  
**PARK GROUP OF HOSPITAL : ★ West Delhi ★ South Delhi ★ Gurugram ★ Faridabad ★ Panipat ★ Karnal**



**DEPARTMENT OF IMAGING & INTERVENTIONAL RADIOLOGY, THE SIGNATURE HOSPITAL**

<b>NAME: SARITA</b>	<b>DATE: 10/12/2022</b>
<b>AGE: 30/F</b>	<b>MR NO.: 17280</b>

**USG WHOLE ABDOMEN**

**LIVER:** is normal in size and echotexture. No evidence of any focal lesion or IHBR dilation is present. Portal vein and CBD are normal in caliber at porta.

**GALL BLADDER** is well distended and lumen is echofree. Wall thickness is normal. No pericholecystic fluid is seen.

**SPLEEN:** is normal in size and echotexture. No focal lesion is seen.

**PANCREAS:** is normal in size and echotexture. Peripancreatic fat planes are clear. MPD is not dilated.

**RIGHT KIDNEY:** is normal in size and position and outline corticomedullary differentiation is maintained. There is no evidence of any focal lesion / calculus / backpressure changes.

**LEFT KIDNEY:** is normal in size and position and outline corticomedullary differentiation is maintained. There is no evidence of any focal lesion / calculus / backpressure changes.

**URINARY BLADDER** is well distended. Wall thickness is normal. No evidence of any focal lesion.

**UTERUS:** is normal in size, shape and position. Myometrial echotexture is normal. There is no focal lesion.

Right ovary is unremarkable.

**Left ovary shows well defined simple anechoic cystic lesion measuring approximately 2 x 1 cms.**

Cul de Sac is clear.

**IMPRESSION:**

- No significant abnormality.
- Left ovary well defined simple anechoic cystic lesion-? Left ovarian simple follicular cyst.

*Please correlate clinically.*

  
**Dr. Guru**  
Senior Consultant  
Diagnostic & Interventional Radiology

(This is only professional opinion and not the diagnosis. Please correlate clinically)

Sector 37-D, BPTP, Dwarka Express Way, Gurugram, Hry.,

Ph.: 0124-6034444, 8526000000, E-mail : signaturehospital@gmail.com, Web.: www.thesignaturehealthcare.com

**PARK GROUP OF HOSPITAL : ★ West Delhi ★ South Delhi ★ Gurugram ★ Faridabad ★ Panipat ★ Karnal**