



Dr. Vandana G. Powar M.B.B.S., D.C.P.
Consultant Pathologist



PARTH
PATHOLOGY LABORATORY
(Computerised)

LAB - Shop No. 7, "Diwan Towers" Mangalwar Peth, Near Mirajkar Tikli, Opp. Nutan Marathi High School, Kolhapur. Mob. 9158529408, 9422047480, 9921285167

DATE - 31/03/2023

PATIENT NAME - Dipak. Patil

AGE - 45 Y/MALE

HEIGHT - 179 cm

WEIGHT - 82 kg

BLOOD PRESSURE - 111/70 mmHg

PULSES - 60/Min

FIT TO PERFORM ALL DUTIES

Dr. Vandana G. Powar
M.B.B.S., D.C.P.
Reg. No. 69137

PATHOLOGIST

Vandana
DR. VANDANA POWAR
M.B.B.S., D.C.P.

All Biochemistry Tests Done By Computerised Auto Analyser

HAEMATOLOGY | CLINICAL PATHOLOGY | BIOCHEMISTRY | SEROLOGY | MICROBIOLOGY | HISTOPATHOLOGY

24 Hours Emergency Service

Home Service Available



भारत सरकार
Unique Identification Authority of India
Government of India

नोंदणी क्रमांक: / Enrolment No.: 1178/95009/00147

To
दिपक बापू पाटील
Dipak Babu Patil
Gorambe Taluka-Kagal
Gorambe
Gorambe
Kolhapur Maharashtra - 416216
9860047909

Download Date: 11/06/2018

Generation Date: 16/03/2013

Signature valid



आपला आधार क्रमांक / Your Aadhaar No. :

7064 9790 7721

माझे आधार, माझी ओळख



भारत सरकार
Government of India



दिपक बापू पाटील
Dipak Babu Patil
जन्म तारीख/DOB: 27/10/1978
पुल्ल/ MALE

7064 9790 7721

माझे आधार, माझी ओळख

Patil



Dr. Vandana G. Powar
M.B.B.S., D.C.P
Reg No 13137



NAME : MR. DIPAK PATIL

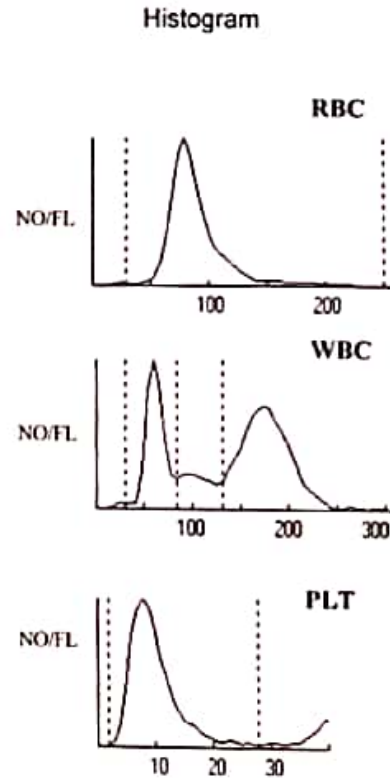
DATE : 04/04/2023 PT.NO. : 201 04042

REF BY : Dr. MEDIWHEEL LIFE INS

AGE : 45. Yrs. SEX : M


HAEMOGRAM WITH INDICES

Test	Result	Units	Normal Range
Haemoglobin	- 12.1	g/dl	14-18
RBC Count	- 4.55	millions / cu-mm	4.5 - 6.5
PCV	- 40.2	%	40 - 54
MCV	- 88.4	fL	80 - 96
MCH	- 26.6	Pg	27 - 33
MCHC	- 30.1	gm/dl	33 - 36
RDW CV	- 13.5	%	11.0 - 14.5
WBC Count	- 7500	/cumm	4000 - 11000
Neutrophils	- 65	%	40 - 75
Lymphocytes	- 30	%	20 - 40
Eosinophils	- 03	%	1 - 6
Monocytes	- 02	%	2-10
Basophils	- 00	%	0 - 1
Platelet Count	- 261000	/ul	150000 - 450000
MPV	- 9.0	fL	7.4 - 10.4
PDW	- 10.8	%	8-12
P-LCR	- 17.9	%	15-35
E.S.R.	- 09	mm at 1hr	0-10
(By Wintrobe Method)			
RBC Morphology	- Normochromic, Normocytic.		
WBC Morphology	- Within Normal Limits		
Platelets	- Adequate		



* Blood group - 'O' Rh Positive

Dr. Vandana G. Powar
M.B.B.S., D.C.P.



All Biochemistry Tests Done By Computerised Auto Analyser

HAEMATOLOGY | CLINICAL PATHOLOGY | BIOCHEMISTRY | SEROLOGY | MICROBIOLOGY | HISTOPATHOLOGY

24 Hours Emergency Service

Home Service Available



LAB - Shop No. 7, "Diwan Towers" Mangalwar Peth, Near Mirajkar Tikti, Opp. Nutan Marathi
High School, Kolhapur. Mob. 9158529408, 9422047480, 9921285167

PT.NAME : MR. DIPAK PATIL

REF. BY : DR. MEDIWHEEL LIFE INS

DATE : 04/04/2023

AGE : 45 Yrs. SEX : M

PT.NO. : 201 040423

BIOCHEMISTRY TEST REPORT

			<u>Normal Range</u>
Fasting Plasma Glucose	: 94.3	mg/dl	60-110 mg/dl
2 Hrs. Plasma Glucose	: 110.4	mg/dl	90-140 mg/dl
S. Creatinine	: 0.9	mg/dl	0.7 - 1.4 mg/dl
Blood Urea	: 23.1	mg/dl	12-42 mg/dl
Blood Urea Nitrogen	: 10.79	mg/dl	5 - 21 mg/dl
S. Uric acid	: 4.7	mg/dl	3.5 -7.2 mg/dl
CHOLESTEROL	: 159.0	mg/dl	0-250 mg/dl
HDL Cholesterol	: 33.1	mg/dl	30 - 70 mg/dl
S. Triglycerides	: 80.6	mg/dl	0-170 mg/dl
LDL Cholesterol	: 109.8	mg/dl	60 - 150 mg/dl
TC/HDLC Ratio	: 4.8		0 - 5
LDLC/HDLC Ratio	: 3.3		2.5 - 3.5

Dr. Vandana G. Powar
M.B.B.S., D.C.P.
* Pathologist
18137
PATHOLOGIST
HAPUR
LABORATORY
DR. VANDANA POWAR
M.B.B.S., D.C.P.

All Biochemistry Tests Done By Computerised Auto Analyser

HAEMATOLOGY | CLINICAL PATHOLOGY | BIOCHEMISTRY | SEROLOGY | MICROBIOLOGY | HISTOPATHOLOGY

24 Hours Emergency Service

Home Service Available



LAB - Shop No. 7, "Diwan Towers" Mangalwar Peth, Near Mirajkar Tikli, Opp. Nutan Marathi
High School, Kolhapur. Mob. 9158529408, 9422047480, 9921285167

PT.NAME : MR. DIPAK PATIL
REF. BY : DR. MEDIWHEEL LIFE INS

DATE : 04/04/2023
AGE : 45 Yrs. SEX : M
PT.NO. : 201 040423

BIOCHEMISTRY TEST REPORT

			Normal Range
S. Bilirubin (Total)	: 0.28	mg/dl	0 - 1.0 mg/dl
S. Bilirubin (Direct)	: 0.16	mg/dl	0 - 0.25 mg/dl
S. Bilirubin (Indirect)	: 0.12	mg/dl	0 - 0.75 mg/dl
S.G.O.T	: 27.9	IU/L	5-40 IU/L
S.G.P.T	: 18.6	IU/L	5-40 IU/L
S. Alkaline Phosphatase	: 88.0	IU/L	37 - 147 IU/L
Total Proteins	: 7.9	g/dl	6.6 - 8.3 g/dl
S. Albumin	: 4.8	g/dl	3.5 - 5.0 g/dl
S. Globulin	: 3.1	g/dl	1.5 - 3 g/dl
A/G Ratio	: 1.5 : 1		0.90 - 2.00

Dr. Vandana G. Powar
M.B.B.S., D.C.P.



All Biochemistry Tests Done By Computerised Auto Analyser

HAEMATOLOGY | CLINICAL PATHOLOGY | BIOCHEMISTRY | SEROLOGY | MICROBIOLOGY | HISTOPATHOLOGY

24 Hours Emergency Service

Home Service Available



PT.NAME : MR. DIPAK PATIL
REF. BY : DR. MEDIWHEEL LIFE INS

DATE : 04/04/2023
AGE : 45 Yrs. SEX : M
PT.NO. : 201 040423

EXAMINATION OF URINE

Normal Range

PHYSICAL EXAMINATION

Quantity	: 05 ml	
Colour	: Pale Yellow	
Appearance	: Clear	
Deposit	: Absent	
Reaction (pH)	: Acidic	
Specific Gravity	: 1.024	1.003 - 1.035

CHEMICAL EXAMINATION

Proteins	: Absent	
Glucose	: Absent	
Ketone Bodies	: --	
Bile Salts	: Absent	Absent
Bile Pigments	: Absent	Absent
Urobilinogen	: --	
Occult Blood	: Absent	

MICROSCOPIC EXAMINATION

Epithelial Cells	: 1 - 2 /hpf
Pus Cells	: 2 - 3 /hpf
Red Blood Cells	: Absent /hpf
Casts	: Absent
Crystals	: Absent
Amorphous Deposits	: Absent

OTHER FINDINGS

Yeast Cells	: Absent
Trichomonas vaginalis	: Absent
Bacteria	: Absent
Mucus Threads	: Absent
Spermatozoa	: Absent

Dr. Vandana G. Powar
M.B.B.S., D.C.P.
PATHOLOGIST
DR. VANDANA POWAR
M.B.B.S., D.C.P.

All Biochemistry Tests Done By Computerised Auto Analyser

HAEMATOLOGY | CLINICAL PATHOLOGY | BIOCHEMISTRY | SEROLOGY | MICROBIOLOGY | HISTOPATHOLOGY

24 Hours Emergency Service

Home Service Available

Dr. Vandana G. Powar M.B.B.S., D.C.P.
Consultant Pathologist



PARTH
PATHOLOGY LABORATORY
(Computerised)

LAB - Shop No. 7, "Diwan Towers" Mangalwar Peth, Near Mirajkar Tikti, Opp. Nutan Marathi
High School, Kolhapur. Mob. 9158529408, 9422047480, 9921285167

PATIENT NAME:- DIPAK PATIL

AGE -45SEX/MALE

REFERANCE= MEDIWHEEL LIFE INS.

DATE - 04/04/2023

BIOCHEMISTRY

NORMAL VALUE

S. GAMMA.G .T : 23.1 mmol/L

10-50 mmol / L

Dr. Vandana G. Powar
M.B.B.S., D.C.P.
Reg. No. 68137

PATHOLOGIST

DR. VANDANA POWAR
M.B.B.S., D.C.P.

All Biochemistry Tests Done By Computerised Auto Analyser

HAEMATOLOGY | CLINICAL PATHOLOGY | BIOCHEMISTRY | SEROLOGY | MICROBIOLOGY | HISTOPATHOLOGY

24 Hours Emergency Service

Home Service Available

Dr. Vandana G. Powar M.B.B.S., D.C.P.
Consultant Pathologist



PARTH
PATHOLOGY LABORATORY
(Computerised)

LAB - Shop No. 7, "Diwan Towers" Mangalwar Peth, Near Mirajkar Tikli, Opp. Nutan Marathi High School, Kolhapur. Mob. 9158529408, 9422047480, 9921285167

PATIENT NAME:- DIPAK PATIL

AGE -45SEX-MALE

REFERANCE= MEDIWHEEL LIFE INS.

DATE - 04/04/2023

BIOCHEMISTRY

SERUM VLDL : 20.1

NORMAL VALUE

10-50 mmol / L

Dr. Vandana G. Powar
M.B.B.S., D.C.P.,
Reg. No. 68137
PATHOLOGIST
PARTH P.O.P.
DR. VANDANA POWAR
M.B.B.S., D.C.P.

All Biochemistry Tests Done By Computerised Auto Analyser

HAEMATOLOGY | CLINICAL PATHOLOGY | BIOCHEMISTRY | SEROLOGY | MICROBIOLOGY | HISTOPATHOLOGY

24 Hours Emergency Service

Home Service Available



04/04/2023

THE ECG OF CLIENT –DIPAK PATIL
IS WITHIN NORMAL LIMIT

NO ABNORMAL FINDINGS ARE DETECTED

Dr. Vandana G. Powar
M.B.B.S., D.C.P.
Reg. No. 68137

PATHOLOGIST

DR. VANDANA POWAR
M.B.B.S., D.C.P.

All Biochemistry Tests Done By Computerised Auto Analyser

HAEMATOLOGY | CLINICAL PATHOLOGY | BIOCHEMISTRY | SEROLOGY | MICROBIOLOGY | HISTOPATHOLOGY

24 Hours Emergency Service

Home Service Available

nest

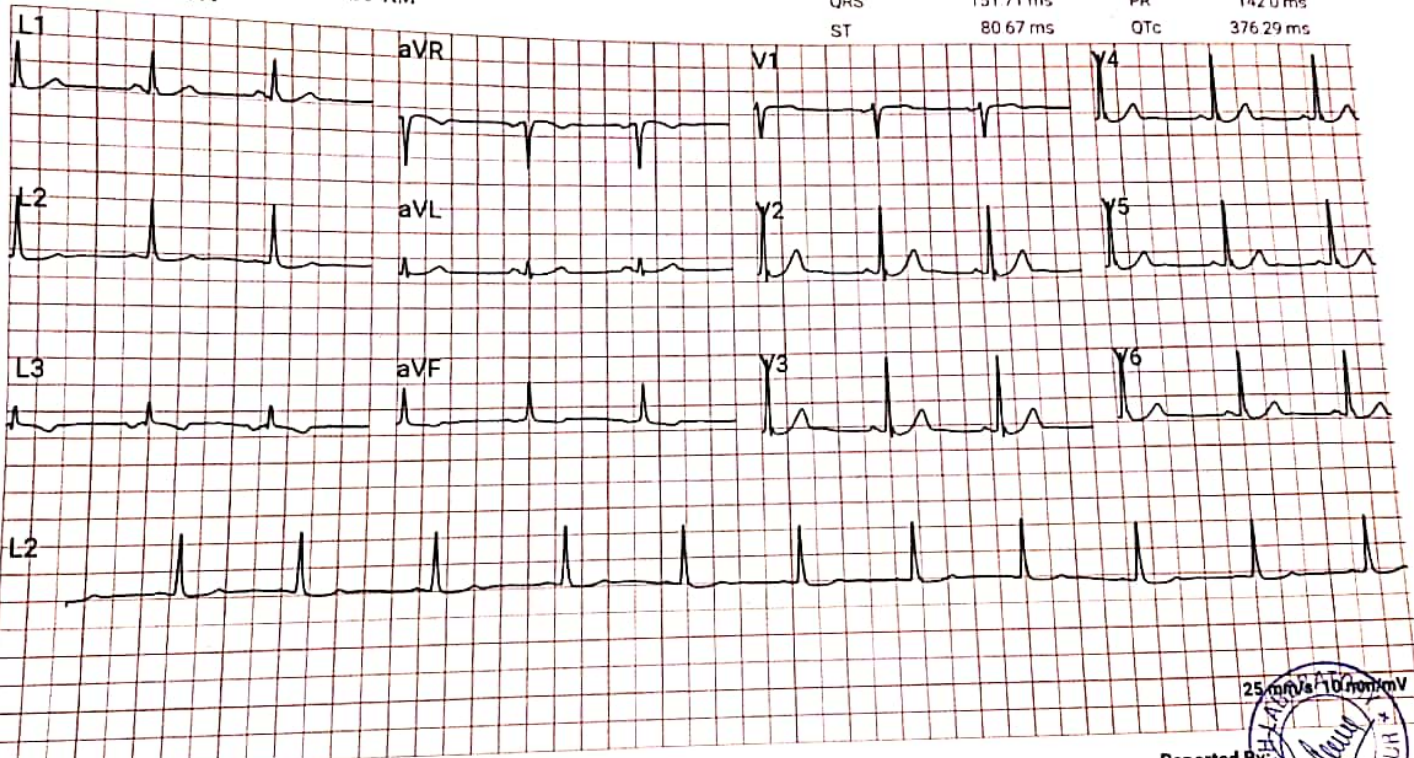
Name Dipak patil
Gender | Age 45 | Male

Date & Time 04 APRIL 2023 08:30 AM

12 lead simultaneous EC

201

Heart Rate	68 bpm	QT	360.29 ms
QRS	151.71 ms	PR	142.0 ms
ST	80.67 ms	QTc	376.29 ms



25 mm/s 10 mm/mV

Reported By
Dr. [Signature] Powar
M.B.B.S., D.C.P.
Reg No. 68137

Comments: Normal

Referred By: Dr. SHANTANU DAIKAR, MBBS, MRCGP, KOLHAPUR, MAHARASHTRA | 01 84110 70055



 GPS Map Camera

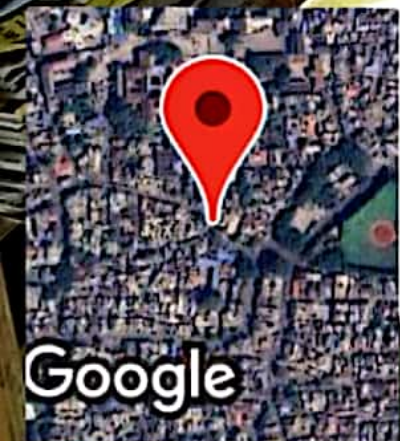Kolhapur, Maharashtra, India

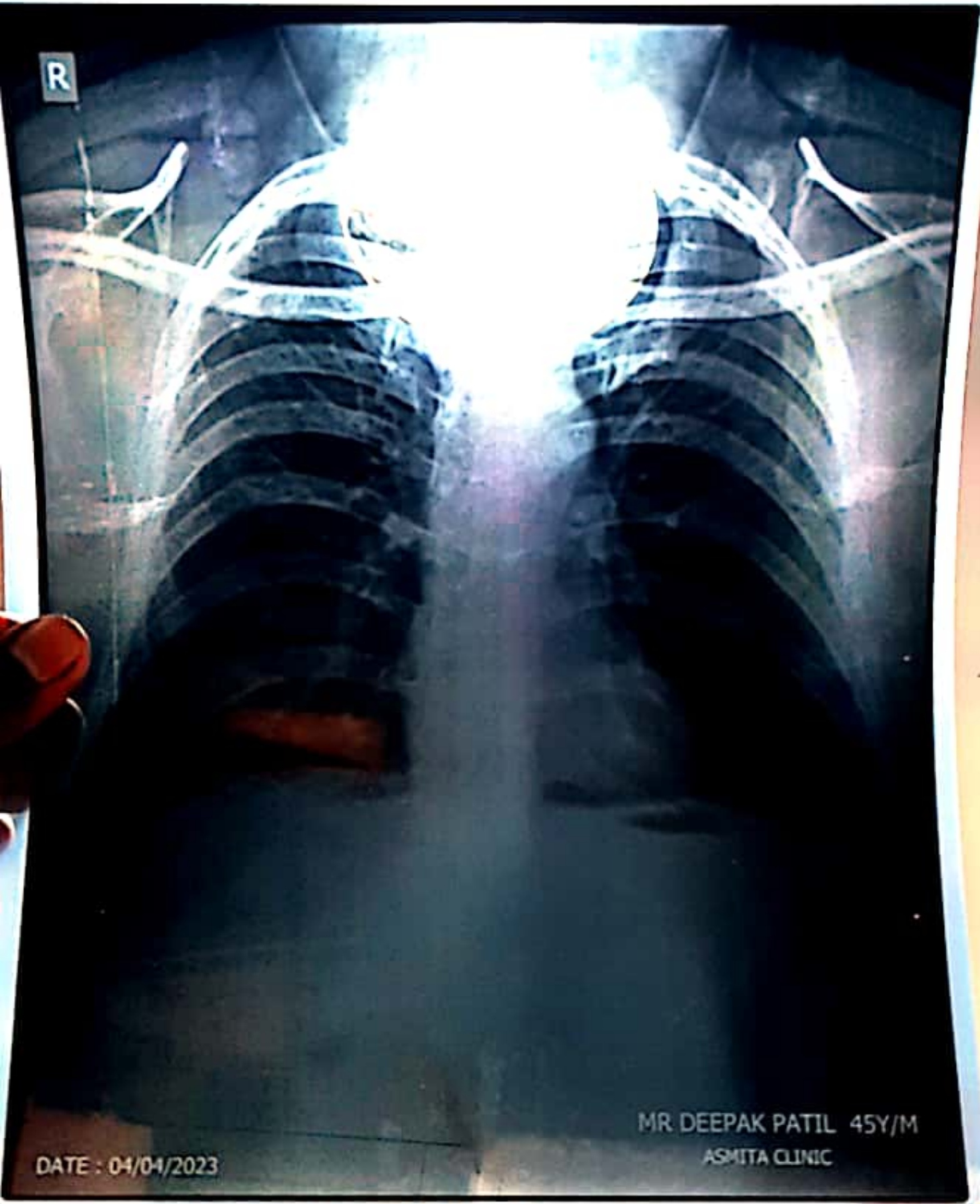
Rajghat Rd, Mangalwar Peth, C Ward, Kolhapur,
Maharashtra 416002, India

Lat 16.69282°

Long 74.224315°

04/04/23 08:48 AM GMT +05:30





DATE : 04/04/2023

MR DEEPAK PATIL 45Y/M
ASMITA CLINIC



अस्मिता क्लिनिक
आणि सोनोग्राफी सेंटर

Name : MR. DIPAK PATIL
Ref By : Dr. VANDANA POWAR

Age/Sex : 45 YEARS/M
Date : 04 Apr 2023

CHEST RADIOGRAPH

No radiological pulmonary parenchymal abnormality seen

The hilar structures are normal.

The heart size and outlines are normal.

The diaphragm contour and costophrenic angles are normal.

Bony rib cage and soft tissues of chest wall are normal.

IMPRESSION:

- Radiograph shows no significant abnormality.
- ADVICE - Clinical correlation and follow up if clinically needed.
- THANKS FOR REFERRAL.FEEDBACK IS WELCOME

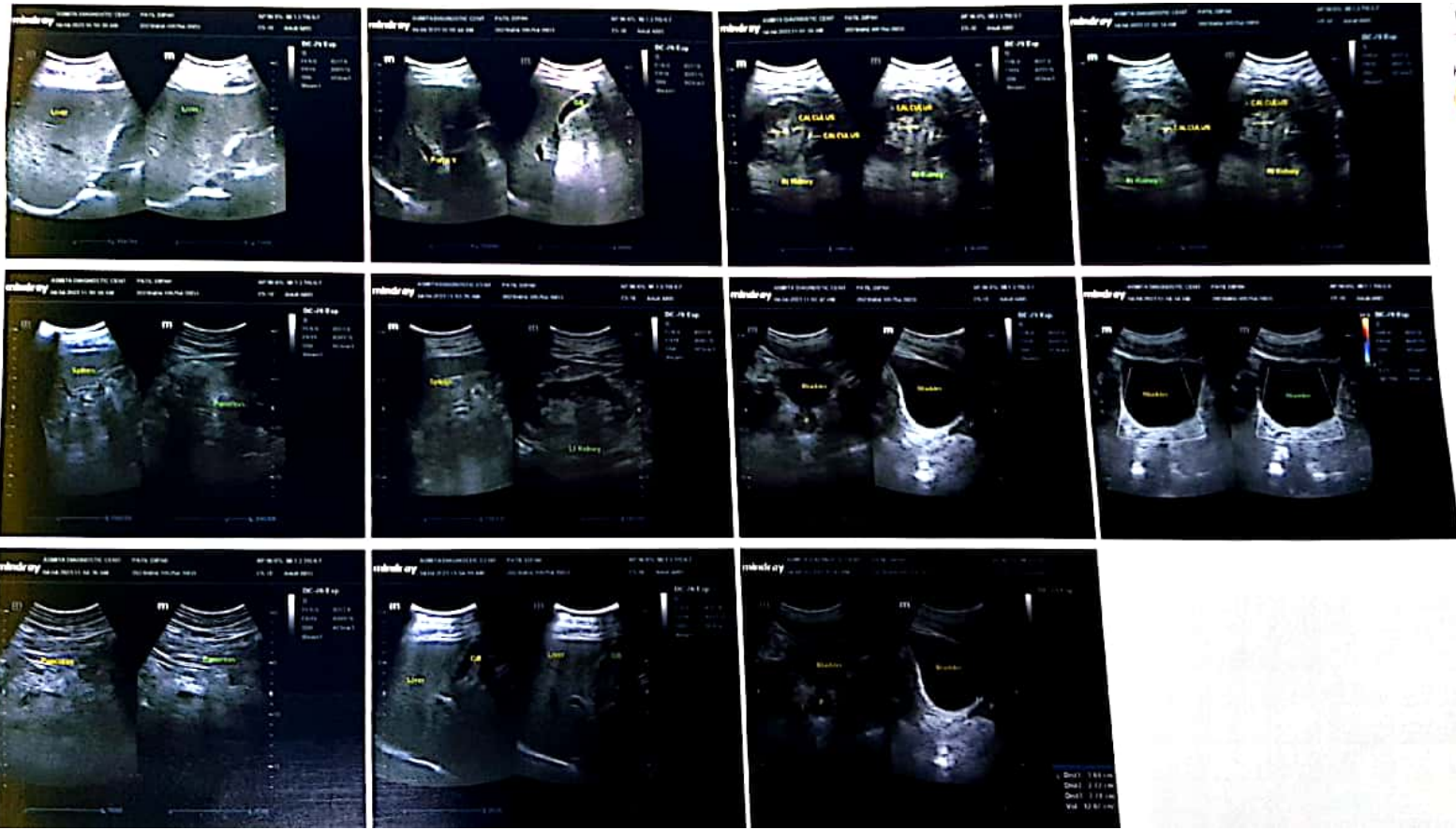
Neहा

DR. NEHA S. GHORPADE
MBBS DMRE Reg. No. 79916
Consulting Radiologist

डॉ. नेहा घोरपडे

एम. बी. बी. एस., डी.एम.आर.ई (रेडीओलॉजिस्ट)
रजि.नं.79916

परत येताना सर्व जुने रिपोर्टस्, सोनोग्राफी रिपोर्टस् अथवा एक्स-रे असल्यास बरोबर घेऊन येणे.



डॉ. बी. जी. जाधव-ढेकळे

एम. बी. बी. एस.
(जनरल फिजिशियन)

डॉ. नेहा घोरपडे

एम. बी. बी. एस., डी.एम.आर.ई
कन्सल्टिंग रेडीओलॉजिस्ट



अस्मिता क्लिनिक
आणि सोनोग्राफी सेंटर

१००४/३३/२. फिरंगाई देवळासमोर, शिवाजी पेठ, कोल्हापूर - ४१६०१२.

Ph. : (0231) 2621071 | E mail: asmitadiagno.neha@gmail.com

Patient Name : MR. DIPAK PATIL
Referred By : Dr. VANDANA POWAR

Date : 04 Apr 2023
Age : 45 YEARS Sex : M

Clinically - For Health check up.

Abdomen Sonography

LIVER : is normal in size, shape, position and shows increased echogenicity. The contours are smooth. The parenchyma shows homogeneous echotexture. The intra - hepatic portal and venous system appears normal. The portal vein is normal and show hepatopetal flow. The intra-hepatic biliary radicals are not dilated. There is no focal mass lesion.

GALL BLADDER: is physiologically distended, normal in size and echotexture. There is no evidence of echoreflexive calculus in gall bladder. There is no abnormal biliary tree dilation noted. The portal vein & C.B.D appear normal. Wall thickness is normal. No e/o cholecystitis/calculus seen. PV measures - 11 mm, CBD measures - 3 mm.

PANCREAS: is normal size, position & echotexture. The contours are smooth. There is no focal mass lesion seen. No pancreatitis or calcification.

SPLEEN: is normal in size, shape and echopattern. The contours are smooth. The splenic vein and portal vein are normal in calibre.

KIDNEYS: Both the kidneys are normal in size, shape and position and contours. There is no echoreflexive obstructing calculus seen on left side, no hydronephrosis. Both visualized ureters appear to be normal. Parenchymal/cortical thickness is normal. Cortico - medullary differentiation is well maintained. Overlying bowel gases does not show further course of ureter.

Right kidney measures - 104 x 45 mm. **Right kidney** shows few tiny calculi in all poles, of average size 3 - 4 mm. **Left kidney** measures - 114 x 53 mm.

Urinary bladder is physiologically distended, appears normal. No intraluminal abnormality. Pre void volume is - 535 ml, Post void residue is - 7 ml.

PROSTATE: is normal size and uniform echotexture, measures 30 x 27 x 27 mm (weight - 12 gms). The gland bulges urinary bladder base.

Aorta and IVC are normal. No e/o free fluid in peritoneal cavity. No ascites. No significant lymphadenopathy. Bowel loops appear normal in size with good peristalsis.

Appendix is not appreciated in today's study. Terminal ileum is well seen. No probe tenderness in right iliac fossa or anywhere in abdomen.

IMPRESSION : < FATTY LIVER-GRADE 1.
< TINY RIGHT RENAL CALCULI.

ADVICE - Clinical correlation and follow up if clinically needed.
THANKS FOR REFERRAL, FEEDBACK IS WELCOME

Neaha

DR. NEHA S. GHORPADE
MBBS DMRE Reg. No. 79916
Consulting Radiologist

परत येताना सर्व जुने रिपोर्ट्स, सोनोग्राफी रिपोर्ट्स अथवा एक्स-रे असल्यास बरोबर घेऊन येणे.

डॉ. नेहा घोरपडे

एम. बी. बी. एस., डी.एम.आर.ई (रेडीओलॉजिस्ट)
रजि.नं. 79916