



# PARKLINE DIAGNOSTICS PVT. LTD.

L.G. 3, 4 & 5, Bhuvana Towers, S.D. Road, Secunderabad - 500 003.

Tel : +91 40-2784 5852, 6649 1787, 7995421787, 7093445852, Fax : +91 40 2784 7864

Email parklinediagnostics@gmail.com www.parklinediagnostics.com



NABL Accredited  
Certificate No.MC-2566

## MEDICAL EXAMINATION REPORT

Name	Mr. Gangaram Kishore		Date :	01/02/2022	
Company	C/O: mediwheel		Reg. No. :	1759178	
Contact No.	9985997649		Sex	<input checked="" type="checkbox"/> M	Age : <input type="checkbox"/> 33
Type	Pre-Emp		Emp. No.:	96292	
	Overseas		Height	160 cm	
	Annual	<input checked="" type="checkbox"/>	Weight	66 kg.	
Remarks					
Fitness Status	Medically Fit / Unfit		Physician's Signature		

# COMPREHENSIVE MEDICAL EXAMINATION REPORT

NAME Mr. Gangaram Kishore  
 AGE 33 yrs / Male  
 MARITAL STATUS Married CHILDREN: M  F   
 IDENTIFICATION (IF ANY) A mole on the (R) Hand.



## PAST HISTORY

Any family H/o : High Blood Pressure, Heart Disease, Tuberculosis, Diabetes, Asthma, Cancer

<sup>CWA Late father</sup>   <sup>Father</sup>

Any personal H/o Major illness like : Typhoid..... NIL Jaundice..... NIL Etc.

Any H/o STD..... NIL Skin infection..... NIL

H/o Blood Transfusion..... NIL Recent Vaccination..... COVASHIELD 2 doses ✓

H/o Epilepsy..... NIL Giddiness..... NIL (occasional)

H/o Surgery..... NIL Fracture in the past..... NIL

### Any Personal H/O.

High Blood Pressure, Heart Disease Tuberculosis, Diabetes, Asthma, Cancer

Drug Abuse, Drug Allergy, Micturition, Bowels, Alcohol, Smoking, Sleep, MC, Wt. Loss/Wt. Gain

Present illness / Medication

## GENERAL EXAMINATION

Conjunctiva :  
 Skin :  
 Ears :  
 Nose :  
 Throat & Oral Cavity :

NAD

Bone, Joints : (N)  
 Nutritional Status : Well Nourished  
 Lymph Nodes : NPD  
 Edema Feet : NIL  
 Varicose Veins : NIL

**Distant Vision : Near Vision :**

Right Eye: 9/12 - 1.50 sph 6/6

Right Eye: NB

With glasses / Without glasses

With glasses / Without glasses

left Eye: 9/18 - 2.0 sph 6/6

left Eye: NB

with glasses / without glasses

with glasses / without glasses

Colour Vision: DE normal

**DR. KATTA**  
M.B.B.S., D.O., F.C.S.  
**Ophthalmologist's Signature**

**Right Ear**

**Left Ear**

Hearing: (N)

(N)

Rinne's Test ;

Weber Test :

Discharge : NIL

NIL

**SYSTEMIC EXAMINATION**

Pulse : 86 bpm

B.P. : 120/90 mmHg

Lungs : A. Shape of Chest R/L symmetrical  
B. Breath Sounds R/L - clear ⊕  
C. Adventitious Sounds NO

Heart : A. Sounds S<sub>1</sub> S<sub>2</sub> ⊕  
B. Murmurs NO murmurs

**Nervous System**

Abdomen : A. Liver NP  
B. Spleen NP  
C. Piles NIL  
D. Any Lump NO

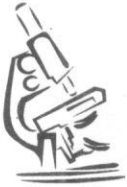A. Higher Function :  
B. Cranial Nerves :  
C. Sensory System :  
D. Motor System :  
E. Jerks :  
(N)

General : A. Hernia  
B. Hydrocele  
C. Varicocele  
(N)

Breast : Rt — Lt. —







# PARKLINE DIAGNOSTICS PVT. LTD.

L.G. 3, 4 & 5, Bhuvana Towers, S.D. Road, Secunderabad - 500 003. Tel : +91 40-2784 5852, 6649 1787, 7995421787, 7093445852, Fax : +91 40 2784 7864 Email parklinediagnostics@gmail.com www.parklinediagnostics.com



NABL Accredited  
Certificate No.MC-2566

## ENT CONSULTATION

S.No. 1759178 Emp.No. \_\_\_\_\_ Date 01/02/2022

Name Ms. Gangaram kishore Age 33 Yrs Sex M/F

### EARS :

Right

Left

EAC : patent no Cerumen. -do-

TM : Intact, pearly white. -do-

TFT : Cone of light (+)  
Rinne's +ve Rinne's +ve.  
Weber's - Central

NOSE : Septum - (N), Bil. Turbinate: (N), Pass - (N), non-tender

THROAT : Oropharynx: (N), Bil. vocal cords: (N) swallowing

NECK : (N) Asymmetry: Nil.

IMPRESSION: EART clinically NAD.



  
 Dr. D. Hanu Krishna Reddy  
 MS (ENT)  
 Head & Neck Surgeon  
 Reg. No: 88379

Name : ..... Kishore ..... Sex : ..... M ..... Age : ..... 33 .....

Date : ..... 1/02/22 .....

OPD No : ..... 416 .....

*Di*  
 adv scaling,  
 enamel cosmes  
 w.r.t / 6

**Smileless**    
 MULTI SPECIALITY DENTAL CLINIC  
*Smile Confidentially... No Compromises...*  
 B.D.S, IMPLANTOLOGIST (USA)  
 1-3-1, Rajamudaliar Street, K. J. Somayajulu  
 Secunderabad, Telangana

--	--	--	--	--	--

--	--	--	--	--	--





# PARKLINE DIAGNOSTICS PVT. LTD.

L.G. 3, 4 & 5, Bhuvana Towers, Sarojini Devi Road, Secunderabad - 500 003 Tel. +91 40-2784 5852  
6649 1787 Fax :+91 40 2784 7864 Email : parklinediagnostics@gmail.com www.parklinediagnostics.com



NABL Accredited  
Certificate No. MC-2566

## TEST REPORT

Name : Mr . GANGARAM KISHORE [96292]  
Age / Gender : 33 Years / Male  
Ref.By : Medi Wheel  
Req. No : BIL1759178

TID : UMR0699861  
Registered on : 01-Feb-2022 08:55 AM  
Reported On : 01-Feb-2022 12:49 PM

### DEPARTMENT OF ULTRASOUND Ultrasound Whole Abdomen

**LIVER** : Normal in size (13.9 cms) and echotexture. No focal lesions.

No IHBD /CBD dilatation. Portal vein is normal.

**SPLEEN** : Normal in size and echotexture. No focal lesion seen.

**GALL BLADDER** : Well distended. No sludge / gall stones / sol.  
Gall bladder - Wall thickness is normal.  
No pericholecystic oedema.

**PANCREAS** : Normal in size and echotexture.No calcification / sol.  
Pancreatic duct is normal. No peripancreatic fluid collection.

**RIGHT KIDNEY** : Measures : 10.8 x 4.5 cms  
Normal in size and echotexture.  
Cortical thickness is normal.  
No evidence of calculi / sol.  
Pelvi calyceal system is normal.

**LEFT KIDNEY** : Measures : 9.7 x 4.4 cms  
Normal in size and echotexture.  
Cortical thickness is normal.  
E/o calculus measuring 4.5 mm noted in the mid pole  
Pelvi calyceal system is normal.

**URINARY BLADDER** : Well distended.Normal in contour.  
Wall thickness is normal. No calculus / sol.

**PROSTATE** : Normal in size and echotexture. Measures : 2.3 x 3.1 x 3.1 cms. Volume 12 cc  
No calcification / sol.

The Test marked with\*are not accredited by NABL

Lab Timings (Weekdays) : 7.00 am to 8.30 pm

Sundays & Holidays : 7.00 am to 1.00 pm

Radiologists Timings (Weekdays) : 7.30 am to 1.30 pm  
& 5.30 pm to 7.45 pm

Sundays & Holidays : 7.30 am to 9.30 am



# PARKLINE DIAGNOSTICS PVT. LTD.

L.G. 3, 4 & 5, Bhuvana Towers, Sarojini Devi Road, Secunderabad - 500 003 Tel. +91 40-2784 5852  
6649 1787 Fax :+91 40 2784 7864 Email : parklinediagnostics@gmail.com www.parklinediagnostics.com



NABL Accredited  
Certificate No. MC-2566

## TEST REPORT


Name : Mr . GANGARAM KISHORE [96292]  
Age / Gender : 33 Years / Male  
Ref.By : Medi Wheel  
Req. No : BIL1759178

TID : UMR0699861  
Registered on : 01-Feb-2022 08:55 AM  
Reported On : 01-Feb-2022 12:49 PM

No pre or para aortic adenopathy / ascites noted.

**IMPRESSION : Non obstructive left renal calculus.**

Clinical correlation

  
Dr. Abid Yazden  
Consultant Radiologist

The Test marked with\* are not accredited by NABL

Lab Timings (Weekdays) : 7.00 am to 8.30 pm

Sundays & Holidays : 7.00 am to 1.00 pm

Radiologists Timings (Weekdays) : 7.30 am to 1.30 pm  
& 5.30 pm to 7.45 pm

Sundays & Holidays

: 7.30 am to 9.30 am





# PARKLINE DIAGNOSTICS PVT. LTD.

L.G. 3, 4 & 5, Bhuvana Towers, Sarojini Devi Road, Secunderabad - 500 003 Tel. +91 40-2784 5852  
6649 1787 Fax :+91 40 2784 7864 Email : parklinediagnostics@gmail.com www.parklinediagnostics.com



NABL Accredited  
Certificate No. MC-2566

## TEST REPORT

Name : Mr . GANGARAM KISHORE [96292]  
Age / Gender : 33 Years / Male  
Ref.By : Medi Wheel  
Req. No : BIL1759178

TID : UMR0699861  
Registered on : 01-Feb-2022 08:55 AM  
Reported On : 01-Feb-2022 09:57 AM

### DEPARTMENT OF X-RAY X-Ray Chest PA View

Lung fields are clear.

Cardia is normal.

Hila are normal.

C P angles are free.

Bony cage is normal.

Soft tissues are normal.

**IMPRESSION** : NORMAL CHEST XRAY.

  
Dr. D.J. MOHAN  
MD DMRD  
(Reg No. 8995)  
Consultant Radiologist

The Test marked with\*are not accredited by NABL

Lab Timings (Weekdays) : 7.00 am to 8.30 pm  
Sundays & Holidays : 7.00 am to 1.00 pm

Radiologists Timings (Weekdays) : 7.30 am to 1.30 pm  
& 5.30 pm to 7.45 pm  
Sundays & Holidays : 7.30 am to 9.30 am

Page:1 of 1



ID: 1759178      01-02-2022 09:15:36 AM  
MR.GANGARAM KISHORE  
Male 33Years

CARDIART

HR : 72 bpm  
P : 104 ms  
PR : 152 ms  
QRS : 72 ms  
QT/QTc : 369/405 ms  
P/QRS/T : 46/-10/-3 °  
RV5/SV1 : 1.680/1.158 mV

NSR  
NJC

(8)  
Dr. NAVEEN KUMAR .C  
M.D., D.M.  
Consultant Cardiologist  
Reg. No. 52291

Diagnosis Information:  
Sinus Arrhythmia  
\*\*\*Normal ECG\*\*\*

Report Confirmed by:



PATIENT SUMMARY REPORT

INE DIAGNOSTICS PVT.LTD

: 1759178  
: MR GANGARAM KISHORE  
SEX : 33 / MALE

HEIGHT (cm) : 160  
WEIGHT (kg) : 66  
PROTOCOL : BRUCE

REF. BY : MEDIWHEEL  
DONE BY : DR NAVEEN KUMAR C  
TECHNICIAN : G.M.SURESH

2022, 09:14:..

HISTORY :

ATION :

T OF TEST : Routine Check Up.

ACTOR : None.

TY : Very Active.

INVESTIGATION : E C G

IN FOR TERMINATION : THR ACHIEVED

ISE TOLERANCE : Good (> 10 METS).

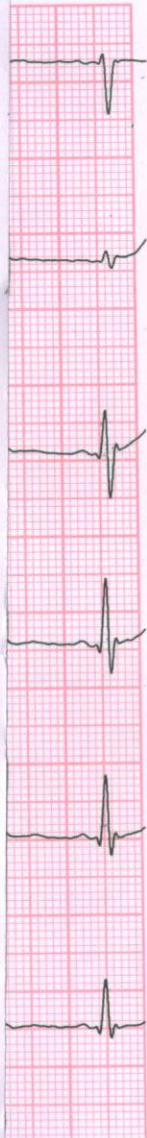
ISE INDUCED ARRHYTHMIAS : No.

Y RESPONSE : Normal.

NO RESPONSE : Normal.

IMPRESSION :

OMMENTS : *Negative for inducible ischemia*



**Dr. NAVEEN KUMAR .C**  
M.D., D.M.  
Consultant Cardiologist  
Reg. No. 52291

Confirmed By : \_\_\_\_\_

Signature