

Email - Your Apollo order has been confirmed

Anand Rajaji Medical Centre rammedicalreporting@gmail.com

12/9/23, 9:08 AM



Your Apollo order has been confirmed
3 messages

nareddy@apollohospitals.in nareddy@apollohospitals.in
To: rammedicalreporting@gmail.com
Cc: rammedicalreporting@gmail.com, praveen.parkash@apollohospitals.com, spandanar.m@apollohospitals.com, deepak.goktam@apollohospitals.com, raaj.g@apollohospitals.com, anand.raajaji@apollohospitals.com, shilpa.k@apollohospitals.com

Greetings from Apollo!!!

Respected Sir/Madam,

Please find corporate HC appointment details scheduled for 12-12-2023 of your ANANDRAJAJI MEDICAL CENTRE LLP - Pune Center

Points to note:-

- Collect photograph of employee & proof of health check is through an employee
- Collect photograph of personal ID proof & health check is for insurance.
- Collect MTH as per package details & final company's format (already shared)
- By 12 noon of appointment date, share Work order number & visit status (Show/No show)
- Upload reports in Apollohub portal as per specifications given earlier

| Company Name | Employee Name | Age | Gender | Referral | Appointment Date | Time | Room No. | Specialist |
|----------------------------|---|-----|--------|----------|------------------|-------|----------|------------|
| ARCOFEM HEALTHCARE LIMITED | ARCOFEM MEDWHEEL - FULL BODY MEDWHEEL HEALTH FEMALE ANNUAL CREDIT PAN PLUS INDIA OP CHECK - AGREEMENT FEMALE - 2D ECHO - PAN INDIA - FY2324 | 30 | Female | Self | 12-12-2023 | 08:30 | N/A | NA |

| Tests |
|---|
| Glycated Hemoglobin (HbA1c) - Whole |
| Blood ECG Package |
| Gynaecological Consultation, HEMOGRAM (CBC+ESR), X-Ray Chest PA, Digital by General Physician, EAR URINE GLUCOSE, (POST PRANDIAL) [Consultation - Dental Package Consultation - ENT Fitness by General Physician, 2D ECHO Lipid Profile (all Parameters), Renal Function Test, Ultrasound - Whole Abdomen URINE GLUCOSE (FASTING), Dietician consultation, GLUCOSE - SERUM / PLASMA (FASTING AND POST PRANDIAL, Blood Grouping And Typing (Abo And Rh), THYROID PROFILE - (T3, T4 AND TSH), LIVER FUNCTION TEST (PACKAGE), Urine Routine (CUE), GGTP: Gamma Glutamyl Transpeptidase - Serum, LBC PAP SMEAR, Doctor, GAMMA GLUTAMYL TRANSFERASE (GGT), GLUCOSE, FASTING, GLUCOSE, POST PRANDIAL (PP), 2 HOURS (POST MEAL), RENAL PROFILE, RENAL FUNCTION TEST (RFT, KFT), LIPID PROFILE, PERIPHERAL SMEAR, BLOOD GROUP ABO AND RH FACTOR, DIET CONSULTATION, BODY MASS INDEX (BMI), LBC PAP TEST, PAPSURE, HEMOGRAM + PERIPHERAL SMEAR, HbA1c, GLYCATED HEMOGLOBIN, THYROID PROFILE (TOTAL T3, TOTAL T4, TSH), LIVER FUNCTION TEST (LFT), COMPLETE URINE EXAMINATION |



31223090015
150N] KA PRITAP SINGH (EDTA)
09-12-2023 09:05:00 27/F
HEPIC BLOOD GROUP, 2D Echo, ECG, Ultras

- Fasting Blood tests ✓
- ECG ✓
- X-ray ✓
- USG A+P ✓
- PAP smear (stop) ✓
- 2D Echo ✓
- Dental ✓
- MERU ✓
- Urine routine ✓

(Signature)

Please login to ANCN Portal for more details.
ANCN Login Url : [Click on Link](#)
Regards,
Team Clinic Operations
Apollo Health and Lifestyle Ltd.,

| | | | | |
|-------------------------------|-----------------------------------|------------|----------------------|-----------|
| PATIENT NAME: | Mrs Monica Pratak | | DATE: | 09/12/23. |
| AGE | YRS | SEX- | 27 female. | |
| HEIGHT- | cms | WEIGHT- KG | BP- | mmhg |
| | 156 | 52.9 | 100/60 mm Hg. | |
| RIGHT EYE | LEFT EYE- | | color vision - (C) | |
| | vision - 20/40 | | - external app - (N) | |
| PAST HISTORY- | L - Lump removal - amput - 2020 | | | |
| PRESENT COMPLAINTS- COMPLAINT | - back pain, lump on leg cervical | | | |

CNS }
 CVS } (C)
 R.S. }
 P.A. }

F/H
 F } Healthy
 M }

UNFIT

FIT WITH RECOMMENDATION



Doctors Stamp & Signature

Dr. Pushyalakshmi Challa
 MD Physician
 Reg. No. 60430
 Per. Reg. No. 1811070027

ANANDRISHIJI MEDICAL CENTRE
DENTAL DEPARTMENT

Date: 9/12/2023

Patient's Name: Monika

Age: 27 Sex: Male / Female Date of Birth: 20/07/96

Address: Pargan, Khandala, Pune

Occupation: Housewife Phone: Resi: _____ Mob: 8210810602 Mob 2: _____

Email: monikak072096@gmail.com Blood Group: B+ve

Medical History: I have / Had following:

- | | | |
|---------------------------------------|---|---|
| Drug Allergy <input type="checkbox"/> | Heart Attack <input type="checkbox"/> | Abnormal bleeding <input type="checkbox"/> |
| Diabetes <input type="checkbox"/> | Jaundice <input type="checkbox"/> | Pregnancy/Breast feeding <input type="checkbox"/> |
| Anaemia <input type="checkbox"/> | Fits/epilepsy <input type="checkbox"/> | Rheumatic fever <input type="checkbox"/> |
| Medication <input type="checkbox"/> | Blood pressure <input type="checkbox"/> | Kidney Disease <input type="checkbox"/> |

Nil {

Stains - ++

Calculus - +++

If age of patient is below 18 years Name of guardian: _____

CHIEF COMPLAINT: _____



Preferred Mode of Payment

- Cash Card Net Banking Cheque

You
toda...



7122309005
 MONIKA PRATAP SINGH (PLASMA F
 09-12-2023 09:05:00 27/F
 RES. #88

Date: 09/12/2023

To,
AHCN team,

Sub: Health check of Mrs. Monika Singh.

Dear Sir/Madam,

Mrs. Monika visited the centre for the health check up dated 09/12/2023. However due to her personal reasons, she wants to eliminate pathology test and PAP smear. However, we are submitting the clarification letter signed & stamped by the client.



Authorised Sign.

Patient name: Monika Singh / 27y
Patient ID: 6acaf97a-dc6f-4684-ab1b-c3111817200b

09.12.2023 10:03:48
Standard 12-Lead

ANAND RIDDI MEDICAL CENTER
PUNE

Age: Gender: female
Height: Weight: Understand
Etiology: Prevalence: Uncommon
Medication: Order ID: Ord. prev: Ord. prev:



HR: 81 bpm
P axis: 12°
QRS axis: 48°
T axis: 18°

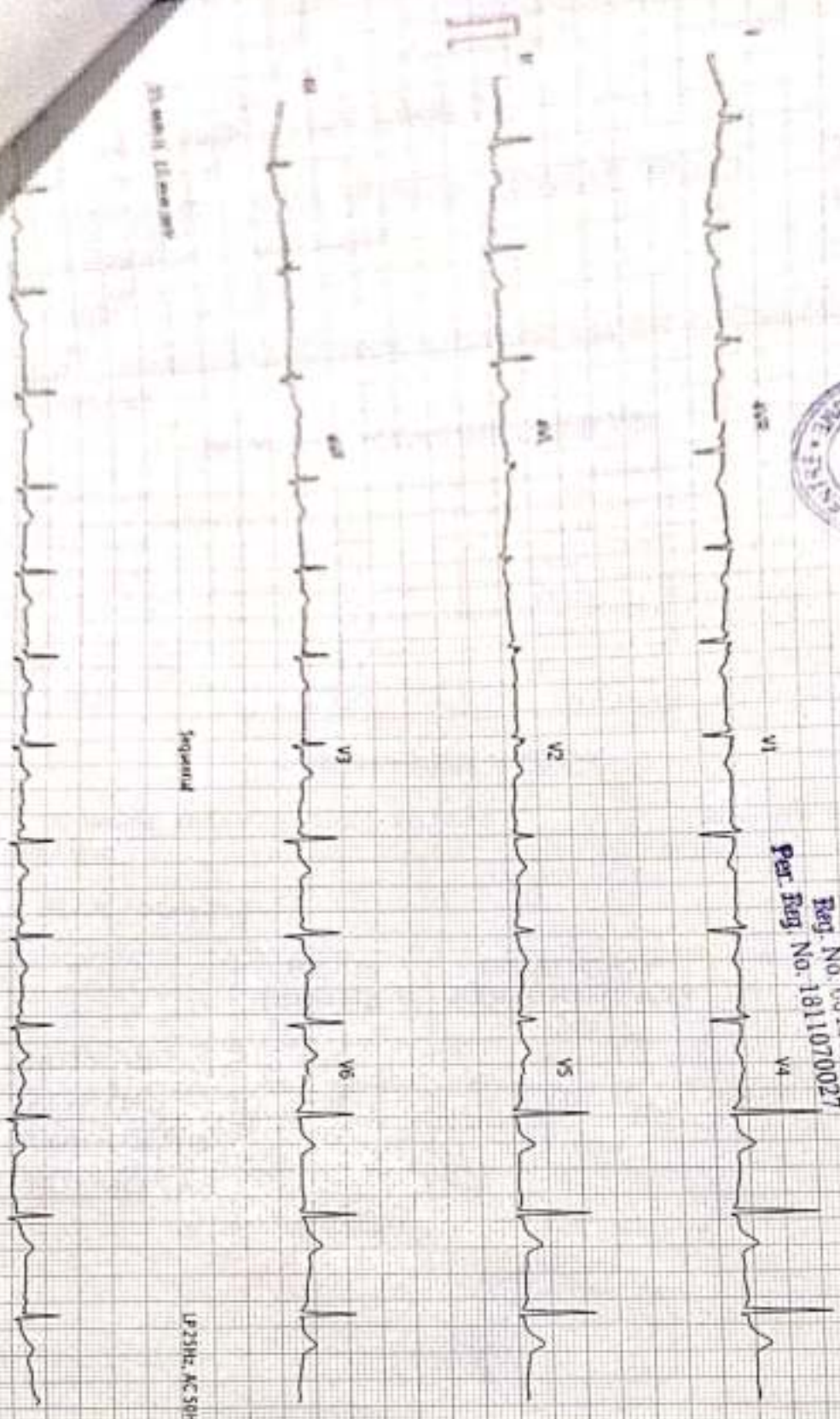
PR: 741 ms
QR: 69 ms
QT: 92 ms
QTc: 77 ms
QTcB: 381 ms
QTcB: 419 ms

Sinus rhythm
Normal electrical axis
R/S transition shift to right
Otherwise normal ECG
Unconfirmed report

Dr. Poojapalaksimi Challa
MD Physician

Reg. No. 604150
Per. Reg. No. 1811070027

axis - 12°
axis - 48°
axis - 18°



25 mm/s (1.25 sec/div)

Standard

1P 25Hz, AC 50Hz

1P 25Hz, AC 50Hz



PATIENT'S NAME: MRS. MONIKA PRATAP SINGH
REF. CLINICIAN : APOLLO

AGE : 27
DATE : 9-Dec-23

**2 DIMENSIONAL ECHOCARDIOGRAPHY & COLOUR DOPPLER
REPORT**

M-MODE MEASUREMENTS:

| | | |
|----------|----|----|
| LA | 25 | mm |
| AO root | 22 | mm |
| LVID(d) | 37 | mm |
| LVID (s) | 21 | mm |
| IVS (d) | 11 | mm |
| LVPW (d) | 11 | mm |
| LVEF | 60 | % |

DOPPLER STUDY:

E wave velocity: 0.55 m/sec
m/sec

A wave velocity: 0.47

E/A ratio > 1

| | PEAK (mmHg) | GRADE OF REGURGITATI ON |
|---------------|-------------------------|--|
| MITRAL | N | Trivial |
| AORTIC | 9 | NIL |
| TRICUSPID | N | Trivial |
| PULMONAR Y | N | Nil |



P.T.O

**2 DIMENSIONAL ECHOCARDIOGRAPHY & COLOUR DOPPLER
REPORT**

COMMENTS:

- No LV regional wall motion abnormality at rest.
- Normal resting LV systolic function. LVEF = 60%.
- Normal LV diastolic function.
- Normal chamber dimensions. No LA/LV enlargement.
- Mitral valve normal. Trivial mitral regurgitation.
- Annulo-papillary apparatus appears intact.
- Aortic valve - is trileaflet.
- Structurally normal tricuspid valve. Trivial TR.
PASP by TR jet 25 mmHg. No pulmonary hypertension.
- Normal RV systolic function. IVC normal. IAS & IVS are intact.
- No LV clot/thrombus/pericardial effusion/ vegetation.

SUMMARY:

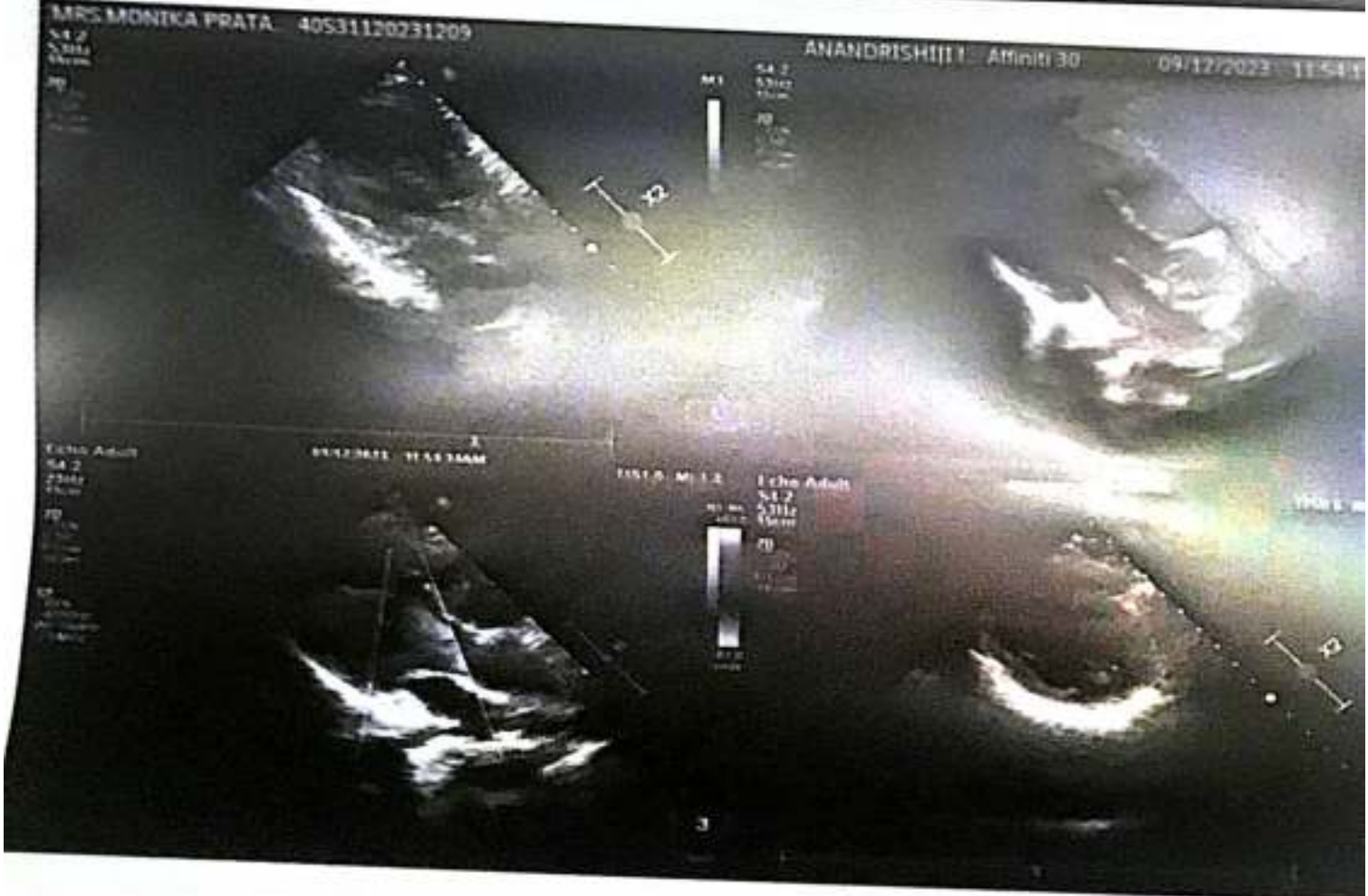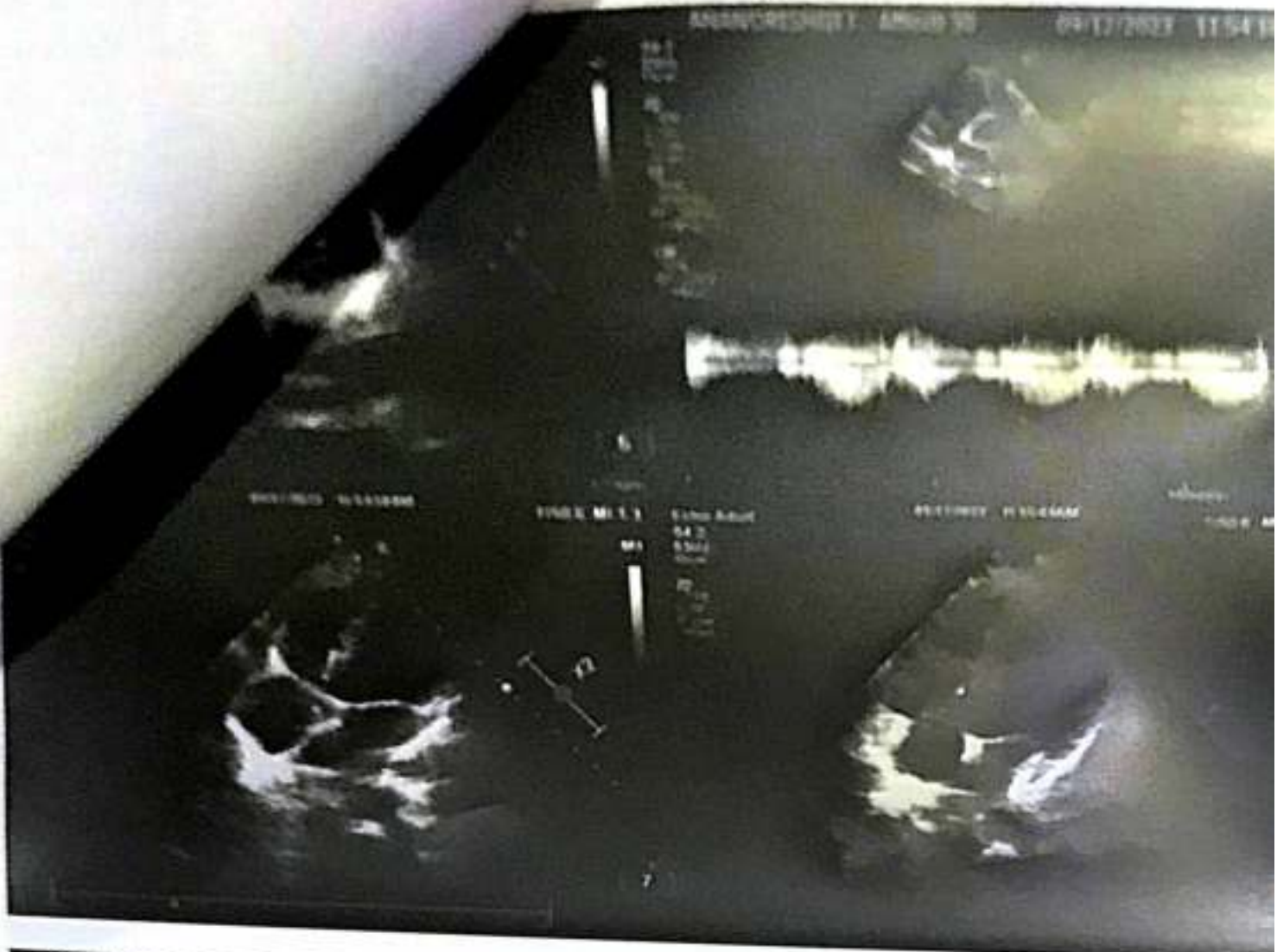
- Normal LV systolic function. LVEF=60%
- No Regional wall motion abnormality at rest.
- Normal LV diastolic function.
- No pulmonary hypertension. IVC- normal



Dr. Nikhil Raut
M.D(Medicine). D.M(Cardiology)

Nikhil Raut
(MED.), DM Cardiology
Reg. No. 2008/04/1568





| | | | |
|---------------------------------------|-------------------|---------|------------|
| PATIENT'S NAME | MRS. MONIKA SINGH | AGE/SEX | 27Y/FEMALE |
| REF BY | HEALTHLEDGER | DATE : | 9-Dec-23 |
| ULTRASONOGRAPHY OF ABDOMEN AND PELVIS | | | |

Liver appears normal in size, shape and shows normal parenchymal echopattern. IHBR & IHPR appear normal. Portal vein and Common bile duct are normal in course and caliber. No focal lesion is seen.

Gall bladder is optimally distended with a normal wall thickness and there are no calculi seen in it. No pericholecystic collection seen.

Visualized Pancreas appears normal in size and echotexture. No focal lesion seen.

Spleen is normal in size, shape. No focal lesion seen.

Right Kidney appears normal in size (10.7 X 3.3 cm), shape and echo pattern with maintained C-M differentiation. No obvious hydronephrosis or calculus.

Left Kidney appears normal in size (9.7 X 3.2 cm), shape and echo pattern with maintained C-M differentiation. No obvious hydronephrosis or calculus.

Urinary bladder is optimally distended and is normal in shape and contour. No intrinsic lesion or calculus is seen in it.

Uterus measures 6.7 x 3.0 x 3.4 cms appears normal in size, shape & echo pattern. Endometrial echo-complex appears normal (measures 6.8 mm). No focal lesion seen.

Both ovaries appear normal in size, shape & echo pattern.

No obvious lymphadenopathy / free fluid noted in the abdomen.

Visualized bowel loops appear normal in caliber and shows normal peristalsis.

IMPRESSION:

***No significant abnormality detected at present scan.**

Thanks for reference with regards.


DR. RUTUJA DOSHI.
MBBS, DMRE
Consultant Radiologist.

ANANDRISHIJI
MEDICAL CENTRE

| | | | |
|--|-------------------|-----------------|------------|
| PATIENT'S NAME | MRS. MONIKA SINGH | AGE/SEX | 27Y/FEMALE |
| REF BY | HEALTHLEDGER | DATE : 9-Dec-23 | |
| ULTRASONOGRAPHY OF ABDOMEN AND PELVIS | | | |

Liver appears normal in size, shape and shows normal parenchymal echopattern. IHBR & IHPR appear normal. Portal vein and Common bile duct are normal in course and caliber. No focal lesion is seen.

Gall bladder is optimally distended with a normal wall thickness and there are no calculi seen in it. No pericholecystic collection seen.

Visualized Pancreas appears normal in size and echotexture. No focal lesion seen.

Spleen is normal in size, shape. No focal lesion seen.

Right Kidney appears normal in size (10.7 X 3.3 cm), shape and echo pattern with maintained C-M differentiation. No obvious hydronephrosis or calculus.

Left Kidney appears normal in size (9.7 X 3.2 cm), shape and echo pattern with maintained C-M differentiation. No obvious hydronephrosis or calculus.

Urinary bladder is optimally distended and is normal in shape and contour. No intrinsic lesion or calculus is seen in it.

Uterus measures 6.7 x 3.0 x 3.4 cms appears normal in size, shape & echo pattern. Endometrial echo-complex appears normal (measures 6.8 mm). No focal lesion seen.

Both ovaries appear normal in size, shape & echo pattern.


No obvious lymphadenopathy / free fluid noted in the abdomen.

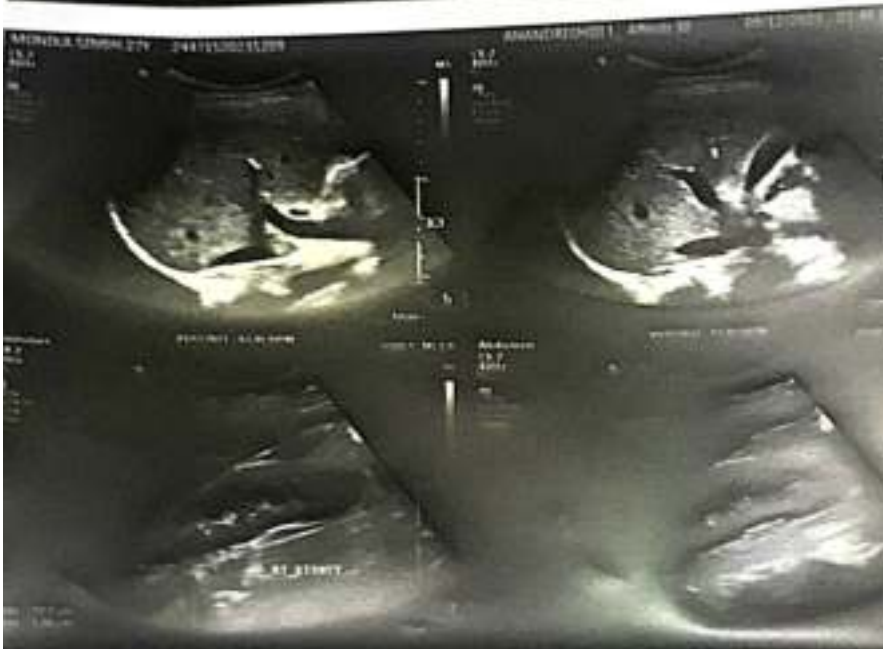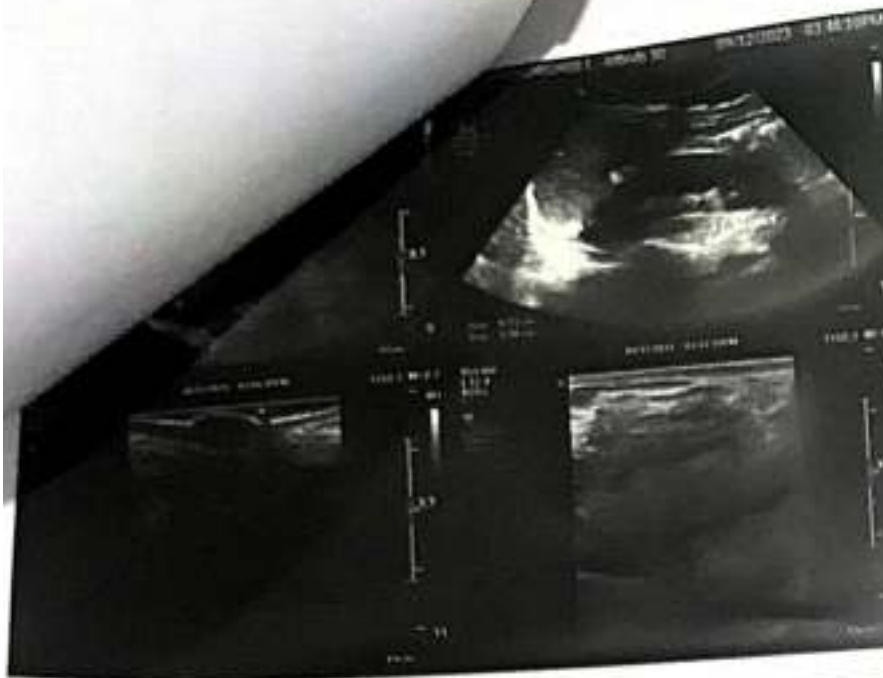
Visualized bowel loops appear normal in caliber and shows normal peristalsis.

IMPRESSION:

***No significant abnormality detected at present scan.**

Thanks for reference with regards.


DR. RUTUJA DOSHI.
MBBS, DMRE
Consultant Radiologist.



| | | | |
|---------------------------------------|------------------|---------|-------------|
| Patient's Name | MRS.MONIKA SINGH | Age/Sex | 27 Y/FEMALE |
| Ref By | HEALTHLEDGER | Date | 09/12/2023 |
| ULTRASONOGRAPHY OF BOTH BREAST | | | |

Both breast parenchyma appears normal.
No evidence of solid or cystic lesion.
The skin appear normal.
The nipple is visualized as well defined nodule with distal attenuation of sound beam.
The retro areolar tissue appears normal.
Retro mammary region appears normal.
No e/o any enlarged intramammary / axillary lymph nodes seen.

IMPRESSION:

- NO ABNORMALITY DETECTED.

Clinical correlation.

Thanks for reference with regards.

DR. RUTUJA DOSHI.
MBBS, DMRE
Consultant Radiologist



| | | | |
|----------------|-------------------|---------|--------------|
| PATIENT'S NAME | MRS. MONIKA SINGH | AGE/SEX | 27 Y/ FEMALE |
| REF BY | APOLLO | DATE : | 9-Dec-23 |

X-RAY CHEST PA VIEW

Mild haziness is noted in bilateral lower zones due to breast shadow.

Rest of the lung fields appear clear.

Both costophrenic angles are normal.
The hila, mediastinal and diaphragmatic outlines appear normal.

The cardiac shadow appears normal.
The bony thoracic cage and soft tissues appear normal.


Impression:- No abnormality detected.

***Kindly correlate clinically.**



DR. RUTUJA DOSHI.
MBBS, DMRE.
Consultant Radiologist.





Patient Name : MRS. MONIKA PRATAP SINGH
Age / Gender : 27 Years / Female
Ref. By Dr : SELF
Patient ID : 122309006
Sample Coll By : ANANDRISHIJI MEDICAL CENTRE

Client Name : APOLLO
Registration Date : 09-Dec-2023 9:05 AM
Sample Coll. Date : 09-Dec-2023 9:05 AM
Authentication Date : 09-Dec-2023 5:33 PM
Report Date : 09-Dec-2023 2:45 PM



* 1 2 2 3 0 9 0 0 6 *

CLINICAL PATHOLOGY

| Investigation | Result | Unit | Bio. Ref. Interval |
|--------------------------------|-------------|-------|--------------------|
| URINE EXAMINATION | | | |
| PHYSICAL EXAMINATION | | | |
| COLOUR | Pale Yellow | | Pale Yellow |
| APPEARANCE | Clear | | Clear |
| PH | 6.0 | | 5.0-7.5 |
| SPECIFIC GRAVITY | 1.010 | | 1.002-1.030 |
| CHEMICAL EXAMINATION | | | |
| PROTEINS | Absent | | Negative |
| GLUCOSE | Absent | | Negative |
| KETONE BODIES | Absent | | Negative |
| BILLIRUBIN | Absent | | Negative |
| BLOOD | Absent | | Negative |
| NITRITE | Absent | | Negative |
| MICROSCOPIC EXAMINATION | | | |
| PUS CELLS | Occasional | / HPF | 0-5 |
| RED BLOOD CELLS | Absent | / HPF | Nil |
| EPITHELIAL CELLS | Occasional | / HPF | < 10 |
| CASTS | Absent | | Absent |
| CRYSTALS | Absent | | Absent |
| YEAST CELLS | Absent | | Absent |
| BACTERIA | Absent | | Absent |
| MUCUS THREADS | Absent | | Absent |
| TRICHOMONAS VAGINALIS | Absent | | Absent |
| SPERMATOZA | Absent | | Absent |
| LEUKOCYTES | Absent | ng/ml | |
| DEPOSIT | Absent | | Absent |

----- END OF REPORT -----



Dr. Jitendra Suru
MD Pathology