



भारतीय विशिष्ट पहचान प्राधिकरण

Unique Identification Authority of India

पता: S/O: शिखर स्वाइन, रामेश्वर,
रामेश्वर, रामेश्वर, खोरदा, ओडिशा,
752020

Address: S/O: Shikhar Swain, rameswar,
Rameswar, Rameswar, Khorda, Odisha,
752020

4256 4476 6622



help@uidai.gov.in

www.uidai.gov.in


1800 11 347

[Handwritten signature]



भारत सरकार

Government of India




गजेन्द्र स्वाइन

Gajendra Swain

जन्म वर्ष / Year of Birth : 1972

पुरुष / Male



4256 4476 6622

आधार - आम आदमी का अधिकार

HARI CHANDLANI
M.B.B.S. (RESP. MEDICINE), PGDIP, PGDMLS
LOW INTENSIVE CARE
M.D.C. REG. NO. - 91702

SO/m

0.0.0 (01/02/1972)

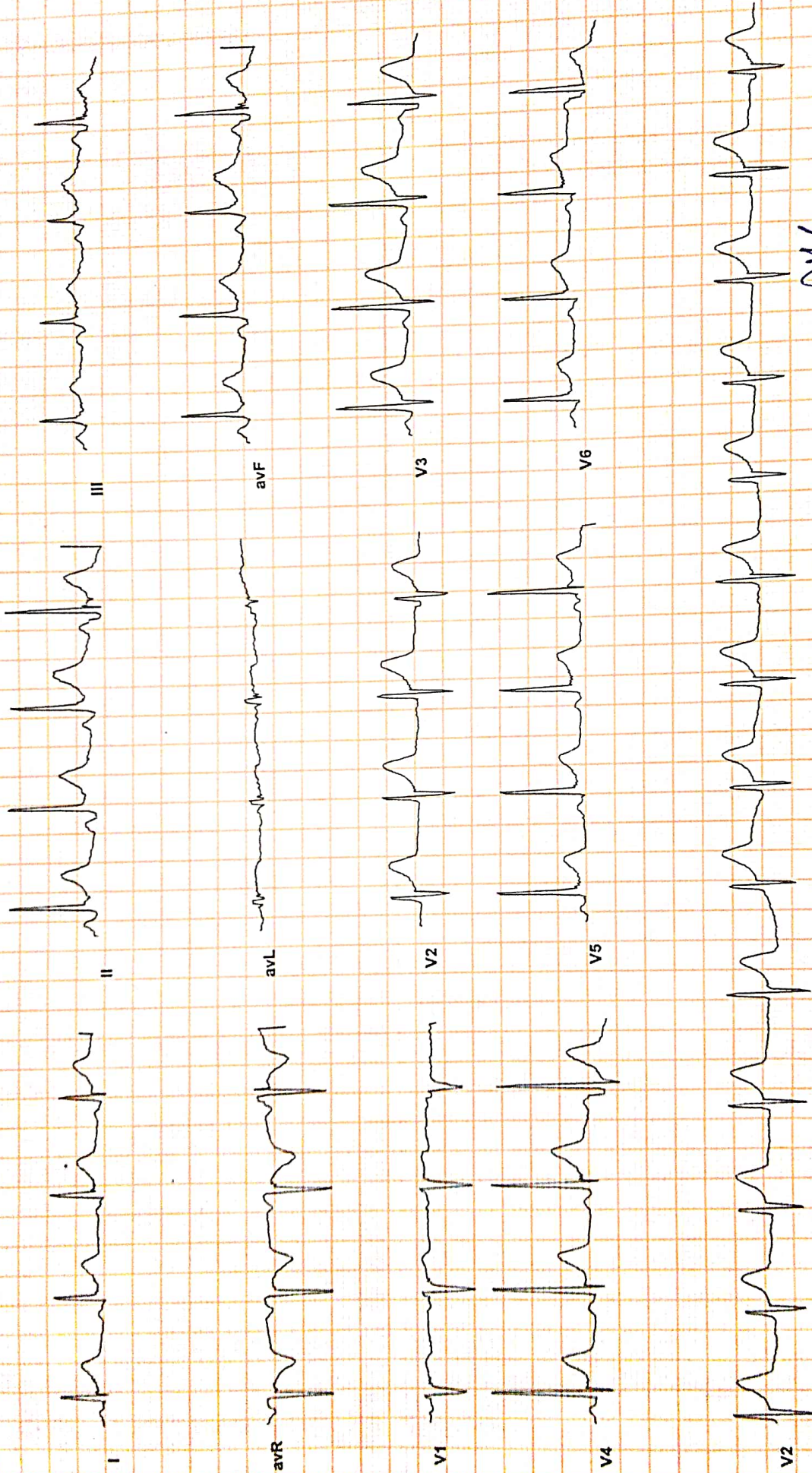
'DR. PLUS HEALTHCARE CENTRE'
NARAYANI HEIGHTS', B-WING,
42, MUMBAI CENTRAL (EAST)

ECG

DR PLUS HEALTHCARE CENTRE- MUMBAI CENTRAL

303 / GAJENDRA SWAIN / 50 Yrs / M

Heart Rate : 84 bpm / Tested On : 26-Mar-22 09:20:59 / HF 0.05 Hz - LF 100 Hz / Notch 50 Hz / Sn 1.00 Cm/mV / Sw 25 mm/s



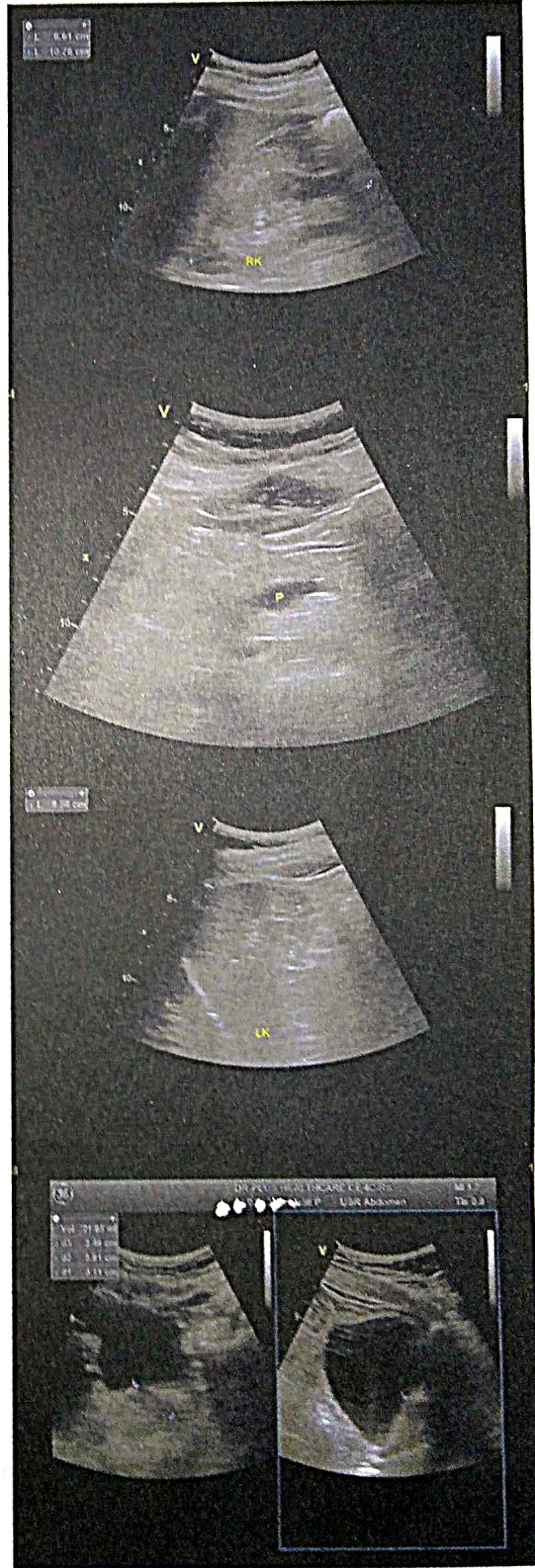
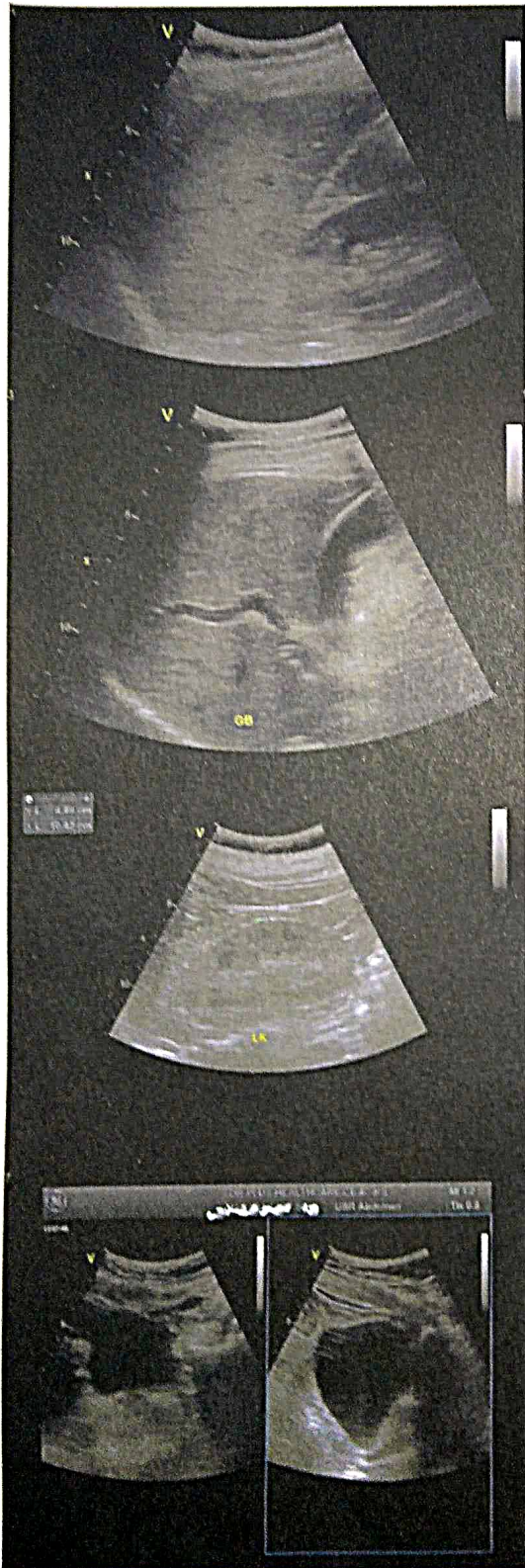DR. PURVI CHHABLAN
Reported By: DR. PURVI CHHABLAN
Cardiologist, Indian and Intensive
REG NO 77896

WNL

Name GAJENDRA SWAIN

Sex Male

Age 50





Dr-Plus Healthcare Centre

NATHANI HEIGHTS, B-Wing, Shop No. 42, Ground Floor, Opp. Mumbai Central Station (East), Mumbai - 400 008.

Patient Name	: GAJENDRA SWAIN	Sex:	MALE
Doctor's Name	: DR. H. CHHABLANI	Age:	50 YEARS
Date	: 26/03/2022		

ULTRASONOGRAPHY OF THE ABDOMEN AND THE PELVIS:

The relevant sonographic findings include the following:

HEPATOBIILIARY APPARATUS

The liver is normal in size and echogenicity. No obvious focal parenchymal lesion is seen. Extrahepatic biliary radicals are not dilated. The portal vein and the common bile duct are normal.

GALL BLADDER

The gall bladder is adequately distended. The wall thickness is normal. No echogenic contents are noted in its lumen. There is no pericholecystic collection noted.

PANCREAS

The pancreas shows normal echogenicity and size. No focal or diffuse lesions are noted. No evidence of calcification is noted.

SPLEEN

The spleen appears normal in size and echogenicity. No focal or diffuse lesions are noted. No evidence of calcification is noted.

KIDNEYS

Right Kidney measure: 10.5 x 5.4 cm, Left kidney measure: 10.6 x 4.4 cm

Both the kidneys appear normal in size, shape and echogenicity. Both the pelvicalyceal system is normal and both corticomedullary differentiations are well maintained. There is no obvious focal or diffuse lesion noted. No evidence of any calculus seen in either kidney.

PROSTATE

The Prostate appears normal and shows a normal echogenicity.

URINARY BLADDER

The urinary bladder shows anechoic contents. Its wall thickness appears normal. No evidence of calcification is seen. There is no obvious evidence of abdominal or pelvic lymphadenopathy or ascites noted.

IMPRESSION: No significant abnormality is detected.


Dr. Parag Jhaveri
MBBS (BOM), DMRE (BOM)
Radio-Sonologist

**'DR. PLUS HEALTHCARE CENTRE'
NATHANI HEIGHTS', B-WING,
42, MUMBAI CENTRAL (EAST)**



Dr-Plus Healthcare Centre

NATHANI HEIGHTS, B-Wing, Shop No. 42, Ground Floor, Opp. Mumbai Central Station (East), Mumbai - 400 008.

Patient's Name : GAJENDRA SWAIN

Report Date : 26/03/2022

Referred By : SELF

Age : 50 Years

Sex : MALE

X- RAY CHEST

BOTH THE LUNG FIELED ARE CLEAR.

THE HILAR SHADOWS APPEAR NORMAL.

THE COSTO-PHRENIC ANGELS ARE CLEAR.

THE CARDIAC SHADOWS APPEAR NORMAL.

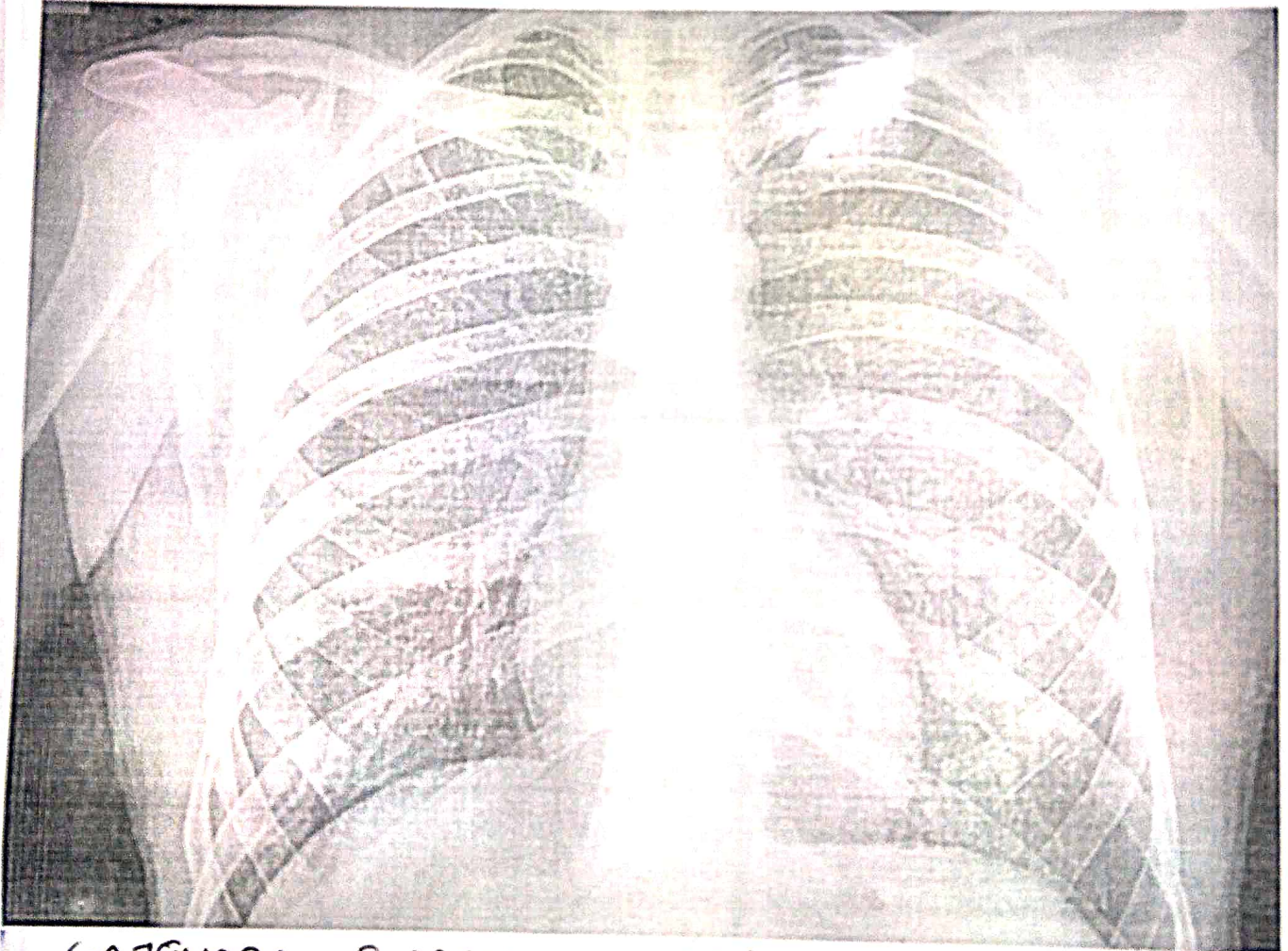
THE TRACHEAL IS CENTRAL IN POSITION.

THE BONY CAGE APPEARS NORMAL.

DR. A. J. MAZUMDAR

MD. DMRE, MDRD

**'DR. PLUS HEALTHCARE CENTRE'
NATHANI HEIGHTS', B-WING,
42, MUMBAI CENTRAL (EAST)**



GAJENDRA SWAIN

SO/m

26/03/2022



Dr-Plus Healthcare Centre

NATHANI HEIGHTS, B-Wing, Shop No. 42, Ground Floor, Opp. Mumbai Central Station (East), Mumbai - 400 008.

Full Name

GAJENDRA SWAIN

50/M

26/03/2022

Life to be assured:

	Type of Test	Actual Reading	Normal Range
1	Fasting Blood Sugar	87.5	70-100 mg%
2	PPBS	123.1	110 TO 140 mg%
3	Total Cholesterol	175.2	120-200 mg%
4	VERY LOW DENSINTY LEVEL(VLDL)	15.1	10-30 mg/dl
5	High Density Lipid (HDL)	50.1	40-60 mg%
6	Low Density Lipid (LDL)	110	Upto 150
7	S. Triglycerides	119.6	50-150 mg%
8	CHOL/HDL	3.4	Upto 5
9	HDL/LDL	0.4	
10	S. Creatinine	0.9	0.5-1.2 mg%
11	Blood Urea Nitrogen (BUN)	18.5	7-21 mg%
12	BUN/CREAT RATIO	20.5	
13	S. Proteins	6.8	6.0-7.9 mg%
14	(a) Albumin	3.8	3.5-5.5 mg%
15	(b) Globulin	3.0	2.0-3.5 mg%
16	A/G RATIO	1.12	
17	S. Bilirubin	0.9	0.3-1.3mg%
18	(a) Direct	0.7	0.0-0.8 mg%
19	(b) Indirect	0.2	0.0-0.5 mg%
20	SGOT (AST)	25.2	05-34 IU
21	SGPT (ALT)	31.2	05-40 IU
22	GGTP (GGT)	40.6	05-50 IU
23	SGOT/SGPT	0.8	
24	HBA1C	5.4	UPTO 6.5
25	S. Alkaline Phosphatase	91.5	30-115 IU
26	T3	162.5	80-180ng/dl
27	T4	6.9	4.6-12 ug/dl
28	TSH	2.0	0.4-4.0 mIU/L
29	SERUM URIC ACID	6.5	2.5-7.2mg/dl
30	URINE SUGAR PP	ABSENT	
31	URINE SUGAR FASTING	ABSENT	
32	BLOOD GROUP	" O POSITIVE "	

DR. RAKESH PATKAR
M.D. N.B. (Pathology)
Reg. No. 2013/1060



Dr-Plus Healthcare Centre

NATHANI HEIGHTS, B-Wing, Shop No. 42, Ground Floor, Opp. Mumbai Central Station (East), Mumbai - 400 008.

Full Name

GAJENDRA SWAIN 50/M

26/03/2022

Life to be assured:

HAEMOGRAM

Normal Range

1.	Red Blood Cell Count	4.6	[M : 4.5 - 5.6 / F : 3.5 - 5.5/cu.mm]
2.	Hb%	14.8	[M: 14-18 / F : 11-16%]
3.	Hematocrit	47	[M : 40-53 / F : 30-47 %]
4.	Indices:		
(a)	MCV(Mean Corpuscular Volume)	92	[79-101 cu.mi.]
(b)	MCH(Mean Corpuscular Hb)	31.3	[27-32 pg]
(c)	MCHC(Mean Corpuscular Hb Concentration)	35.4	[32-38%]
5.	Morphology		
	Macrocytes :	--	Microcytes: -- Hypochromia: --
	Piokilocytosis:	--	Anisocytosis: --
6.	Target cells:	--	
	Spherocytes:	--	Elliptocytes: --
7.	TOTALW.B.C.Count	7,000	{4000-11000/cu.mm}
Differential Count0			
a)	Neutrophils :	54 [45 - 70%]	c) Eosinophils: 05 [01 - 06%]
b)	Lymphocytes :	36 [20 - 45%]	d) Monocytes: 05 [00 - 08%]
e)	Basophils :	00 [00 - 01%]	
8.	Platelets :3.60	1.5-4.5 Lacks/cu.mm	
9.	Erythrocyte Sedimentation Rate:08	20 mm at end of 1 hour	Method : Westergrens

ROUTINE URINE EXAMINATION (RUA)

1. Physical Examination:

(i)	Colour:	YELLOW	(ii)	Sediment:	CLEAR
(iii)	Transparency:	CLEAR	(iv)	Reaction:	6.0
(v)	Specific gravity	1.015			

2. Chemical Examination:

(i)	Protein :	ABSENT	(ii)	Sugar:	ABSENT
(iii)	Bile salt:	ABSENT	(iv)	Bile pigment:	ABSENT

3. Microscopic Examination:

(i)	Red Blood Cells:	ABSENT	(ii)	Epithelial Cells:	02-03
(iii)	Crystals:	ABSENT	(iv)	Pus Cells:	0 TO 1
(v)	Casts:	ABSENT	(vi)	Deposits:	ABSENT
(vii)	Bacteria's :	ABSENT			

DR. PRAKESH PATKAR
M.D. D.N.B. (Pathology)
Reg. No. 2013/05/1660



Dr. Hari Chhablani

Cardiometabolic Physician & Intensivist
M.B.B.S., F.C.C.P. (RESP. MED.), PGDHHM,
PGDMLS, FELLOW INTENSIVE CARE MED.

ATTACHED TO : Wockhardt Hospital • Saifee Hospital • Apollo Spectra Hospital

NATHANI HEIGHTS, B-Wing, Shop No. 42, Ground Floor, Opp. Mumbai Central Station (East),
Mumbai - 400 008. • Cell : 98206 46163 • E : drharichhablani@gmail.com

PHYSICIAN REPORT

DATE : 26/03/2022

NAME : GAJENDRA SWAIN 50/M

PRESENTING COMPLAINS : K/C/O HTN SINCE 1 YEAR ON CTD-T

PAST HISTORY : NIL

FAMILY HISTORY: NOT SIGNIFICANT.

HABITS: NIL

HT.- 168 CM. WT.- 67 Kg. BMI.-23.7

P: 84/MIN ., REGULAR BP: 130/82

EYE EXAMINATION : NEAR VISION - B/E - N12,, DISTANT VISION -B/E -6/12

COLOR VISION : NORMAL

RS: CLEAR

CVS: S1,S2 REGULAR

PA: SOFT

CNS: CLINICALLY NAD

LABS: ATTACHED

USG - WNL

ECG: WNL

X-RAY - WNL

IMPRESSION : FIT ON CLINICAL MEDICAL EXAMINATION .


DR. HARI CHHABLANI
M.B.B.S., F.C.C.P. (RESP. MEDICINE) PGDHHM, PGDMLS
FELLOW INTENSIVE CARE
MMC REG. NO. - 91702



बुध्मबई महानगरपालिका
सार्वजनिक आरोग्य विभाग


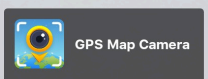
सुलभीच्या पहचानी क्वागल करु,
सुलभी पाचुका, देरु पाचुका !

सुलभीचा लिंग तयारी नका

PRE-NATAL SEX DETERMINATION
IN/OF GALS BEFORE BIRTH
IS NOT DONE HERE.

IT IS A PUNISHABLE ACT

सुलभी लिंग तयारी करु नका
सुलभी लिंग तयारी करु नका
सुलभी लिंग तयारी करु नका



Mumbai, Maharashtra, India
 Shop No 65, Nathani Heights, Marzban Parsi Colony, Dalal
 Estate, Mumbai Central, Mumbai, Maharashtra 400008, India
 Lat 18.968744°
 Long 72.819946°
 26/03/22 12:06 PM