



Atharva Hospital &lt;atharvahospital22@gmail.com&gt;

**Fwd: Health Check up Booking Confirmed Request(bobE1422),Package Code-PKG10000240, Beneficiary Code-31269**

1 message

Atul Chirmade <atulpc2@gmail.com>  
To: atharva hospital <atharvahospital22@gmail.com>

Tue, Jun 22, 2021 at 8:25 PM

----- Forwarded message -----

From: Mediwheel <noreply@mediwheel.in>  
Date: Wed, 23 Jun, 2021, 11:46 am  
Subject: Health Check up Booking Confirmed Request(bobE1422),Package Code-PKG10000240, Beneficiary Code-31269  
To: atulpc2@gmail.com <atulpc2@gmail.com>  
Cc: Mediwheel CC <wellness@mediwheel.in>, Mediwheel CC <customercare@mediwheel.in>, Mediwheel CC <customercare@policywheel.com>, Mediwheel CC <santosh@policywheel.com>



**Mediwheel**  
Your wellness partner



011-41195959

Email:wellness@mediwheel.in

Hi Atharva Hospital And Research Centre,  
Diagnostic/Hospital Location:Block No 126 Opp- Croma Showroom ,City:Mumbai  
We have received the confirmation for the following booking -

Beneficiary Name : PKG10000240  
Beneficiary Name : MR. KOKATE VIJAY HIRU  
Member Age : 29  
Member Gender : Male  
Member Relation : Employee  
Package Name : Metro Gob Full Body Health Checkup Male Below 40  
Location : PUNE,Maharashtra-411005  
Contact Details : 7719839468  
Booking Date : 23-06-2021  
Appointment Date : 26-06-2021

**ATHARVA DIAGNOSTIC CENTRE**  
Gr. Floor, Shop No. 5, Salprasad Bldg.,  
F-Wing, Sion Kamgar CHS, Sion,  
Mumbai - 400 022.

**Instructions to undergo Health Check:**

1. Please ensure you are on complete fasting for 10-To-12-Hours prior to check.
2. During fasting time do not take any kind of medication, alcohol, cigarettes, tobacco or any other liquids (except Water) in the morning.
3. Bring urine sample in a container if possible (containers are available at the Health Check centre).
4. Please bring all your medical prescriptions and previous health medical records with you.
5. Kindly inform the health check reception in case if you have a history of diabetes and cardiac problems.

**For Women:**

1. Pregnant Women or those suspecting are advised not to undergo any X-Ray test.
2. It is advisable not to undergo any Health Check during menstrual cycle.

We request you to facilitate the employee on priority.

**B** बैंक ऑफ़ बड़ौदा  
**Bank of Baroda**

नाम  
Name : **Vijay H Kokate**  
कार्यकारी दूर क्र.  
E.C.No. : **122369**



जारीकर्ता प्राधिकारी  
Issuing Authority  
Chief Manager (HRM)  
Pune Zone

*Vijay H Kokate*  
धारक के हस्ताक्षर  
Signature of Holder

*Vijay H Kokate*

**ATHARVA DIAGNOSTIC CENTRE**  
Gr. Floor, Shop No. 5, Saiprasad Bldg.,  
F-Wing, Sion Kamgar CHS, Sion,  
Mumbai - 400 022.

**DR. ATUL P. OHIRMADE**  
M.B.B.S., M.S.  
Consultant Laproscopic & Oncosurgeon  
Reg. No. 86962

मिलने पर, निम्नलिखित को सौंपा जावे  
सहायक महाप्रबंधक (सुरक्षा)  
बैंक ऑफ़ बड़ौदा, बडौदा कॉर्पोरेट सेंटर  
सी-26, जी-ब्लॉक, बान्द्रा-कुरला कॉम्प्लेक्स, मुंबई - 400 051, भारत  
फोन: 91 22 8698 5196 फैक्स 91 22 2652 5747

**If found, please return to**  
Asst. General Manager (Security)  
Bank of Baroda, Baroda Corporate Centre  
C-26, G-Block, Bandra-Kurla Complex, Mumbai 400 051, India  
Phone 91 22 5698 5196 Fax 91 22 2652 5747

रक्त समूह / Blood Group : **O+ve**  
परचान चिह्न / Identification Marks : **Mark on right knee**



भारत सरकार  
GOVERNMENT OF INDIA



विजय हिरु कोकटे  
Vijay Hiru Kokate  
जन्म तारीख/DOB: 15/08/1991  
पुरुष/ MALE  
Mobile No: 8087433879



**6786 8739 0091**  
VID : 9143 5098 2136 9796

माझे आधार, माझी ओळख

*@kokate*

**ATHARVA DIAGNOSTIC CENTRE**  
Gr. Floor, Shop No. 5, Saiprasad Bldg.,  
F-Wing, Sion Kamgar CHS, Sion,  
Mumbai - 400 022.

**DR. ATUL P. CHIRMADE**  
M.B.B.S., M.S.  
Consultant Laproscopic & Oncosurgeon  
Reg. No. 86962



भारतीय विशिष्ट पहचान प्राधिकरण  
UNIQUE IDENTIFICATION AUTHORITY OF INDIA

पत्ता:  
S/O: हिरु कोकटे, घर क्र 939, माथेरान रोड, पयारमळ,  
गणेश नगर, अन्जाप, रायगड,  
महाराष्ट्र - 410101



Address :  
S/O: Hiru Kokate, house no 939, matheran  
road, payarnal, ganesh nagar, Anjap,  
Raigarh,  
Maharashtra - 410101



help@uidai.gov.in

www.uidai.gov.in

P.O. Box No. 1847,  
Bangalore 560 001



# ATHARVA HOSPITAL & RESEARCH CENTRE

MATERNITY • SURGICAL • GENERAL ORTHOPEDIC • SUPER SPECIALITY

101, 1st Floor, Saiprasad Building, Sion Kamgar CHS Ltd., Opp. Croma Showroom,  
Sion (East), Mumbai - 400 022. • Email : atharvahospital@ymail.com  
Tel. : 022-2401 6640 / 913609 6640 • Mobile : 98922 44833 / 98678 39996

Date : 26/06/21

Mr. Kokate. Vijay Hiran

Age - : 29 yrs / Male

Booking Reference No - PKG10000240

- Dental checkup.
- physician consultation.
- Eye checkup consultation
- Skin / ENT consultation

NAD.

**ATHARVA DIAGNOSTIC CENTRE**  
Gr. Floor, Shop No. 5, Saiprasad Bldg.,  
F-Wing, Sion Kamgar CHS, Sion,  
Mumbai - 400 022.

**DR. ATUL P. CHIRMADE**  
M.B.B.S., M.S.  
Consultant Laproscopic & Oncosurgeon  
Reg. No. 86962



# ATHARVA DIAGNOSTIC CENTRE

## FULLY AUTOMATED COMPUTERISED PATHOLOGY

### X-RAY, SONOGRAPHY, E.C.G. & 2D ECHO

Shop No. 6, Ground Floor, Sai Prasad Building, Sion Kamgar CHS. Ltd., Opp. Croma Showroom,  
Sion (E), Mumbai - 400 022. • Email : atharvahospital@ymail.com  
Ph.: 022-2401 6640 / 913609 6640 • Mob.: 98922 44833 / 98678 39996

Patient's Name :- Mr. Vijay Kokate. Date: - 26 Jun 2021  
Referred By :- Dr. Atul P. Chirmade. Age & Sex: - 29 Yrs / M  
Examination :- USG ABDOMEN & PELVIS

#### USG ABDOMEN & PELVIS:-

Liver appears normal in size and shows bright echotexture.  
The intra hepatic and portal radicles are normally calibered.  
There is no evidence of any focal lesion in the liver.  
Portal Vein appears normal and measures mms.11 (Normal < 13mms.)


Gall Bladder shows few mobile calculi 5-6 mm in size.  
Spleen is normal in size and echotexture.  
Pancreas is normal in echotexture.

Both Kidneys are normal in size and echotexture.  
Right Kidney measures 87 x 46 mm.  
Left Kidney measures 102 x 50 mm.  
No evidence of ascites, para-aortic or any other lymphadenopathy.

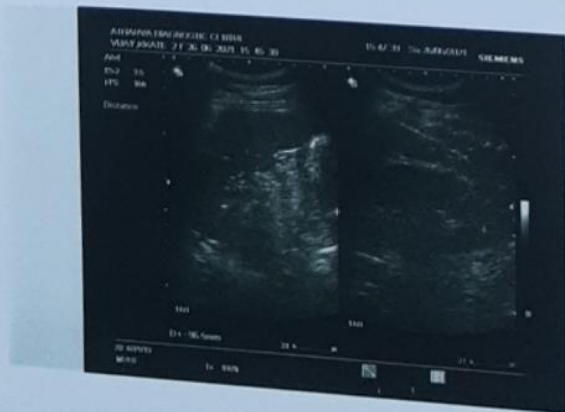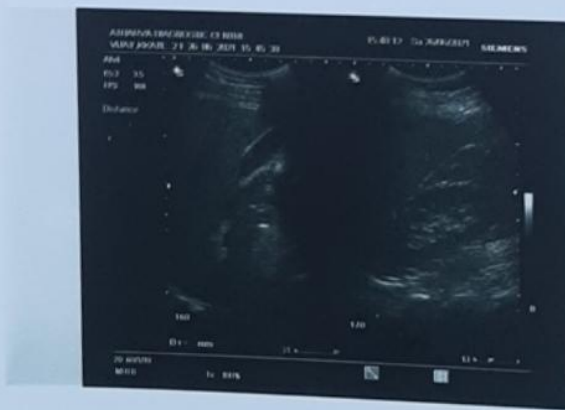
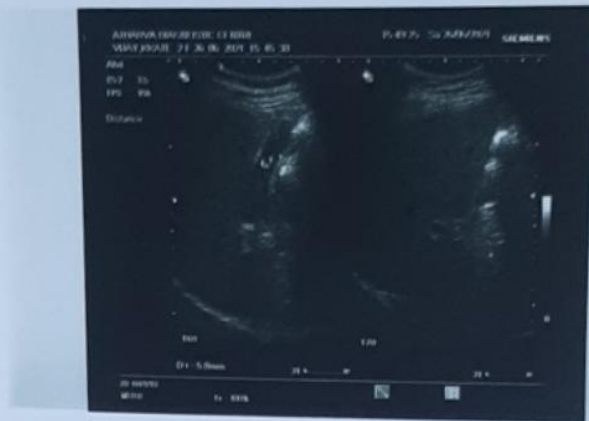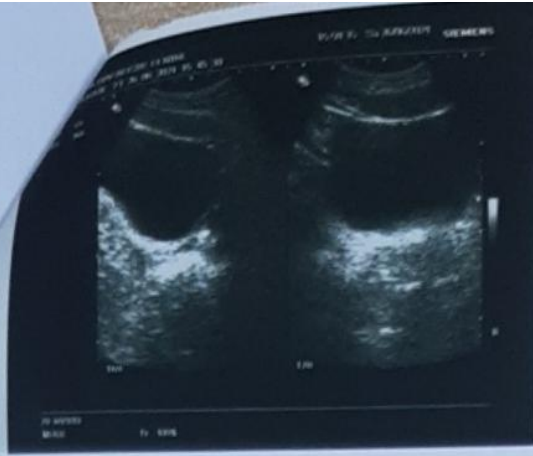
Bladder and Prostate are normal.

#### IMPRESSION:-

- > Fatty liver
- > Gall Stones.

  
DR. SANDEEP NYAYANIRGUNE  
MD DNB DMRE  
RADIOLOGIST & SONOLOGIST







# ATHARVA DIAGNOSTIC CENTRE

## FULLY AUTOMATED COMPUTERISED PATHOLOGY

### X-RAY, SONOGRAPHY, E.C.G. & 2D ECHO

Shop No. 6, Ground Floor, Sai Prasad Building, Sion Kamgar CHS. Ltd., Opp. Croma Showroom,  
Sion (E), Mumbai - 400 022. • Email : [atharvahospital@ymail.com](mailto:atharvahospital@ymail.com)  
Ph.: 022-2401 6640 / 913609 6640 • Mob.: 98922 44833 / 98678 39996

PATIENT NAME: Mr. Kokate Vijay Hiru.

DATE:- 26 Jun 2021

AGE: 29 YRS/M

#### Measurements:

LA : 33 mm  
AO : 21 mm  
LVID(d) : 45 mm  
LVID (s) : 28 mm  
IVS (d) : 11mm  
LVPW (d): 11 mm  
RA/RV : 28/29mm  
LVEF : 60 %

**RWMA: NO RESTING RWMA**

#### 2 D Echo:

Mitral valve- NORMAL  
Aortic valve- NORMAL  
PV/RVOT-NORMAL  
IVS/IAS- intact  
Left sided arch, no coarctation  
IVC- NORMAL



# ATHARVA DIAGNOSTIC CENTRE

## FULLY AUTOMATED COMPUTERISED PATHOLOGY

### X-RAY, SONOGRAPHY, E.C.G. & 2D ECHO

Shop No. 6, Ground Floor, Sai Prasad Building, Sion Kamgar CHS. Ltd., Opp. Croma Showroom,  
Sion (E), Mumbai - 400 022. • Email : [atharvahospital@ymail.com](mailto:atharvahospital@ymail.com)  
Ph.: 022-2401 6640 / 913609 6640 • Mob.: 98922 44833 / 98678 39996

#### Doppler study

Mitral valve - TRIVIAL MR.

Aortic valve- NO AR, AV PG- 7 mm of Hg

Tricuspid valve -NO TR

PASP by TR jet velocity- 21 mm Hg

NO PAH

GRADE I DD

#### Final Diagnosis

NORMAL CHAMBER DIMENSION


NO RESTING RWMA

NO PAH

E/O DD

NORMAL LV SYSTOLIC FUNCTION

ADV- CLINICAL CORRELATION



  
DR.T. ABHAY

M.D (MEDICINE),

DM (CARDIOLOGY)





# ATHARVA DIAGNOSTIC CENTRE

## FULLY AUTOMATED COMPUTERISED PATHOLOGY

### X-RAY, SONOGRAPHY, E.C.G. & 2D ECHO

Shop No. 6, Ground Floor, Sai Prasad Building, Sion Kamgar CHS. Ltd., Opp. Croma Showroom,  
Sion (E), Mumbai - 400 022. • Email : atharvahospital@ymail.com  
Ph.: 022-2401 6640 / 913609 6640 • Mob.: 98922 44833 / 98678 39996

Patient's Name :- Mr. Vijay Kokate.

Date: - 26 Jun 2021

Referred By :- Dr. Atul P. Chirmade.

Age & Sex: - 29 Yrs / M

Examination :- X-RAY CHEST P.A. VIEW

#### REPORT:-

#### X-RAY CHEST

Both lung fields are clear

Heart and aorta are normal.

Both C.P. angles are clear

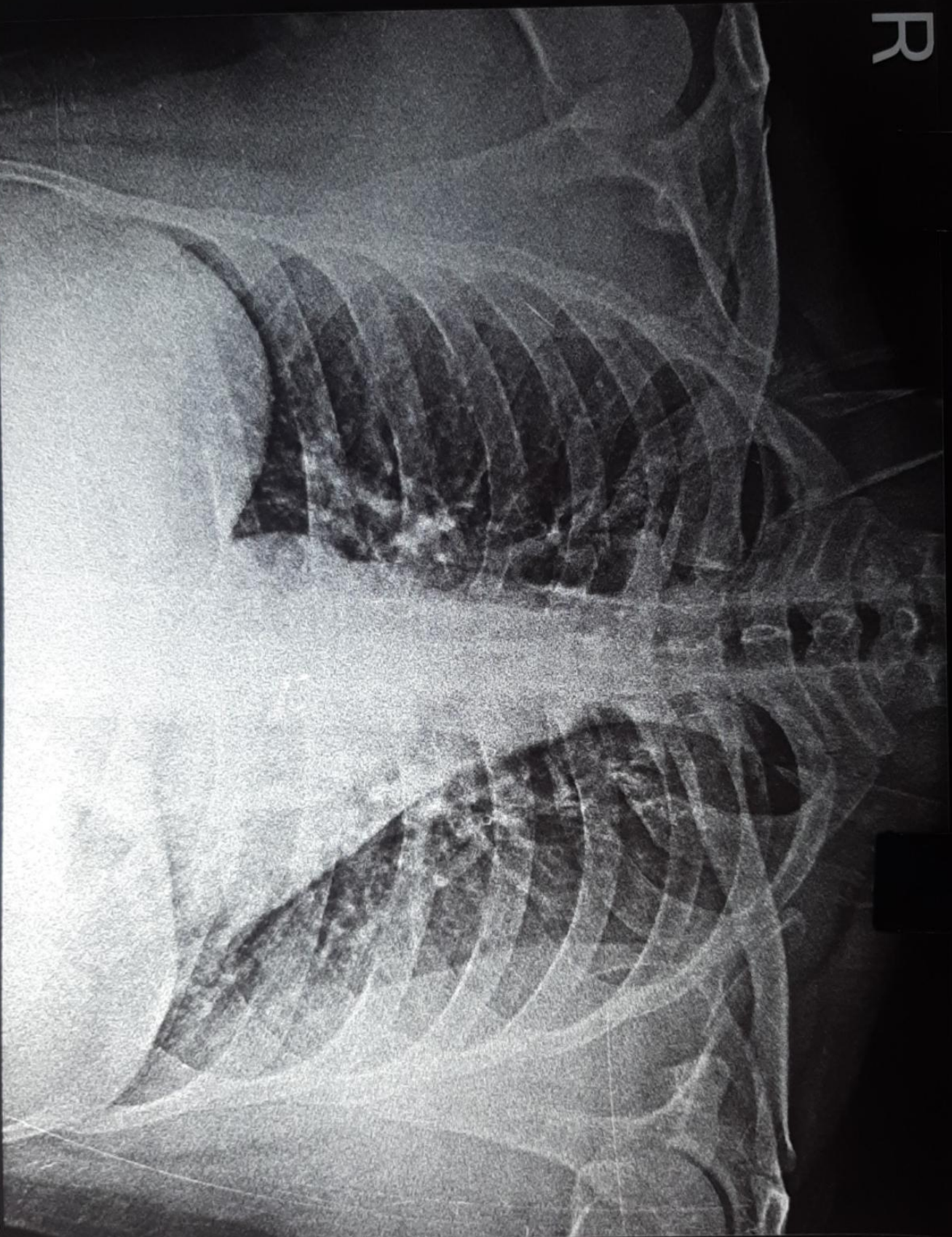
Pleura, diaphragm and ribcage appear normal.

#### IMPRESSION: -

➤ Normal Radiogram

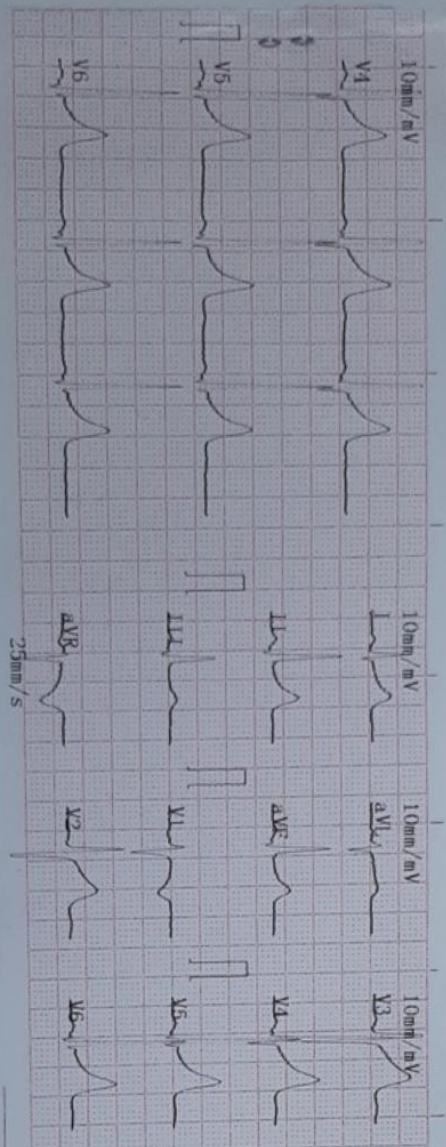
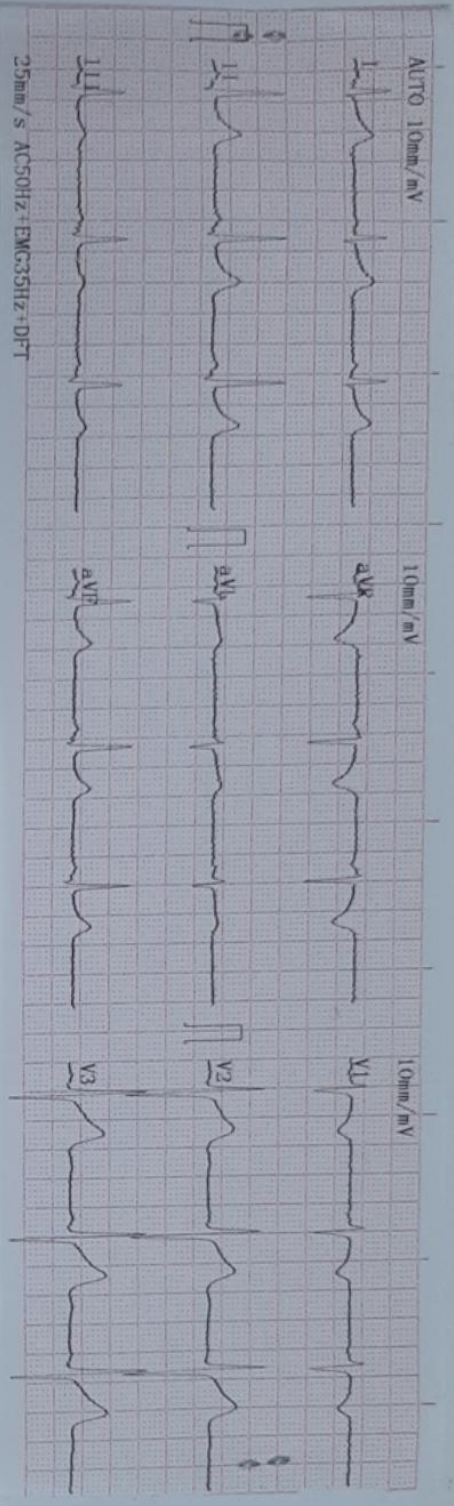
DR. SANDEEP NYAYANIRGUNE  
MD DNB DMRE  
RADIOLOGIST & SONOLOGIST

R



MR. VIJAY KOKATE 26062101 29 YRS MALE CHEST,FRN P->A 26-Jun-21 09:41  
ATHARVA HOSPITAL AND RESEARCH CENTRE PH: 24016640





8  
 2021-06-26 09:55  
 Name: **Kotate Vijay Hiru**  
 Sex: **Male** Age: **39**  
 Height: **166** cm Weight: **75** kg  
 SWS: **120** mmHg  
 DIA: **90** mmHg  
 HR: **62** bpm  
 PR Interval: **157** ms  
 P Duration: **150** ms  
 QRS Duration: **95** ms  
 I Duration: **234** ms  
 QT/QTc: **417/454** ms  
 P/QRS/T Axis: **-42, 4/68, 4/43, 9**  
 R(V5)/S(V1): **-2, 24/0, 65**  
 R(V5)/S(VI): **-2, 89**

<< Conclusions >>

Normal Sinus Rhythm  
 Cardiac electrical axis normal

**ATHARVA DIAGNOSTIC CENTRE**  
 Gr. Floor, Shop No. 5, Saiprasad Bldg,  
 F-Wing, Sion Kamgar C-15, Sion,  
 Mumbai - 400 022.

**DR. ATUL P. CHIRMADE**  
 M.B.B.S., M.S.  
 Consultant Leproscopic & Oncosurgeon  
 Reg. No. 86962

**Dr. Abhay Tidake**  
 MD, D.M. Cardiology  
 Reg. No. 2004/02/0618



Patient's Name: Mr Kokate Vijay Hira

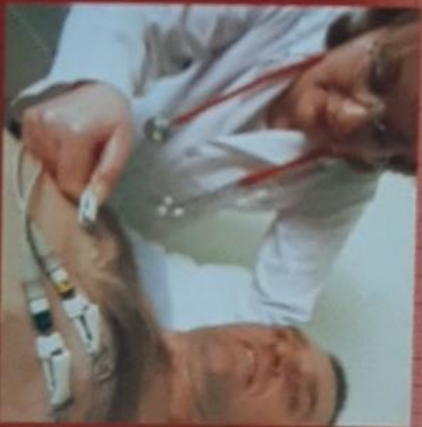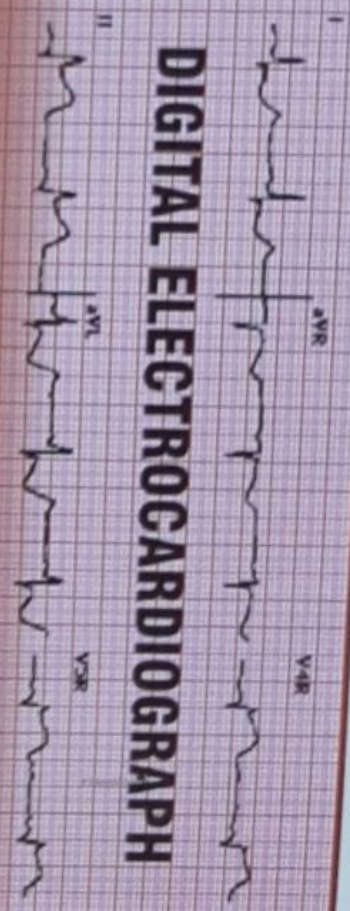
Age: 29 yrs Sex: M

Date: 26/06/21 Receipt No.: \_\_\_\_\_

Referred by Dr.: \_\_\_\_\_

Conclusion: WNL

Probable Diagnosis: \_\_\_\_\_



# AT HARVA DIAGNOSTIC CENTRE

FULLY AUTOMATED COMPUTERISED PATHOLOGY  
X-RAY, SONOGRAPHY, E.C.G. & 2D ECHO

Shop No. 6, Ground Floor, Sai Prasad Building,  
Sion Kamgar CHS. Ltd., Opp. Croma Showroom,  
Near PVR Cinemas, Sion (E), Mumbai - 400 022.  
Ph.: 022-2401 6640 / 913609 6640  
Mobile : 98922 44833 / 98678 39996

# AT HARVA