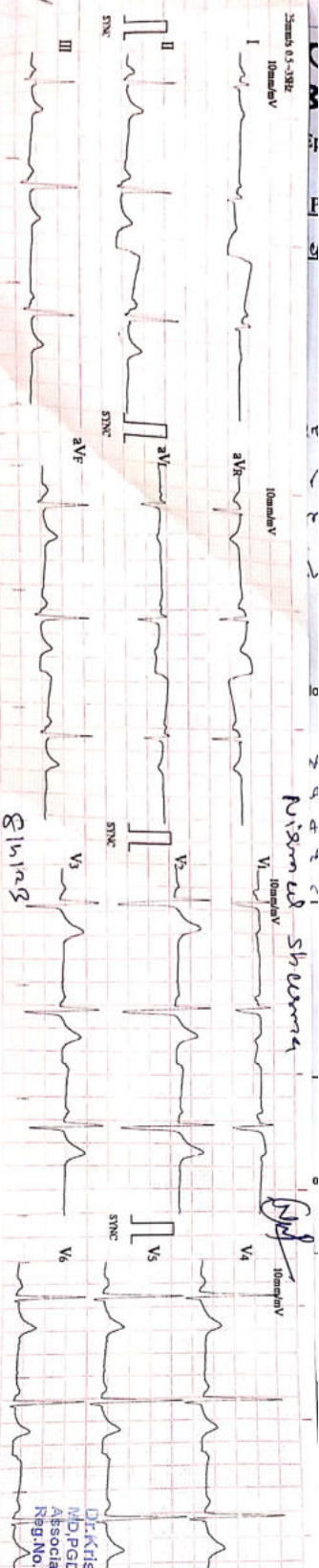


71.00Hz (1.00) 2011-01-08 04:04



HR : 63 bpm  
 R-R : 94.2 ms  
 P-R : 137 ms  
 QRS : 97 ms  
 QT/QTc : 372/383 ms  
 P/QRST : 61/91/73 ms  
 RV5/SM1 : -880/0-600mV  
 RV6/SM1 : 2.480 mV

— Sinus Rhythm  
 Borderline Normal ECG

Dr. Krish R. Vaidya  
 MD PGDCC  
 Associate Consultant-Cardiology  
 Reg.No.G-50578

Unconfirmed report Verified by: \_\_\_\_\_



# Heart & General Clinic

Icure Heart & Diet Clinic, 402, Epsilon tower, opp Pasha bhai park, Race course, Vadodara

## :: PERSONAL HEALTH REPORT ::

Nirmal Shesma		*DATE 8/1/23
		SR. NO. SEX. Male AGE 40 year HEIGHT 180 cm WEIGHT 89 k.g.

### HISTORY

Present History : HT medicines since 2014  
 Past Illness History : Diabetes/Hypertension/Tuberculosis/Asthma/Epilepsy  
 Past Occupational History : No  
 Family History : mother HT  
 Personal History : He had ACL Repair of knee st in 2011  
 Addiction : No Tobacco/Gutkha/Smoking/Alcohol

### GENERAL EXAMINATION

T.P.R. : 63/min B.P. : 132/90 mm Hg

Pallor/Icterus/Cyanosis/Varicosity/Lymph Nodes/Thyroid/Oedema/NVE/Other :

### SYSTEMIC EXAMINATION

R.S. : NAD  
 C.V.S : NAD  
 C.N.S : NAD  
 A.S. : NAD  
 Musculo-skelet System : NAD



E.N.T. Ex. NAD Dental Ex. NAD Skin Ex. NAD Psychic Ex. NAD	ACUITY OF VISION		RT EYE	LT EYE
	Without Glass	DISTANT	6/ 6	6/ 6
		Near	6/ 6	6/ 6
	With Glass	DISTANT	6/	6/
Near		6/	6/	
COLOUR BLINDNESS NAD				

### REMARK

### ADVICE

The Worker is FIT/UNFIT for the assigned job.

Dr. Krish P. Vaidya  
 MD, PG ACC  
 Associate Consultant-Cardiology  
 Reg. No. G-50510

DR. KRISH VAIDYA

MD G-50510, CIH




आयकर विभाग  
INCOME TAX DEPARTMENT

भारत सरकार  
GOVT. OF INDIA

NIRMAL CHANDRA SHARMA  
KUNVER NATH ROY

14/03/1983  
Permanent Account Number  
BRBPS8607Q

*Nirmal*  
Signature



17012008

*Nirmal*





# BARODA DIAGNOSTIC LABORATORY



Patient's name : Nirmal Sharma  
Age/Sex : 40 Years/Male  
Referred by : C/o. I Cure Heart & Diet Clinic  
Sample From : LAB  
UHID :

Reg. ID : icure-50-19  
Accession : 29315  
Reg. Date : 08/04/2023  
Collection Time : 08/04/2023 13:22

## COMPLETE BLOOD COUNT

Sample Type: EDTA

Test Name	Result	Units	Biological Reference Interval
<b><u>Blood Counts</u></b>			
Haemoglobin :	<b>13.4</b>	Gms%	13.5 - 18.0
Total R.B.C. :	<b>4.48</b>	mill/c.mm	4.7 - 6.0
Total W. B. C. :	6200	/cu mm	4000 - 10500
Platelet Count :	315000	/cu.mm	1,50,000 - 4,50,000
<b><u>Differential Count</u></b>			
Neutrophils :	62	%	40 - 70
Lymphocytes :	35	%	20 - 40
Eosinophils :	02	%	1 - 4
Monocytes :	<b>01</b>	%	2 - 6
Basophils :	00	%	0 - 01
<b><u>Blood Indices</u></b>			
P. C. V. :	<b>36.9</b>	%	42 - 52
M. C. V. :	82.4	fl	78 - 100
M.C.H. :	29.9	pg	27 - 31
M. C. H. C. :	<b>36.3</b>	%	32 - 36
R.D.W. :	13.0	%	11.5 - 14.0

### E.S.R.( Westergren Method )

After one hour : **08** mm 1 - 7

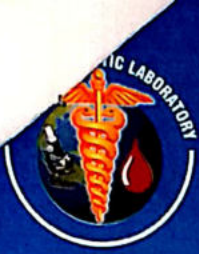

*Dr. Harsh Pandya*  
(MD)  
Consultant Pathologist  
Reg. No.: G-32582

*Dr. Priya Kriplani*  
(MD)  
Consultant Pathologist  
Reg. No.: G-46004

302, Trivia Complex, Natubhai Circle, Race Course, Vadodara. ☎: +91 88660 09950 / 74050 09950 ✉: bdl95950@gmail.com

Laboratory results serve as an aid to diagnosis & should be interpreted in relation to clinical findings. Please refer back to laboratory in case of any discrepancy.



# BARODA DIAGNOSTIC LABORATORY



\* 2 9 3 1 5 \*

Patient's name : Nirmal Sharma  
Age/Sex : 40 Years/Male  
Referred by : C/o. I Cure Heart & Diet Clinic  
Sample From : LAB  
UHID :

Reg. ID : icure-50-19  
Accession : 29315  
Reg. Date : 08/04/2023  
Collection Time : 08/04/2023 13:22

## THYROID FUNCTION

Sample Type: Serum

Test Name	Result	Units	Biological Reference Interval
TOTAL T3 :	1.42	ng/ml	0.84 - 2.0
TOTAL T4 :	6.12	ug/dl	5.1 - 14.0
TSH :	1.37	mIU/L	0.25 - 5.0

Method : CLIA

Dr. Niti Adhwaryu  
M.D. Pathology  
Reg. No. G-34888

Dr. Priya Kriplani  
M.D. Pathology.  
Reg. No. G-46004

LAB  
LAB USE ONLY (Entered by :AP Enter Date/Time:08/04/2023 2:05:00 PM) (Verify by :OP1 Verify Date/Time:08/04/2023 2:43:00 PM)

BARODA DIAGNOSTIC LABORATORY



**Dr Harsh Pandya**  
(MD)  
Consultant Pathologist  
Reg. No.: G-32582

**Dr. Priya Kriplani**  
(MD)  
Consultant Pathologist  
Reg. No.: G-46004

302, Trivia Complex, Natubhai Circle, Race Course, Vadodara. ☎: +91 88660 09950 / 74050 09950 ✉: bdl95950@gmail.com

Laboratory results serve as an aid to diagnosis & should be interpreted in relation to clinical findings. Please refer back to laboratory in case of any discrepancy.



Scanned with OKEN Scanner



# BARODA DIAGNOSTIC LABORATORY



\* 2 9 3 1 5 \*

Patient's name : Nirmal Sharma  
Age/Sex : 40 Years/Male  
Referred by : C/o. I Cure Heart & Diet Clinic  
Sample From : LAB  
UHID :  
Reg. ID : icure-50-19  
Accession : 29315  
Reg. Date : 08/04/2023  
Collection Time : 08/04/2023 13:22

## PSA

Sample Type: Serum

Test Name	Result	Units	Biological Reference Interval
PSA :	1.0	ng/ml	0 - 4.5

### Interpretation guide :

: PSA is a Glycoprotein found in prostate acinar cells,  
Ref. range <4.5 ng/ml. increased with age < 6.5 ng/ml, if more than 70yrs.

### \* Use:

-Monitor response to therapy of ca. prostate.  
-PSA of >100 ng/ml predicts bone metastasis with 73% positive predictive value.

### \* Increased in ->

-Prostate cancer.  
-Prostatitis.  
-Prostatic ischemia (Sometime too high level).  
-Prostate massage.  
-Needle biopsy/TUR.  
-Indwelling catheter.  
-Vigorous bicycle exercise.  
-Radiation therapy.

Method : Electrochemiluminescence Immunoassay "ECLIA"

Dr. Niti Adhwaryu  
M.D. Pathology  
Reg. No. G-34888

Dr. Priya Kriplani  
M.D. Pathology.  
Reg. No. G-46004

LAB

LAB USE ONLY (Entered by : AP Enter Date/Time: 08/04/2023 21:00:00 PM) (Verify by : OP1 Verify Date/Time: 08/04/2023 21:03:00 PM)



Dr. Harsh Pandya

Dr. Priya Kriplani

(MD)

(MD)

Consultant Pathologist

Consultant Pathologist

Reg. No.: G-32582

Reg. No.: G-46004

302, Trivia Complex, Natubhai Circle, Race Course, Vadodara. ☎: +91 88660 09950 / 74050 09950 ✉: bdl95950@gmail.com

Laboratory results serve as an aid to diagnosis & should be interpreted in relation to clinical findings. Please refer back to laboratory in case of any discrepancy.



Scanned with OKEN Scanner



# BARODA DIAGNOSTIC LABORATORY



\* 2 9 3 1 5 \*

Patient's name : Nirmal Sharma  
Age/Sex : 40 Years/Male  
Referred by : C/o. I Cure Heart & Diet Clinic  
Sample From : LAB  
UHID :  
Reg. ID : icure-50-19  
Accession : 29315  
Reg. Date : 08/04/2023  
Collection Time : 08/04/2023 13:22

## RENAL FUNCTION TEST

Test Name	Result	Units	Biological Reference Interval
Urea :	12	mg/dl	10 - 50
Bun (Calculated) :	5.6	mg/dl	0 - 18
Creatinine :	0.89	mg/dl	0.4 - 1.5
Uricacid :	5.30	mg/dl	3.4 - 7.0

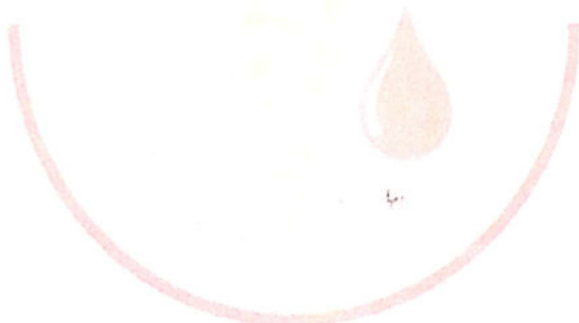Done on Fully automated biochemistry analyser - COBAS C 111

Dr. Niti Adhwaryu  
M.D. Pathology  
Reg. No. G-34888

Dr. Priya Kriplani  
M.D. Pathology  
Reg. No. G-46004

LAB  
LAB USE ONLY (Entered by :OP1 Enter Date/Time:08/04/2023 2:43:00 PM) (Verify by :OP1 Verify Date/Time:08/04/2023 2:43:00 PM)

BARODA DIAGNOSTIC LABORATORY



**Dr Harsh Pandya**  
(MD)  
Consultant Pathologist  
Reg. No.: G-32582

**Dr. Priya Kriplani**  
(MD)  
Consultant Pathologist  
Reg. No.: G-46004

302, Trivia Complex, Natubhai Circle, Race Course, Vadodara. ☎ : +91 88660 09950 / 74050 09950 ✉ : bdl95950@gmail.com

Laboratory results serve as an aid to diagnosis & should be interpreted in relation to clinical findings. Please refer back to laboratory in case of any discrepancy.



Scanned with OKEN Scanner



# BARODA DIAGNOSTIC LABORATORY



Patient's name : Nirmal Sharma  
Age/Sex : 40 Years/Male  
Referred by : C/o. I Cure Heart & Diet Clinic  
Sample From : LAB  
UHID :

Reg. ID : icure-50-19  
Accession : 29315  
Reg. Date : 08/04/2023  
Collection Time : 08/04/2023 13:22


## LIVER FUNCTION TEST

Sample Type: Serum

Test Name	Result	Units	Biological Reference Interval
S.G.P.T (ALT) :	12	U/L	0 - 40
S.G.O.T (AST) :	19	U/L	0 - 37
ALK.PHOSPHATASE :	74	U/L	40 - 130
G.G.T :	22.0	U/L	8 - 78
<b><u>Bilirubin</u></b>			
Total :	0.21	mg/dl	0.2 - 1.0
Direct :	0.14	mg/dl	0 - 0.6
Indirect :	0.07	mg/dl	0 - 0.5
<b><u>Serum Proteins</u></b>			
Total Protein :	7.12	gms/dl	6.4 - 8.3
Albumin :	4.20	gms/dl	3.8 - 4.4
Globulins :	2.92	gms/dl	2.3 - 3.5
A/G Ratio :	1.44		0.9 - 2.9

Done on Fully automated biochemistry analyser - COBAS C 111

Dr. Niti Adhwaryu  
M.D. Pathology  
Reg. No. G-34888

  
Dr. Priya Kriplani  
M.D. Pathology.  
Reg. No. G-46004

LAB  
LAB USE ONLY (Entered by :AP

Enter Date/Time:08/04/2023 2:04:14 PM Verify by :OP1



**Dr Harsh Pandya**  
(MD)  
Consultant Pathologist  
Reg. No.: G-32582

**Dr. Priya Kriplani**  
(MD)  
Consultant Pathologist  
Reg. No.: G-46004

302, Trivia Complex, Natubhai Circle, Race Course, Vadodara. ☎ : +91 88660 09950 / 74050 09950 ✉ : bdl95950@gmail.com

Laboratory results serve as an aid to diagnosis & should be interpreted in relation to clinical findings. Please refer back to laboratory in case of any discrepancy.







# BARODA DIAGNOSTIC LABORATORY



Patient's name : Nirmal Sharma  
Age/Sex : 40 Years/Male  
Referred by : C/o. I Cure Heart & Diet Clinic  
Sample From : LAB  
UHID :

Reg. ID : icure-44-19  
Accession : 29309  
Reg. Date : 08/04/2023  
Collection Time : 08/04/2023 13:19


## LIPID PROFILE

Sample Type: Serum

Test Name	Result	Units	Biological Reference Interval
Cholesterol :	194	mg/dl	0 - 200
Triglyceride :	<b>200</b>	mg/dL	0 - 150
HDL - Cholesterol :	46	mg/dL	35 - 65
LDL - Cholesterol :	108	mg/dL	0 - 130
VLDL - Cholesterol :	<b>40</b>	mg/dL	0 - 30
Total Cholesterol/HDL Ratio :	4.22		1 - 6
LDL / HDL Cholesterol Ratio :	2.35		0 - 3.5

Done on Fully automated biochemistry analyser - COBAS C 111

Dr. Niti Adhwaryu  
M.D. Pathology  
Reg. No. G-34888

  
Dr. Priya Kriplani  
M.D. Pathology.  
Reg. No. G-46004

LAB  
LAB USE ONLY (Entered by :AP Enter Date/Time:08/04/2023 2:15:00 PM) (Verify by :OP1 Verify Date/Time:08/04/2023 2:26:00 PM)



**Dr Harsh Pandya**  
(MD)  
Consultant Pathologist  
Reg. No.: G-32582

**Dr. Priya Kriplani**  
(MD)  
Consultant Pathologist  
Reg. No.: G-46004

302, Trivia Complex, Natubhai Circle, Race Course, Vadodara. ☎: +91 88660 09950 / 74050 09950 ✉: bdl95950@gmail.com

Laboratory results serve as an aid to diagnosis & should be interpreted in relation to clinical findings. Please refer back to laboratory in case of any discrepancy.



Scanned with OKEN Scanner



# BARODA DIAGNOSTIC LABORATORY



Patient's name : Nirmal Sharma  
Age/Sex : 40 Years/Male  
Referred by : C/o. I Cure Heart & Diet Clinic  
Sample From : LAB  
UHID :

Reg. ID : icure-44-19  
Accession : 29309  
Reg. Date : 08/04/2023  
Collection Time : 08/04/2023 13:19

## HbA1C REPORT

Sample Type: EDTA

Test Name	Result	Units	Biological Reference Interval
HbA1C :	5.78	%	Excellent control: 4.2-6.2 Good Control : 6.3-7.2 Fair Control : 7.3-8.2 Poor Control : >8.3
Mean Blood Glucose levels : of last 03months	119.18	mg/dl	

### NOTE

\*As per the new 2009 update of American Diabetes Association regarding HbA1C & Mean Blood Glucose relationship.

This test is used to monitor diabetic patients compliance with the therapeutic regimen and long term blood glucose control. It's level is proportional to both the average blood glucose concentration and the life span of the red blood cells (RBC) in circulation. HbA1c values are free of day to day glucose fluctuations and are unaffected by exercise or recent food intake.

Dr. Niti Adhwaryu  
M.D. Pathology  
Reg. No. G-34888

Dr. Priya Kriplani  
M.D. Pathology.  
Reg. No. G-46004

LAB

LAB USE ONLY (Entered by :AP Enter Date/Time:08/04/2023 2:15:00 PM) (Verify by :OP1 Verify Date/Time:08/04/2023 2:26:00 PM)



**Dr Harsh Pandya**  
(MD)  
Consultant Pathologist  
Reg. No.: G-32582

**Dr. Priya Kriplani**  
(MD)  
Consultant Pathologist  
Reg. No.: G-46004

302, Trivia Complex, Natubhai Circle, Race Course, Vadodara. ☎: +91 88660 09950 / 74050 09950 ✉: bdi95950@gmail.com

Laboratory results serve as an aid to diagnosis & should be interpreted in relation to clinical findings. Please refer back to laboratory in case of any discrepancy.



Scanned with OKEN Scanner

  
**Heart & General Clinic**

iCure Heart& Diet Clinic, 402, Epsil on tower, opp Pasha bhai park, Race course, Vadodara

**Name** : NIRMAL SHARMA  
**Ref By** : ICURE HEART & DIET CLINIC

**Age/Sex** : 40 Yrs./M  
**Date** : 08/04/2023  
**Report ID.** : 4

**EXAMINATION OF URINE**

<u>TEST</u>	<u>RESULT</u>	<u>UNIT</u>
Sample	: FASTING	
<b><u>PHYSICAL EXAMINATION</u></b>		
Quantity	: 20	mL
Colour	: PALE YELLOW	
Transperancy	: CLEAR	
Specific Gravity	: 1.030	
Reaction	: ACIDIC	
Deposits	: ABSENT	
<b><u>CHEMICAL EXAMINATION</u></b>		
Albumin	: NIL	
Sugar	: NIL	
Acetone	: ABSENT	
Bile Salts	: ABSENT	
Bile Pigments	: ABSENT	
Urobilinogen	: NORMAL : ~ < 1.0 mg/dL	
Occult Blood	: ABSENT	
Nifrate	: ABSENT	
<b><u>MICROSCOPIC EXAMINATION</u></b>		
Pus Cells	: 0-1 / hpf	
RBC	: NIL	
Epithelial Cells	: NIL	
Crystals	: NIL	
Amorphous Phosphate	: NIL	
Cast	: NIL	



END OF REPORT

  
**Heart & General Clinic**

iCure Heart& Diet Clinic, 402, Epsil on tower, opp Pasha bhai park, Race course, Vadodara

**Name** : NIRMAL SHARMA  
**Ref By** : ICURE HEART & DIET CLINIC

**Age/Sex** : 40 Yrs./M  
**Date** : 08/04/2023  
**Report ID.** : 4

**HAEMOGRAM PROFILE**

<u>TEST</u>	<u>RESULT</u>
Blood Group	: * B *
Rh Factor (Anti D.)	: * POSITIVE *

**BIOCHEMISTRY**

**FASTING (FBS)**

Blood Glucose : 99.0 mg/dL 70 - 110 mg/dL

**POST-PRANDIAL**

Blood Glucose : 107.0 mg/dL 80 - 140 mg/dL

*Done By Fully Auto Analyzer MIURA, A-1004*



END OF REPORT

  
**Heart & General Clinic**

**2D Echocardiography & Color Doppler Report**

iCure Hear care, 402, Epsilon tower, opp Pasha bhai park, Race course, Vadodara

**Patient Name: Mr Nirmal Sharma**

**Dates: 08 / 04 / 2023**

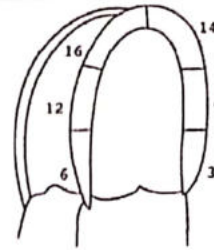
**Age Gender: male - 40 Years**

**M. Mode Study:**

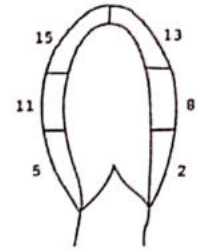
<b>LA</b>	<b>37</b>	<b>IVS</b>	<b>10</b>	<b>PWD</b>	<b>10</b>
<b>AO</b>	<b>22</b>	<b>LVDs</b>	<b>25</b>	<b>LVDD</b>	<b>47</b>

**Doppler Study:**

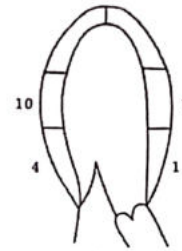
<b>Mitral Valve</b>	<b>E: 0.62 A: 0.98</b>
<b>Aortic Valve</b>	<b>Normal</b>
<b>Tricuspid Valve</b>	<b>Normal</b>
<b>Pulmonary Valve</b>	<b>Normal</b>



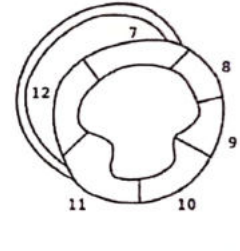
Apical 4 chamber view



Apical 2 chamber view



Apical 3 chamber view



Parasternal short axis view

**Conclusion:**

- **Normal LV Systolic function**
- **LVEF: 58 % ,No RWMA**
- **Cardiac Chambers: Normal**
- **Diastolic function: Normal**
- **TR: No PAH: No RVSP: 17mmhg**
- **No Ms , No MR**
- **No AR , No AS**
- **ASD/VSD/PDA/Co-A : No**
- **No Clots or vegetations found**
- **IVC: 10mm size with Normally collapsive**



**Dr. Krish P. Vaidya**  
 MD, PGCC  
 Associate Consultant-Cardiology  
 Reg.No.G-50510

**Dr. Krish P Vaidya**  
 Consultant Cardiologist, Diabetologist  
 & General Physician

**Note:**

Normal 2D echo report does not rule out cardiac diseases  
 this report shall not be used for Medico legal purposes,  
 Clinical Correlation advisable.

 icure™  
**Heart & General Clinic**

NAME : Mr Nirmal Sharma	AGE : 40Y/M	DATE : 08/04/2023
-------------------------	-------------	-------------------

**ULTRASONOGRAPHY OF WHOLE ABDOMEN**  
(Screening Only)

**Liver** is normal in size and echotexture and shows normal parenchymal reflectivity. No focal lesion is seen. Hepatic veins appear normal. There is no evidence of any dilated intra hepatic billiary radicals.

**Portal Vein** appears normal in diameter.

**Common Bile Duct** is of normal diameter.

**Gallbladder** is physiologically distended with normal wall thickness. There is no evidence of gallstones. No evidence of peri-cholecystic fluid or probe tenderness.

**Pancreas** is normal in size and shows homogenous reflectivity. There is no evidence of any calcification or ductal dilatation.

**Spleen** is normal size and shows a homogenous echotexture. There is no evidence of any focal lesion.

**Both Kidneys** are normal in position and size. They show normal cortical reflectivity and cortico-medullary distinction. Right kidney measures 95x41mm. Left kidney measures 97x42mm. There is no evidence of calculi, hydronephrosis or mass seen.

**Bladder** is well distended and shows normal wall thickness. No evidence of intra-luminal mass or calculi.

**Prostate gland** is normal in size . it has smooth outlines and normal reflectivity

There is no evidence of ascites.

No evidence of any gross bowel mass seen.

No evidence of any aorto-caval or mesenteric root lymphadenopathy.

No mass or collection in right iliac fossa.

Conclusion : No Sonographic abnormality seen.



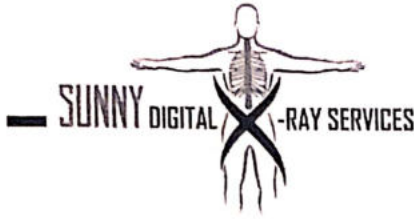*Mehul Prajapati*

**DR. MEHUL PRAJAPATI**  
**CONSULTANT RADIOLOGIST**



icure™  
Heart & General Clinic

iCure Heart& Diet Clinic, 402, Epsil on tower, opp Pasha bhai park, Race course, Vadodara



Sunny K. Machhi  
+91 87585 30074  
+91 83205 61551  
sunnydigitalxray@yahoo.com

NAME	NIRMAL SHARMA	AGE/SEX	40/MALE
REF BY	I CURE HEART & DIET CLINIC	DATE	08-04-2023

**X-RAY CHEST PA VIEW (PORTABLE)**

**FINDING**

BOTH LUNGS FIELDS ARE NORMAL .

REMAINING LUNG FIELDS ARE NORMAL.

BOTH COSTOPHRENIC RECESS ARE CLEAR.

CARDIAC SIZE WITHIN NORMAL LIMITS.

MEDIASTINUM AND BONY THORACIC CAGE REVEAL NO ABNORMALITY.

**IMPRESSION :NORMAL LUNGS HEART AND MEDIASTUINUM..**

**DR.HIMANI VIRAPARA**  
Regn. No: G.28771  
M.D. [Radiodiagnosis]  
(CONSULTANT RADIOLOGIST)

