

1947  
1800 300 1947  
help@uidai.gov.in  
www.uidai.gov.in  
P.O. Box No. 1947,  
Bengaluru-560 001

6940 9048 7364  
VID : 9127 8190 8146 8966

Address:  
S/O Gaurishor Bhandari, C/2-467, Azad Pur  
Village, Near BCC Modern Public School, New  
Delhi, New Delhi, North West Delhi, Delhi - 110033

Download Date: 24/10/2019  
Generation Date: 04/02/2012

भारत  
भारतीय रिपब्लिक प्रदान की गई है।  
QR Code with Photograph  
भारत

युवराज भंडारी

Dr. NITIN AGARWAL  
MBBS, MD  
Regn. No. DMG-R-1436


भारत सरकार

युवराज भंडारी  
Yuvraj Bhandari  
जन्म तिथि / DOB: 05/11/1963  
पुरुष / MALE  
Mobile No.: 7701821487  
6940 9048 7364  
VID : 9127 8190 8146 8966

PLUS ULTRASOUND LAB  
Harsh Vihar, Pitam Pura,  
Delhi-110034  
Ph. 011-42480101, 9599913051  
E-mail: oneplusul@gmail.com

मेरा आधार, मेरी पहचान





*[Handwritten signature]*

Dr. NITIN AGARWAL  
MBBS, MD  
Regn. No. DMC-R-1436

*अवकाश मंडरी*

ONEPLUS ULTRASOUND LAB  
47, Harsh Vihar, Pitam Pura,  
Delhi-110034  
Ph. 011-42480101, 9599913051  
E-mail: oneplusul@gmail.com

# ONEPLUS ULTRASOUND LAB

47, HARSH VIHAR, PITAMPURA, DELHI- 110034

Mr. YUVRAJ BHANDARI  
Age : 59M  
Ref. by : MEDIWHEEL  
Indication1 :  
Indication2 :  
Indication3 :  
COMMENTS : Normal ECG.

ID : 1907  
H/Wt : 173/54  
Recorded : 12-3-2022 11:39  
Medication1 :  
Medication2 :  
Medication3 :

*Yuvraj Bhandari*

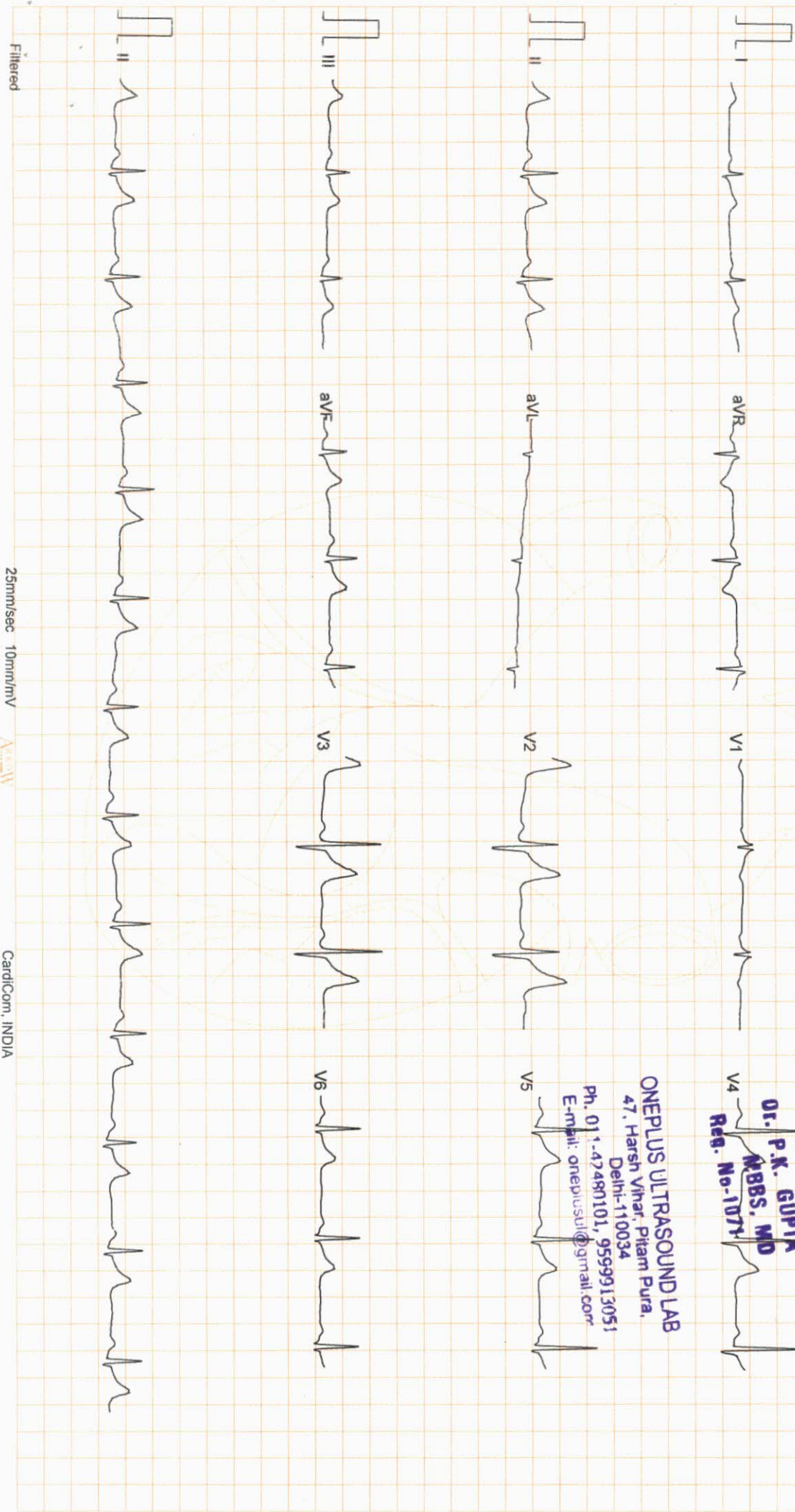
BPM : 75  
BP : 134/86  
P Axis : 73 deg  
QRS Axis : 78 deg  
T Axis : 71 deg

Unconfirmed Report Reviewed By:  
Cardiologist

P duration : 96 msec  
PR duration : 146 msec  
QRS duration : 96 msec  
QT Interval : 306 msec  
QTc Interval : 332 msec  
Raw E. C. G. (Seq)

*Dr. P.K. Gupta*  
**Dr. P.K. GUPTA**  
**MBBS, MD**  
Reg. No-1074

**ONEPLUS ULTRASOUND LAB**  
47, Harsh Vihar, Pitam Pura,  
Delhi-110034  
Ph. 011-47480101, 9599913051  
E-mail: oneplusul@gmail.com



Filtered

25mm/sec 10mm/mV

AccuV

CardiCom, INDIA

# ONEPLUS ULTRASOUND LAB

47, HARSH VIHAR PITAMPURA DELHI 110034

Mr. YUVRAJ BHANDARI

ID : 993

TREADMILL TEST SUMMARY REPORT

Age/Sex : 59/M

Ht/Wt : 173/54

Protocol: BRUCE

Ref. by : MEDIWHEEL

Recorded : 12-3-2022 11:43

Indication1 :

History:

Indication2 :

Medication1 :

Indication3 :

Medication2 :

Medication3 :

PHASE	PHASE TIME	STAGE TIME	SPEED (Km./Hr.)	GRADE (%)	H.R. (BPM)	B.P. (mmHg)	RPP X100	II	ST LEVEL (mm) V2	V5	METS
SUPINE											
STANDING											
STAGE 1	2:59	2:59	2.70	10.00	83	134/86	111	1.4	3.2	1.4	4.80
STAGE 2	5:59	2:59	4.00	12.00	120	150/90	180	1.6	2.8	1.5	7.10
STAGE 3	8:44	2:44	5.40	14.00	138	160/92	220	1.2	2.5	1.2	9.76
PEAK EXER	8:58	2:58			139	160/92	222	1.1	2.0	1.1	9.98
RECOVERY	2:59	2:59	0.00	0.00	79	136/86	107	0.8	1.8	0.6	

**RESULTS**

Exercise Duration : 8:58 Minutes  
 Max Heart Rate : 139 bpm 86 % of target heart rate 161 bpm  
 Max Blood Pressure : 160/92 mmHg  
 Max Work Load : 9.98 METS  
 Reason of Termination :

*Negative for ischemic work*

**ONEPLUS ULTRASOUND LAB**  
 47, Harsh Vihar, Pitam Pura,  
 Delhi-110034  
 Ph. 011-42480101, 9599913051  
 E-mail: oneplusul@gmail.com

*[Signature]*  
**DR. P. K. GUPTA**  
 Cardiologist  
**M.B.B.S., MD**  
 Reg. No-11071

*[Signature]*



# ONEPLUS ULTRASOUND LAB

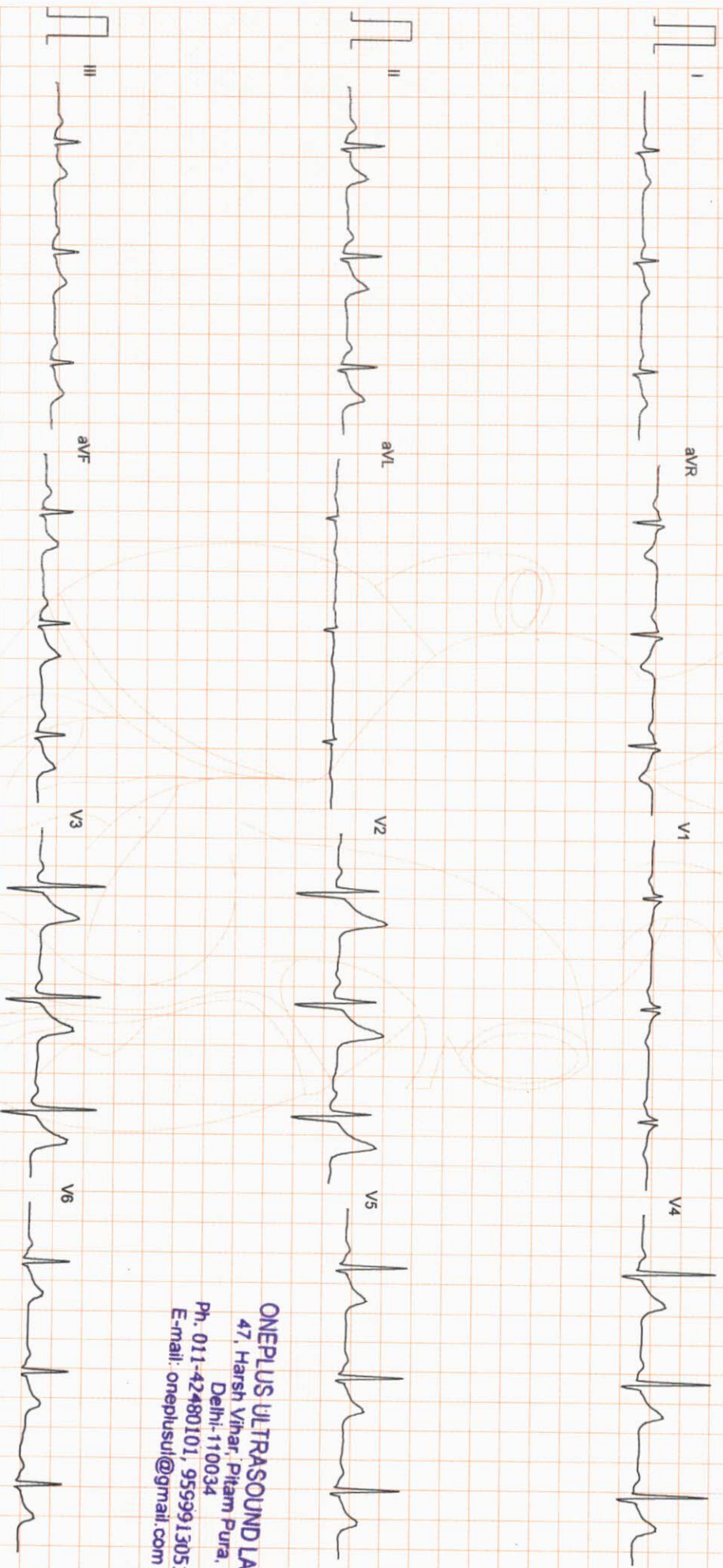
SUPINE  
PRETEST

ST @ 10mm/mV  
80ms PostJ

Mr: YUVRAJ BHANDARI  
I.D. : 993  
AGE/SEX : 59/M

RATE : 83 BPM  
B.P. : 134/86 mmHg

RAW E.C.G.



**ONEPLUS ULTRASOUND LAB**  
47, Harsh Vihar, Pitam Pura,  
Delhi-110034  
Ph. 011-42480101, 9599913051  
E-mail: oneplusul@gmail.com

Filtered

25mm/sec 10mm/mV

AVR aVL aVF

V1 V2 V3 V4 V5 V6  
CardiCom, INDIA Ph.:091-731-2620740, TeleFax:091-731-2431214





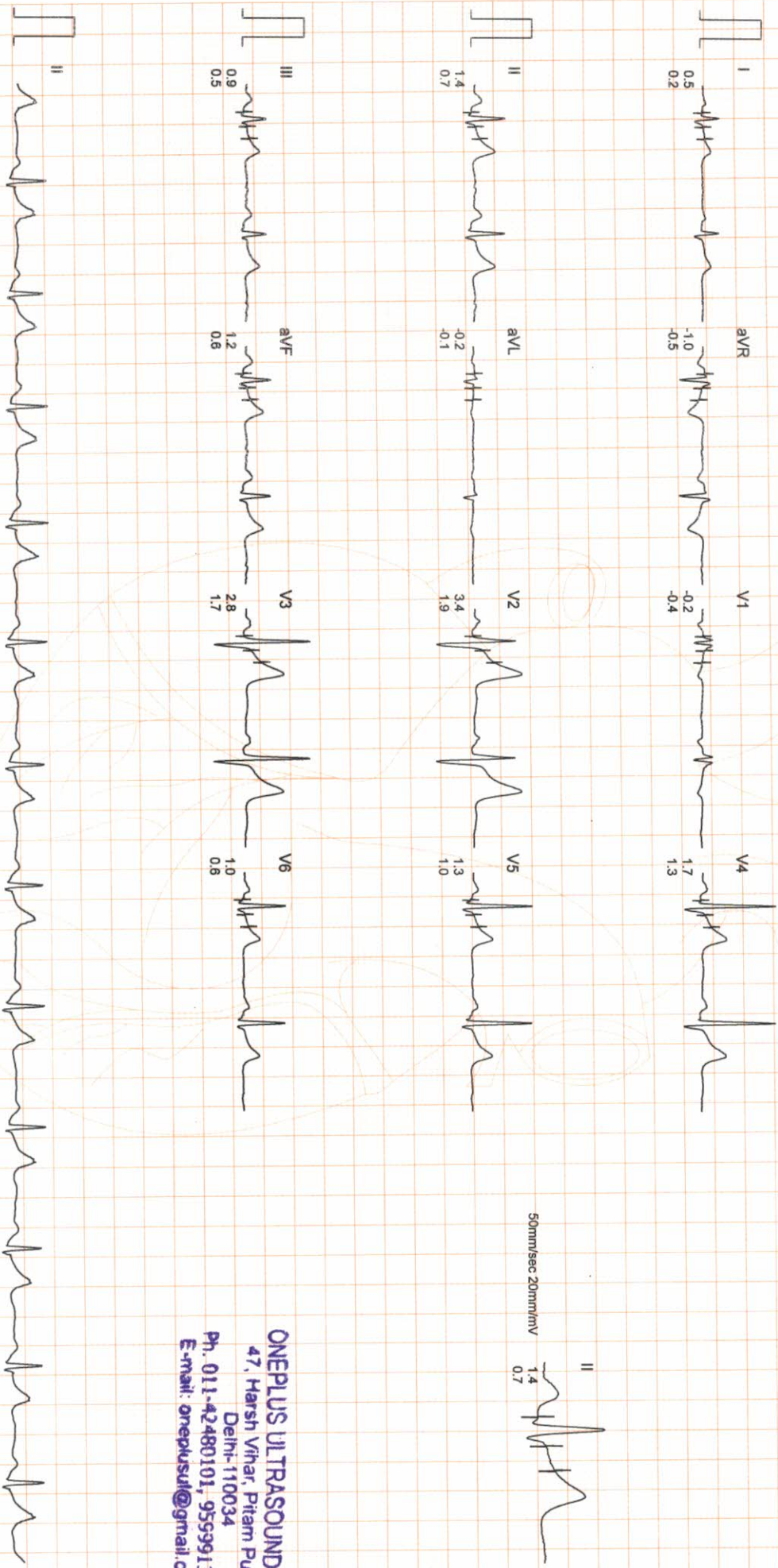
# ONEPLUS ULTRASOUND LAB

STANDING  
PRETEST

ST @ 10mm/mV  
80ms PostJ

LINKED MEDIAN

M: YUVRAJ BHANDARI  
I.D. : 993  
AGE/SEX : 59/M  
RECORDED : 12-3-2022 11:43  
RATE : 75 BPM  
B.P. : 134/86 mmHg



**ONEPLUS ULTRASOUND LAB**  
47, Harsh Vihar, Pitam Pura,  
Delhi-110034  
Ph. 011-42480101, 9559913051  
E-mail: [oneplusul@gmail.com](mailto:oneplusul@gmail.com)



# ONEPLUS ULTRASOUND LAB

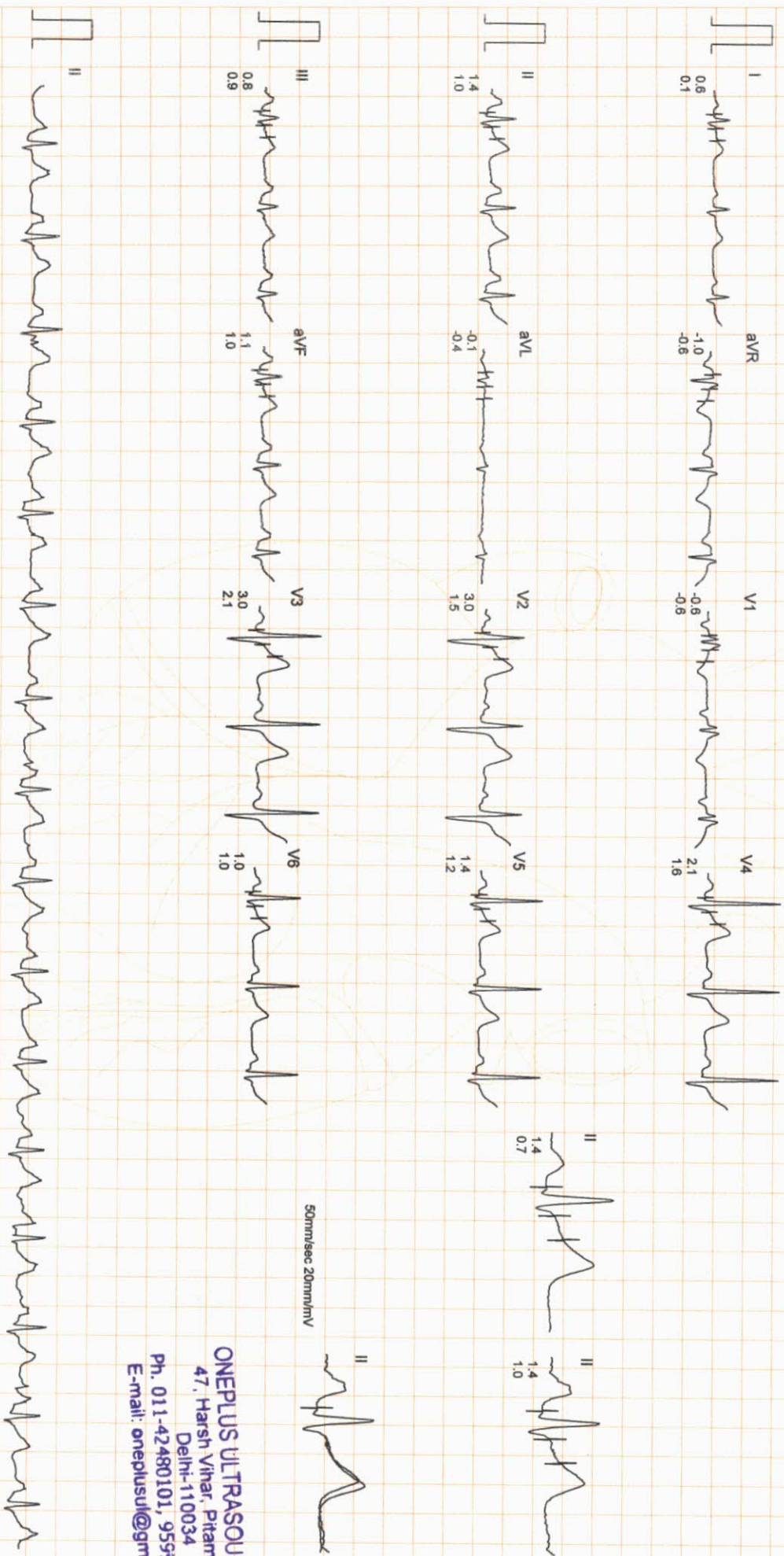
Mr: YUVRAJ BHANDARI  
 I.D. : 993  
 AGE/SEX : 59/M  
 RECORDED : 12-3-2022 11:43

RATE : 99 BPM  
 B.P. : 134/86 mmHg

BRUCE  
 EXERCISE 1  
 PHASE TIME : 2:59  
 STAGE TIME : 2:59

ST @ 10mm/mV  
 80ms PostI  
 SPEED : 2.7 Km./Hr.  
 GRADE : 10.0 %

LINKED MEDIAN



Filtered Computer Corrected Baseline 25mm/sec 10mm/mV CardCom, INDIA Ph.:091-731-2620740, TeleFax:091-731-2431214

ONEPLUS ULTRASOUND LAB  
 47, Harsh Vihar, Pitam Pura,  
 Delhi-110034  
 Ph. 011-42480101, 9559913051  
 E-mail: oneplusul@gmail.com



# ONEPLUS ULTRASOUND LAB

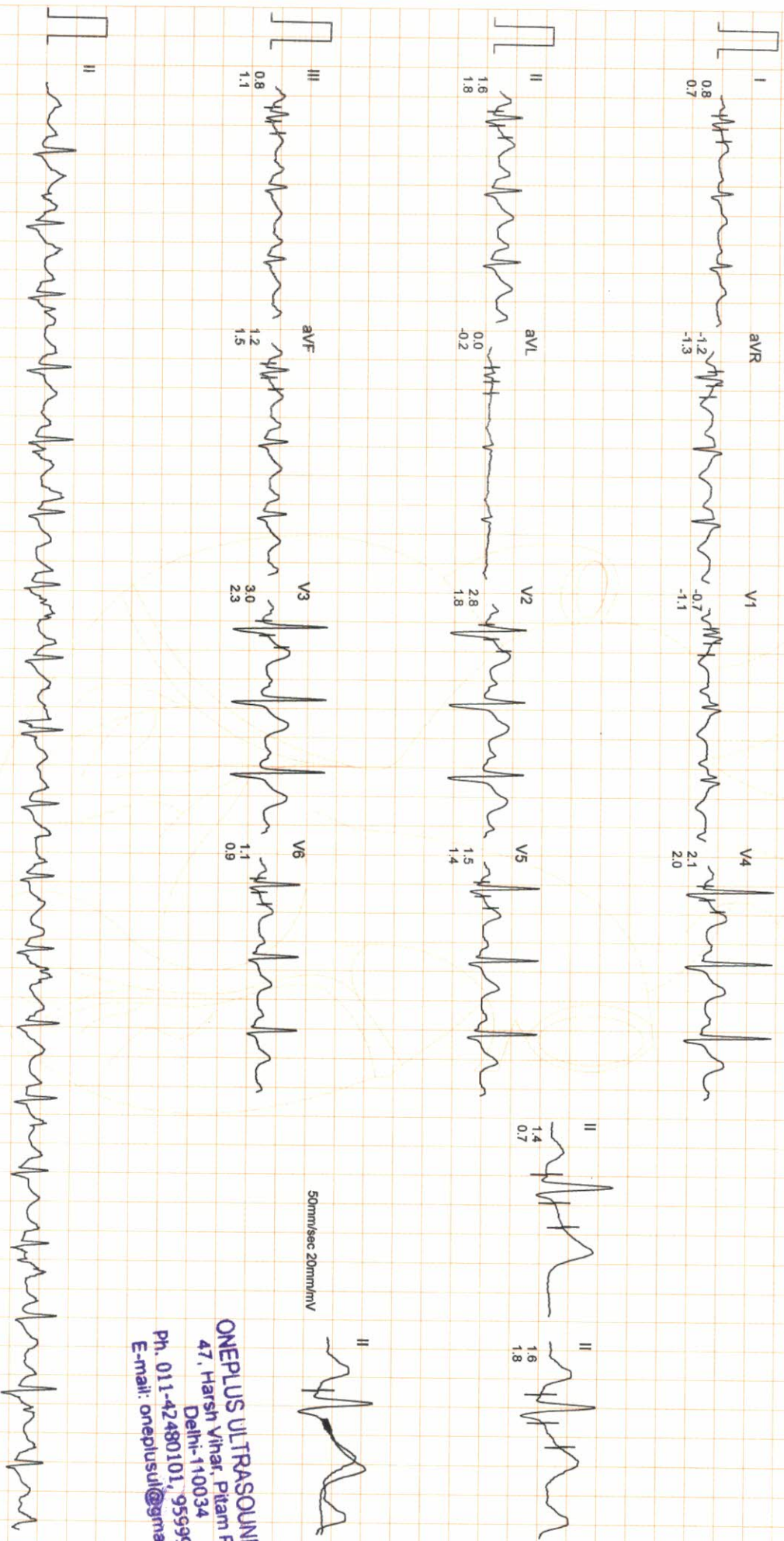
Mr: YUVRAJ BHANDARI  
I.D. : 993  
AGE/SEX : 59/M  
RECORDED : 12-3-2022 11:43

RATE : 120 BPM  
B.P. : 150/90 mmHg

BRUCE  
EXERCISE 2  
PHASE TIME : 5:59  
STAGE TIME : 2:59

ST @ 10mm/mV  
80ms PostJ  
SPEED : 4.0 Km./Hr.  
GRADE : 12.0 %

LINKED MEDIAN



50mm/sec 20mm/mV

**ONEPLUS ULTRASOUND LAB**  
47, Harsh Vihar, Pitam Pura,  
Delhi-110034  
Ph. 011-42480101, 9559913051  
E-mail: oneplusul@gmail.com

14

# ONEPLUS ULTRASOUND LAB

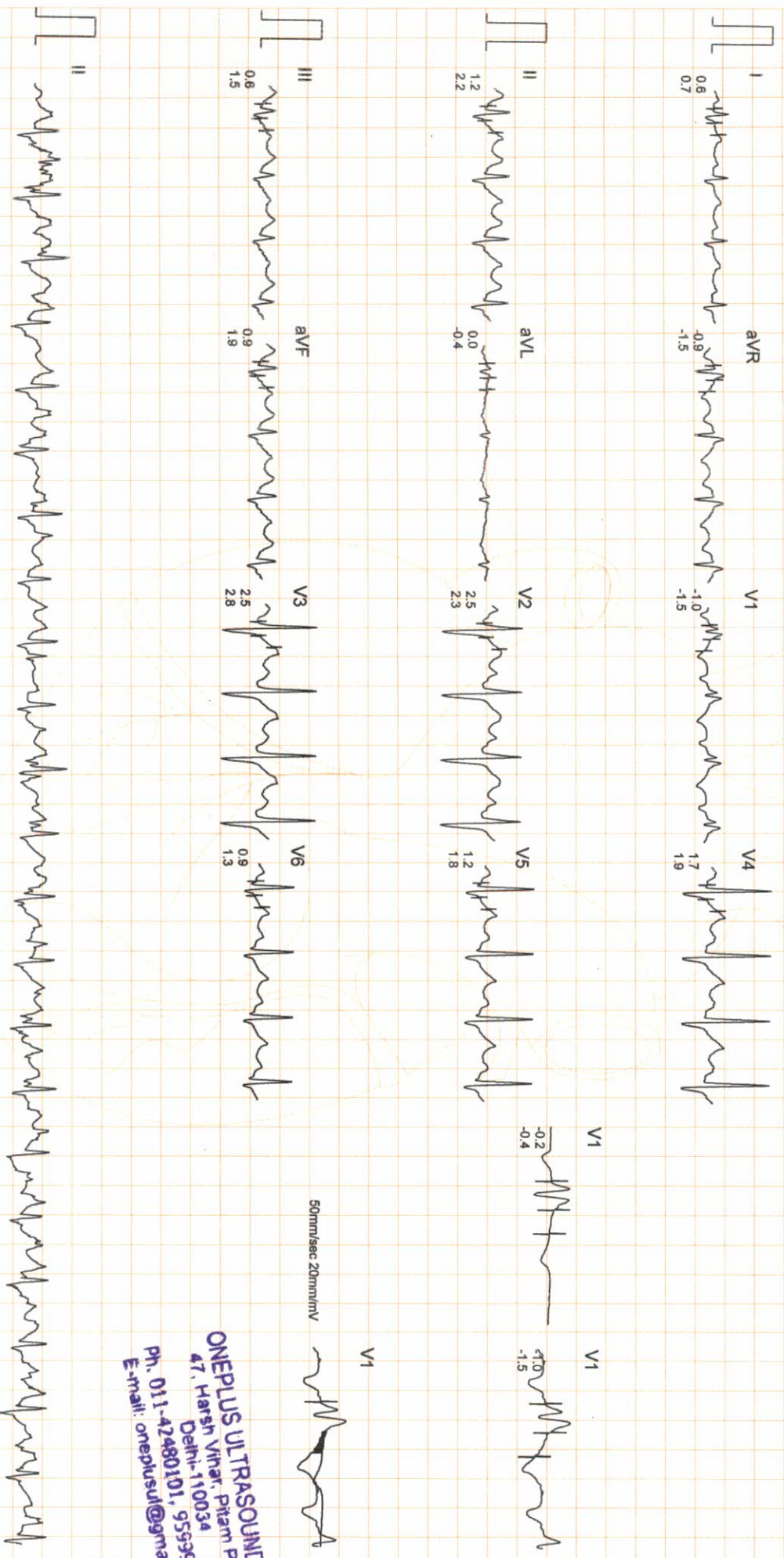
Mr. YUVRAJ BHANDARI  
 I.D. : 993  
 AGE/SEX : 59/M  
 RECORDED : 12-3-2022 11:43

RATE : 138 BPM  
 B.P. : 160/92 mmHg

BRUCE  
 EXERCISE 3  
 PHASE TIME : 8:44  
 STAGE TIME : 2:44

ST @ 10mm/mV  
 80ms PostJ  
 SPEED : 5.4 Km./Hr.  
 GRADE : 14.0 %

LINKED MEDIAN



ONEPLUS ULTRASOUND LAB  
 47, Harsh Vihar, Pitam Pura,  
 Delhi-110034  
 Ph. 011-42480101, 9559951305  
 E-mail: oneplusul@gmail.com





# ONEPLUS ULTRASOUND LAB

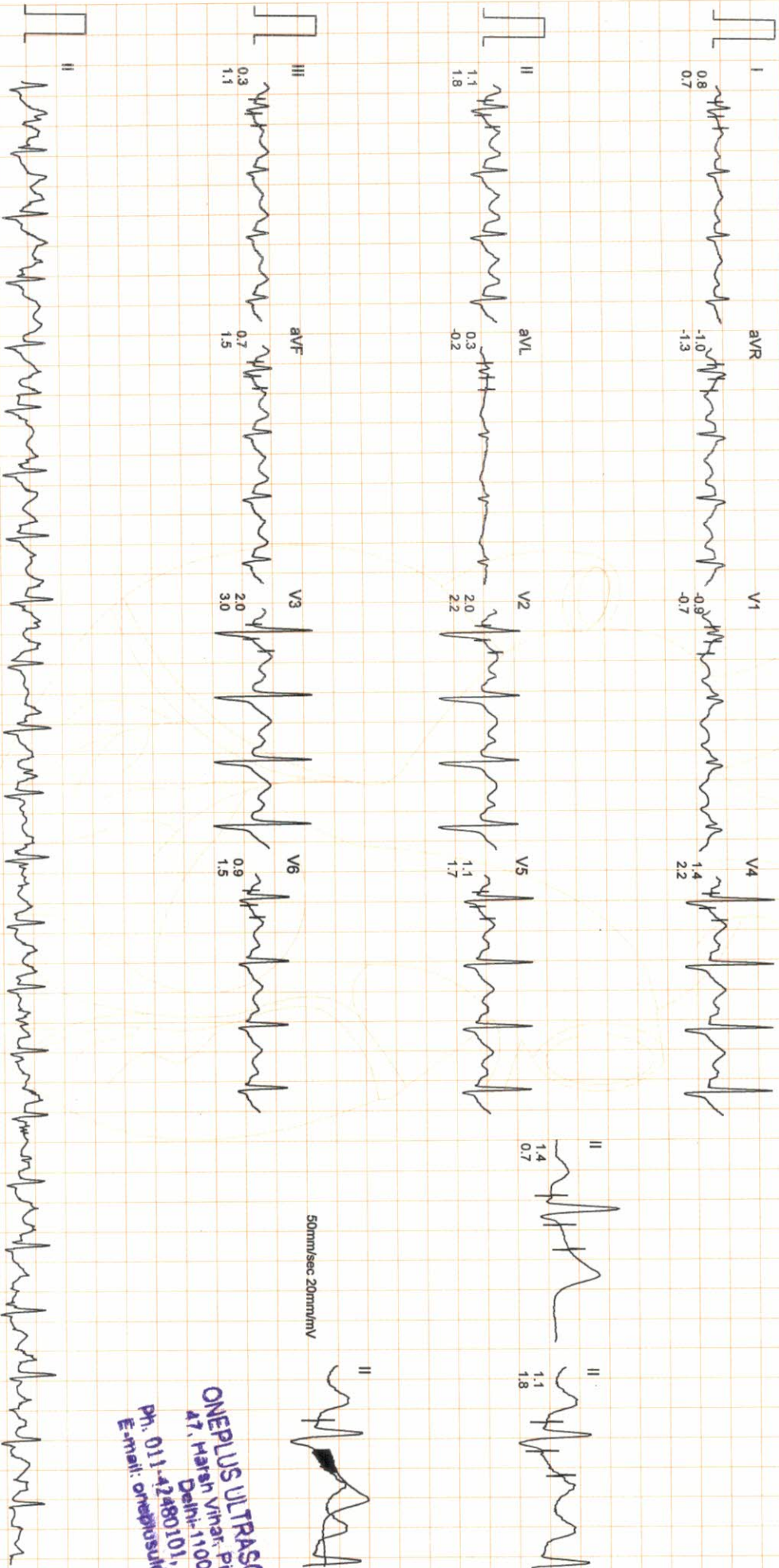
MR. YUVRAJ BHANDARI  
 I.D. : 993  
 AGE/SEX : 59/M  
 RECORDED : 12-3-2022 11:43

RATE : 139 BPM  
 B.P. : 160/92 mmHg

BRUCE  
 PEAK EXER  
 PHASE TIME : 8:58  
 STAGE TIME : 2:58

ST @ 10mm/mv  
 80ms PostJ  
 SPEED : 5.4 Km./Hr.  
 GRADE : 14.0 %

LINKED MEDIAN



ONEPLUS ULTRASOUND LAB  
 47, Harsh Vihar, Pitam Pura,  
 Delhi-110034  
 Ph. 011-42480101, 9559913051  
 E-mail: oneplusul@gmail.com

100

# ONEPLUS ULTRASOUND LAB

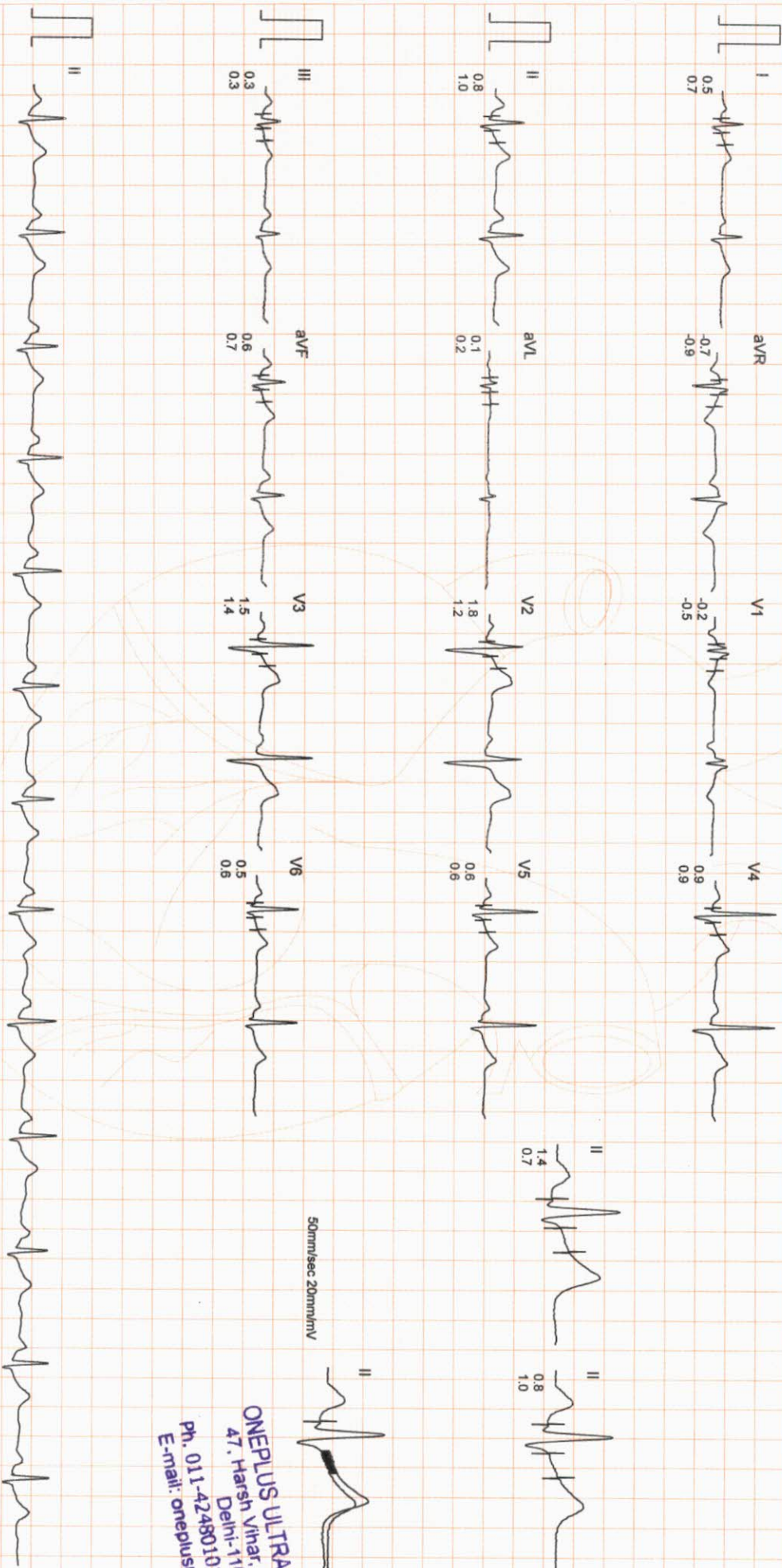
Mr: YUVRAJ BHANDARI  
I.D. : 993  
AGE/SEX : 59/M  
RECORDED : 12-3-2022 11:43

RATE : 79 BPM  
B.P. : 136/86 mmHg

BRUCE  
RECOVERY  
PHASE TIME : 2:59

ST @ 10mm/mV  
80ms PostJ  
SPEED : 0.0 Km./Hr.  
GRADE : 0.0 %

LINKED MEDIAN



ONEPLUS ULTRASOUND LAB  
47, Harsh Vihar, Pitam Pura,  
Delhi-110034  
Ph. 011-42480101, 9599913051  
E-mail: oneplusul@gmail.com

Filtered

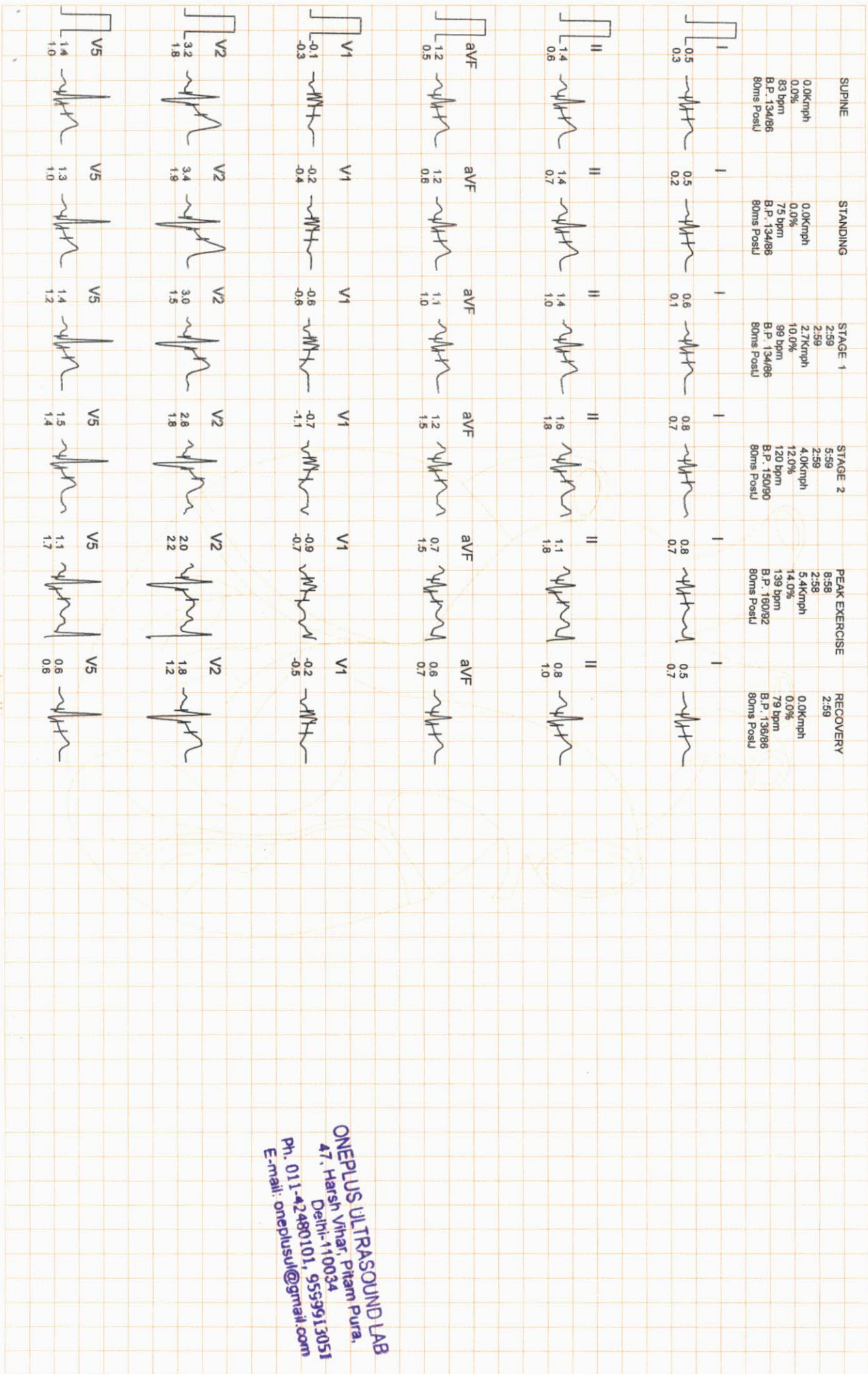
Computer Corrected Baseline

25mm/sec 10mm/mV

Area IV

CardiCom, INDIA Ph.:091-731-2620740, TeleFax:091-731-2431214





ONEPLUS ULTRASOUND LAB  
 47, Harsh Vihar, Pitam Pura,  
 Delhi-110034  
 Ph. 011-42480101, 9559913051  
 E-mail: oneplusul@gmail.com



# ONEPLUS ULTRASOUND LAB









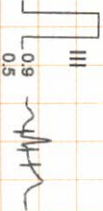



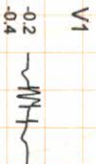


## COMPARISON REPORT

STANDING  
 0.0kmph  
 0.0%  
 75 bpm  
 B.P. 134/86  
 80ms PostJ

PEAK EXERCISE  
 8:58  
 2:58  
 5.4kmph  
 14.0%  
 139 bpm  
 B.P. 160/92  
 80ms PostJ

STANDING  
 0.0kmph  
 0.0%  
 75 bpm  
 B.P. 134/86  
 80ms PostJ

PEAK EXERCISE  
 8:58  
 2:58  
 5.4kmph  
 14.0%  
 139 bpm  
 B.P. 160/92  
 80ms PostJ



**ONEPLUS ULTRASOUND LAB**  
 47, Harsh Vihar, Pitam Pura,  
 Delhi-110034  
 Ph. 011-42480101, 9599913051  
 E-mail: onepiusul@gmail.com



# OnePLUS Ultrasound Lab

QUALITY FIRST... ALWAYS!

**Dr. Nitin Agarwal**  
Pathologist & Director  
Ex. Sr. Res. MAMC  
& Lok Nayak Hospital  
Ex. Chief of Lab Dr. Lal Path Labs.

**Dr. Pooja (Garg) Agarwal**  
Radiologist & Director  
MAMC & Lok Nayak Hospital



NAME	:Mr. YUVRAJ BHANDARI	Barcode No	:10115138
AGE/GENDER	:59 YRS/Male	SPECIMEN DATE	:12/Mar/2022 09:22AM
PATIENT ID	:92431	SPECIMEN RECEIVED	:12/Mar/2022 09:32AM
REFERRED BY	:Dr. MEDIWHEEL	REPORT DATE	:12/Mar/2022 04:34PM
CENTRE NAME	:ONEPLUS ULTRASOUND LAB	LAB NO.	:012203120011

Test Name	Result	Unit	Ref. Range
-----------	--------	------	------------

## HAEMATOLOGY

### Health checkup 2 Male

<b>Glycosylated Hemoglobin (HbA1c)</b>	5.1	%	Non Diabetic adults <5.7 Prediabetic (at risk) 5.7-6.4 Diabetes >6.4
--	-----	---	--

<b>Estimated average blood glucose (eag)</b>	100
--	-----

#### Reference range (mg/dl):

90 - 120:Excellent control, 121 - 150:Good Control, 151 - 180:Average Control, 181 - 210:Action Suggested

>211:Panic value

<b>BLOOD GROUP (ABO)</b>	O
<b>Rh typing</b>	POSITIVE

#### NOTE :

- \* Apart from major A,B,H antigens which are used for ABO grouping and Rh typing, many minor blood group antigens exist. Agglutination may also vary according to titre of antigen and antibody.
- \* So before transfusion, reconfirmation of blood group as well as cross-matching is needed.
- \* Presence of maternal antibodies in newborns, may interfere with blood grouping.
- \* Auto agglutination (due to cold antibody, falciparum malaria, sepsis, internal malignancy etc.) may also cause erroneous result.

## CBC

Haemoglobin	13.1	g/dl	13.0-17.0
Total Leucocyte Count	4690	/cumm	4000-10000
<b>Differential leucocyte count</b>			
Neutrophils	63.8	%	40-80
Lymphocyte	25.70	%	20-40
Monocytes	6.40	%	2-10
Eosinophils	3.4	%	1-6
Basophils	0.7	%	0-2
RBC Count	4.09	million/cumm	4.5 - 5.5

Checked By.

DR. NITIN AGARWAL  
MBBS,MD(PATHOLOGIST)

47, Harsh Vihar, Pitampura, New Delhi-110034 | Ph.: 011-4288101, 9599913051  
E-mail: oneplusul@gmail.com | Web.: www.oneplusul.in

Page 1 of 5





# OnePLUS Ultrasound Lab

— QUALITY FIRST... ALWAYS! —

**Dr. Nitin Agarwal**  
Pathologist & Director  
Ex. Sr. Res. MAMC  
& Lok Nayak Hospital  
Ex. Chief of Lab Dr. Lal Path Labs.

**Dr. Pooja (Garg) Agarwal**  
Radiologist & Director  
MAMC & Lok Nayak Hospital



NAME	:Mr. YUVRAJ BHANDARI	Barcode No	:10115138
AGE/GENDER	:59 YRS/Male	SPECIMEN DATE	:12/Mar/2022 09:22AM
PATIENT ID	:92431	SPECIMEN RECEIVED	:12/Mar/2022 09:32AM
REFERRED BY	:Dr. MEDIWHEEL	REPORT DATE	:12/Mar/2022 04:34PM
CENTRE NAME	:ONEPLUS ULTRASOUND LAB	LAB NO.	:012203120011

Test Name	Result	Unit	Ref. Range
PCV(Hematocrit)	41.8	%	40-50
MCV	<b>102.2</b>	fL	83-101
MCH	31.9	Pg	27-32
MCHC	<b>31.3</b>	G/dL	32-35
Platelet count	184000	/cumm	150000-450000
RDW-CV	13.6	%	11.4-14.0
ESR(WESTEGRENs METHOD)	15	mm in 1st hr	0-20

### BIOCHEMISTRY

<u>Blood sugar fasting</u>	98	mg/dL	70-110
<u>Blood sugar pp</u>	132	mg/dL	70.0-140.0
<u>Bun (blood urea nitrogen )</u>	12.50	mg/dl	8.4-25.7
<u>Uric acid, serum</u>	4.8	mg/dl	3.4-7.0
<u>Creatinine, serum</u>	0.75	mg/dl	0.60-1.1


### LFT(LIVER FUNCTION TEST)

Bilirubin Total	0.76	mg/dl	0.1-1.2
Bilirubin Conjugated	0.26	mg/dl	0-0.4
Bilirubin Unconjugated	0.50	mg/dl	up to 0.7
SGOT (AST)	26	U/L	0-35
SGPT (ALT)	22	U/L	<45.0
Alkaline phosphatase	74	U/L	40-129
Gamma glutamyl transpeptidase	22	U/L	<66
Total Protein	6.8	gm/dl	6.60 - 8.70
Albumin	3.8	g/dL	3.8-5.1
Globulin	3.00	gm/dl	1.8-3.4
Albumin/Globulin Ratio	1.27		1.10 - 2.50

### LIPID PROFILE

Cholesterol	158	mg/dl	50-200
Triglycerides	59	mg/dL	25-150

Checked By.

  
DR. NITIN AGARWAL  
MBBS, MD (PATHOLOGIST)

47, Harsh Vihar, Pitampura, New Delhi-110034 | Ph.: 011-42480103, 9599913051  
E-mail: [oneplusul@gmail.com](mailto:oneplusul@gmail.com) | Web.: [www.oneplusul.in](http://www.oneplusul.in)

Page 2 of 5

Clinical correlation is essential for final diagnosis. • If test results are unsatisfactory please contact personally or on phone. • This report is for perusal of doctors only.  
• All disputes Subject to Delhi Jurisdiction only. • Not for medicolegal purposes. • All congenital anomalies in a foetus may not be diagnosed in routine obstetric ultrasound.



# OnePLUS Ultrasound Lab

QUALITY FIRST... ALWAYS!

**Dr. Nitin Agarwal**  
Pathologist & Director  
Ex. Sr. Res. MAMC  
& Lok Nayak Hospital  
Ex. Chief of Lab Dr. Lal Path Labs.

**Dr. Pooja (Garg) Agarwal**  
Radiologist & Director  
MAMC & Lok Nayak Hospital



NAME	:Mr. YUVRAJ BHANDARI	Barcode No	:10115138
AGE/GENDER	:59 YRS/Male	SPECIMEN DATE	:12/Mar/2022 09:22AM
PATIENT ID	:92431	SPECIMEN RECEIVED	:12/Mar/2022 09:32AM
REFERRED BY	:Dr. MEDIWHEEL	REPORT DATE	:12/Mar/2022 04:34PM
CENTRE NAME	:ONEPLUS ULTRASOUND LAB	LAB NO.	:012203120011

Test Name	Result	Unit	Ref. Range
HDL Cholesterol	36	mg/dL	30-70
LDL cholesterol	110	mg/dL	<130
VLDL cholesterol	11.8	mg/dL	5-40
Cholesterol/HDL Ratio	4.4		Low Risk 3.3-4.97 Average Risk 4.4-7.1 Moderate Risk 7.1-11.0 High Risk >11.0
LDL/HDL Ratio	3.1		0 - 3.55

According to ATP III and NCEP guidelines

Parameter	Normal	Desirable	Borderline	High
Total cholesterol	<200	200-239		240
Triglycerides	<150	150-199	200-499	500
LDL	Optimal <100 Near Optimal 100-129	130-159	160-180	190
HDL	<40 : LOW 60 : HIGH			

## ENDOCRINOLOGY

### PSA TOTAL

Prostatic specific antigen, Total 1.20 ng/ml <4.0

< 40 years	0.21 to 1.72 ng/ml
40 - 49	0.27 to 2.19 ng/ml
50 - 59	0.27 to 3.42 ng/ml
60 - 69	0.22 to 6.16 ng/ml
> 69	0.21 to 6.77 ng/ml

### Notes:

PSA is principally produced by the glandular epithelium of the prostate, and is secreted in the seminal fluid. PSA is also present in

Checked By.

DR. NITIN AGARWAL  
MBBS, MD (PATHOLOGIST)

Dr NITIN AGARWAL  
MBBS, MD (Path)  
DMCR/01/13051

47, Harsh Vihar, Pitampura, New Delhi-110034 | Ph.: 011-42480101, 9599913051  
E-mail: oneplusul@gmail.com | Web.: www.oneplusul.in

Page 3 of 5



# OnePLUS Ultrasound Lab

QUALITY FIRST... ALWAYS!

**Dr. Nitin Agarwal**  
Pathologist & Director  
Ex. Sr. Res. MAMC  
& Lok Nayak Hospital  
Ex. Chief of Lab Dr. Lal Path Labs.

**Dr. Pooja (Garg) Agarwal**  
Radiologist & Director  
MAMC & Lok Nayak Hospital



NAME	:Mr. YUVRAJ BHANDARI	Barcode No	:10115138
AGE/GENDER	:59 YRS/Male	SPECIMEN DATE	:12/Mar/2022 09:22AM
PATIENT ID	:92431	SPECIMEN RECEIVED	:12/Mar/2022 09:32AM
REFERRED BY	:Dr. MEDIWHEEL	REPORT DATE	:12/Mar/2022 04:34PM
CENTRE NAME	:ONEPLUS ULTRASOUND LAB	LAB NO.	:012203120011

Test Name	Result	Unit	Ref. Range
-----------	--------	------	------------

urine and blood. PSA acts on seminal fluid to fluidify and increase sperm mobility. PSA levels rise in prostatic pathologies such as benign prostatic hyperplasia (BPH) or prostate cancer.

### THYROID PROFILE(T3,T4,TSH)

Triiodothyronine total [t3]	0.84	ng/dl	0.52-1.9
Thyroxine total [t4]	7.60	µg/dl	4.4 - 10.8
TSH (Thyroid Stimulating Hormone)	1.12	µIU/ml	0.25-5.0

### AGE WISE VARIATION IN TSH

AGE	TSH(µIU/ml)	AGE	TSH(µIU/ml)
1-4 weeks	1.00 - 19.0	16-20 yrs	0.25 - 5.0
1-12 mths	1.70 - 9.1	21 - 80 yrs	0.25 - 5.0
1-5 yrs	0.80 - 8.2	I <sup>st</sup> trimester	0.25 - 5.0
6-10 yrs	0.25 - 5.0	II <sup>nd</sup> trimester	0.50 - 5.0
11-15 yrs	0.25 - 5.0	III <sup>rd</sup> trimester	0.4 - 6.0

### Reference ranges - Interpretation of Diagnostic tests - (Jacques Wallach)

1. Primary hypothyroidism is accompanied by depressed serum T3 and T4 values and elevated serum TSH level.
2. Primary hyperthyroidism is accompanied by elevated serum T3 and T4 levels along with depressed TSH values.
3. Slightly elevated T3 levels may be found in pregnancy and estrogen therapy, while depressed levels may be encountered in severe illness, renal failure and during therapy with drugs like propranolol and propyl thiouracil.
4. Although elevated TSH levels are nearly always indicative of primary hypothyroidism, and may be seen in secondary thyrotoxicosis

Checked By.

47, Harsh Vihar, Pitampura, New Delhi-110034 | Ph.: 011-42486101, 9899913051  
E-mail: oneplusul@gmail.com | Web.: www.oneplusul.in

Dr. NITIN AGARWAL  
MBBS, MD (Path)  
Dr. NITIN AGARWAL  
MBBS, MD(PATHOLOGIST)

Page 4 of 5



# OnePLUS Ultrasound Lab

QUALITY FIRST... ALWAYS!

**Dr. Nitin Agarwal**  
Pathologist & Director  
Ex. Sr. Res. MAMC  
& Lok Nayak Hospital  
Ex. Chief of Lab Dr. Lal Path Labs.

**Dr. Pooja (Garg) Agarwal**  
Radiologist & Director  
MAMC & Lok Nayak Hospital



NAME	:Mr. YUVRAJ BHANDARI	Barcode No	:10115138
AGE/GENDER	:59 YRS/Male	SPECIMEN DATE	:12/Mar/2022 09:22AM
PATIENT ID	:92431	SPECIMEN RECEIVED	:12/Mar/2022 09:32AM
REFERRED BY	:Dr. MEDIWHEEL	REPORT DATE	:12/Mar/2022 02:01 PM
CENTRE NAME	:ONEPLUS ULTRASOUND LAB	LAB NO.	:012203120011

Test Name	Result	Unit	Ref. Range
-----------	--------	------	------------

## CLINICAL PATHOLOGY

### URINE ROUTINE

#### Physical examination

Quantity	15		ML
Colour	PALE YELLOW		
Transparency	CLEAR		CLEAR
Sp.gravity	1.015		1.010-1.030
pH	6.00		
Reaction	ACIDIC		ACIDIC

#### Chemical examination

Urine protein	NIL		NIL
Urine sugar	NIL		NIL
Bilirubin, urine	NEGATIVE		NEGATIVE
Urobilinogen	NORMAL		NORMAL
Ketones	NEGATIVE		NEGATIVE

#### Microscopic examination

<b>Pus cells.</b>	1-2	/HPF	0-2
Epithelial cells	1-2	/HPF	NIL
R.B.C.	NIL	/HPF	NIL
Casts	NIL	/HPF	NIL
Crystals	NIL	/HPF	NIL
Bacteria	NIL	/HPF	NIL
Others.	NIL	NIL	NIL

\*\*\* End Of Report \*\*\*

Checked By.

DR. NITIN AGARWAL  
MBBS,MD(PATHOLOGIST)

Dr NITIN AGARWAL

47, Harsh Vihar, Pitampura, New Delhi-110034 | Ph.: 011-42480101, 999913091

E-mail: oneplusul@gmail.com | Web.: www.oneplusul.in

DMG/R/01436

Page 5 of 5

Clinical correlation is essential for final diagnosis. • If test results are unsatisfactory please contact personally or on phone. • This report is for perusal of doctors only. • All disputes Subject to Delhi Jurisdiction only. • Not for medicolegal purposes. • All congenital anomalies in a foetus may not be diagnosed in routine obstetric ultrasound.



**OnePLUS**  
Ultrasound Lab  
— QUALITY FIRST... ALWAYS! —

**Dr. Nitin Agarwal**  
Pathologist & Director  
Ex. Sr. Res. MAMC  
& Lok Nayak Hospital  
Ex. Chief of Lab Dr. Lal Path Labs.

**Dr. Pooja (Garg) Agarwal**  
Radiologist & Director  
MAMC & Lok Nayak Hospital

<b>Name</b>	: Mr. YUVRAJ BHANDARI	<b>Age/Sex</b>	: 59 YRS/Male
<b>Ref. By</b>	: Dr. MEDIWHEEL	<b>Lab No</b>	: 012203120011
<b>Date</b>	: 12-Mar-2022	<b>Patient ID</b>	: LSHHI92431

**ULTRASOUND EXAMINATION---WHOLE ABDOMEN**

**Liver** is normal in size (13.1 cm) and normal in outline with normal echopattern. Intrahepatic biliary radicles are not dilated. No abscess or mass lesion seen. Hepatic veins, portal vein, IVC and aorta are normal. CBD is normal (3.7 mm) in caliber.

**Gall bladder** is well distended with anechoic lumen. Wall thickness is normal.

**Both kidneys** are normal in size, shape, position, outline and echopattern. Corticomedullary differentiation is maintained. No pelvicalyceal dilation or mass lesion is seen.

**Spleen** is normal in size and echotexture. No mass lesion seen.

**Pancreas** is normal in size, outline and echotexture.

**Urinary bladder** is normal in shape and position. No evidence of intravesical stone or mass seen.

**Prostate** is normal in size, shape and echopattern.

**Prostate measures** 3.4 x 3.0 x 4.4 cm. **Weight of prostate is 23 grams.**

No abnormal bowel wall thickening seen in right iliac fossa.

No free fluid seen anywhere in abdomen.

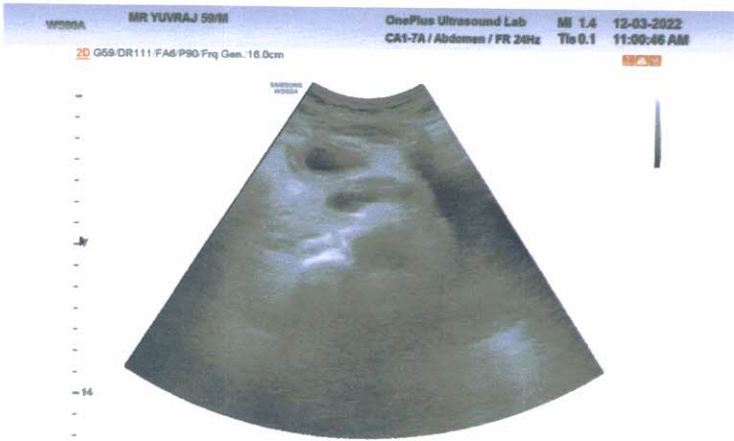
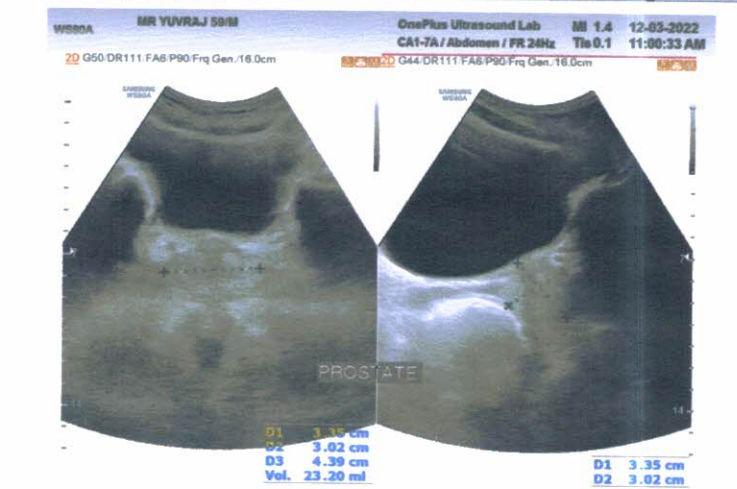
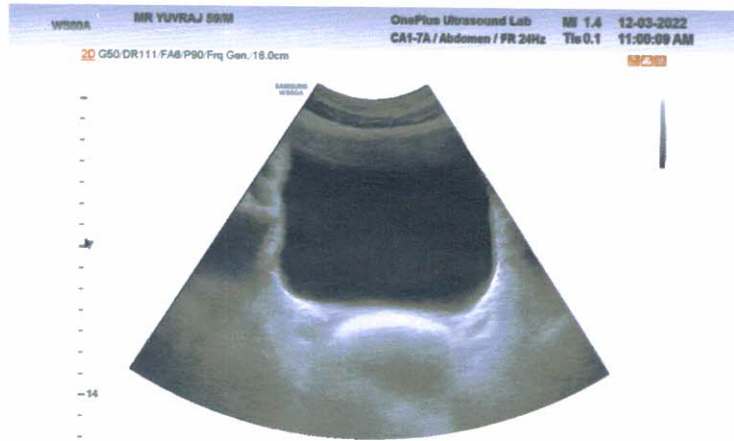
**IMPRESSION:**

- Normal study.

**DR. POOJA GARG**  
RADIOLOGIST  
REG NO- DMC/R/03398

**Dr. POOJA GARG**  
M.B.B.S., D.M.R.D  
Reg No. DMC/R/03398  
Radiologist

47, Harsh Vihar, Pitampura, New Delhi-110034 | Ph.: 011-42480101, 9599913051  
E-mail: oneplusul@gmail.com | Web.: www.oneplusul.in

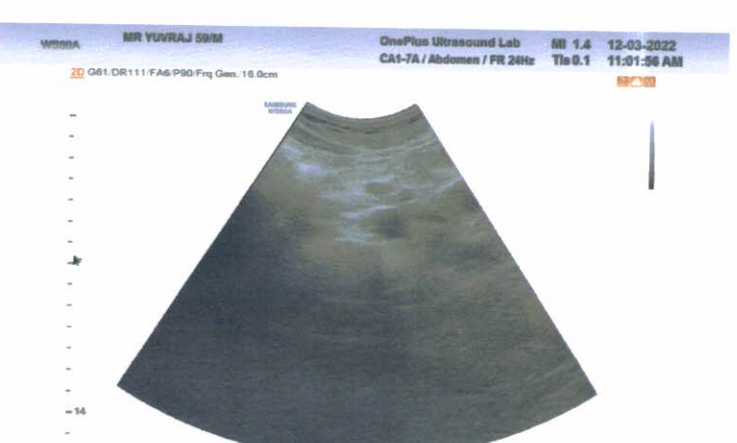
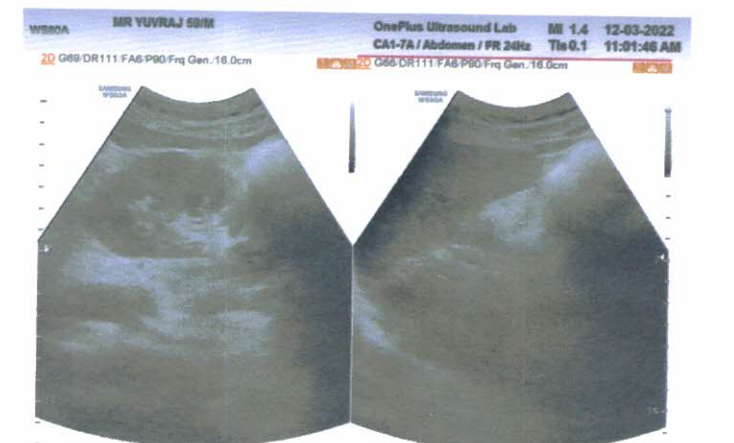
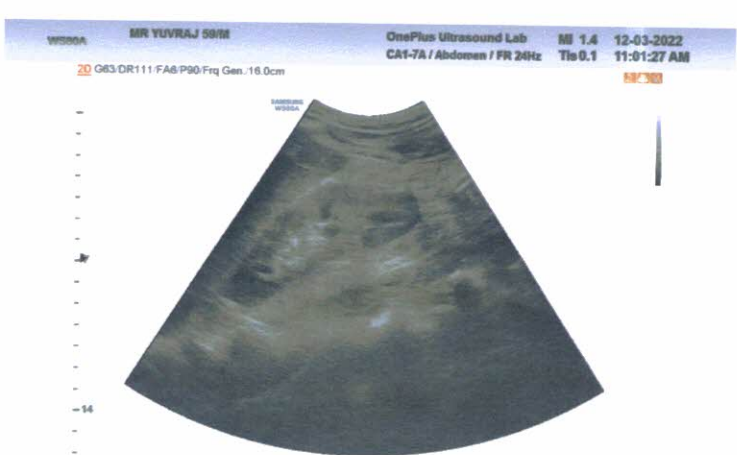
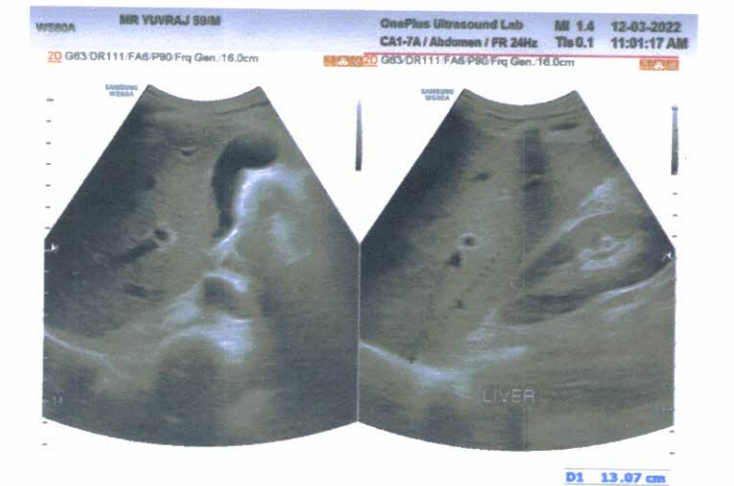
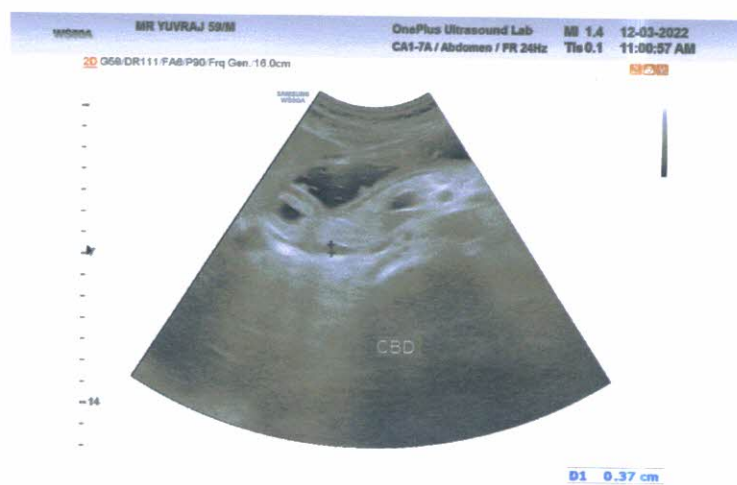

Figure 1. Left: Comparison of two different views of the same object. Right: Comparison of two different views of the same object.

Figure 2. Comparison of two different views of the same object.





Figure 3. Left: Comparison of two different views of the same object. Right: Comparison of two different views of the same object.

Figure 4. Comparison of two different views of the same object.





Figure 5. Comparison of two different views of the same object.

Figure 6. Comparison of two different views of the same object.





Figure 7. Comparison of two different views of the same object.

Figure 8. Comparison of two different views of the same object.



**OnePLUS**  
Ultrasound Lab

— QUALITY FIRST... ALWAYS! —

**Dr. Nitin Agarwal**

Pathologist & Director  
Ex. Sr. Res. MAMC  
& Lok Nayak Hospital  
Ex. Chief of Lab Dr. Lal Path Labs.

**Dr. Pooja (Garg) Agarwal**

Radiologist & Director  
MAMC & Lok Nayak Hospital

<b>Name</b> : Mr. YUVRAJ BHANDARI	<b>Age/Sex</b> : 59 YRS/Male
<b>Ref. By</b> : Dr. MEDIWHEEL	<b>Lab No</b> : 012203120011
<b>Date</b> : 12-Mar-2022	<b>Patient ID</b> : LSHHI92431

### X-ray-Chest PA view

Bony cage and soft tissues are normal.

Cardiothoracic ratio is normal.

Mediastinum is normal.


Both hila are normal.

Both costophrenic angles are clear.

Both domes of diaphragm are normal.

Lung fields are clear. No parenchymal lesion seen.

**IMPRESSION: Normal Study.**

  
**DR. POOJA GARG**  
RADIOLOGIST  
REG NO- DMC/R/03398

**Dr. POOJA GARG**  
M.B.B.S., D.M.R.D  
Reg No. DMC/R/03398  
Radiologist

Type By : darshita

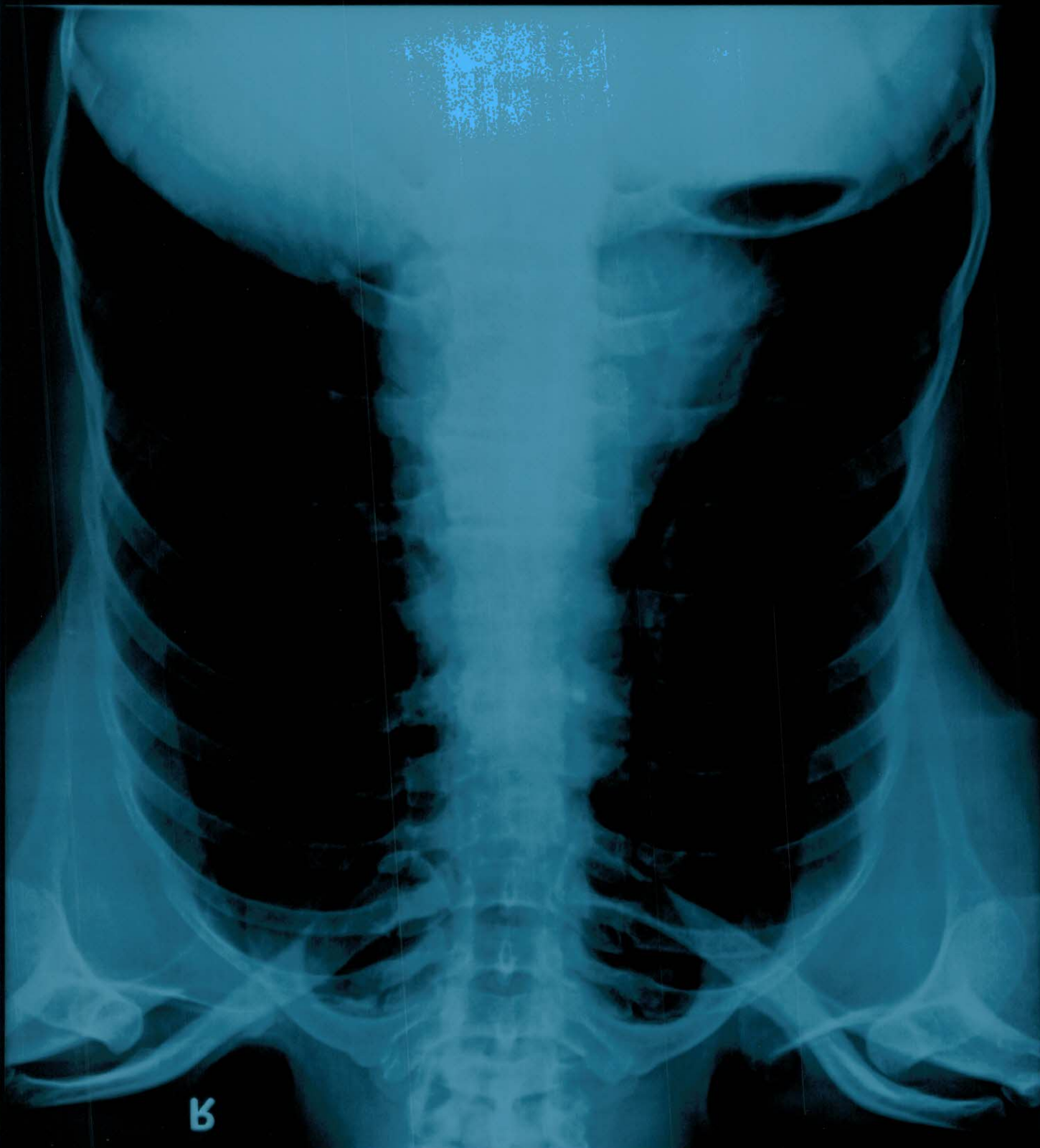47, Harsh Vihar, Pitampura, New Delhi-110034 | Ph.: 011-42480101, 9599913051

E-mail: [oneplusul@gmail.com](mailto:oneplusul@gmail.com) | Web.: [www.oneplusul.in](http://www.oneplusul.in)

Clinical correlation is essential for final diagnosis. • If test results are unsatisfactory please contact personally or on phone. • This report is for perusal of doctors only.  
• All disputes Subject to Delhi Jurisdiction only. • Not for medicolegal purposes. • All congenital anomalies in a foetus may not be diagnosed in routine obstetric ultrasound.

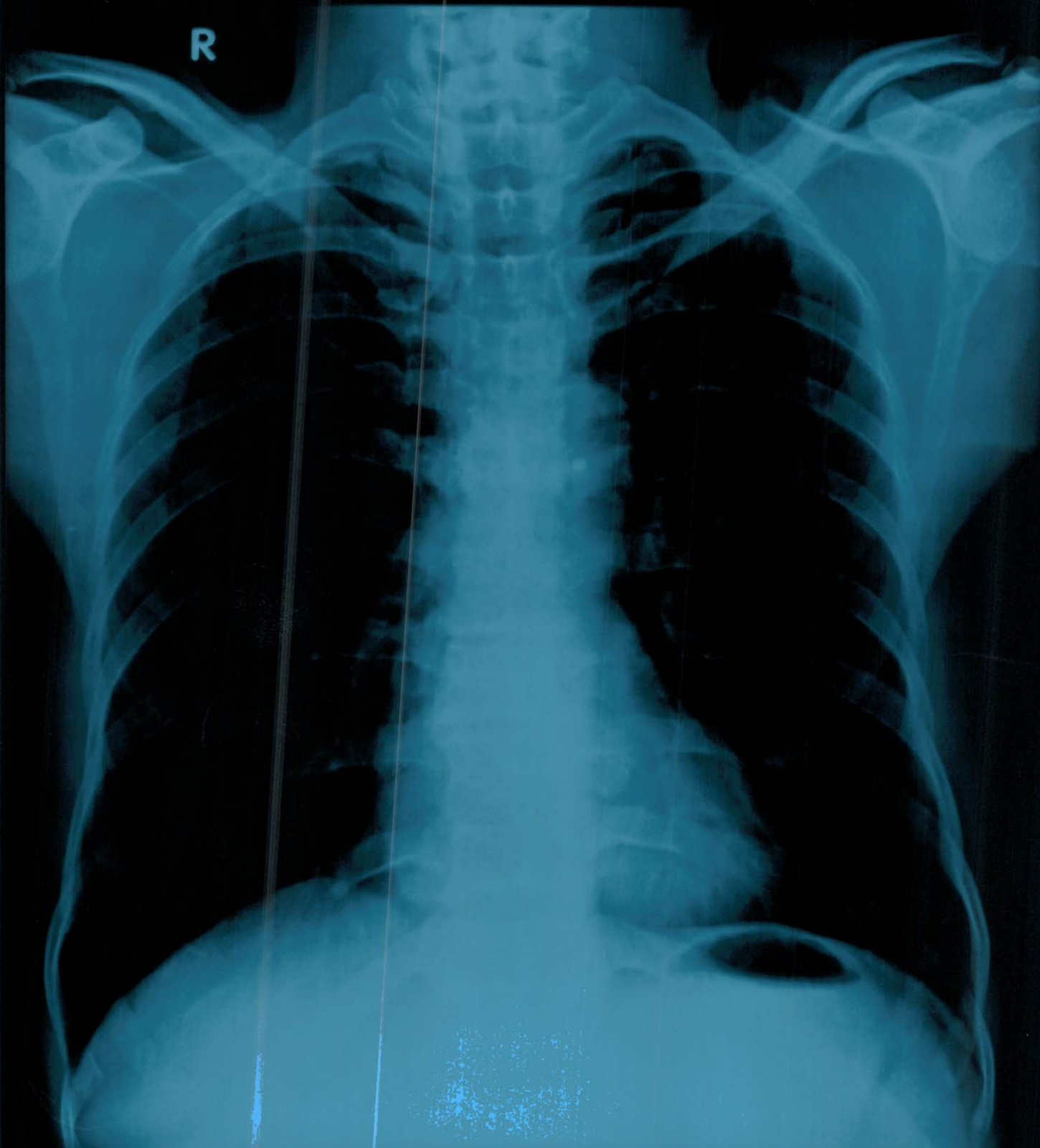


АПТЭСТ РА М СЕСТ РА 2202-20-21 РА 29 29 ІПАДАНА РАУУ. МВ. УУВАУ ВНАІВАІ 29 РА2 І2-03-2022  
ОІЕБГУ2 ПГТРА2ОІІД ГАВ'4-НАК2Н АІНАВ'РІТАМЬУКА



В

R



MR.YUVRAJ BHANDARI 59 YRS 12-03-2022 M CHEST PA  
ONEPLUS ULTRASOUND LAB,47-HARSH VIHAR,PITAMPURA