

ID 1418 CASE
AGE 45 Y 0M 0D
SEX M

HEALTH HISTORY
WELL

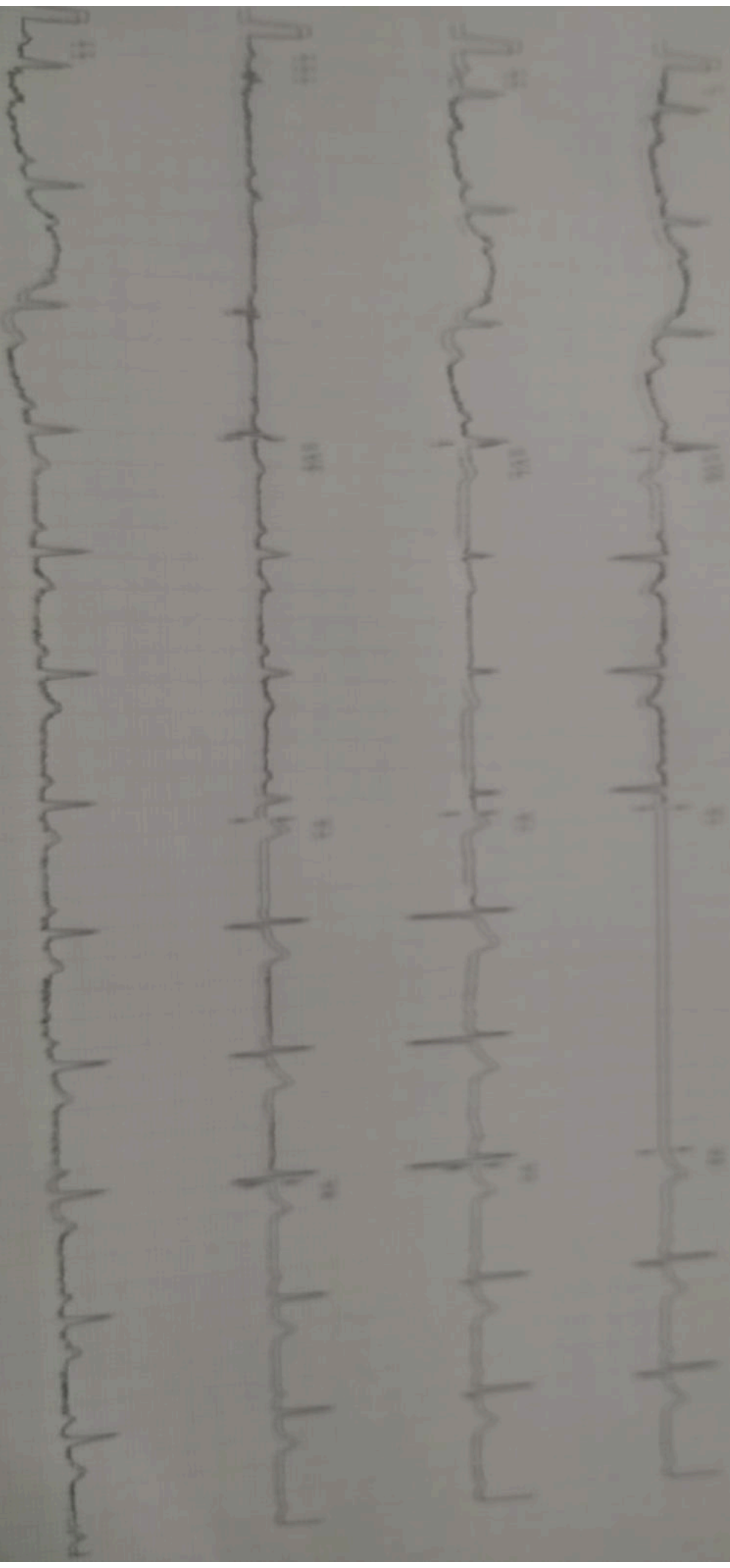
DATE/TIME 10/05/2022 10:55:18
ACUITY MONITORING DISTANCE 17CM
EKG 12 LEAD ECG (RHYTHM STRIP) P-7734



WIDENED QRS BASED ON AVAILABLE LEADS

ALL IN SINGLE LEAD

DR. ANAND K



STANDARDIZING THE FINDINGS



Pl. Name :- KUMAR BIRENDAR

Ref. By :- DR. /SELF

Date:- 9-Dec-22

Age / Sex - 45Yrs. M

Thanks for your kind referral

X-RAYCHEST (P.A.VIEW)

The lungs on the either side show equal translucency.

The peripheral pulmonary vasculature is increased in Both Lungs

No focal lung lesion is seen.

The pleural spaces are normal.

Both hila are normal in size, have equal density and bear normal relationship.

The heart and trachea are central in position and no mediastinal abnormality is visible.

The cardiac size is normal.

The domes of the diaphragms are normal in position, and show smooth outline.

IMPRESSION

- The peripheral pulmonary vasculature is increased in Both Lungs with Fibrous opacity***

Adv :- Further work up / other investigation for Pulmonary Pathology





A.L.C. Advance Imaging Diagnostics

(A Unit of Subham Imaging P.K. Arogyam Health & Wellness Center)

E-95, P.C. Colony, Near Sai Netryalaya Transformer, Kankarbagh, Patna - 20

alcdiagnostics@gmail.com

www.pkarogayamhealthcheckup.com

7050037494, 8271206196

OPINION MUST BE CORRELATES WITH CLINICALLY & OTHER INVESTIGATION FOR FINAL DIAGNOSIS. NOT FOR MEDICO LEGAL PURPOSE

Pt. Name :- KUMAR BIRENDER
Ref. By :- DR. MEDIWECHAL

Date:- 8-Dec-22
Age / Sex - 45 Yrs. M.

REAL TIME U.S.G. OF WHOLE ABDOMEN Thanks for your kind referral

(Report.)

LIVER :- Measures 16.21cm. Mild Enlarged in shape , size and echo texture fatty change seen in liver parenchyma .I.H.B.R. are not dilated.
Hepatic veins are normal. No SOL seen.

G.BL :- Lumen is echo free. Wall thickness appears normal.

C.B.D. :- Measures 3.5 mm in diameter with echo free lumen. No calculi or mass seen.

P.V. :- Measures 7.7 mm in diameter. Appears normal. No thrombus seen.

PANCREAS :- Normal in shape, size and echo texture. No calcification mass seen.

SPLEEN :- Measures 12.20 cm. Mild Enlarge in shape, size and echo texture.
No SOL seen.

KIDNEY :- Both kidney shows normal shape, size & echo texture. C.M.D.intact.
P.C.S.is not dilated. A calculi, Measures 4 mm seen at mid pole of Rt. Kidney
Right Kidney :- Measures 10.73 X 3.50 cm.
Left Kidney :- Measures 10.61X 3.50 cm.

URETER :- Not dilated .No apparent calculi seen.

U.BLADDER:- Shows normal in outline with echo free lumen. No calculi or mass seen.
Pre void - 360 ml. Post void - 40 ML is in significant

PROSTATE :- Measures 24 gms.(approx). Appears Mild Enlarge ,in shape ,size and Echo texture.

No calcification , mass ,growth seen. capsule is intact.

:- Son graphically no appendicular mass or collection seen.

OTHERS :- No Ascites . no Lymph Adenopathy. No pleural effusion seen on either side .

IMPRESSION

Mild Hepatosplenomegaly With fatty liver G-I

Mild Enlarge prostate BPH - G-1 With 40 ml PVR

Adv:- Further work up other investigation

Otherwise son graphically normal scan. of rest organs



Consultant Radiologist

Dr. S. Kumar Dr. Abhishek Kumar

MD (Pat)

MBBS MD

Dr. Kumari Suman

Dr. A. K. S.

8/12



Pt. Name :- KUMAR BIRENDER
Ref. By :- DR. MEDHUKAR

Date :- 8-Dec-12
Age / Sex :- 45 Yrs. M.

REAL TIME U.S.G. OF WHOLE ABDOMEN

Thanks for your kind referral

(Report)

- LIVER** :- Measures 16.21cm. Mild Enlarged in shape , size and echo texture fatty change seen in liver parenchyma .L.H.B.R. are not dilated.
Hepatic veins are normal. No SOL seen.
- G.B.L.** :- Lumen is echo free. Wall thickness appears normal.
- C.B.D.** :- Measures 3.5 mm in diameter with echo free lumen. No calculi or mass seen.
- P.V.** :- Measures 7.7 mm in diameter. Appears normal. No thrombus seen.
- PANCREAS** :- Normal in shape, size and echo texture. No calcification mass seen.
- SPLEEN** :- Measures 12.20 cm. Mild Enlarge in shape, size and echo texture.
No SOL seen.
- KIDNEY** :- Both kidney shows normal shape, size & echo texture. C.M.D.intact.
P.C.S.is not dilated. A calculi, Measures 4 mm seen at mid pole of Rt. Kidney
Right Kidney :- Measures 10.73 X 3.50 cm.
Left Kidney :- Measures 10.61 X 3.50 cm.
- URETER** :- Not dilated .No apparent calculi seen.
- U.BLADDER**:- Shows normal in outline with echo free lumen. No calculi or mass seen.
Pre void - 360 ml. Post void - 40 ML is in significant
- PROSTATE** :- Measures 24 gms.(approx). Appears Mild Enlarge ,in shape ,size and Echo texture.
No calcification , mass ,growth seen. capsule is intact.
- R.I.F.** :- Son graphically no appendicular mass or collection seen.
- OTHERS** :- No Ascites . no Lymph Adenopathy. No pleural effusion seen on either side .

IMPRESSION

- Mild Hepatosplenomegaly With fatty liver G-I
 - Mild Enlarge prostate BPH - G-I With 40 ml PVR
- Adv:- Further work up other investigation
Otherwise son graphically normal scan. of rest organs

8/12/12



Consultant Radiologist

K. Tiwari (Radio Imaging) Nuclear Medicine) **Dr. S. Kumar** MD (Pat) Consultant Pathologist **Dr. Abhishek Kumar** MBBS, MD Consultant Neuropatho Physiologist **Dr. Kumari Suman** MBBS, DGO, MD Consultant (TVS & HSG Specialist) **Dr. A. K. Singh** MBBS, PGDMCH Consultant Radiologist & Sonologist

ING MISTAKE SHOULD BE REPORTED BACK IMMEDIATELY/ यहाँ जन्म से पहले भ्रुण का लिंग जाँच नहीं हो



PATIENT NAME : KUMAR BIRENNA
PATIENT ID: 2628
COL DATE : 08/12/2022 REPORTING DATE: 08/12/2022 AGE SEX : 45 YRS/M
REF BY : DR./BOB..

TEST NAME	RESULT	Unit	REF. RANGE
-----------	--------	------	------------

Serum TSH	3.05	µIU/mL	0.27 - 4.20 µIU/mL
-----------	------	--------	--------------------

THYROID DISORDER (-): Increase: < Decrease: n Normal

1. T3(n) T4(n) TSH(n) : EUTHYROID STATE:
2. T3(>) T4(>) TSH(<): HYPERTHYROIDISM:
3. T3(<) T4(<) TSH(>): HYPOTHYROIDISM:
4. T3(n) T4(n) TSH(>) : SUB-CLINICAL HYPO-THYROIDISM:
5. T3(n) T4(n) TSH(<): SUB-CLINICAL HYPER-THYROIDISM:
6. T3(>) T4(n) TSH(<): T3 THYROTOXICOSIS:

Total T3/T4 level is dependent on Level:

So determination of free T3/T4 is a better MARKER of Thyroid Function.

Consultant Radiologist

Dr. S. Kumar MD (Part) Consultant, Pathologist
Dr. Abhishek Kumar MBBS, MD Consultant, Neurophysiologist
Dr. Kumari Suman MBBS, DGO, MD Consultant (TVS & HSG Specialist)
Dr. A. K. Singh MBBS, PGDMCH Consultant Radiologist Esom

TAKE SHOULD BE REPORTED BACK IMMEDIATELY/ यहाँ जल्द से जल्द रिपोर्ट आना चाहिए

A.L.C. Advance Imaging Dignostics

(A Unit of Subham Imaging P.K. Arogyam Health & Wellness Center)

E-95, P.C. Colony, Near Sai Netryalaya Transformer, Kankarbagh, Patna - 20

pkarogayam@gmail.com

www.pkarogayamhealthcheckup.com

7050037694, 8271206196

THIS REPORT MUST BE CORRELATES WITH CLINICALLY & OTHER INVESTIGATION FOR FINAL DIAGNOSIS. NOT FOR MEDICO LEGAL PURPOSE

PATIENT NAME : .KUMAR BIRENDRA

PATIENT ID: 2628

COL DATE : 10/12/2022 REPORTING DATE: 110/12/2022 AGE SEX:- 45 YRS/M

REF.BY : DR. /BOB.

TEST NAME	RESULT	Unit	REF.RANGE
BLOOD SUGAR (PP)	141.0	mg/dl	70 - 140 mg/dl

AR
10/12/22

Consultant Radiolog

Dr. S. Kumar Dr. A. S. ...

LLC. Advance Imaging Dignostics

(A Unit of Subham Imaging P.K. Arogyam Health & Wellness Center)

E-95, P.C. Colony, Near Sai Netryalaya Transformer, Kankarbagh, Patna - 20
www.pkarogayamhealthcheckup.com

7056037694, 9271 206176

PERSON MUST BE CORRELATES WITH CLINICALLY & OTHER INVESTIGATION FOR FINAL DIAGNOSIS. NOT FOR MEDICO LEGAL PURPOSE

PATIENT NAME : .KUMAR BIRENDRA PATIENT ID: 2628
COL DATE : 10/12/2022 REPORTING DATE: 110/12/2022 AGE SEX:- 45 YRS/M
REF.BY : DR. /BOB.

ROUTINE EXAMINATION OF URINE

PHYSICAL EXAMINATION

Quantity	40 ml	Colour... .	Straw
Appearance...	Clear	Sediment ...	Nil
Specific gravity....	1.010		

CHEMICAL EXAMINATION

Reaction	6.0	Nitrite.....	Not done
Sugar	Nil	Bile Pigment	Not done
Albumin	Nil	Urobilinogen....	Not done
Excess of Phosphate....	Nil	Chile.....	Not done
Bile Salt	Not Done	Acetone...	Not done

MICROSCOPIC EXAMINATION

Erythrocytes....	Nil	Casts	Nil
Leucocytes	1-5 / HPE	Crystals....	Nil
Epith. Cell	A, Few	Others	Nil

K. Tiwari
(Radio Imaging)
(Nuclear Medicine)
Radiationologist & Sonologist

Dr. S. Kumar
MD (Pat)
Consultant Pathologist

Dr. Abhishek Kumar
MBBS, MD
Consultant Neuropatho Physiologist

Dr. Kumari Suman
MBBS, DGO, MD
Consultant (TVS & HSG Specialist)

Dr. A. K. Singh
MBBS, PGDMCH
Consultant Radiologist & Sonologist

NG MISTAKE SHOULD BE REPORTED BACK IMMEDIATELY/ यहाँ जन्म से पहले भ्रूण का लिंग जाँच नहीं होता है

P.L.C. Advance Imaging Dignostics

(A Unit of Subham Imaging P.K. Arogyam Health & Wellness Center)

E-95, P.C. Colony, Near Sai Netryalaya Transformer, Kankarbagh, Patna - 20
www.pkarogayamhealthcheckup.com

7050037694 8271206198

THIS REPORT MUST BE CORRELATES WITH CLINICALLY & OTHER INVESTIGATION FOR FINAL DIAGNOSIS. NOT FOR MEDICO LEGAL PURPOSE

PATIENT NAME : KUMAR BIRENDRA PATIENT ID: 2628
COL DATE : 08/12/2022 REPORTING DATE: 08/12/2022 AGE SEX:- 45 YRS/M
REF.BY : DR. / BOB.

TEST NAME	RESULT	Unit	REF.RANGE
ESR	12 mm/hr		<20 mm/hr
CBC			
Total W.B.C. Count	5,200 /cumm		4000-11,000 /cumm
R B C COUNT	4.88 Million/ CUmm		4 - 7 Million/ CUmm
Platelets count	1.48 Lakh/ cumm		1.5-5.0 Lakh/ cumm
Differential Count of W.B.C.			
Neutrophils	65 %		40-70%
Lymphocytes	29 %		25-40%
Eosinophils	05 %		01-05%
Mnonocytes	01 %		00-02%
Basophiles	00 %		00 -0%
HAEMOGLOBIN	13.4 gm/dl (91.7 %)		14.6 gm/dl = 100%
PCV	39.4 %		35-47 %
MCV	81.8 fl		76-96 fl
MCH	27.4 pg		29-35 pg
MCHC	33.6 %		30-38 %

(Signature)
8/12/22
Consultant Radiologist

Tiwari (Imaging) (Medicine) Radiologist & Sonologist
Dr. S. Kumar MD (Pat) Consultant Pathologist
Dr. Abhishek Kumar MBBS, MD Consultant Neuropatho Physiologist
Dr. Kumari Suman MBBS, DGO, MD Consultant (TVS & HSG Specialist)
Dr. A. K. Singh MBBS, PGDMCH Consultant Radiologist & Sonologist

MISTAKE SHOULD BE REPORTED BACK IMMEDIATELY/ यहाँ जन्म से पहले भ्रुण का लिंग जाँच नहीं होता

PATIENT NAME : KUMAR BIENDRA

PATIENT ID: 2628

COL DATE : 08/12/2022 REPORTING DATE: 08/12/2022 AGE SEX:- 45 YRS/M

REF.BY : DR./ BOB.

TEST NAME	RESULT	Unit	REF.RANGE
LFT:-			
SGPT	5.4	IU/L	5 - 48 IU/L
SGOT	31.2	IU/L	5 - 40 IU/L
ALKALINE PHOSPHATASE	92.6	IU/L	25 - 147 IU/L
TOTAL PROTIN	7.8	g/dl	6.0 - 8.7 g/dl
SERUM ALBUMIN	5.0	g/dl	3.5 - 5.4 g/dl
SERIUM GLUBLINE	2.8	g/dl	2.3 - 3.6 g/dl
AG RATIO	1.7 : 1		1.0 - 2.3 g/dl
BILIRUBIN			
TOTAL	0.76	mg/dl	0.1 - 1.1 mg/dl
IRECT	0.27	mg/dl	0.0 - 0.32 mg/dl
INDIRECT	0.49	mg/dl	0.0 - 0.78 mg/dl
GGTP (GGT)	27.8	iu/L	8 - 38 iu/L
KFT/RFT			
URIC ACID	4.5	mg/dl	3.2 - 7.0 mg/dl
SERUM CREATNINE	1.1	mg/dl	0.6 - 1.5 mg/dl
BLOOD URIA	30.2	mg/dl	5 - 45 mg/dl
BLOOD URIA NITROZEN(BUN).	14.1	mg/dl	5 - 39 mg/dl

Abh
8/12/22
Consultant Radiologist

Dr. S. Kumar MD (Pat) Consultant Pathologist
Dr. Abhishek Kumar MBBS, MD Consultant Neuropatho Physiologist
Dr. Kumari Suman MBBS, DGO, MD Consultant (TVS & HSG Specialist)
Dr. A. K. Singh MBBS, PGDMCH Consultant Radiologist & Sonologist

PATIENT NAME : KUMAR BIRENDRA

PATIENT ID: 2628

COL DATE : 08/12/2022

REPORTING DATE: 08/12/2022

AGE SEX : 45 YRS/M

REF.BY : DR. / BOB.

GLYCOSYLATED HEMOGLOBIN

TEST NAME	RESULT	Unit	REF.RANGE
HbA1c	4.2 %		Below 5.7 % : Normal 5.7 – 6.4 % : Prediabetic > = 6.5 % : Diabetic
AVERAGE PLASMA GLUCOSE	99.0 mg/dl		90 – 120 mg/dl : Good Control 121– 150 mg/dl : Fair Control 151- 180 mg/dl: Unsatisfactory Control >180 mg/dl : Poor Control


8/12/22

Consultant Radiolo

Dr. S. Kumar
MD (Pat)
Consultant Pathologist

Dr. Abhishek Kumar
MBBS, MD
Consultant Neuropatho Physiologist

Dr. Kumari Suman
MBBS, DGO, MD
Consultant

Dr. A. K. Singh
MBBS, BCDMCH

PATIENT NAME : KUMAR BIRENDRA

PATIENT ID: 2628

COL DATE : 08/12/2022

REPORTING DATE: 08/12/2022

AGE SEX : 45 YRS/F

REF.BY : DR. /BOB.

TEST NAME	RESULT	Unit	REF.RANGE
BLOOD SUGAR (F)	102.0 mg/dl		70 - 110 mg/dl

LIPID PROFILE:-

TOTAL CHOLESTROL	142.0 mg/dl		130 - 250 mg/dl
TRIGLYCERIDE	149.2 mg/dl		50 - 160 mg/dl
HDL CHOLESTROL	40.0 mg/dl		30 - 60 mg/dl
LDL CHOLESTROL	72.2 mg/dl		80 - 130 mg/dl
VLDL CHOLESTROL	29.8 mg/dl		15 - 40 mg/dl
T.CH./HDL RATIO	3.5 : 1		Upto 5 : 1
LDL./HDL RATIO	1.8 : 1		2 - 4 : 1

[Signature]
8/12
Consultant R

ESTB BY:-

Dr. P. K. Tiwari
MD, M.Sc (Radio Imaging)
D (Alt Nuclear Medicine)
Consultant Imagonologist & Sonologist

Dr. S. Kumar
MD (Pat)
Consultant Pathologist

Dr. Abhishek Kumar
MBBS, MD
Consultant Neuropatho Physiologist

Dr. Kumari Suman
MBBS, DGO, MD
Consultant (TVS & HSG Specialist)

Dr. A. K.
MBBS, PGDM
Consultant R

TESTES WITH CLINICALLY & OTHER INVESTIGATION FOR FINAL DIAGNOSIS. NOT FOR MEDICO LEGAL PURPOSE

PATIENT NAME : KUMAR BIRENDRA PATIENT ID: 2628
COL DATE : 08/12/2022 REPORTING DATE: 08/12/2022 AGE SEX:- 45 YRS/M
REF.BY : DR. / BOB.

TEST NAME	RESULT	Unit	REF.RANGE
BLOOD GROUP	: ' B '		
Rh Typing	: POSITIVE		

Note: Do always cross - matching before blood transfusion

[Signature]
8/12/22

Consultant Radiologist

ESTB BY:-

Dr. P. K. Tiwari
MD, M.Sc (Radio Imaging)
Ph.D (Ab Nuclear Medicine)
Consultant Imagionologist & Sonologist

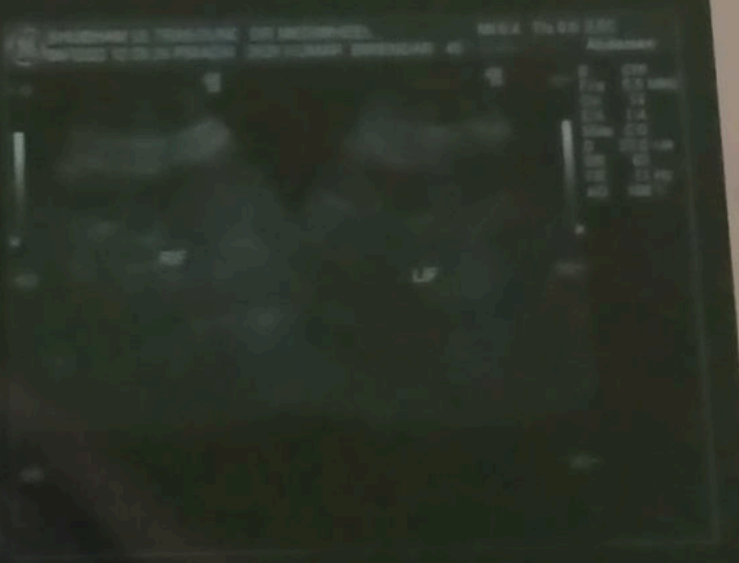
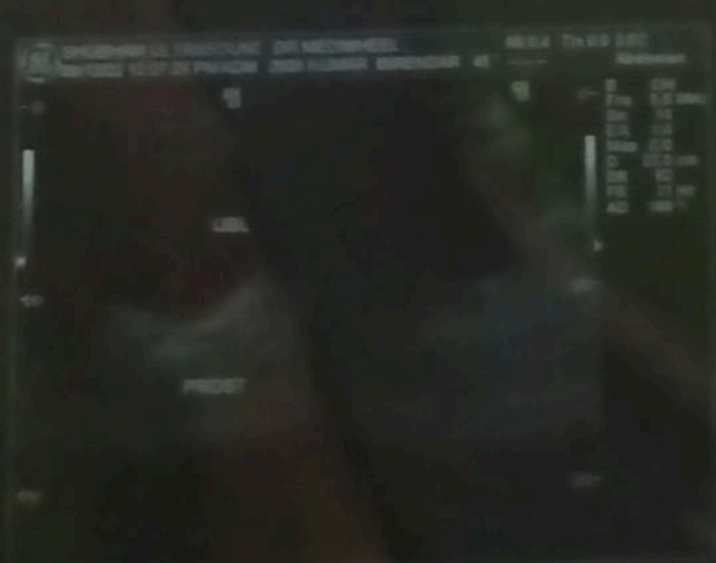
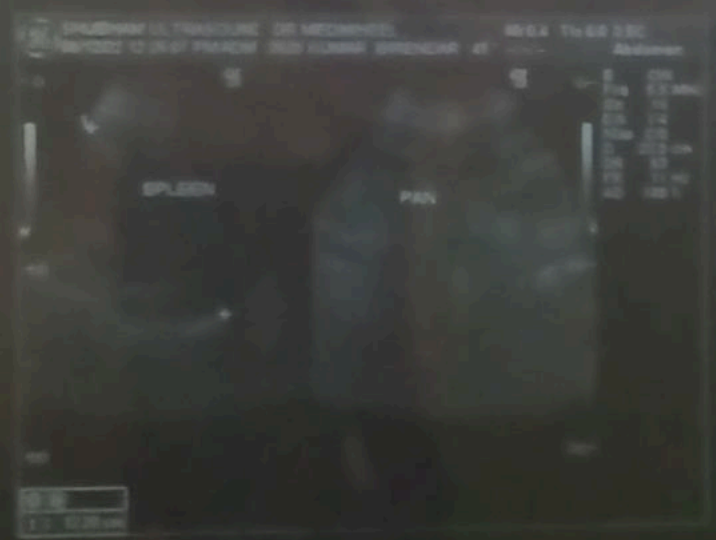


Dr. S. Kumar
MD (Pat)
Consultant Pathologist

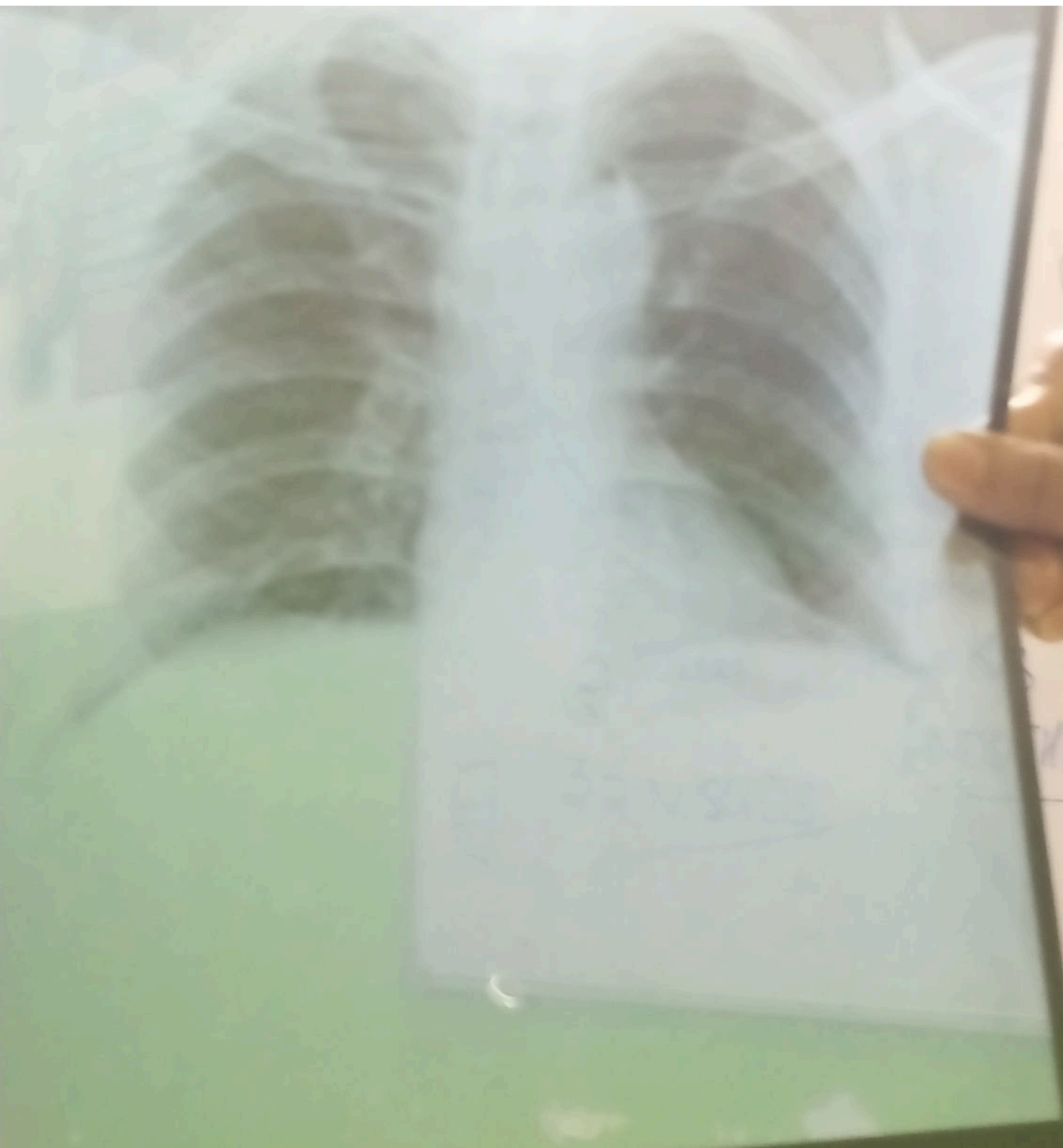
Dr. Abhishek Kumar
MBBS, MD
Consultant Neuropatho Physiologist

Dr. Kumari Suman
MBBS, DGO, MD
Consultant (TVS & HSG Specialist)

Dr. A. K. Singh
MBBS, PGDMCH
Consultant Radiologist

PRINTING MISTAKE SHOULD BE REPORTED BACK IMMEDIATELY/ यहाँ जन्म से पहले भ्रुण का लिंग जाँचें





Handwritten notes in blue ink are visible on the right side of the X-ray images. The text is partially obscured and difficult to read, but appears to include the name "MEL" and some other illegible characters.