



ISO Certified (9001-2008)
Late R. T. Bhoite Smruti Arogya Pratisthan's

GIRIRAJ HOSPITAL

(State Govt. Recognised Hospital)



PADMASHREE DR. APPASAHEB PAWAR HEART CARE CENTRE

DR. RAMESH R. BHOITE M.D.

Chairman

Reg.No.Mah.Soc.Act 1860/9888/95 Pune
Bombay Public Trust Act. 1950/F/10595 Pune
I.T.ded. U/S 80 G/PN 165 Rate 216/05/00
F.C.R.A. 083930350

Only for Clinical Use

CARDIAC COLOR DOPPLER

Patients Name: Mrs Trupti Pankaj Chandanshive

Age/Sex: 28 Year/Female

Ref.: - Dr Ramesh Bhoite

Date -07th March ,2023

Findings: -

MV -MVA adequate, Mild MR

AV -Degenerative NO AS (AVG: 18 mmHg)/ No AR

TV - Mild TR, No PH (RVSP/TR: 14 mmHg)

PV - Normal

No Clot / Vegetation/ Pericardial Effusion

No RWMA

Grade I DD

Measurements (mm); -AO-21, LA-34, IVS-10, LVPW-10, LVIDd-42, LVIDs-30 LVEF - 60%

Impression:

- No RWMA
- Normal LV systolic function LVEF 60%


Dr. Sunny Shinde

MD (MED) (BJMC, Pune),

DM (CARD) (KEMH, Mumbai)

Arora *Raj*

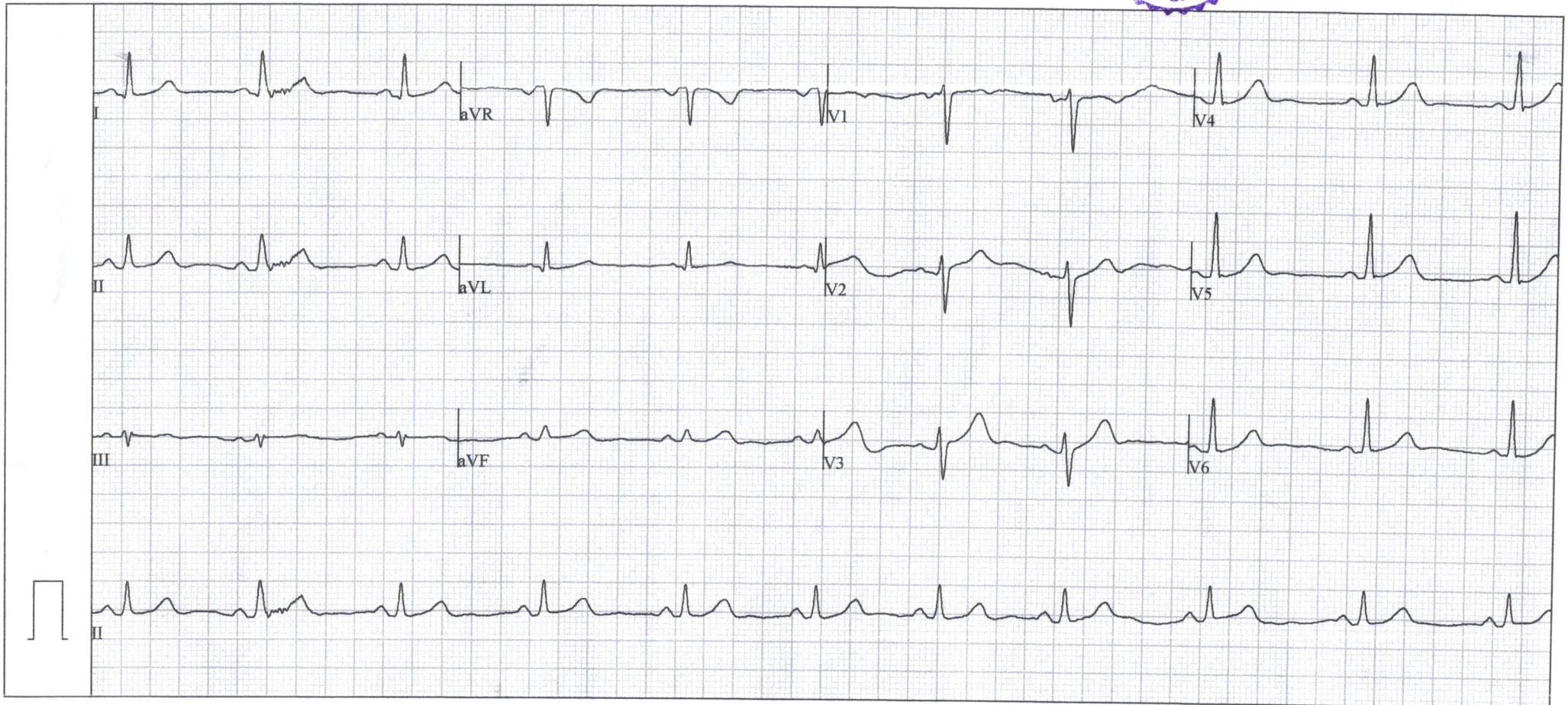
Ramesh

QRS : 70 ms
QT / QTcBaz : 410 / 419 ms
PR : 140 ms
P : 98 ms
RR / PP : 96 / 952 ms
P / QRS / T : 46 / 26 / 40 degrees

Normal sinus rhythm with sinus arrhythmia
Normal ECG

ECG - Normal

DR. RAMESH R. BHOITE, M.D.
Cardiologist
Giriraj Hospital & Intensive Care Unit
Indapur Road, Baramati-413102



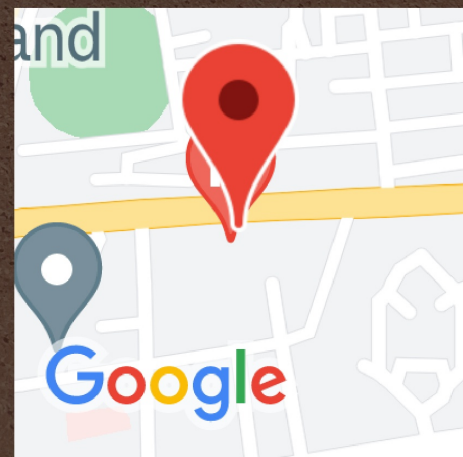


Baramati, Maharashtra, India

Near Bhoite Hospital, Indapur Road, ST Stand, Samarth Nagar, Baramati, Maharashtra 413102, India

Lat 18.1463078 / Long 74.5772572

Tuesday 07 March 2023 12:14:06





GIRIRAJ DIAGNOSTIC CENTRE

Ultrasonography, Whole Body Colour Doppler Ultrasound, Echocardiography.



NAME : MRS. TRUPTI CHANDANSHIVE AGE/SEX : 32 YEARS/F
REF BY : DR. MEDIWHEEL INSURANCE DATE : 07-03-2023

USG STUDY OF ABDOMEN & PELVIS

Liver appears normal in size, shape & shows normal parenchymal reflectivity. No e/o focal mass lesion or any neoplasm seen in liver. Portal vein & CBD are normal.

Gall bladder is well distended. Its wall thickness is normal. No peri gb collection and fat stranding.

Pancreas: normal in size and shape. No focal lesion or calcifications are seen within it. The pancreatic duct is normal.

Spleen normal in size & normal echotexture. No focal mass lesion seen in spleen.

Both kidneys appear normal size, shape, position & echotexture. No calculus or mass lesion or scarring seen in both kidneys. No hydronephrosis. Cortical echogenicity and thickness appears normal in both kidneys. Cortico-medullary differentiation is well maintained in both kidneys.

Urinary bladder is well distended. No obvious calculus/mass lesion.

Uterus is anteverted, normal in size. No obvious focal lesion. ET appears normal.

Both ovaries are visualised and appears normal.

Visualized small bowel loops appear non dilated. Gaseous distension of large bowel loops.

No free fluid is seen in abdomen and pelvis.

No significant abdominal lymphadenopathy.

Conclusion:

- Normal USG abdomen and pelvis study.

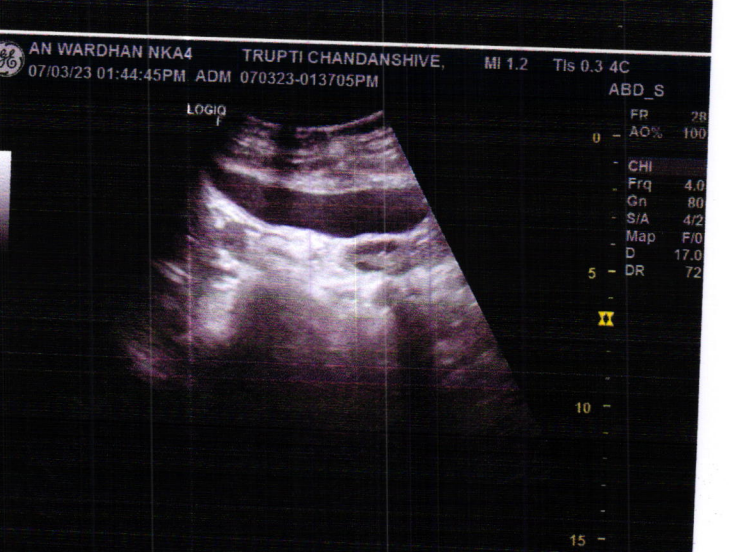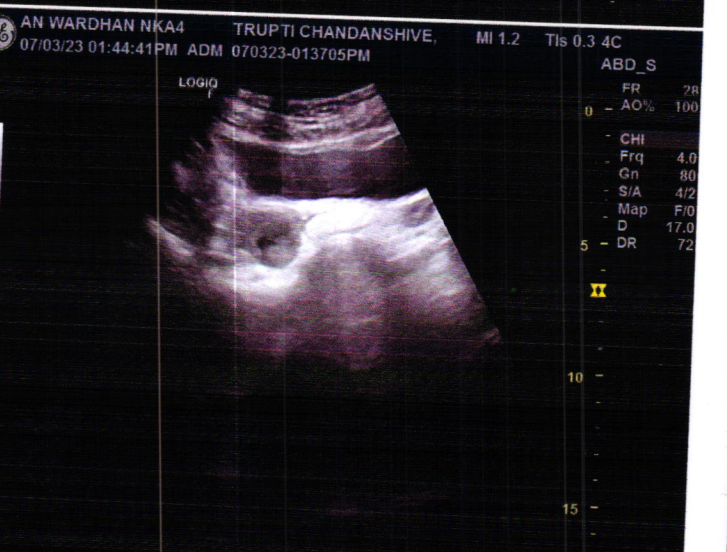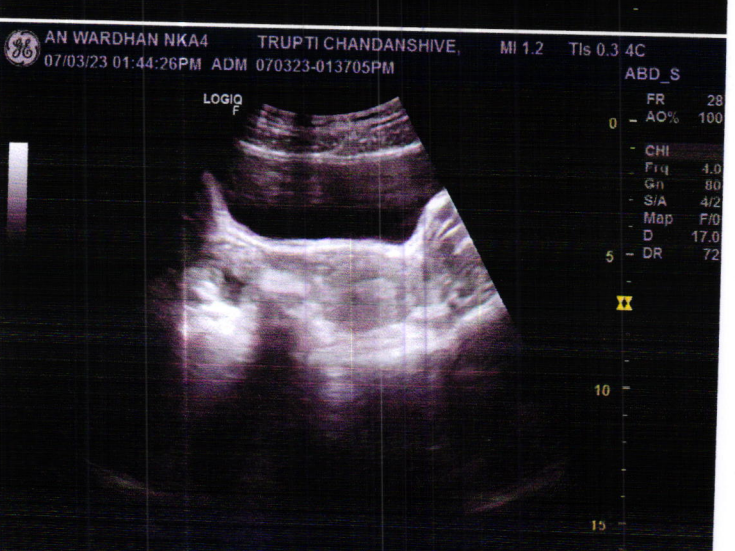
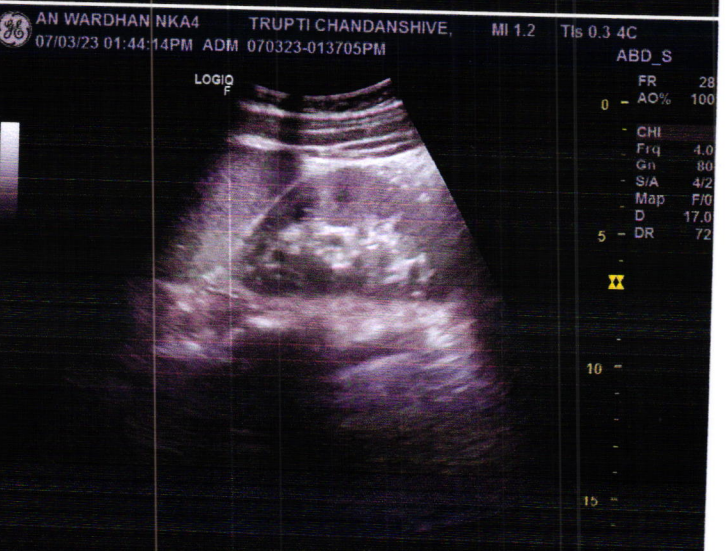
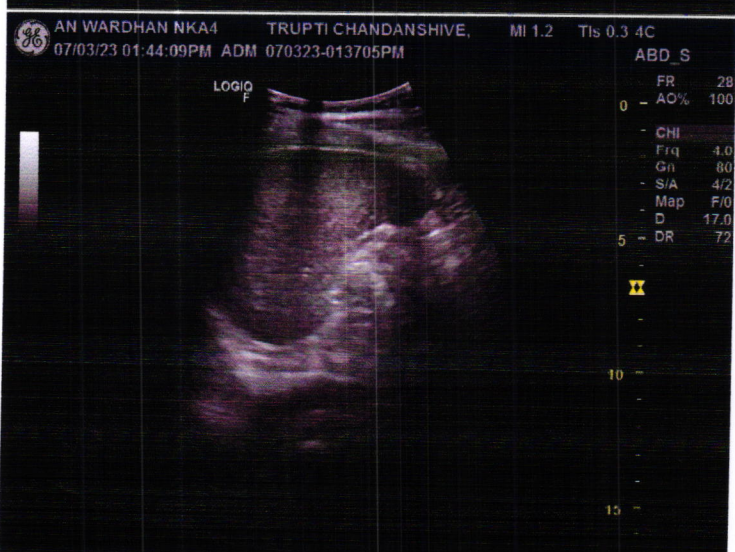
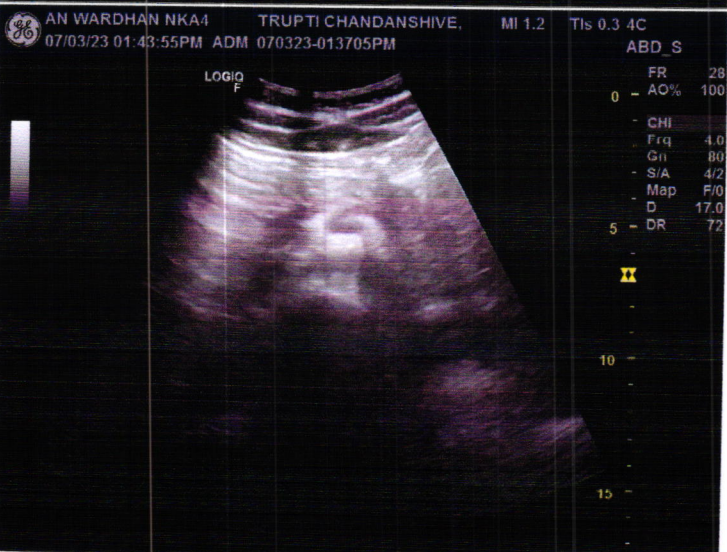
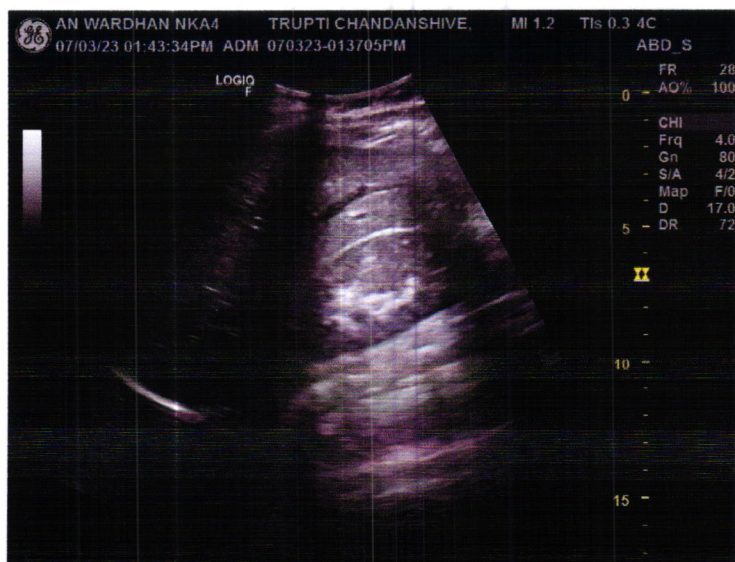
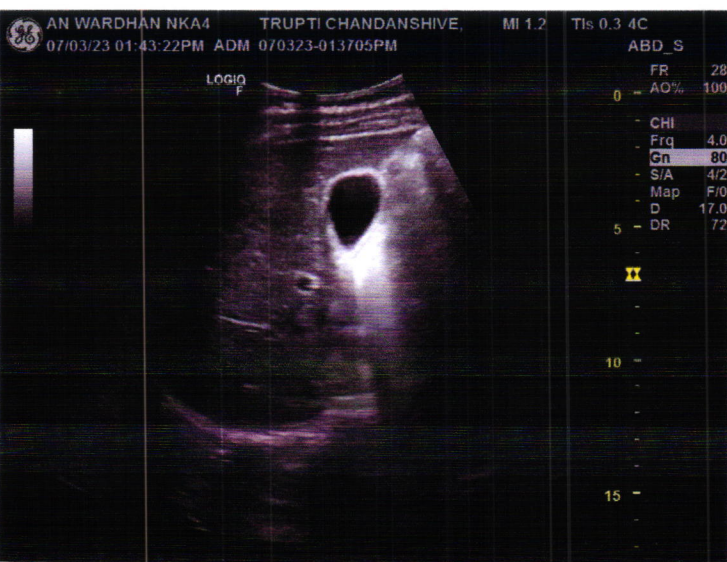
Suggested clinical and lab correlation.

Navid's

DR.NAVID SHATTARI

M.B.B.S, M.D. D.N.B

CONSULTANT RADIOLOGIST



GIRIRAJ DIAGNOSTIC SERVICES

Whole Body Colour Doppler Ultrasound, Echocardiography & X-Ray



NAME	: MR. TRUPTI CHANDANSHIVE
AGE / SEX	: 32 YRS / FEMALE
REF	: MEDIWHEEL INSURANCE
DATE	: 07/03/2023

X- RAY CHEST PA VIEW

- ❖ Both lung fields show equal translucency and vasculature.
- ❖ No obvious infiltration is seen on either side.
- ❖ Costo-phrenic and cardio-phrenic angles on both sides appears clear
- ❖ The cardiac size is normal.
- ❖ The domes of diaphragm are normal in position & show smooth outline.
- ❖ Visualized bones appear normal.

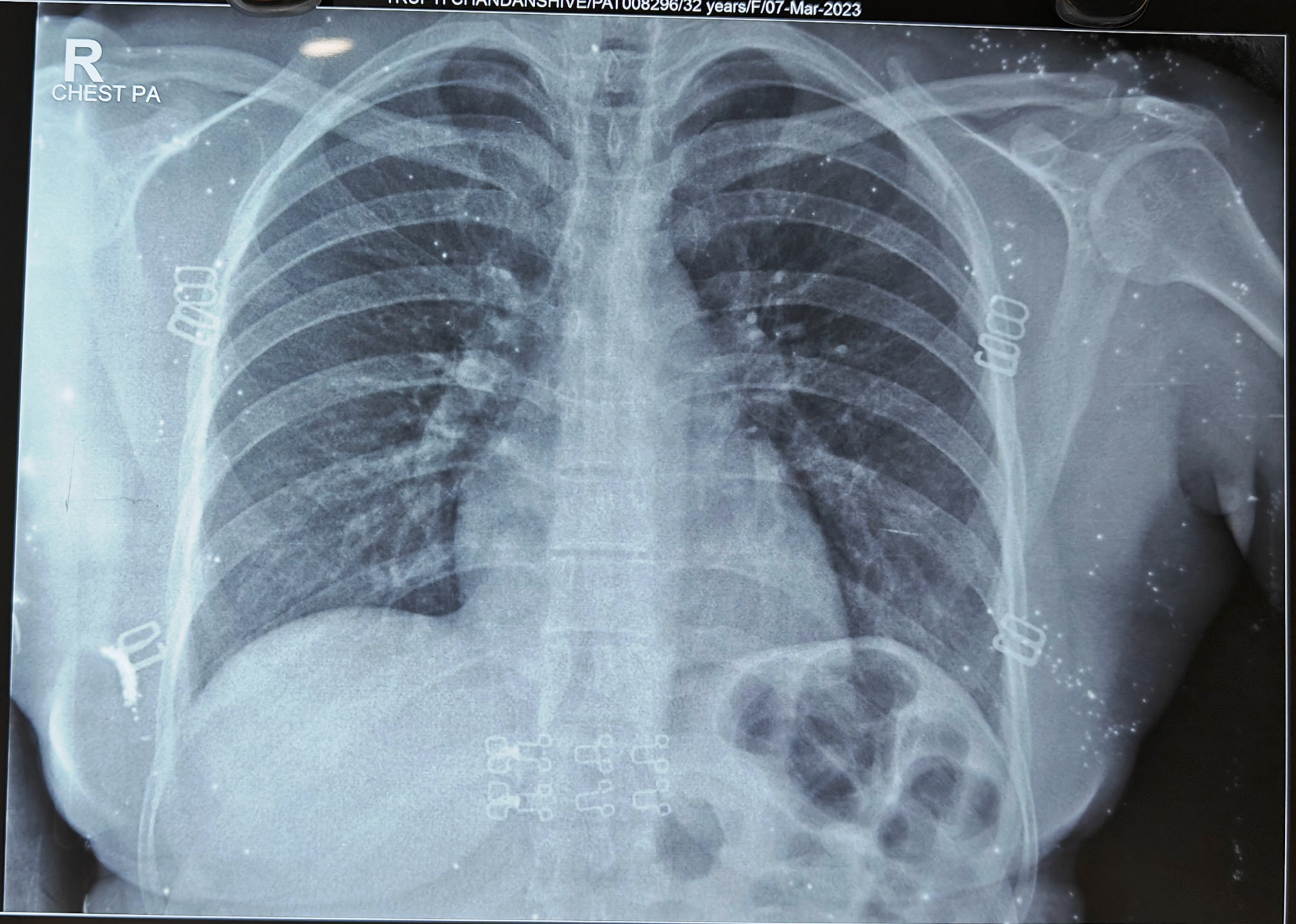
Navid

DR. NAVID SHATTARI
MBBS, MD, DNB
CONSULTANT RADIOLOGIST

GIRIRAJ HOSPITAL

TRUPTI CHANDANSHIVE/PAT008296/32 years/F/07-Mar-2023

R
CHEST PA



GIRIRAJ DIAGNOSTIC CENTER BARAMATI

GIRIRAJ HOSPITAL CAMPUS, INDAPUR ROAD, BARAMATI, PH. 02112-222739/221335.