



இந்திய தனிப்பட்ட அடையாள ஆணைய அமைப்பு

இந்திய அரசாங்கம்  
Unique Identification Authority of India  
Government of India


பதிவேட்டு எண் / Enrolment No.: 2193/10402/00800

To  
பு. சோபா  
P Shobana  
D/O K Panneerselvam  
C2/11, SAF GAMES VILLAGE, JAWAHARLAL NEHRU ROAD  
KOYAMBEDU  
KOYAMBEDU  
Chennai Tamil Nadu - 600107  
9566341515

Download Date: 04/10/2018

Generation Date: 20/09/2013

Signature Not Verified



QR Code with Photograph

உங்கள் ஆதார் எண் / Your Aadhaar No. :

5550 3671 7885

VID : 9148 5344 3059 2285

எனது ஆதார். எனது அடையாளம்



இந்திய அரசாங்கம்  
Government of India



பு. சோபா  
P Shobana  
பிறந்த நாள்/DOB: 11/06/1986  
புணர் / FEMALE



5550 3671 7885

VID : 9148 5344 3059 2285

எனது ஆதார். எனது அடையாளம்



Government of India

AADHAAR

தகவல்

- ஆதார் அடையாளத்திற்கான சான்று, குடியரிமைக்கு அவ்வ.
- அடையாள சான்ற ஆன்வைன் ஆதர்டு கேஷன் மூலமாகப் பெறவும்.
- இது எயக்டானிக் செயல்முறை மூலம் தயாரிக்கப்பட்ட கடிதமாகும்.

INFORMATION

- Aadhaar is a proof of identity, not of citizenship.
- To establish identity, authenticate online.
- This is electronically generated letter.

- ஆதார் நாடு முழுவதிலும் செல்லுபடியாகும்.
- வருங்காலத்தில் அரசு மற்றும் அரசு சாரா சேவைகளை பயன்படுத்திக் கொள்ள ஆதார் உதவிகரமாக இருக்கும்.


- Aadhaar is valid throughout the country.
- Aadhaar will be helpful in availing Government and Non-Government services in future.



இந்திய தனிப்பட்ட அடையாள ஆணைய அமைப்பு  
Unique Identification Authority of India

நபர்:  
D/O க. பன்னேர்செல்வம், #12/11, எஸ்.கே.எம்.பி. விளம்  
செயல்பெட்டு, கோயம்பேடு, சென்னை, தமிழ்நாடு - 600107

Address:  
D/O K Panneerselvam, C2/11, SAF GAMES VILLAGE, JAWAHARLAL NEHRU ROAD, KOYAMBEDU, KOYAMBEDU, Chennai, Tamil Nadu - 600107



QR Code with Photograph

5550 3671 7885

VID : 9148 5344 3059 2285

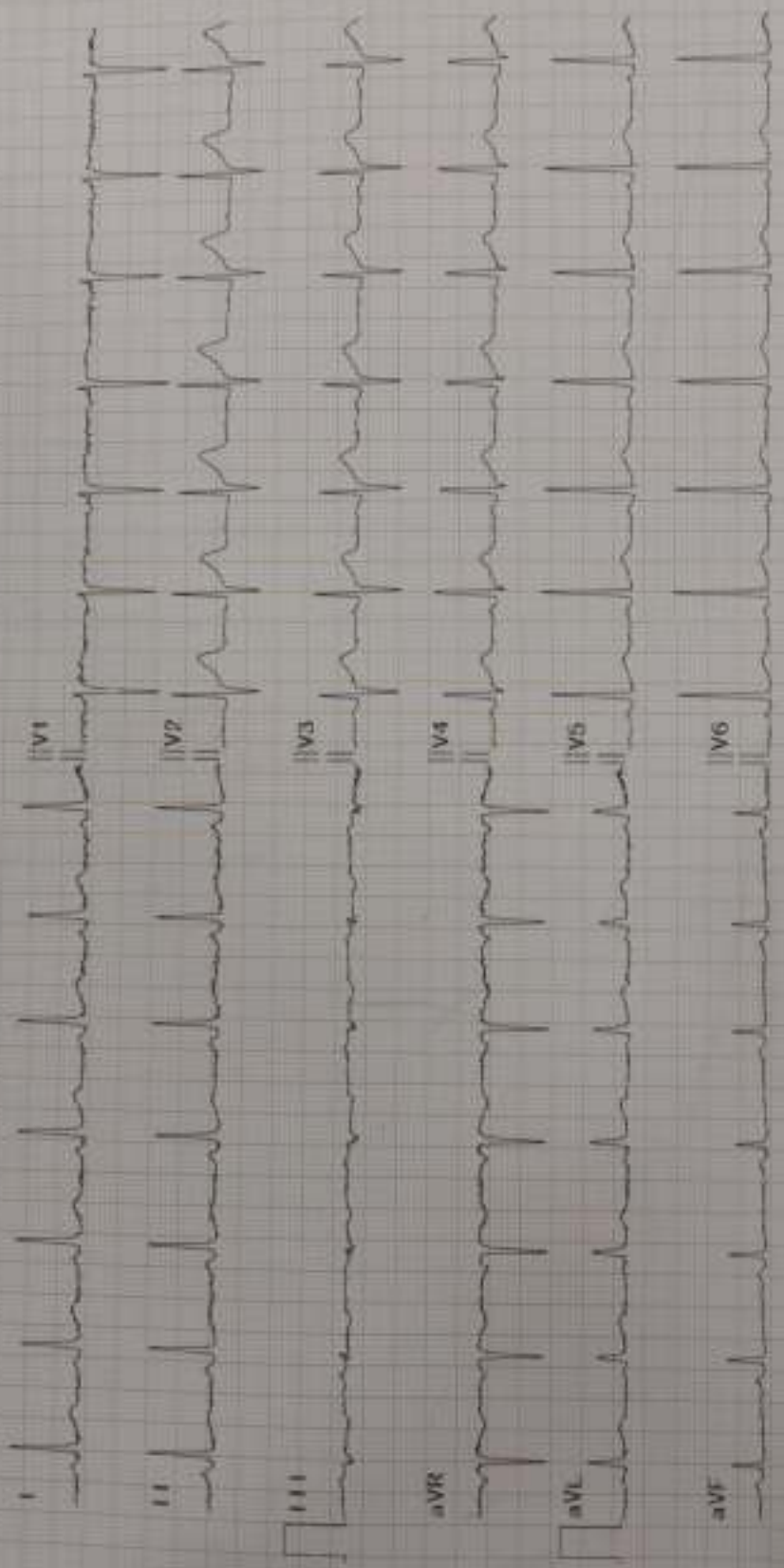
Handwritten signature and date: 23/09/2013

ID: 2309230002  
 Name: MISS SHOBANA  
 Sex: Female  
 Divisions:  
 HR: 85 bpm  
 P Dur: PR int: 88 104ms  
 QRS Dur: 104ms  
 QT/QTc: int: 350/419 ms  
 P-QRS-T axis: 50/25/5

Date/Time: 2023-09-23 10:00  
 Age: 37  
 BP: 100/70 mmHg  
 Bed No:  
 RV5 SV1 amp: 1.409 1.345mV  
 RV5+SV1 amp: 2.754mV  
 RV6 SV2 amp: 1.559 0.640mV

Patient ID: 50082  
 Height: 154 cm  
 Weight: 59 kg  
 Hospital No:  
 Minnesota Code: 9-3-0  
 5-5-0 (I, V5)

Hospital: MURUGAN HOSPITALS  
 Diagnosis Info:  
 800 Sinus Rhythm  
 401 Short PR Interval



SIDHARTHAN MD DM  
 Consultant Cardiologist  
 Reg No. 62979

Diagnosis for reference, ask your doctor to confirm  
 AUTO PRINT 6X2+1R 85bpm 10 mm mV 0.50Hz-35Hz AC 50Hz 25 mm sec Confirmed By





## ECHO CARDIOGRAM REPORT

NAME : MRS.P.SHOBANA PATIENT ID : MH20230050082  
AGE/SEX : 37- Years /Female IP / OP NO : OP21059026  
CONSULTANT : DR.ARUN PRAKASH DATE : 23/09/2023

### 2D PLAX (mm)

RV - 24 mm  
AO - 38 mm  
LA - 46 mm

### M-Mode (mm)

IVS - 06 mm  
PW - 08 mm  
LVD - 41 mm  
LVS - 23 mm  
EF - 68 %  
FS - 43 %

### COLOR DOPPLER

Normal

### DOPPLER (m/sec)

MITRAL E - 0.4 m/s  
MITRAL A - 0.7 m/s  
PULMONARY - 0.7 m/s  
AORTIC - 1.1 m/s  
TRICUSPID - 0.4 m/s

### IMPRESSION:

No regional wall motion abnormality  
Normal LV Systolic function  
Grade I left ventricular diastolic dysfunction  
Normal RV function  
No pulmonary hypertension  
No pericardial effusion  
No obvious clot/ Vegetation.



DR.SIDHARTHAN MD.DM.,  
CONSULTANT CARDIOLOGIST

**Healing Hearts and Lives**

264/125, Kilpauk Garden Road, Kilpauk, Chennai - 600 010.  
Phone : +91 44 4644 8989 / 75500 53335 | Email : muruganhosp@gmail.com  
Website : www.muruganhospitals.in



### SCAN REPORT

NAME	:MRS.P.SHOBANA	PATIENT ID	:MH20230050082
AGE/SEX	:37- Years /Female	IP / OP NO	:OP21059026
CONSULTANT	:DR.ARUN PRAKASH	DATE	:23/09/2023

### ULTRA SOUND SCAN OF ABDOMEN

**LIVER:** Normal in size and normal in echotexture. No focal lesions are seen. No dilatation of intra-hepatic biliary radicals present. Hepatic veins and IVC appear normal. Portal vein is normal in caliber. Common bile duct is normal in caliber.

**GALL BLADDER:** Normal in size and wall thickness. No evidence of any calculus or mass present. No evidence of pericholecystic collections.

**PANCREAS:** Normal in size and echotexture. No focal lesions are seen. No evidence of calculi or calcifications. No evidence of pancreatic duct dilation.

**PARA AORTIC AREAS:** Aorta and IVC appear normal. No evidence of para aortic lymphadenopathy.

**SPLEEN:** Normal in size and measures-11.2 cm. Normal in echotexture. No evidence of focal lesions.

**RIGHT KIDNEY:** Measures 10.6 X 10.2 cm and is normal in size and echotexture. Cortico medullary differentiation is well maintained. There is no hydronephrosis or mass.

**LEFT KIDNEY:** Measures 11.9 x 5.2 cm and is normal in size and echotexture. Cortico medullary differentiation is well maintained. There is no calculus or hydronephrosis or mass.

**Healing Hearts and Lives**

264/125, Kilpauk Garden Road, Kilpauk, Chennai - 600 010. Phone : +91 44 4644 8989 / 75500 53335  
Email : muruganhosp@gmail.com | Website : www.muruganhospitals.in

**URINARY BLADDER:** Normal in size, contour and wall thickness. There is no evidence of calculus or mass. No vesical diverticulum present.

**UTERUS :** Normal in size and normal in echotexture.

No ascites present. No retroperitoneal lymphadenopathy present.

**IMPRESSION:**

***No significant abnormality detected in the visualized abdominal organs.***



**CONSULTANT RADIOLOGIST,**





# MURUGAN HOSPITALS

HEALING HANDS

NAME : MRS.P.SHOBANA UHID : MH20230050082  
AGE / SEX : 37Y/FEMALE OP/IP : OP  
CONSULTANT: DR.ARUN PRAKASH DATE : 23.09.2023

## CHEST XRAY PA VIEW

- Trachea is in midline.
- Hila appear Normal.
- Mediastinal shadow appears normal.
- Costophrenic&Cardiophrenic angles appear free.
- Cardiothoracic ratio is within normal limits.
- Lungs fields appear clear
- Bony thorax and soft tissue appear normal

## IMPRESSION:

- No significant abnormality noted.

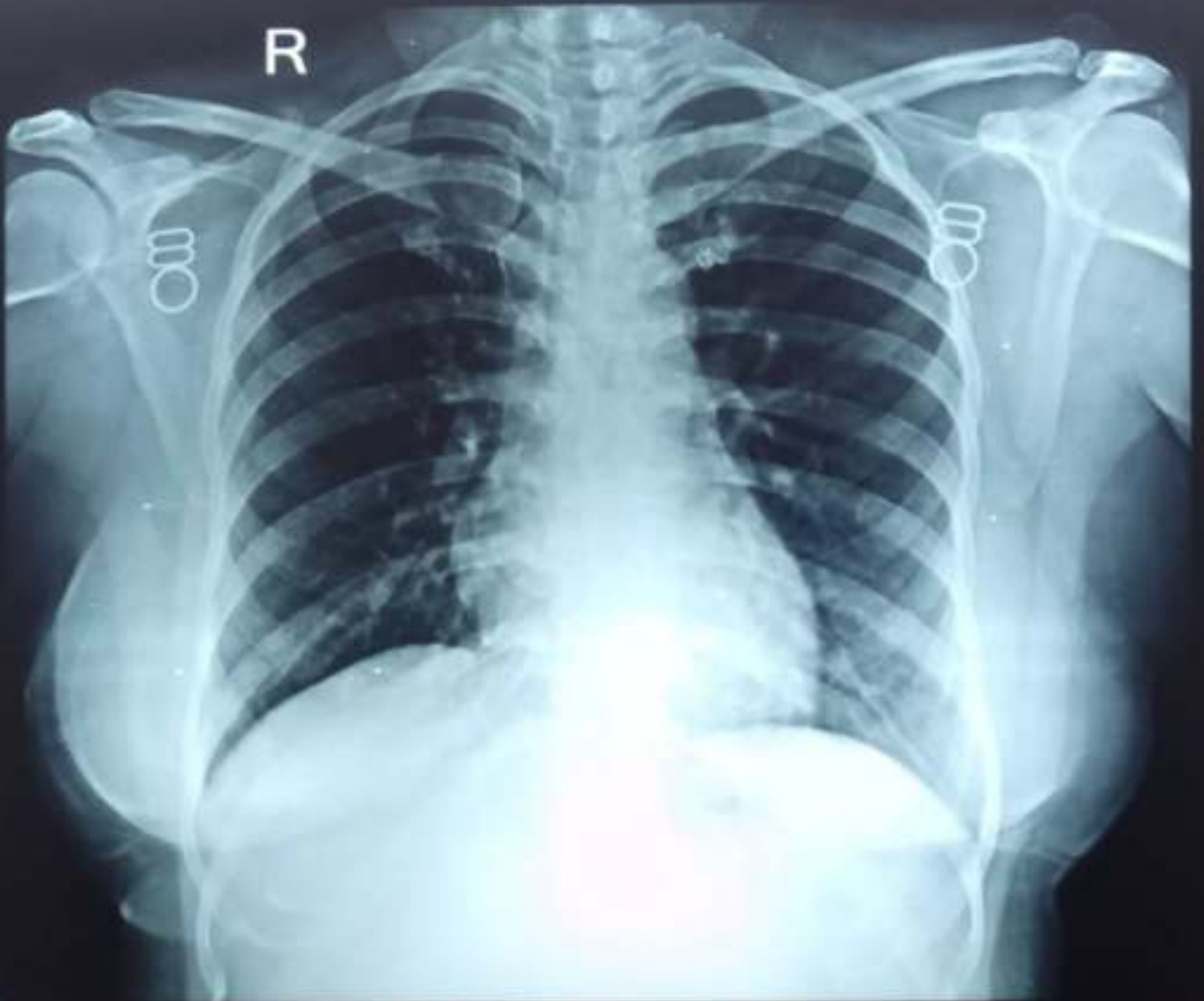CONSULTANT RADIOLOGIST



264/125, Kilpauk Garden Road, Kilpauk, Chennai - 600 010.

☎ : +91 44 4644 8989 / 75500 53335 email : muruganhosp@gmail.com

Website : www.muruganhospitals.in



MRS.P.SHOBANA 37YRS 50082 CHEST-PA 23-09-2023  
MURUGAN HOSPITALS, KILPAUK,CHENNAI-10 PH NO: 7550053335 / 46448989



# MURUGAN HOSPITALS

HEALING HANDS



## LAB REPORT

Patient Name : Mrs. P.SHOBANA  
Age / Gender : 37-Years / Female  
UHID ID : MH20230050082  
Doctor Name : Dr. ARUN PRAKASH

OP Report No. : INVA2111469  
Bill No. : INV2304419  
Sample Date : 23/09/2023 - 10:30 AM  
Report Date : 23/09/2023 - 01:54 PM

Test Name	Result	Units	Reference Interval
<b><u>HAEMATOLOGY</u></b>			
<b>COMPLETE BLOOD CELL COUNT(CBC)</b>			
HAEMOGLOBIN	<u>10.4</u>	gms/dl	male :13.0 - 17.0 female :12.0 - 15.0
PACKED CELL VOLUME	<u>31.5</u>	%	male : 40 - 50 female : 36 - 46
RBC COUNT	4.46	millions cells/cu.mm	female: 3.8 - 4.8 male : 4.5 - 5.5
TOTAL WBC	5,990	Cells/Cumm	4,000 - 11,000
<b>Differential Count</b>			
NEUTROPHILS	53.6	%	40 - 65
LYMPHOCYTES	37.5	%	30-50
EOSINOPHILS	4.0	%	01-06
MONOCYTES	4.9	%	1-10
BASOPHILS	0.0	%	0-2
ESR 60 MTS	10	mm	5 - 20
PLATELET COUNT	2.77	Lakhs/cumm	1.5 - 4.5
MCV	<u>70.6</u>	fL	76 - 96
MCH	<u>23.3</u>	pg	27 - 32
MCHC	33.0	gms/dl	30 - 36
BLOOD GROUPING & RH TYPING	" A " POSITIVE		

Page 1 of 4

**Healing Hearts and Lives**

264/125, Kilpauk Garden Road, Kilpauk, Chennai - 600 010.  
Phone : +91 44 4644 8989 / 75500 53335 | Email : muruganhosp@gmail.com  
Website : www.muruganhospitals.in





# MURUGAN HOSPITALS

HEALING HANDS



## LAB REPORT

Patient Name : Mrs. P.SHOBANA  
Age / Gender : 37-Years / Female  
UHID ID : MH20230050082  
Doctor Name : Dr. ARUN PRAKASH

OP Report No. : INVA2111469  
Bill No. : INV2304419  
Sample Date : 23/09/2023 - 10:30 AM  
Report Date : 23/09/2023 - 01:54 PM

Test Name	Result	Units	Reference Interval
<b><u>BIO CHEMISTRY</u></b>			
BLOOD SUGAR FASTING	<u>189</u>	mg/dl	70-110
BLOOD SUGAR POST PRANDIAL	<u>242</u>	mg/dl	80- 160
SERUM CREATININE	0.8	mg/dl	0.6-1.4
SERUM URIC ACID	3.4	mg/dl	male 3.1-7.0 , female 2.5-5.6
<b>LIPID PROFILE</b>			
TOTALCHOLESTEROL	<u>224</u>	mg/dl	< 200
TRIGLYCERIDE	<u>156</u>	mg/dl	< 150
HDL	48	mg/dl	35 - 80
VLDL	31	mg/dl	2 to 30
LDL	<u>145</u>	mg/dl	<130
CHOLESTEROL/ HDL RATIO	4.6	mg/dl	



### LAB REPORT

Patient Name : Mrs. P.SHOBANA  
Age / Gender : 37-Years / Female  
UHID ID : MH20230050082  
Doctor Name : Dr. ARUN PRAKASH

OP Report No. : INVA2111469  
Bill No. : INV2304419  
Sample Date : 23/09/2023 - 10:30 AM  
Report Date : 23/09/2023 - 01:54 PM

Test Name	Result	Units	Reference Interval
<b>LIVER FUNCTION TEST</b>			
BILLIRUBIN(TOTAL)	0.7	mg/dl	0.0 -1.0
BILLIRUBIN(DIRECT)	0.2	mg/dl	0.1- 0.30
BILLIRUBIN(INDIRECT)	0.5	mg/dl	0.2-0.8
SGOT	28	IU/L	0-38
SGPT	34	IU/L	0.0-40
ALKALINE PHOSPHATASE	63	IU/L	40-140 4-6Years 93-309 13-15Years 74-390
TOTAL PROTEIN	7.9	gm/dl	6.6-8.7
ALBUMIN	4.8	gm/dl	3.5 - 5.5
GLOBULIN	3.1	gm/dl	2.0-3.5
AG RATIO	1.5		
GAMMA G T	52	U/L	< 55 U/ L
BLOOD UREA NITROGEN	7.5	mg/dl	7-21



### LAB REPORT

Patient Name : Mrs. P.SHOBANA  
Age / Gender : 37-Years / Female  
UHID ID : MH20230050082  
Doctor Name : Dr. ARUN PRAKASH

OP Report No. : INVA2111469  
Bill No. : INV2304419  
Sample Date : 23/09/2023 - 10:30 AM  
Report Date : 23/09/2023 - 01:54 PM

Test Name	Result	Units	Reference Interval
-----------	--------	-------	--------------------

### CLINICAL PATHOLOGY

URINE SUGAR (F)	Nil		
URINE SUGAR (PP)	Nil		
<b>URINE ROUTINE</b>			
COLOUR	Pale yellow		
APPEARANCE	Clear		
REACTION	Acidic		
SUGAR	Nil		
ALBUMIN	Nil		
<b>DEPOSITES</b>			
PUS CELLS	1 - 2	/ HPF	
EPI CELLS	2 - 3	/ HPF	
RBC COUNT	Nil	/ HPF	
CAST	Nil		
CRYSTALS	Nil		
OTHERS	Nil		

SHENBAGAVALLI

Verified by

\*\*\* End of Report \*\*\*







# MURUGAN HOSPITALS

HEALING HANDS



## LAB REPORT

Patient Name : Mrs. P.SHOBANA  
Age / Gender : 37-Years / Female  
UHID ID : MH20230050082  
Doctor Name : Dr. ARUN PRAKASH

OP Report No. : INVA2111469  
Bill No. : INV2304419  
Sample Date : 23/09/2023 - 10:30 AM  
Report Date : 24/09/2023 - 03:53 PM

Test Name	Result	Units	Reference Interval
-----------	--------	-------	--------------------

### ENDOCRINOLOGY

T3	0.967	ng/ml	0.52-1.85
T4	8.922	ug/dl	5.0 -13.0 ug/dl
TSH	2.004	uIU/ml	0.39 - 6.16 uiu/ml

SASIKUMAR  
Verified by

\*\*\* End of Report \*\*\*



PAVITHRA  
Pathologist  
Reg. No- 78256

Healing Hearts and Lives