



PARKLINE DIAGNOSTICS PVT. LTD.

L.G. 3, 4 & 5, Bhuvana Towers, S.D. Road, Secunderabad - 500 003.

Tel : +91 40-2784 5852, 6649 1787, 7995421787, 7093445852, Fax : +91 40 2784 7864

Email parklinediagnostics@gmail.com www.parklinediagnostics.com



NABL Accredited
Certificate No.MC-2566

MEDICAL EXAMINATION REPORT

Name	MS. Akasapu nagalakshmi		Date : 26/03/2022
Company	Olo! Mediawheel		Reg. No. : 1902152
Contact No.	9966669001		Sex <input type="checkbox"/> Male <input checked="" type="checkbox"/> Female Age : <input type="checkbox"/> 48
Type	Pre-Emp		Emp. No.: spouse
	Overseas		Height 162 cm
	Annual	<input checked="" type="checkbox"/>	Weight 70 kgs
Remarks	<p>Pap : 70% neutrophils. ? Infection. Advice follow up to Gynaecologist.</p> <p>Mammography : GRADE - I Advice USG - Breast.</p> <p>Rest all clinical & Lab parameters wnl</p>		
			DR. PRIYANKA SANNIDHI MBBS Regn. No. 11351
Fitness Status	Medically Fit / Unfit		Physician's Signature

COMPREHENSIVE MEDICAL EXAMINATION REPORT

NAME Ms. AKASAPU NAGA LAKSHMI

AGE 48 yr / Female.

MARITAL STATUS Married CHILDREN : M F 2

IDENTIFICATION (IF ANY) A mole on the (RT) Forearm

PAST HISTORY

Any family H/o : High Blood Pressure, Heart Disease, Tuberculosis, Diabetes, Asthma, Cancer

Both parents Lab CVD Father Both parents

Any personal H/o Major illness like : Typhoid.....NIL.....Jaundice.....NIL.....Etc.

Any H/o STD.....Skin infection.....On Dorsal surface of the palm.

H/o Blood Transfusion.....Recent Vaccination.....COVISHIELD 2 doses ✓

H/o Epilepsy.....NIL.....Giddiness.....NIL

H/o Surgery.....Fracture in the past.....NIL

Any Personal H/O.

High Blood Pressure, Heart Disease Tuberculosis, Diabetes, Asthma, Cancer

Drug Abuse, Drug Allergy, Micturition, Bowels, Alcohol, Smoking, Sleep, MC, Wt. Loss/Wt. Gain

Present illness / Medication

GENERAL EXAMINATION

Conjunctiva :

Skin :

Ears :

Nose :

Throat & Oral Cavity :

NAD

Bone, Joints :

Nutritional Status :

Lymph Nodes :

Edema Feet :

Varicose Veins :

Spandilytis on/off
Well Nourished 85 years
NPD
NIL
NIL

Distant Vision : Near Vision :

Right Eye: 6/6

With glasses / Without glasses

left Eye : 6/6

with glasses / without glasses

Colour Vision : DE normal

Right Ear

Hearing :

(N)

Rinee's Test ;

Weber Test :

Discharge :

NIL

Right Eye: NB +2.0 sph NB

With glasses / Without glasses

left Eye : NB +2.0 sph NB

with glasses / without glasses

Ophthalmologist's Signature

Left Ear

(N)

SYSTEMIC EXAMINATION

Pulse : 80 bpm

B.P. : 130/80 mmHg

Lungs : A. Shape of Chest B/L symmetrical
B. Breath Sounds B/L clear ⊕
C. Adventitious Sounds No

Heart : A. Sounds S₁ S₂ ⊕
B. Murmurs No murmurs

Abdomen : A. Liver NPD
B. Spleen NPD
C. Piles NIL
D. Any Lump NIL

Nervous System

A. Higher Function :
B. Cranial Nerves :
C. Sensory System :
D. Motor System :
E. Jerks :

(N)

General : A. Hernia
B. Hydrocele
C. Varicocele
] NAD

Breast : Rt _____ Lt. _____

CANDIDATE'S DECLARATION

I hereby solemnly declare that I am not suffering from Asthma, Hypertension, Diabetes, Occult Psychological disorders or any other ailment which can be suppressed without my voluntary declaration.

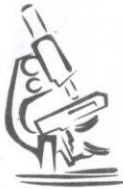Date :

A. Lakshmi

Signature

Place :

Note : General Physical Examination and Investigation included in the health check-up Have certain limitations and may not be able to detect all latent and asymptomatic diseases. Any new symptoms developing after the health check-up or persisting thereafter should be brought to the attention of the treating physician.



PARKLINE DIAGNOSTICS PVT. LTD.

L.G. 3, 4 & 5, Bhuvana Towers, S.D. Road, Secunderabad - 500 003. Tel : +91 40-2784 5852, 6649 1787, 7995421787, 7093445852, Fax : +91 40 2784 7864 Email parklinediagnostics@gmail.com www.parklinediagnostics.com



NABL Accredited
Certificate No.MC-256

ENT CONSULTATION

S.No. 1902152

Emp.No. spouse

Date 26/03/22

Name MS. Akasapu ragga
Lakshmi Age 48 Yrs

Sex M/F

EARS :

Right

Left

EAC : Patent, no Cerumen. - do -

TM : Intact, pearly white. - do -

TFT : Cone of light (+)
Rinne's +ve
Weber's - central

NOSE : Septum (N). Bil. S. mucosa (N). Pans (N) non blocked

THROAT : Oropharynx (N). Bil. uvula (N) moving

NECK : (N) Astenoid bit

IMPRESSION: EAR: clinically normal

Dr. D. Hari Krishna Reddy

Dr. D. Hari Krishna Reddy
MS (ENT)
Head & Neck Surgeon
Reg. No: 88379



PARKLINE DIAGNOSTICS PVT. LTD.

L.G 3, 4 & 5, Bhuvana Towers, Sarojini Devi Road, Secunderabad - 500 003.
Tel. +91 40 2784 5852, 6649 1787, 77995421787, 7093445852, Fax : + 91 40 2784 7864
Email : parklinediagnostics@gmail.com, www.parklinediagnostics.com



NABL Accredited
Certificate No.: MC-2566

TEST REPORT

Mrs. Nagalakshmi

48 yrs

AMP - 15 days?

26-3-22

P₂L₂ A₁

BOTH F-TN

Bowel routine
(N) + Regular

W-D - MIL

periods regular
3-4 days (N) flow

no pain.

Breast - NAD

P/A - NAD

- Exercise

- Balanced Healthy Diet -

- calcium + vit. D

fd

Xtra Cal - 1st D

- 0 - 2 months

fd

Dr. Jamuna Devi. G.
MBBS, DGO, LL.B.(LL.M.)
Regd. No. 9202 A.P. Medical Council,
Obstetrician & Gynaecologist

The Test marked with *are not accredited by NABL

Lab Timings (Weekdays) : 7.00 am to 8.30 pm
Sundays & Holidays : 7.00 am to 1.00 pm

Prenderghat Radiology & Diagnostic Centre (weekdays) : 7.30 am to 1.30 pm
Near Paradise Circle, Secunderabad-500 003. & 5.30 pm to 7.45 pm
Sundays & Holidays : 7.30 am to 9.30 am

7799686970

Name : A. Naga Laxmi Sex : F Age : 48

Date : 26/3/22


OPD No : 528

Attrition in lower anterior

O/E
 Deep bite in lower
 anterior.

Trauma from occlusion
 in lower anterior.

Adv. of G.

Smilesss 
 MULTI SPECIALITY DENTAL CLINIC
Smile Confidently... Non-Identically...
 B.D.S, IMPLANTOLOGIST (USA)
 1-3-1, Rajamudaliar Street, Kalasiguda,
 Secunderabad, Cell : 8977910590



PARKLINE DIAGNOSTICS PVT. LTD.

L.G 3, 4 & 5, Bhuvana Towers, Sarojini Devi Road, Secunderabad - 500 003.
Tel. +91 40 2784 5852, 6649 1787, 77995421787, 7093445852, Fax : + 91 40 2784 7864
Email : parklinediagnostics@gmail.com, www.parklinediagnostics.com



NABL Accredited
Certificate No.: MC-2566

TEST REPORT

Name : Ms . AKASAPU NAGA LAKSHMI [SPOUSE]
Age / Gender : 48 Years / Female
Ref.By : Medi Wheel
Req. No : BIL1907152

TID : UMR0752885
Registered on : 26-Mar-2022 07:36 AM
Reported On : 26-Mar-2022 01:25 PM

ABDOMINO-PELVIC ULTRASONOGRAPHY

LIVER is normal shape, size (12.2 cms) and increased echopattern.
No evidence of focal lesion or intrahepatic biliary ductal dilatation.
Hepatic and portal vein radicals are normal.

GALL BLADDER shows normal shape and has clear contents.
Gall bladder wall is of normal thickness. CBD is of normal calibre.

PANCREAS has normal shape, size and uniform echopattern.
No evidence of ductal dilatation or calcification.

SPLEEN shows normal shape, size (9.2 cms) and echopattern.

KIDNEYS move well with respiration and have normal shape, size and echopattern. Cortico-medullary differentiations are well made out.
No evidence of calculus or hydronephrosis.
Right kidney measures: 9.0 x 4.2 cms, Left kidney measures: 9.9 x 3.7 cms.

URINARY BLADDER shows normal shape and wall thickness.
It has clear contents. No evidence of diverticula.

UTERUS is anteverted has normal shape and size.
It has uniform myometrial echopattern.
Endometrial echo is of normal thickness 4.2 mm.
Uterus measures 6.4 x 3.5 x 3.5 cms.


OVARIES are not visualized.

No evidence of free fluid in the abdomen and pelvis.

IMPRESSION:

* **Grade I fatty liver.**

Suggested clinical correlation and follow up


Dr. Karuna Belide
Consultant Radiologist

The Test marked with*are not accredited by NABL

Lab Timings (Weekdays) : 7.00 am to 8.30 pm
Sundays & Holidays : 7.00 am to 1.00 pm

Radiologists Timings (Weekdays) : 7.30 am to 1.30 pm
& 5.30 pm to 7.45 pm
Sundays & Holidays : 7.30 am to 9.30 am



PARKLINE DIAGNOSTICS PVT. LTD.

L.G 3, 4 & 5, Bhuvana Towers, Sarojini Devi Road, Secunderabad - 500 003.
Tel. +91 40 2784 5852, 6649 1787, 77995421787, 7093445852, Fax : + 91 40 2784 7864
Email : parklinediagnostics@gmail.com, www.parklinediagnostics.com



NABL Accredited
Certificate No.: MC-2566

TEST REPORT

Name	: Ms . AKASAPU NAGA LAKSHMI [SPOUSE]	TID	: UMR0752885
Age / Gender	: 48 Years / Female	Registered on	: 26-Mar-2022 07:36 AM
Ref.By	: Medi Wheel	Reported On	: 26-Mar-2022 12:27 PM
Req. No	: BIL1907152		

DEPARTMENT OF ULTRASOUND Mammography

Bilateral CC and MLO views done.

Both breasts show normal fibro-glandular parenchyma.

No dominant mass /pleomorphic micro calcifications /skin thickening /
Nipple retraction on either side.

No architectural distortion.


No evidence of duct dilatation.

No axillary lymphadenopathy.

IMPRESSION : No breast abnormality noted - BIRADS-I

Advised : USG Breast.

Note: Please bring previous reports on next visit.


Dr. PRAJAKTA SUKHADEVE
DNB RADIOLOGY
Reg. No. 88493

The Test marked with*are not accredited by NABL

Lab Timings (Weekdays) : 7.00 am to 8.30 pm
Sundays & Holidays : 7.00 am to 1.00 pm

Radiologists Timings (Weekdays) : 7.30 am to 1.30 pm
& 5.30 pm to 7.45 pm
Sundays & Holidays : 7.30 am to 9.30 am

Page 1 of 2

PARKLINE DIAGNOSTICS PVT. LTD.

L.G 3, 4 & 5, Bhuvana Towers, Sarojini Devi Road, Secunderabad - 500 003.
Tel. +91 40 2784 5852, 6649 1787, 77995421787, 7093445852, Fax : + 91 40 2784 7864
Email : parklinediagnostics@gmail.com, www.parklinediagnostics.com



NABL Accredited
Certificate No.: MC-2566

TEST REPORT

Name	: Ms . AKASAPU NAGA LAKSHMI [SPOUSE]	TID	: UMR0752885
Age / Gender	: 48 Years / Female	Registered on	: 26-Mar-2022 07:36 AM
Ref.By	: Medi Wheel	Reported On	: 26-Mar-2022 12:27 PM
Req. No	: BIL1907152		

BIRADS ASSESSMENT CATEGORIES

- 0 - Needs additional imaging.
- 1 - Negative - There is nothing the comment on.
- 2 - Benign finding.
- 3 - Probably benign finding - followup after 3 months suggested.
- 4 - Suspicious abnormality. Biopsy should be considered
[4A - Low suspicion ,4B - Intermediate suspicion, 4C- Moderate concern]
- 5 - Highly suggestive of malignancy.
- 6 - Known biopsy proven malignancy.

The Test marked with*are not accredited by NABL.

Lab Timings (Weekdays) : 7.00 am to 8.30 pm
Sundays & Holidays : 7.00 am to 1.00 pm

Radiologists Timings (Weekdays) : 7.30 am to 1.30 pm
& 5.30 pm to 7.45 pm
Sundays & Holidays : 7.30 am to 9.30 am



PARKLINE DIAGNOSTICS PVT. LTD.

L.G 3, 4 & 5, Bhuvana Towers, Sarojini Devi Road, Secunderabad - 500 003.
Tel. +91 40 2784 5852, 6649 1787, 77995421787, 7093445852, Fax : + 91 40 2784 7864
Email : parklinediagnostics@gmail.com, www.parklinediagnostics.com



NABL Accredited
Certificate No.: MC-2566

TEST REPORT

Name : Ms . AKASAPU NAGA LAKSHMI [SPOUSE]
Age / Gender : 48 Years / Female
Ref.By : Medi Wheel
Req. No : BIL1907152

TID : UMR0752885
Registered on : 26-Mar-2022 07:36 AM
Reported On : 26-Mar-2022 10:05 AM

X-RAY CHEST PA VIEW

Lung fields are clear.

Cardia is normal.

Hila are normal.


C P angles are free.

Bony cage is normal.

Soft tissues are normal.

IMPRESSION : NORMAL CHEST X-RAY




Dr. D.J. MOHAN
MD DMRD
(Reg No. 8995)
Consultant Radiologist

The Test marked with*are not accredited by NABL

Lab Timings (Weekdays) : 7.00 am to 8.30 pm
Sundays & Holidays : 7.00 am to 1.00 pm

Radiologists Timings (Weekdays) : 8.30 am to 1.30 pm
& 5.30 pm to 7.45 pm
Sundays & Holidays : 7.30 am to 9.30 am

ID: 1907152 26-03-2022 08:11:58 AM
MS.AKASAPU NAGA LAKSHMI
Female 48Years

CARDIART

HR : 76 bpm
P : 89 ms
PR : 129 ms
QRS : 72 ms
QT/QTc : 359/405 ms
P/QRS/T : 60/14/-24 °
RV5/SV1 : 1.315/0.934 mV

N.S.P.
DR. NAVEEN KUMAR .C
M.D., D.M.
Consultant Cardiologist
Reg. No. 52291

Diagnosis Information:
Sinus Rhythm
Poor R Wave Progression(V2)
Flattened T Wave(V4,V5)

Report Confirmed by:

PATIENT SUMMARY REPORT

PARKLINE DIAGNOSTICS PVT.LTD

ID : 1907152
NAME : **MS AKASAPU NAGA LAKSHMI**
AGE / SEX : 48 / FEMALE

HEIGHT (cm) : 162
WEIGHT (kg) : 70
PROTOCOL : BRUCE

REF. BY : MEDIWHEEL
DONE BY : DR NAVEEN KUMAR C
TECHNICIAN : G.M.SURESH

CASE HISTORY :

MEDICATION :

OBJECT OF TEST : Routine Check Up.

RISK FACTOR : None.

ACTIVITY : Very Active.

OTHER INVESTIGATION : ECG

REASON FOR TERMINATION : THR ACHIEVED

EXERCISE TOLERANCE : Good (> 10 METS).

EXERCISE INDUCED ARRHYTHMIAS : No.

HAEMO RESPONSE : Normal.

CHRONO RESPONSE : Normal.

FINAL IMPRESSION :

Negative for inducible ischemia

EXTRA COMMENTS :

Dr. NAVEEN KUMAR .C
M.D., D.M.
Consultant Cardiologist
Reg. No. 52291

Confirmed By : _____

Signature

RPI - DYNATRAC