



PARKLINE DIAGNOSTICS PVT. LTD.

L.G. 3, 4 & 5, Bhuvana Towers, S.D. Road, Secunderabad - 500 003.
Tel : +91 40-2784 5852, 6649 1787, 7995421787, 7093445852, Fax : +91 40 2784 7864
Email parklinediagnostics@gmail.com www.parklinediagnostics.com



NABL Accredited
Certificate No.MC-2566

MEDICAL EXAMINATION REPORT

Name	Mr. Antony Johnson		Date :	26/03/2022	
Company	CO: Mediwheel		Reg. No. :	1907488	
Contact No.	9809869609		Sex	<input checked="" type="checkbox"/> M	Age : <input type="checkbox"/> 30
Type	Pre-Emp		Emp. No.:	183280	
	Overseas		Height	173cm	
	Annual	<input checked="" type="checkbox"/>	Weight	84kg	
Remarks	Both physical & Lab parameters within (N) limits.				
Fitness Status	Medically Fit / Unfit		DR. PRIYANKA SANNIDHI MBBS Regn. No : 11351		
			Physician's Signature		


COMPREHENSIVE MEDICAL EXAMINATION REPORT

NAME Mr ANTONY JOHNSON

AGE 30 yrs / Male

MARITAL STATUS Married CHILDREN: M F

IDENTIFICATION (IF ANY) A mole on the (RH Forearm)



PAST HISTORY

Any family H/o : High Blood Pressure, Heart Disease, Tuberculosis, Diabetes, Asthma, Cancer Pat's Father

Father Mother Mother Brain (Buser)

Any personal H/o Major illness like : Typhoid.....NIL.....Jaundice.....NIL.....Etc.

Any H/o STD.....NIL.....Skin infection.....NIL

H/o Blood Transfusion.....NIL.....Recent Vaccination.....COVISHIELD 2 Doses ✓

H/o Epilepsy.....NIL.....Giddiness.....NIL

H/o Surgery.....NIL.....Fracture in the past.....NIL

Any Personal H/O.

High Blood Pressure, Heart Disease Tuberculosis, Diabetes, Asthma, Cancer

Drug Abuse, Drug Allergy, Micturition, Bowels, Alcohol, Smoking, Sleep, MC, Wt. Loss/Wt. Gain

occasional

Present illness / Medication

GENERAL EXAMINATION

Conjunctiva :
 Skin :
 Ears : NAD
 Nose :
 Throat & Oral Cavity :


Bone, Joints : (N)
 Nutritional Status : well nourished
 Lymph Nodes : NPP
 Edema Feet : N/L
 Varicose Veins : N/L

CANDIDATE'S DECLARATION

I hereby solemnly declare that I am not suffering from Asthma, Hypertension, Diabetes, Occult Psychological disorders or any other ailment which can be suppressed without my voluntary declaration.

Date :

Signature



Place :

Note : General Physical Examination and Investigation included in the health check-up Have certain limitations and may not be able to detect all latent and asymptomatic diseases. Any new symptoms developing after the health check-up or persisting thereafter should be brought to the attention of the treating physician.



PARKLINE DIAGNOSTICS PVT. LTD.

L.G. 3, 4 & 5, Bhuvana Towers, S.D. Road, Secunderabad - 500 003. Tel : +91 40-2784 5852, 6649 1787, 7995421787, 7093445852, Fax : +91 40 2784 7864 Email parklinediagnostics@gmail.com www.parklinediagnostics.com



NABL Accredited
Certificate No.MC-2566

ENT CONSULTATION

S.No. 1902088

Emp.No. 183280

Date 26/3/22

Name Mr. Antony Johnson Age 30 Yrs

Sex M F

EARS :

Right

Left

EAC

: patent, no Cerumen

-ob-

TM

: Intact, pearly white.

-ob-

TFT

: Cone of light (+)

Rinne's +ve

Rinne's +ve

Weber's - central

NOSE

: Septum 2 Dns to Rt. Bil. Visc, med. l. n. pos n. non tend.

THROAT

: Oropharynx n. Bil. v. c. & j. n. moving
Arytenoids bil.

NECK

: n

IMPRESSION:

ENT! Dns to Rt.

Dr. D. Hanu Krishna Reddy
MS (ENT)
Head & Neck Surgeon
Reg. No: 88379

7799686970


Name : Antony Johnson Sex : M Age : 30

Date : 26/3/22

OPD No : 538

DC int 

P.

Adv. Restⁿ int 


MULTI SPECIALITY DENTAL CLINIC
Smile Confidentially, Not Compromisingly...
B.D.S. IMPLANTOLOGIST (USA)
11, Rajamudaliar Street, Kalasiguda,
90,

--	--	--	--	--	--

--	--	--	--	--	--



PARKLINE DIAGNOSTICS PVT. LTD.

L.G 3, 4 & 5, Bhuvana Towers, Sarojini Devi Road, Secunderabad - 500 003.
Tel. +91 40 2784 5852, 6649 1787, 77995421787, 7093445852, Fax : + 91 40 2784 7864
Email : parklinediagnostics@gmail.com, www.parklinediagnostics.com



TEST REPORT

Name : Mr . ANTONY JOHNSON [183280]
Age / Gender : 30 Years / Male
Ref.By : Medi Wheel
Req. No : BIL1907488

TID : UMR0753097
Registered on : 26-Mar-2022 09:34 AM
Reported On : 26-Mar-2022 01:24 PM

Ultrasound Whole Abdomen

LIVER is normal shape, size (14.6 cms) and has uniform echopattern. No evidence of focal lesion. No intrahepatic biliary ductal dilatation. Hepatic and portal vein radicals are normal.

GALL BLADDER shows normal shape and has clear contents. Gall bladder wall is of normal thickness. CBD is of normal calibre.

PANCREAS has normal shape, size and uniform echopattern. No evidence of ductal dilatation or calcification.

SPLEEN shows normal shape, size (12.2 cms) and echopattern.

KIDNEYS move well with respiration and have normal shape, size and echopattern. Cortico-medullary differentiations are well made out. No evidence of calculus or hydronephrosis. Right kidney measures : 10.5 x 4.0 cms, Left kidney measures : 11.6 x 4.2 cms.


URINARY BLADDER shows normal shape and wall thickness. It has clear contents. No evidence of diverticula.

PROSTATE shows normal shape, size and echopattern.

No evidence of free fluid in the abdomen and pelvis.

IMPRESSION: NORMAL STUDY.

Suggested clinical correlation and follow up


Dr. Karuna Belide
Consultant Radiologist

The Test marked with*are not accredited by NABL

Lab Timings (Weekdays) : 7.00 am to 8.30 pm
Sundays & Holidays : 7.00 am to 1.00 pm

Radiologists Timings (Weekdays) : 7.30 am to 1.30 pm
& 5.30 pm to 7.45 pm
Sundays & Holidays : 7.30 am to 9.30 am



PARKLINE DIAGNOSTICS PVT. LTD.

L.G 3, 4 & 5, Bhuvana Towers, Sarojini Devi Road, Secunderabad - 500 003.
Tel. +91 40 2784 5852, 6649 1787, 77995421787, 7093445852, Fax : + 91 40 2784 7864
Email : parklinediagnostics@gmail.com, www.parklinediagnostics.com



NABL Accredited
Certificate No.: MC-2566

TEST REPORT

Name : Mr . ANTONY JOHNSON [183280]
Age / Gender : 30 Years / Male
Ref.By : Medi Wheel
Req. No : BIL1907488

TID : UMR0753097
Registered on : 26-Mar-2022 09:34 AM
Reported On : 26-Mar-2022 12:19 PM

X-RAY CHEST PA VIEW

Lung fields are clear.

Cardia is normal.

Hila are normal.

C P angles are free.

Bony cage is normal.

Soft tissues are normal.

IMPRESSION : NORMAL CHEST X-RAY



ds
Dr. PRAJAKTA SUKHADEVE
DNB RADIOLOGY
Reg. No. 68493

The Test marked with*are not accredited by NABL

Lab Timings (Weekdays) : 7.00 am to 8.30 pm
Sundays & Holidays : 7.00 am to 1.00 pm


Radiologists Timings (Weekdays) : 7.30 am to 1.30 pm
& 5.30 pm to 7.45 pm
Sundays & Holidays : 7.30 am to 9.30 am

ID: 1907488 26-03-2022 09:46:16 AM
MR. ANTONY JOHNSON
Male 30Years

CARDIART

HR : 64 bpm
P : 118 ms
PR : 182 ms
QRS : 93 ms
QT/QTc : 376/389 ms
P/QRS/T : 16/64/11 °
RV5/SV1 : 1.436/0.793 mV

Diagnosis Information:
Sinus Rhythm
Normal ECG

USA
WNC

Dr. NAVEEN KUMAR .C
M.D., D.M.
Consultant Cardiologist
Reg. No. 57291

Report Confirmed by:

PATIENT SUMMARY REPORT

CG

REF. BY : MEDIWHEEL
DONE BY : DR NAVEEN KUMAR C
TECHNICIAN : G.M.SURESH

VE DIAGNOSTICS PVT.LTD
: 1907488
: MR ANTHONY JOHNSON
EX : 30 / MALE

HEIGHT (cm) : 173
WEIGHT (kg) : 84
PROTOCOL : BRUCE

-2022, 13:14:0

ISTORY :

ATION :

F OF TEST :

Routine Check Up.

ACTOR :

None.

TY :

Very Active.

R INVESTIGATION :

E C G

ON FOR TERMINATION :

THR ACHIEVED

ISE TOLERANCE :

Good (> 10 METS).

ISE INDUCED ARRHYTHMIAS :

No.

IO RESPONSE :

Normal.

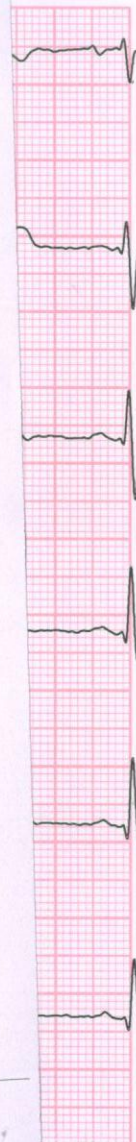NO RESPONSE :

Normal.

L IMPRESSION :

Negative for inducible ischemia

COMMENTS :



Dr. NAVEEN KUMAR .C
M.D., D.M.

Confirmed By : *[Signature]*
Consultant Cardiologist
Reg. No 52291

Signature