

Patient Name : Mr.RAJU POLISETTY  
 Age/Gender : 37 Y 8 M 26 D/M  
 UHID/MR No : CMYS.0000056561  
 Visit ID : CMYSOPV131291  
 Ref Doctor : Self  
 Emp/Auth/TPA ID : 22E38022

Collected : 09/Nov/2024 08:31AM  
 Received : 09/Nov/2024 10:10AM  
 Reported : 09/Nov/2024 11:52AM  
 Status : Final Report  
 Sponsor Name : ARCOFEMI HEALTHCARE LIMITED

**DEPARTMENT OF HAEMATOLOGY**

**ARCOFEMI - MEDIWHEEL - FULL BODY ANNUAL PLUS MALE - 2D ECHO - PAN INDIA - FY2324**

**PERIPHERAL SMEAR , WHOLE BLOOD EDTA**

-----



**Dr. PAVAN KUMAR M**  
 M.B.B.S,M.D(Pathology)  
 Consultant Pathologist

SIN No:MYS241100369



Patient Name : Mr.RAJU POLISETTY	Collected : 09/Nov/2024 08:31AM
Age/Gender : 37 Y 8 M 26 D/M	Received : 09/Nov/2024 10:10AM
UHID/MR No : CMYS.0000056561	Reported : 09/Nov/2024 01:13PM
Visit ID : CMYSOPV131291	Status : Final Report
Ref Doctor : Self	Sponsor Name : ARCOFEMI HEALTHCARE LIMITED
Emp/Auth/TPA ID : 22E38022	

**DEPARTMENT OF HAEMATOLOGY**

**ARCOFEMI - MEDIWHEEL - FULL BODY ANNUAL PLUS MALE - 2D ECHO - PAN INDIA - FY2324**

Test Name	Result	Unit	Bio. Ref. Interval	Method
<b>HEMOGRAM , WHOLE BLOOD EDTA</b>				
<b>HAEMOGLOBIN</b>	14.8	g/dL	13-17	Spectrophotometer
PCV	44.30	%	40-50	Electronic pulse & Calculation
RBC COUNT	5.09	Million/cu.mm	4.5-5.5	Electrical Impedance
MCV	87	fL	83-101	Calculated
MCH	29.1	pg	27-32	Calculated
MCHC	33.4	g/dL	31.5-34.5	Calculated
R.D.W	<b>11.5</b>	%	11.6-14	Calculated
TOTAL LEUCOCYTE COUNT (TLC)	6,490	cells/cu.mm	4000-10000	Electrical Impedance
<b>DIFFERENTIAL LEUCOCYTIC COUNT (DLC)</b>				
NEUTROPHILS	43	%	40-80	Electrical Impedance
LYMPHOCYTES	39	%	20-40	Electrical Impedance
EOSINOPHILS	<b>12</b>	%	1-6	Electrical Impedance
MONOCYTES	5	%	2-10	Electrical Impedance
BASOPHILS	1	%	0-2	Electrical Impedance
<b>ABSOLUTE LEUCOCYTE COUNT</b>				
NEUTROPHILS	2790.7	Cells/cu.mm	2000-7000	Calculated
LYMPHOCYTES	2531.1	Cells/cu.mm	1000-3000	Calculated
EOSINOPHILS	<b>778.8</b>	Cells/cu.mm	20-500	Calculated
MONOCYTES	324.5	Cells/cu.mm	200-1000	Calculated
BASOPHILS	64.9	Cells/cu.mm	0-100	Calculated
Neutrophil lymphocyte ratio (NLR)	1.1		0.78- 3.53	Calculated
<b>PLATELET COUNT</b>	220000	cells/cu.mm	150000-410000	Electrical impedance
<b>ERYTHROCYTE SEDIMENTATION RATE (ESR)</b>	<b>24</b>	mm at the end of 1 hour	0-15	Modified Westergren
<b>PERIPHERAL SMEAR</b>				

**R.B.C:** Majority are normocytic normochromic.

**W.B.C:** Are normal in number,morphology and increase in eosinophils.

**Platelets:** Adequate and are seen in singles and clumps.

**Hemoparasites:** Not seen.



Dr. PAVAN KUMAR M  
M.B.B.S,M.D(Pathology)  
Consultant Pathologist

SIN No:MYS241100369



Patient Name : Mr.RAJU POLISETTY  
 Age/Gender : 37 Y 8 M 26 D/M  
 UHID/MR No : CMYS.0000056561  
 Visit ID : CMYSOPV131291  
 Ref Doctor : Self  
 Emp/Auth/TPA ID : 22E38022

Collected : 09/Nov/2024 08:31AM  
 Received : 09/Nov/2024 10:10AM  
 Reported : 09/Nov/2024 01:13PM  
 Status : Final Report  
 Sponsor Name : ARCOFEMI HEALTHCARE LIMITED

**DEPARTMENT OF HAEMATOLOGY**

**ARCOFEMI - MEDIWHEEL - FULL BODY ANNUAL PLUS MALE - 2D ECHO - PAN INDIA - FY2324**

**IMPRESSION: NORMOCYTIC NORMOCHROMIC BLOOD PICTURE WITH EOSINOPHILIA.**



**Dr. PAVAN KUMAR M**  
 M.B.B.S,M.D(Pathology)  
 Consultant Pathologist

SIN No:MYS241100369




Patient Name : Mr.RAJU POLISETTY	Collected : 09/Nov/2024 08:31AM
Age/Gender : 37 Y 8 M 26 D/M	Received : 09/Nov/2024 10:10AM
UHID/MR No : CMYS.0000056561	Reported : 09/Nov/2024 01:13PM
Visit ID : CMYSOPV131291	Status : Final Report
Ref Doctor : Self	Sponsor Name : ARCOFEMI HEALTHCARE LIMITED
Emp/Auth/TPA ID : 22E38022	

**DEPARTMENT OF HAEMATOLOGY**

**ARCOFEMI - MEDIWHEEL - FULL BODY ANNUAL PLUS MALE - 2D ECHO - PAN INDIA - FY2324**

Test Name	Result	Unit	Bio. Ref. Interval	Method
<b>BLOOD GROUP ABO AND RH FACTOR , WHOLE BLOOD EDTA</b>				
BLOOD GROUP TYPE	O			Forward & Reverse Grouping with Slide/Tube Aggluti
Rh TYPE	POSITIVE			Forward & Reverse Grouping with Slide/Tube Agglutination



**Dr. PAVAN KUMAR M**  
M.B.B.S,M.D(Pathology)  
Consultant Pathologist

SIN No:MYS241100369



Patient Name : Mr.RAJU POLISETTY	Collected : 09/Nov/2024 08:31AM
Age/Gender : 37 Y 8 M 26 D/M	Received : 09/Nov/2024 10:10AM
UHID/MR No : CMYS.0000056561	Reported : 09/Nov/2024 10:51AM
Visit ID : CMYSOPV131291	Status : Final Report
Ref Doctor : Self	Sponsor Name : ARCOFEMI HEALTHCARE LIMITED
Emp/Auth/TPA ID : 22E38022	

**DEPARTMENT OF BIOCHEMISTRY**

**ARCOFEMI - MEDIWHEEL - FULL BODY ANNUAL PLUS MALE - 2D ECHO - PAN INDIA - FY2324**

Test Name	Result	Unit	Bio. Ref. Interval	Method
GLUCOSE, FASTING , NAF PLASMA	75	mg/dl	74-106	GOD, POD

**Comment:**

As per American Diabetes Guidelines, 2023

Fasting Glucose Values in mg/dL	Interpretation
70-100 mg/dL	Normal
100-125 mg/dL	Prediabetes
≥126 mg/dL	Diabetes
<70 mg/dL	Hypoglycemia

**Note:**

- 1.The diagnosis of Diabetes requires a fasting plasma glucose of > or = 126 mg/dL and/or a random / 2 hr post glucose value of > or = 200 mg/dL on at least 2 occasions.
2. Very high glucose levels (>450 mg/dL in adults) may result in Diabetic Ketoacidosis & is considered critical.



Dr. PAVAN KUMAR M  
M.B.B.S,M.D(Pathology)  
Consultant Pathologist

SIN No:MYS241100371





Patient Name : Mr.RAJU POLISETTY	Collected : 09/Nov/2024 08:31AM
Age/Gender : 37 Y 8 M 26 D/M	Received : 09/Nov/2024 04:33PM
UHID/MR No : CMYS.0000056561	Reported : 09/Nov/2024 04:35PM
Visit ID : CMYSOPV131291	Status : Final Report
Ref Doctor : Self	Sponsor Name : ARCOFEMI HEALTHCARE LIMITED
Emp/Auth/TPA ID : 22E38022	

**DEPARTMENT OF BIOCHEMISTRY**

**ARCOFEMI - MEDIWHEEL - FULL BODY ANNUAL PLUS MALE - 2D ECHO - PAN INDIA - FY2324**

Test Name	Result	Unit	Bio. Ref. Interval	Method
<b>HBA1C (GLYCATED HEMOGLOBIN) , WHOLE BLOOD EDTA</b>				
HBA1C, GLYCATED HEMOGLOBIN	5.1	%		HPLC
ESTIMATED AVERAGE GLUCOSE (eAG)	100	mg/dL		Calculated

**Comment:**

Reference Range as per American Diabetes Association (ADA) 2023 Guidelines:

REFERENCE GROUP	HBA1C %
NON DIABETIC	<5.7
PREDIABETES	5.7 – 6.4
DIABETES	≥ 6.5
DIABETICS	
EXCELLENT CONTROL	6 – 7
FAIR TO GOOD CONTROL	7 – 8
UNSATISFACTORY CONTROL	8 – 10
POOR CONTROL	>10

**Note:** Dietary preparation or fasting is not required.

1. HbA1c is recommended by American Diabetes Association for Diagnosing Diabetes and monitoring Glycemic Control by American Diabetes Association guidelines 2023.

2. Trends in HbA1C values is a better indicator of Glycemic control than a single test.

3. Low HbA1C in Non-Diabetic patients are associated with Anemia (Iron Deficiency/Hemolytic), Liver Disorders, Chronic Kidney Disease. Clinical Correlation is advised in interpretation of low Values.

4. Falsely low HbA1c (below 4%) may be observed in patients with clinical conditions that shorten erythrocyte life span or decrease mean erythrocyte age. HbA1c may not accurately reflect glycemic control when clinical conditions that affect erythrocyte survival are present.

5. In cases of Interference of Hemoglobin variants in HbA1C, alternative methods (Fructosamine) estimation is recommended for Glycemic Control

A: HbF >25%

B: Homozygous Hemoglobinopathy.

(Hb Electrophoresis is recommended method for detection of Hemoglobinopathy)



Dr. PAVAN KUMAR M  
M.B.B.S,M.D(Pathology)  
Consultant Pathologist

SIN No:MYS241100375

















Patient Name : Mr.RAJU POLISETTY	Collected : 09/Nov/2024 08:31AM
Age/Gender : 37 Y 8 M 26 D/M	Received : 09/Nov/2024 11:12AM
UHID/MR No : CMYS.0000056561	Reported : 09/Nov/2024 12:30PM
Visit ID : CMYSOPV131291	Status : Final Report
Ref Doctor : Self	Sponsor Name : ARCOFEMI HEALTHCARE LIMITED
Emp/Auth/TPA ID : 22E38022	

**DEPARTMENT OF CLINICAL PATHOLOGY**

**ARCOFEMI - MEDIWHEEL - FULL BODY ANNUAL PLUS MALE - 2D ECHO - PAN INDIA - FY2324**

Test Name	Result	Unit	Bio. Ref. Interval	Method
<b>COMPLETE URINE EXAMINATION (CUE) , URINE</b>				
<b>PHYSICAL EXAMINATION</b>				
COLOUR	PALE YELLOW		PALE YELLOW	Visual
TRANSPARENCY	CLEAR		CLEAR	Physical Measurement
pH	5.5		5-7.5	Double Indicator
SP. GRAVITY	1.025		1.002-1.030	Bromothymol Blue
<b>BIOCHEMICAL EXAMINATION</b>				
URINE PROTEIN	NEGATIVE		NEGATIVE	Protein Error Of Indicator
GLUCOSE	NEGATIVE		NEGATIVE	Glucose Oxidase
URINE BILIRUBIN	NEGATIVE		NEGATIVE	Azo Coupling Reaction
URINE KETONES (RANDOM)	NEGATIVE		NEGATIVE	Sodium Nitro Prusside
UROBILINOGEN	NORMAL		NORMAL	Modified Ehrlich Reaction
NITRITE	NEGATIVE		NEGATIVE	Diazotization
LEUCOCYTE ESTERASE	NEGATIVE		NEGATIVE	Leucocyte Esterase
<b>CENTRIFUGED SEDIMENT WET MOUNT AND MICROSCOPY</b>				
PUS CELLS	2 - 3	/hpf	0-5	Microscopy
EPITHELIAL CELLS	5 - 7	/hpf	<10	Microscopy
RBC	NIL	/hpf	0-2	Microscopy
CASTS	NIL		0-2 Hyaline Cast	Microscopy
CRYSTALS	ABSENT		ABSENT	Microscopy

**Comment:**

All urine samples are checked for adequacy and suitability before examination. All abnormal chemical examination are rechecked and verified by manual methods. Microscopy findings are reported as an average of 10 high power fields.



**Dr. PAVAN KUMAR M**  
M.B.B.S.,M.D(Pathology)  
Consultant Pathologist

SIN No:MYS241100374



Patient Name : Mr.RAJU POLISETTY	Collected : 09/Nov/2024 08:31AM
Age/Gender : 37 Y 8 M 26 D/M	Received : 09/Nov/2024 11:12AM
UHID/MR No : CMYS.0000056561	Reported : 09/Nov/2024 11:54AM
Visit ID : CMYSOPV131291	Status : Final Report
Ref Doctor : Self	Sponsor Name : ARCOFEMI HEALTHCARE LIMITED
Emp/Auth/TPA ID : 22E38022	

**DEPARTMENT OF CLINICAL PATHOLOGY**

**ARCOFEMI - MEDIWHEEL - FULL BODY ANNUAL PLUS MALE - 2D ECHO - PAN INDIA - FY2324**

Test Name	Result	Unit	Bio. Ref. Interval	Method
URINE GLUCOSE(POST PRANDIAL)	NEGATIVE		NEGATIVE	GOD-POD

Test Name	Result	Unit	Bio. Ref. Interval	Method
URINE GLUCOSE(FASTING)	NEGATIVE		NEGATIVE	GOD-POD

**\*\*\* End Of Report \*\*\***



**Dr. PAVAN KUMAR M**  
M.B.B.S,M.D(Pathology)  
Consultant Pathologist

SIN No:MYS241100372









---

Patient	Mr. RAJU POLISETTY	Doctor	MADHURA B P	Appt ID	CMYSAPT1416
Age/Gender	37Y   Male	Qualification	M.Sc. Nutrition and Dietetics	Consult Date	10 Nov 2024
UHID	CMYS.0000056561	Reg. No.	A104102	Order Bill ID	CMYS-OCR-24653
				Visit Display ID	CMYSOPV131291

---

## VITALS

---

Weight : 109.8Kgs	Height : 170Cms
Pulse : 64 BPM	Spo2 : 96%
BP : 120 / 70 MmHg	Respiratory Rate : 20 BPM
Temperature : 98 °F	

MADHURA B P  
**Doctor's Signature**

**Apollo Health and Lifestyle Limited**

(CIN-U85110TG2000PLC115819)

Corporate Office: 7-1-617/A, 7\* Floor, Imperial Towers, Ameerpet, Hyderabad-500016, Telangana

Ph No: 040-4904 7777 | www.apollohl.com | Email ID:enquiry@apollohl.com

---

Patient Name	: Mr. RAJU POLISETTY	Age	: 37Yrs 8Mths 28Days
UHID	: CMYS.0000056561	OP Visit No.	: CMYSOPV131291
Printed On	: 10-11-2024 04:47 AM	Advised/Pres Doctor	: --
Department	: Radiology	Qualification	: --
Referred By	: Self	Registration No.	: --
Employeer Id	: 22E38022		

---

### DEPARTMENT OF RADIOLOGY

---

**LIVER:** It is normal in size, outline and is increased in echotexture. No focal lesions seen. IHBR are not dilated. CBD and Portal vein are normal.

**GALL BLADDER:** It is distended and normal. No evidence of calculi.

**SPLEEN:** It is normal in size, outline and echopattern. No e/o focal lesions.

**PANCREAS:** It is normal in size, outline and echopattern.

**RIGHT KIDNEY:** It measures 10.6 cm with parenchymal thickness of 1.6 cm. It is normal in size, outline and echotexture. No e/o calculus or hydronephrosis seen.

**LEFT KIDNEY:** It measures 10.2 cm with parenchymal thickness of 1.4 cm. It is normal in size, outline and echotexture. No e/o calculus or hydronephrosis seen. A tiny simple cyst measuring ~8x7mm is noted in interpole cortex of left kidney.

**URINARY BLADDER:** It is well distended. The UB wall is normal. No e/o calculi.

**PROSTATE:** It is mildly enlarged (measures~25cc) with normal echotexture.

---

---

No e/o free fluid in the abdomen.

**IMPRESSION:**

**GRADE I FATTY LIVER .**

**GRADE I PROSTATOMEGLY**

---End Of The Report---



Dr.CHETAN HOLEPPAGOL  
MBBS, DNB(RADIO DIAGNOSIS)

90037

Radiology

---

---

Patient Name	: Mr. RAJU POLISETTY	Age	: 37Yrs 9Mths 1Days
UHID	: CMYS.0000056561	OP Visit No.	: CMYSOPV131291
Printed On	: 14-11-2024 07:39 AM	Advised/Pres Doctor	: --
Department	: Cardiology	Qualification	: --
Referred By	: Self	Registration No.	: --
Employer Id	: 22E38022		

---

**DEPARTMENT OF CARDIOLOGY**

---

**2D ECHOCARDIOGRAPHY STUDY**

**Impression:**

Normal chambers and valves  
No regional wall motion abnormality  
Normal left ventricular systolic function. EF 67 %  
No clots. No pericardial effusion

??????

**Findings**

Left Ventricle: No RWMA  
Right Ventricle Normal  
Left Atrium Normal  
Right Atrium Normal  
Aorta Normal  
Pulmonary Artery Normal  
IAS Intact  
IVS Intact  
Valves Normal  
Pericardium Normal  
Doppler Normal

---

**Patient's Name : Mr. RAJU POLISETTY Age & Sex; 37Yrs /Male**

**Date : 09.11.2024**

**UHID No: 56561**

#### Measurements

AO:2.8cm

LA :2.7 cm

RV :2.2 cm

LVIDd 4.51 cm

LVIDs :2.83 cm

IVSd :0.79cm

---

IVSs :1.11 cm

PWd :0.98cm

PWs :1.11 cm

EF : 67.0 %

FS : 37.0 %

Doppler

MV TV AV PV

E :0.61 m/sE --- m/sV max1.17 m/sV max0.94 m/s

A: 0.32m/sA --- m/s

---End Of The Report---



---

---

Dr. GURU PRASAD B V  
MBBS, PGDCC  
69949  
Cardiology

---

Patient Name	: Mr. RAJU POLISETTY	Age	: 37Yrs 8Mths 28Days
UHID	: CMYS.0000056561	OP Visit No.	: CMYSOPV131291
Printed On	: 10-11-2024 03:57 AM	Advised/Pres Doctor	: --
Department	: Cardiology	Qualification	: --
Referred By	: Self	Registration No.	: --
Employer Id	: 22E38022		

---

**DEPARTMENT OF CARDIOLOGY**

---

Observation :-

1. Sinus Rhythm.
2. Heart rate is 66 beats per minutes.

**Impression:**

NORMAL RESTING ECG.

---End Of The Report---



Dr. GURU PRASAD B V  
MBBS, PGDCC  
69949  
Cardiology



Name : Mr. RAJU POLISETTY  
Address : Mysore Mysore Karnataka INDIA 570001  
Plan : ARCOFEMI MEDIWHEEL MALE AHC CREDIT  
PAN INDIA OP AGREEMENT

Age : 37Y 8M 26D  
sex : Male  
H - 170  
W - 109.8  
BP - 120/70

UHID : CMYS.0000056561



CMYS.0000056561

OP No: CMYSOPV131291  
Bill No: CMYS-OCR-24653  
Date: Nov 9th, 2024, 8:29 AM

Sno.	Service Type/Service Name	Department	
1	ARCOFEMI - MEDIWHEEL - FULL BODY ANNUAL PLUS MALE - 2D ECHO - PAN INDIA - FY2324		
1	DENTAL CONSULTATION	Consultation	<input type="checkbox"/>
2	ENT CONSULTATION	Consultation	<input type="checkbox"/>
3	FITNESS BY GENERAL PHYSICIAN	Consultation	<input type="checkbox"/>
4	OPHTHAL BY GENERAL PHYSICIAN	Consultation	<input type="checkbox"/>
5	GAMMA GLUTAMYL TRANSFERASE (GGT)	Biochemistry	<input type="checkbox"/>
6	LIPID PROFILE	Biochemistry	<input type="checkbox"/>
7	HbA1c, GLYCATED HEMOGLOBIN	Biochemistry	<input type="checkbox"/>
8	GLUCOSE, POST PRANDIAL (PP), 2 HOURS (POST MEAL)	Biochemistry	<input type="checkbox"/>
9	GLUCOSE, FASTING	Biochemistry	<input type="checkbox"/>
10	PERIPHERAL SMEAR	Haematology	<input type="checkbox"/>
11	HEMOGRAM + PERIPHERAL SMEAR	Haematology	<input type="checkbox"/>
12	BLOOD GROUP ABO AND RH FACTOR	Blood Bank	<input type="checkbox"/>
13	COMPLETE URINE EXAMINATION	Clinical Pathology	<input type="checkbox"/>
14	RENAL PROFILE/RENAL FUNCTION TEST (RFT/KFT)	Biochemistry	<input type="checkbox"/>
15	THYROID PROFILE (TOTAL T3, TOTAL T4, TSH)	Biochemistry	<input type="checkbox"/>
16	ULTRASOUND - WHOLE ABDOMEN	Ultrasound Radiology	<input type="checkbox"/>
17	X-RAY CHEST PA	X Ray Radiology	<input type="checkbox"/>
18	URINE GLUCOSE(POST PRANDIAL)	Clinical Pathology	<input type="checkbox"/>
19	URINE GLUCOSE(FASTING)	Clinical Pathology	<input type="checkbox"/>
20	LIVER FUNCTION TEST (LFT)	Biochemistry	<input type="checkbox"/>
21	2 D ECHO	Cardiology	<input type="checkbox"/>
22	ECG	Cardiology	<input type="checkbox"/>
23	BODY MASS INDEX (BMI)	General	<input type="checkbox"/>
24	DIET CONSULTATION	General	<input type="checkbox"/>

## CERTIFICATE OF MEDICAL FITNESS

This is to certify that I have conducted the clinical examination

of Mr. Raju Polisetty on 9/11/24.

After reviewing the medical history and on clinical examination it has been found that he/she is

	Tick
<ul style="list-style-type: none"> <li>• Medically Fit</li> </ul>	<input checked="" type="checkbox"/>
<ul style="list-style-type: none"> <li>• Fit with restrictions/recommendations</li> </ul> <p>Though following restrictions have been revealed, in my opinion, these are not impediments to the job.</p> <p>1.....</p> <p>2.....</p> <p>3.....</p> <p>However the employee should follow the advice/medication that has been communicated to him/her.</p> <p>Review after _____</p>	
<ul style="list-style-type: none"> <li>• Currently Unfit.</li> </ul> <p>Review after _____ recommended</p>	
<ul style="list-style-type: none"> <li>• Unfit</li> </ul>	

Dr. Jankund  
 Medical Officer  
**Apollo Clinic**  
 # 23, 1st Floor  
 Kalidasa Road, Mysore - 02  
 Ph: 0824-9026040/43

*This certificate is not meant for medical-legal purposes*

**Apollo Health and Lifestyle Limited**

(CIN - U85110TG2000PLC115819)  
 Regd. Office: 1-10-60/62, Ashoka Raghupathi Chambers, 5th Floor, Begumpet, Hyderabad, Telangana - 500 016.  
 Ph No: 040-4904 7777, Fax No: 4904 7744 | Email ID: enquiry@apollohl.com | www.apollohl.com

**APOLLO CLINICS NETWORK KARNATAKA**  
 Bangalore (Basavanagudi) | Bellandur | Electronic City | Fraser Town | HSR Layout | Indira Nagar | JP Nagar | Kundalahalli |  
 Koramangala | Sarjapur Road | Mysore (VV Mohalla)  
 Online appointments: www.apolloclinic.com

TO BOOK AN APPOINTMENT  
 **1860 500 7788**

[Phy]

Mr. Raju Polisetty

37yrs / Male

Dr. J. MUKUND  
MBBS, MD (Internal  
Medicine)

Height: 170cm	Weight: 109.8kg	BMI:	Waist Circum:
Temp:	Pulse:	Resp:	B.P: 120/70

General Examination /  
Allergies History

Clinical Diagnosis & Management Plan

Routine Health Check up.

NO comorbidities.

Reports - Noted


Nil Intervention

Follow up date :

*J. Mukund*

Doctor Signature

**Apollo Clinic**  
# 23, 1st Floor,  
Kalidasa Road, Mysore - 02  
Ph : 0821-4006040/41



Date : 11/9/2024 Department : Nutrition & Dietetics  
 Patient Name : Mr. RAJU POLISETTY Doctor : Miss.MADHURA B P  
 UHID : CMYS.0000056561 Registration No. : A104102  
 Age / Gender : 37Yrs 8Mths 26Days/ Male Qualification : M.Sc. Nutrition and Dietetics  
 Consultation Timing : 9:40 AM Ph.D.

T.B.W - 69kg

Height : 170	Weight : 109.8	BMI : 37.9 kg/m <sup>2</sup>	Waist Circum : 120/70
Temp :	Pulse :	Resp :	B.P :

General Examination / Allergies History

ESR - 24  
 Triglycerides - 226  
 HDL - 26  
 VLDL - 45.12  
 chol/HDL - 5.39

Clinical Diagnosis & Management Plan

- Δ<sup>sr</sup> - Grade I fatty liver
- ⇒ Advise low fat diet with fiber rich foods.
  - ⇒ Take small frequent meals, do not skip meals.
  - ⇒ Include all variety of seasonal fruits, vegetables and green leafy vegetables.
  - ⇒ Include nuts like Almonds and walnuts.
  - ⇒ Include dry-fruits like dried dates and raisins.
  - ⇒ Include seeds like Flaxseeds, Pumpkin seeds, Sesame seeds, Sunflower seeds & watermelon seeds - 1 teaspoon each, dry roasted.
  - ⇒ Regular physical activity is compulsory.
  - ⇒ Drink 12-14 big glasses of water daily.

Follow up date :

Doctor Signature

*[Signature]*  
 M. B. P  
 9/11/2024

**Apollo Clinic**  
 # 23, 1st Floor,  
 Kalidasa Road, Mysore - 02  
 Ph : 0821-4006040/41

Date : 11/9/2024 Department : ENT  
 Patient Name : Mr. RAJU POLISETTY Doctor : Dr. PRAVEEN KUMAR R  
 UHID : CMYS.0000056561 Registration No. : 66012  
 Age / Gender : 37Yrs 8Mths 26Days/ Male Qualification : MBBS, MS (ENT)  
 Consultation Timing : 9:39 AM

Height : 170	Weight : 109.8	BMI :	Waist Circum :
Temp :	Pulse :	Resp :	B.P : 120/70

General Examination /  
Allergies History

Clinical Diagnosis & Management Plan

Come for regular health checkup

(R) Chronic Otitis media  
All. sinus

P/E

Ears - (R) TM - subtotal perforation

(L) TM - normal

Note - normal mucosa pale. dnwto (R)  
poly (L)

nasal cavity is clear (L)

neck - (L)

Follow up date:

11/10/2024

Doctor Signature

**Apollo Clinic**

# 23, 1st Floor,

Kalidasa Road, Mysore - 02

Ph: 0822-440889/9101

June to

PK

Date : 11/9/2024 Department : Dental  
 Patient Name : Mr. RAJU POLISETTY Doctor : Dr. JYOTHISHREE P V  
 UHID : CMYS.0000056561 Registration No. : 33268A  
 Age / Gender : 37Yrs 8Mths 26Days/ Male Qualification : B.D.S[Bachelor of Dental Surgery]  
 Consultation Timing : 9:39 AM

Height : 170	Weight : 69.8	BMI :	Waist Circumf :
Temp :	Pulse :	Resp :	B.P : 120/80

General Examination /  
Allergies History

Clinical Diagnosis & Management Plan

O/E

Catt, Stt

ADU, - Oral Prophy

8 | Decay

ADU, - Resolution



*Seetha*

Follow up date :

Doctor Signature

**Apollo Clinic**  
 # 23, 1st Floor,  
 Kalidasa Road, Mysore - 02  
 Ph : 0821-4006040/41

[Ophthalmology]

Date : 11/9/2024 Department : General Practice  
Patient Name : Mr. RAJU POLISETTY Doctor : Dr. SUJATHA T R  
UHID : CMYS.0000056561 Registration No. : 69649  
Age / Gender : 37Yrs 8Mths 26Days/ Male Qualification : MBBS, PGDMCH  
Consultation Timing : 9:38 AM

Height : 170	Weight : 109.8	BMI :	Waist Circum :
Temp :	Pulse :	Resp :	B.P : 120/70

General Examination /  
Allergies History

Clinical Diagnosis & Management Plan

Distance  
vision

un { 6/6  
6/6

Colour  
vision

no

near  
vision


(cu) = normal

Follow up date : 09/11/24

*Sujatha T R*  
Doctor Signature

**Apollo Clinic**  
# 23, 1st Floor,  
Kalidasa Road, Mysore - 02  
Ph : 0821-4006040/41

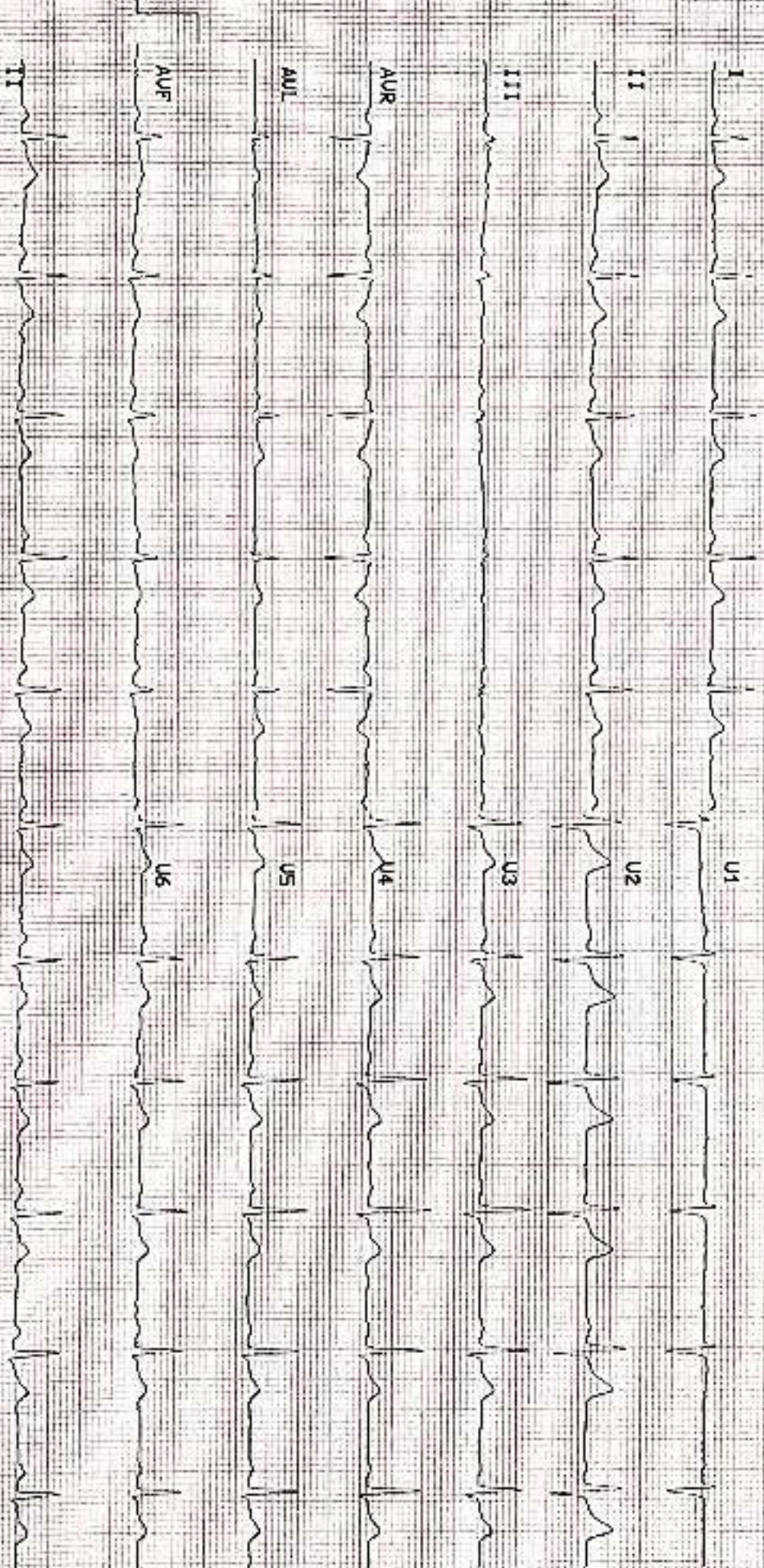
AGE: 37 NO:   
 Measurement Results:   
 QRS : 102 ms   
 QT/QTcB : 392 / 415 ms   
 PR : 166 ms   
 P : 132 ms   
 RR/PP : 892 / 835 ms   
 P/QRS/T : 25 / 30 / 20 degrees   
 QTd/QTcBD : 22 / 23 ms   
 Sokolow : 1.4 mV   
 NK : 9



Interpretation:

Unconfirmed report.

**Apollo Clinic**  
 # 23, 1st Floor,  
 Kalladasa Road, Mysore - 02  
 Ph : 0821-4006040/41





Patient Name	: Mr. RAJU POLISETTY	Age	: 37Yrs 8Mths 26Days
UHID	: CMYS.0000056561	OP Visit No.	: CMYSOPV131291
Printed On	: 09-11-2024 12:44 PM	Advised/Pres Doctor	: --
Department	: Radiology	Qualification	: --
Referred By	: Self	Registration No.	: --
Employee Id	: 22E38022		

**DEPARTMENT OF RADIOLOGY**

Lung fields are clear.

Cardio thoracic ratio is normal.

Apices, costo and cardio phrenic angles are free.

Cardio vascular shadow and hila show no abnormal feature.

Bony thorax shows no significant abnormality.

Domes of diaphragm are well delineated.

**IMPRESSION: NORMAL STUDY .**

---End Of The Report---



**Dr.CHETAN HOLEPPAGOL**  
**MBBS, DNB(RADIO DIAGNOSIS)**  
90037  
Radiology

Patient Name: Mr. RAJU POLISETTY	Date: 09.11.2024	Referring Doctor: Self
Age / Sex : 37 yrs / Male	UHID : 56561	
<b>ULTRASONOGRAPHY – ABDOMEN &amp; PELVIS</b>		

**LIVER:** It is normal in size, outline and is increased in echotexture. No focal lesions seen. IHBR are not dilated. CBD and Portal vein are normal.

**GALL BLADDER:** It is distended and normal. No evidence of calculi.

**SPLEEN:** It is normal in size, outline and echopattern. No e/o focal lesions.

**PANCREAS:** It is normal in size, outline and echopattern.

**RIGHT KIDNEY:** It measures 10.6 cm with parenchymal thickness of 1.6 cm. It is normal in size, outline and echotexture. No e/o calculus or hydronephrosis seen.

**LEFT KIDNEY:** It measures 10.2 cm with parenchymal thickness of 1.4 cm. It is normal in size, outline and echotexture. No e/o calculus or hydronephrosis seen. A tiny simple cyst measuring ~8x7mm is noted in interpole cortex of left kidney.

**URINARY BLADDER:** It is well distended. The UB wall is normal. No e/o calculi.

**PROSTATE:** It is mildly enlarged (measures ~25cc) with normal echotexture.

No e/o free fluid in the abdomen.

**IMPRESSION:**

**GRADE I FATTY LIVER,  
GRADE I PROSTATOMEGLY**

*Karthik*  
Dr. Karthik H V MDRD, DNB  
Consultant Radiologist.

Apollo Health and Lifestyle Limited

CIN: UR51107G2000PLC115819

Regd Office: 1-10-60-62, Ashoka Raghupathi Chambers, 5th Floor Begumpet, Hyderabad, Telangana - 500 016  
Ph No: 040-4904 7777 Fax No: 4904 7744 | Email ID: enquiry@apollohd.com | www.apollohd.com

APOLLO CLINICS NETWORK KARNATAKA

Bangalore | Banavahally | Bellandur | Electronic City | Frazer Town | HSR Layout | Indira Nagar | JP Nagar | Kundalahalli | Koramangala | Sarjapur Road | Mysore (VV Mohalla)

Online appointments: www.apolloclinic.com

TO BOOK AN APPOINTMENT

**1860/500 7788**

Patient's Name : Mr. RAJU POLISETTY	Age & Sex; 37Yrs /Male
Date : 09.11.2024	UHID No: 56561

## 2D ECHOCARDIOGRAPHY STUDY

### Impression:

- Normal chambers and valves
- No regional wall motion abnormality
- Normal left ventricular systolic function. EF 67 %
- No clots. No pericardial effusion

### Findings

Left Ventricle:	No RWMA
Right Ventricle	Normal
Left Atrium	Normal
Right Atrium	Normal
Aorta	Normal
Pulmonary Artery	Normal
IAS	Intact
IVS	Intact
Valves	Normal
Pericardium	Normal
Doppler	Normal

### Apollo Health and Lifestyle Limited

CIN: U85110TG2000PLC1158191

Regd Office: 1-10-60-62, Ashoka Raghupathi Chambers, 5th Floor, Begumpet, Hyderabad, Telangana - 500 016

Ph. No: 040 4904 7777 Fax No: 4904 7744 | Email ID: enquiry@apollohl.com | www.apollohl.com

### APOLLO CLINICS NETWORK KARNATAKA

Bangalore | Basavanahalli | Bellandur | Electronic City | Fraser Town | HSR Layout | Indira Nagar | JP Nagar | Kundalahalli | Koramangala | Sarjapur Road | Mysore (VV Mohalla)

Online appointments: www.apolloclinic.com

TO BOOK AN APPOINTMENT

 **1860 500 7788**

Patient's Name : Mr. RAJU POLISETTY

Age & Sex; 37 Yrs / Male

Date : 09.11.2024

UHID No: 56561

Measurements

AO : 2.8 cm  
LA : 2.7 cm

RV : 2.2 cm  
LVIDd : 4.51 cm  
LVIDs : 2.83 cm  
IVSd : 0.79 cm  
IVSs : 1.11 cm  
PWd : 0.98 cm  
PWs : 1.11 cm  
EF : 67.0 %  
FS : 37.0 %

Doppler  
MV TV AV PV  
E 0.61 m/s E --- m/s V max 1.17 m/s V max 0.94 m/s  
:  
A: 0.32 m/s A --- m/s



Dr. GURU PRASAD. B. V, MBBS, PGDCC  
CONSULTANT – NON-INVASIVE CARDIOLOGY

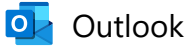
Apollo Health and Lifestyle Limited

ICIN U85110TG2000PLC1158191  
Head Office: 1-10-60-62, Ashoka Raghupathi Chambers, 5th Floor, Begumpet, Hyderabad, Telangana - 500 016  
Ph.No: 040-4904 7777 Fax No: 4904 7744 | Email ID: enquiry@apolloh.com | www.apolloh.com

APOLLO CLINICS NETWORK KARNATAKA  
Bangalore | Survanagudi | Bellandur | Electronic City | Fraser Town | HSR Layout | Indra Nagar | JP Nagar | Kundalahalli |  
Koramangala | Sarjapur Road | Mysore (VV Mohalla)  
Online appointments: www.apolloh.com

TO BOOK AN APPOINTMENT  
**1860 500 7788**





Your appointment is confirmed

From noreply@apolloclinics.info <noreply@apolloclinics.info>

Date Thu 07-11-2024 18:36

To raju.mca222@gmail.com <raju.mca222@gmail.com>

Cc Mysore Apolloclinic <mysore@apolloclinic.com>; Yogeesh KV <mkt.mysore@apolloclinic.com>; Syamsunder M <syamsunder.m@apollohl.com>



Dear MR. POLISETTY RAJU,

Greetings from Apollo Clinics,

Your corporate health check appointment is confirmed at **KALIDASA RAOD clinic** on **2024-11-09** at **08:15-08:30**.

Payment Mode	
Corporate Name	<b>ARCOFEMI HEALTHCARE LIMITED</b>
Agreement Name	<b>[ARCOFEMI MEDIWHEEL MALE AHC CREDIT PAN INDIA OP AGREEMENT]</b>
Package Name	<b>[ARCOFEMI - MEDIWHEEL - FULL BODY ANNUAL PLUS MALE - 2D ECHO - PAN INDIA - FY2324]</b>

"Kindly carry with you relevant documents such as HR issued authorization letter and or appointment confirmation mail and or valid government ID proof and or company ID card and or voucher as per our agreement with your company or sponsor."

**Note: Video recording or taking photos inside the clinic premises or during camps is not allowed and would attract legal consequences.**

**Note: Also once appointment is booked, based on availability of doctors at clinics tests will happen, any pending test will happen based on doctor availability and clinics will be updating the same to customers.**

**Instructions to be followed for a health check:**

1. Please ensure you are on complete fasting for 10-To-12-Hours prior to check.
2. During fasting time do not take any kind of alcohol, cigarettes, tobacco or any other liquids (except Water) in the morning. If any medications taken, pls inform our staff before health check.

3. Please bring all your medical prescriptions and previous health medical records with you.
4. Kindly inform our staff, if you have a history of diabetes and cardiac problems.

**For Women:**

1. Pregnant women or those suspecting are advised not to undergo any X-Ray test.
2. It is advisable not to undergo any health check during menstrual cycle.

**For further assistance, please call us on our Help Line #: 1860 500 7788.**

**Clinic Address: 23, KALIDASA ROAD, VV MOHLLA, MYSORE.**

**Contact No: (0821) 400 6040 - 41.**

P.S: Health Check-Up may take 4 - 5hrs for completion on week days & 5 - 6hrs on Saturdays, kindly plan accordingly, Doctor Consultation will be completed after all the Reports are ready.

Warm Regards,  
Apollo Clinic