



# ABI SCANS & LABS

A unit of Aarthi Scans and Labs

Name	MRS.MEENA A	Patient ID	86475
Accession No	89986	Age/Gender	35Y / Female
Referred By	Dr.MEDIWHEEL	Date	27-Feb-2022

## USG REPORT - ABDOMEN AND PELVIS

### LIVER:

Is normal in size ~ 13.9 cm and shows increased echo texture.

No obvious focal lesion seen. No intra - Hepatic biliary radical dilatation seen.

### GALL BLADDER:

Is adequately distended. No calculus or internal echoes are seen. Wall thickness is normal.

### PANCREAS:

Appears normal in size and it shows uniform echo texture.

### SPLEEN:

Is normal in size ~ 10 cm and shows uniform echogenicity.

### RIGHT KIDNEY:

Right kidney measures ~ 10.5 x 3.3 cms.

The shape, size and contour of the right kidney appear normal.

Cortico medullary differentiation is within normal. No evidence of pelvicalyceal dilatation.

No calculi seen.

### LEFT KIDNEY:

Left kidney measures ~ 10.9 x 4.7 cms.

The shape, size and contour of the left kidney appear normal.

Cortico medullary differentiation is within normal. No evidence of pelvicalyceal dilatation.

No calculi seen.



# ABI SCANS & LABS

A unit of Aarthi Scans and Labs

Name	MRS.MEENA A	Patient ID	86475
Accession No	89986	Age/Gender	35Y / Female
Referred By	Dr.MEDIWHEEL	Date	27-Feb-2022

## USG REPORT - ABDOMEN AND PELVIS

### BLADDER:

Is normal contour. No intra luminal echoes are seen.

### UTERUS:

Measures ~ 9.1 x 4.2 x 5.5cms.

**Uterus appears bulky and heterogenous with multiple subcentimetric myometrial cysts and altered endo myometrial junction.**

Endometrium is regular and normal (8 mm).

Cervix appears normal.

### OVARIES:

Right ovary measures ~ 2.7 x 1.7 cms.


Left ovary measures ~ 2.4 x 1.3 cms.

No adnexal mass lesion seen. Pouch of Douglas is free. No free fluid in abdomen.

### IMPRESSION:

- ❖ Grade I fatty liver.
- ❖ Uterine adenomyosis.

- Suggested clinical correlation.

  
Dr. Abinaya Rajasekaran., MDRD.,  
Radiologist

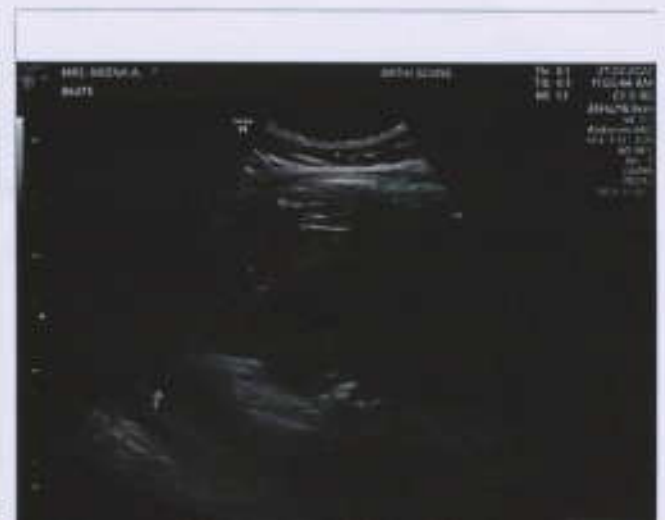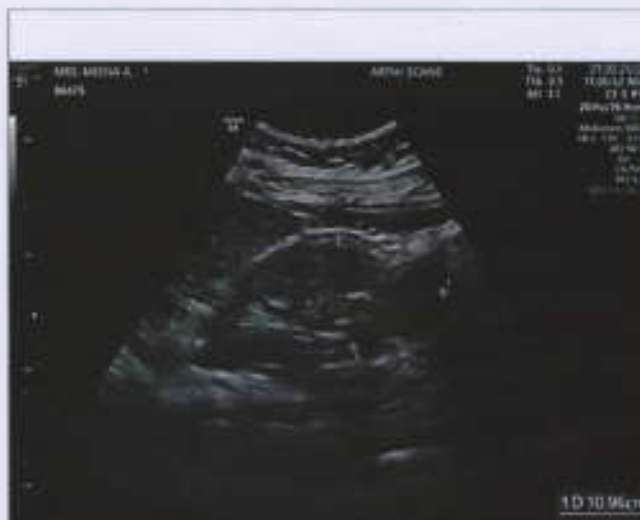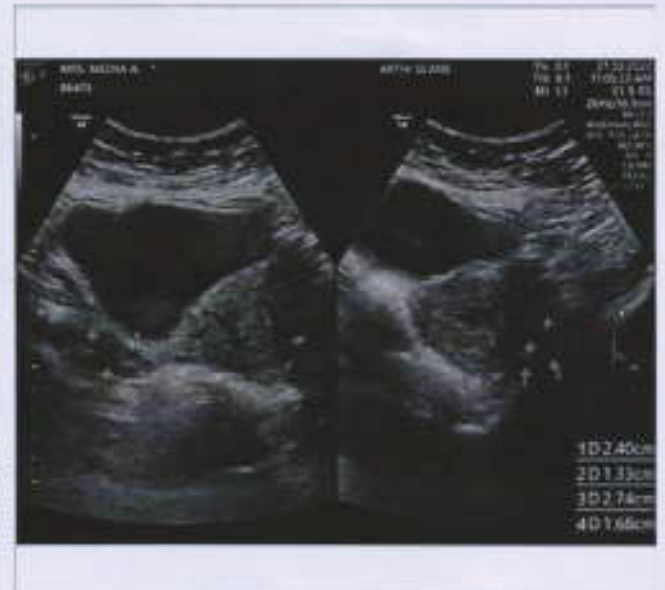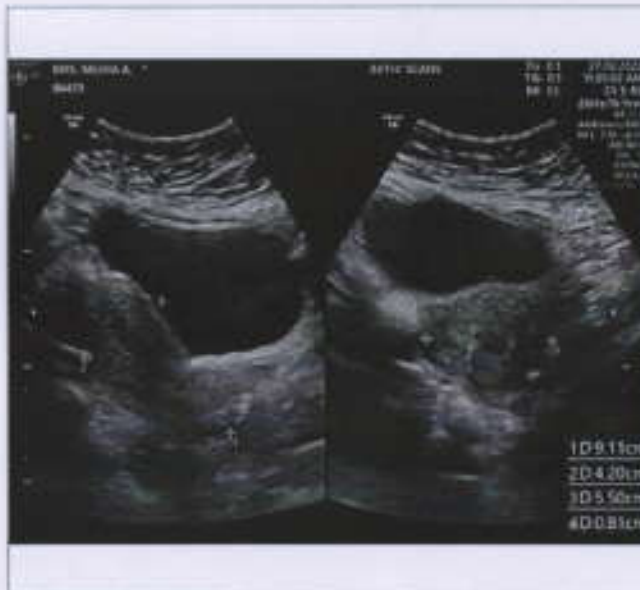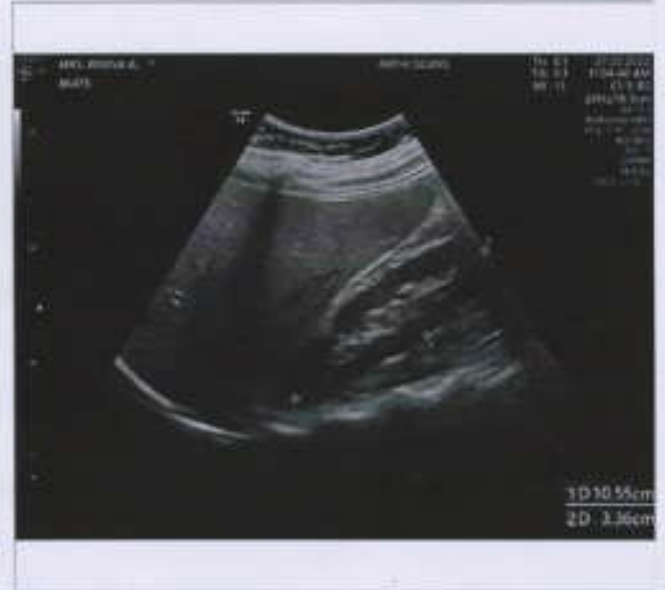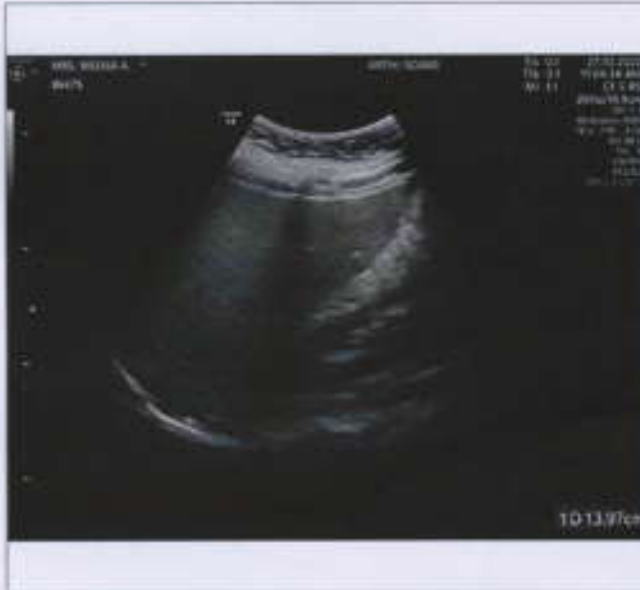Thank you for the courtesy of this referral

Foot Note: Patient's identity is not verified. Report is not valid for medico legal purpose.

Dr. Abinaya Rajasekaran, MD, RD.,  
Reg. No: 119538.

# ABI SCANS AND LABS

MRS. MEENA A /F 86475 27-Feb-2022 09:08:21 AM







# ABI SCANS & LABS

A unit of Aarthi Scans and Labs

Name	MRS.MEENA A	Patient ID	89986
Accession No	86475	Age/Gender	35Y / Female
Referred By	MEDIWHEEL	Date	27-Feb-2022

## X-RAY - CHEST PA VIEW

### OBSERVATION:

The trachea is central.

The mediastinal and cardiac silhouette are normal.

Cardiothoracic ratio is normal.

Cardiophrenic and costophrenic angles are normal.

Both hila are normal.

Lung zones are clear.

Bones of the thoracic cage are normal.

Soft tissues of the chest wall are normal.

### IMPRESSION:

- No significant abnormality seen.

Dr. Abinaya R MDRD.,  
Consultant Radiologist

MRS.MEENA A 35Y ...  
89986



27/02/2022  
09:19:50

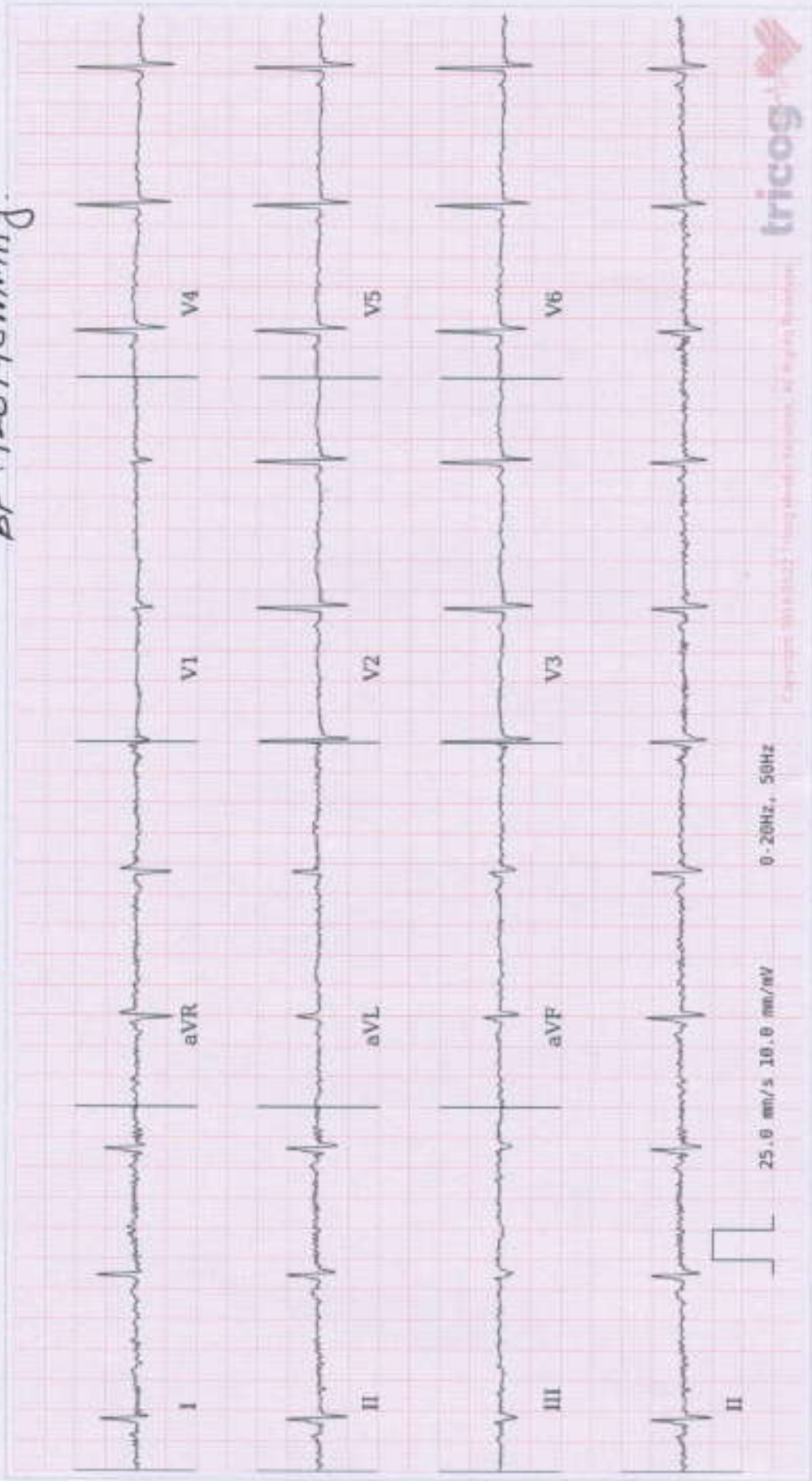


Aarthi CT and MRI Scans, R S Puram West

Age / Gender: 35/Female  
Patient ID: 0000086475  
Patient Name: MRS. MEENA A

Date and Time: 27th Feb 22 9:28 AM

BP: 120/90 mmHg.



AP: 67bpm Vb: 67bps QRSD: 70ms QT: 434ms QTc: 458ms PPI: 10Bms P-PR-T: 8° 1° -5°

Within Normal Limits: Sinus Rhythm, Normal Axis. Baseline artefacts. Please correlate clinically.





# ABI SCANS & LABS

A unit of Aarthi Scans and Labs

## VISION TEST

NAME	MRS. MEENA A	PATIENT ID	86475
ACCESSION NO	89986	AGE/GENDER	35Y/FEMALE
REFERRED BY	MEDIWHEEL	DATE	27.02.2022

### VISUAL ACUITY (VA)

#### WITH BEST CORRECTION

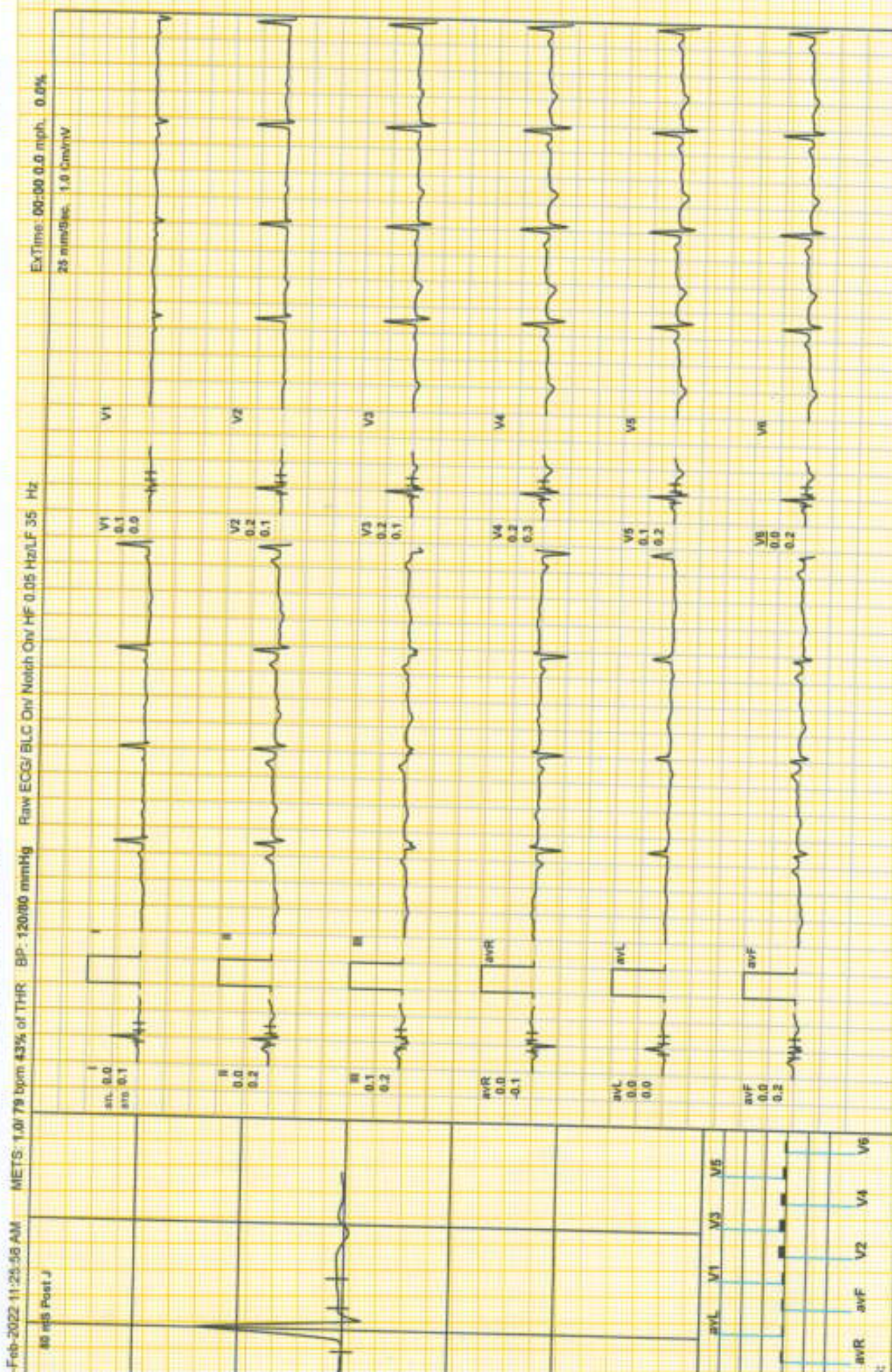
<b>DISTANCE VISION (With glasses)</b>	
Right	10/10
Left	10/10
Both	10/10
<b>NEAR VISION (With glasses)</b>	
Both	N6

<b>COLOUR VISION (With glasses)</b>	
BOTH	Normal

<b>DISTANCE VISION (Without glasses)</b>	
Right	9/10
Left	9/10
Both	9/10
<b>NEAR VISION (Without glasses)</b>	
Both	N6

<b>COLOUR VISION (Without glasses)</b>	
BOTH	Normal





Feb-2022 11:25:56 AM METS: 1.01 79 bpm 43% of THR BP: 120/80 mmHg Raw ECG/ BLC Div/ Notch On/ HF 0.05 Hz/ LF 35 Hz

80 mS Post J

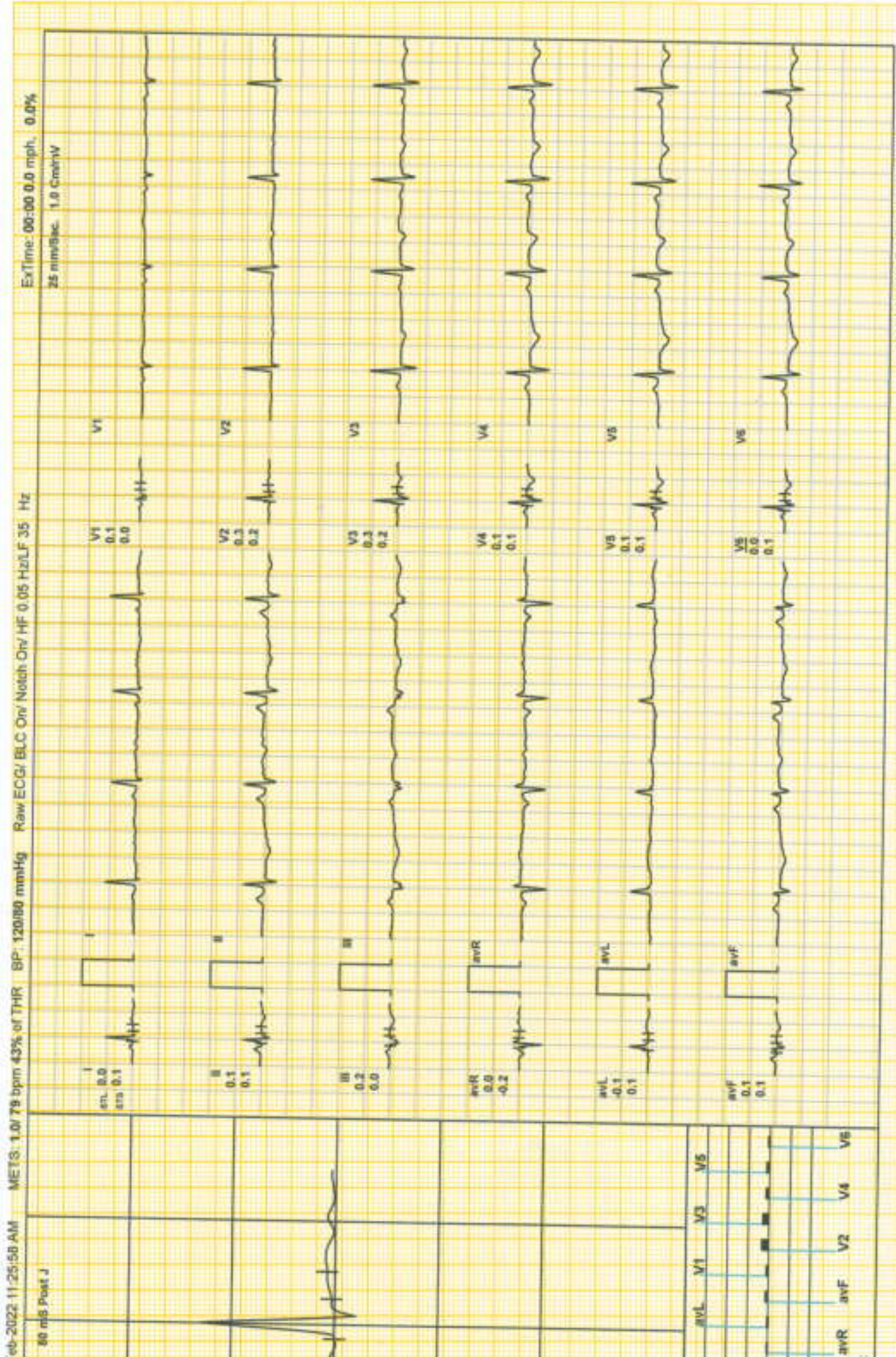
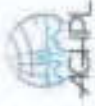Lead I: 0.0, 0.1, 0.5  
Lead II: 0.0, 0.2  
Lead III: 0.1, 0.2  
Lead aVR: 0.0, -0.1  
Lead aVL: 0.0, 0.0  
Lead aVF: 0.0, 0.2  
Lead V1: 0.1, 0.5  
Lead V2: 0.2, 0.1  
Lead V3: 0.2, 0.1  
Lead V4: 0.2, 0.3  
Lead V5: 0.1, 0.2  
Lead V6: 0.0, 0.2



SCANS & LABS

162) / MRS. MEENA A / 35 Yrs / F / 160 Cms / 72 Kg / HR : 79

HV ( 01:17 )

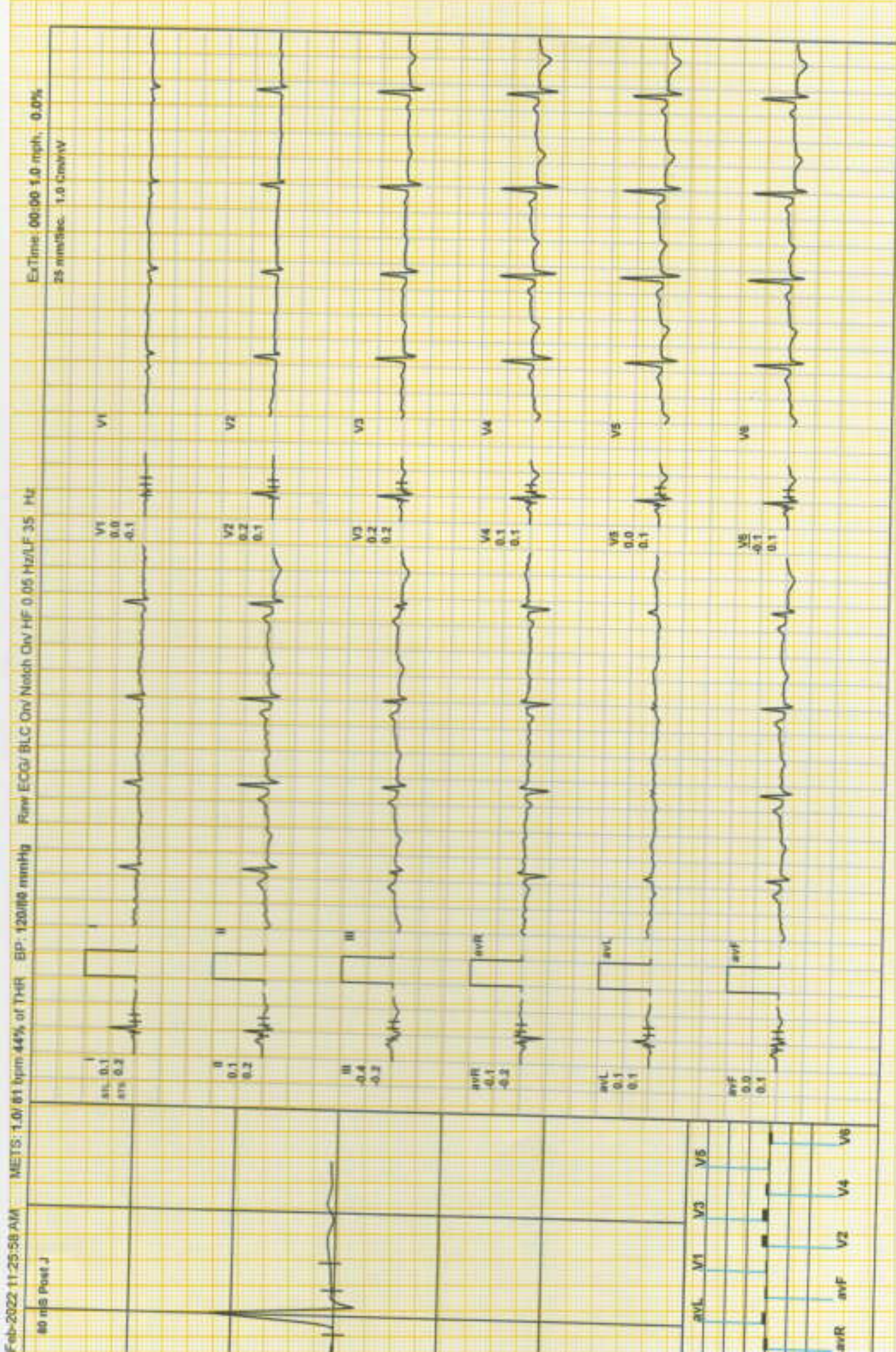
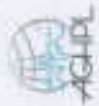



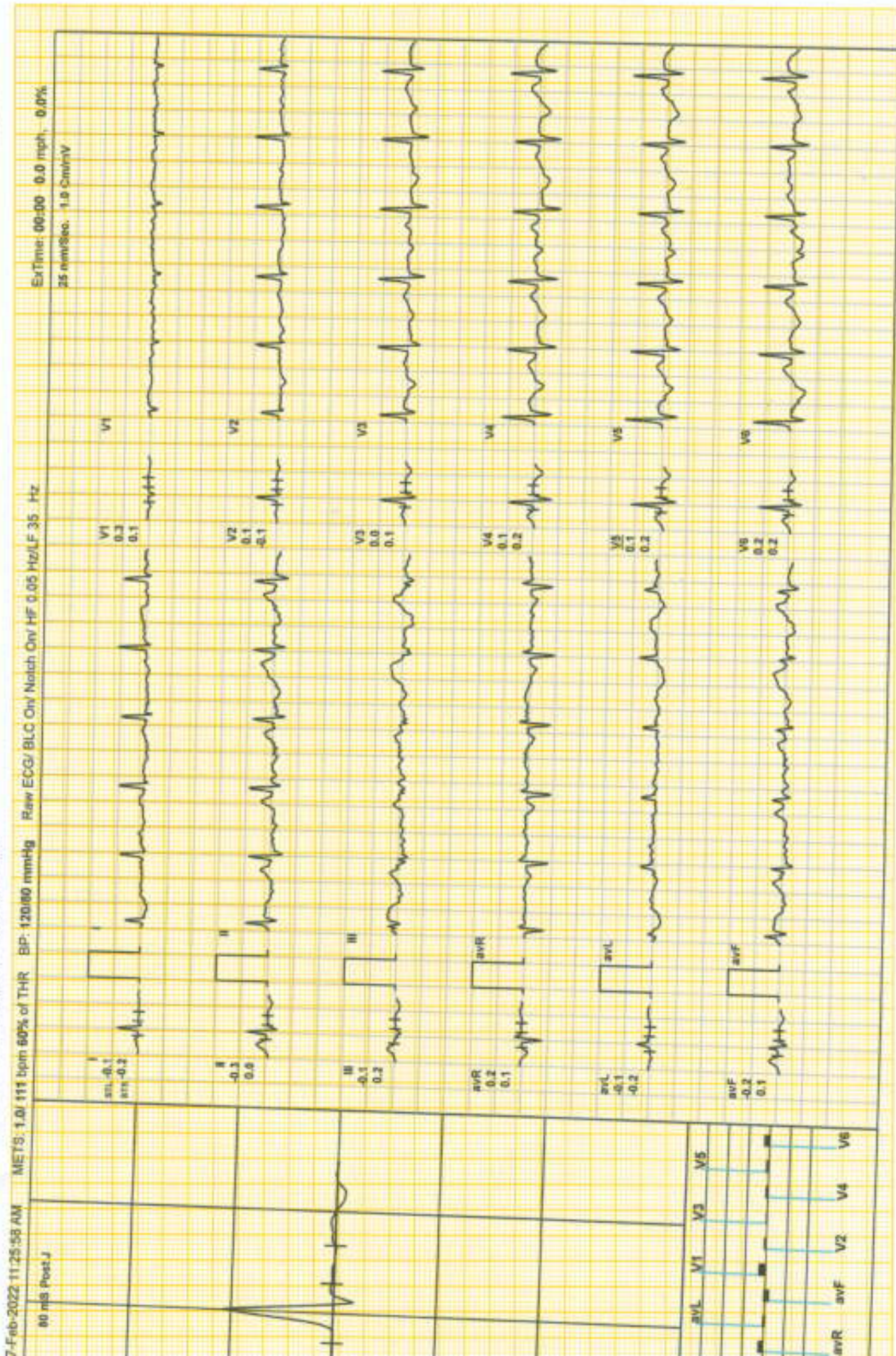
II SCANS & LABS

(162) / MRS. MEENA A / 35 Yrs / F / 160 Cms / 72 Kg / HR : 81

WARM UP ( 00:10 )





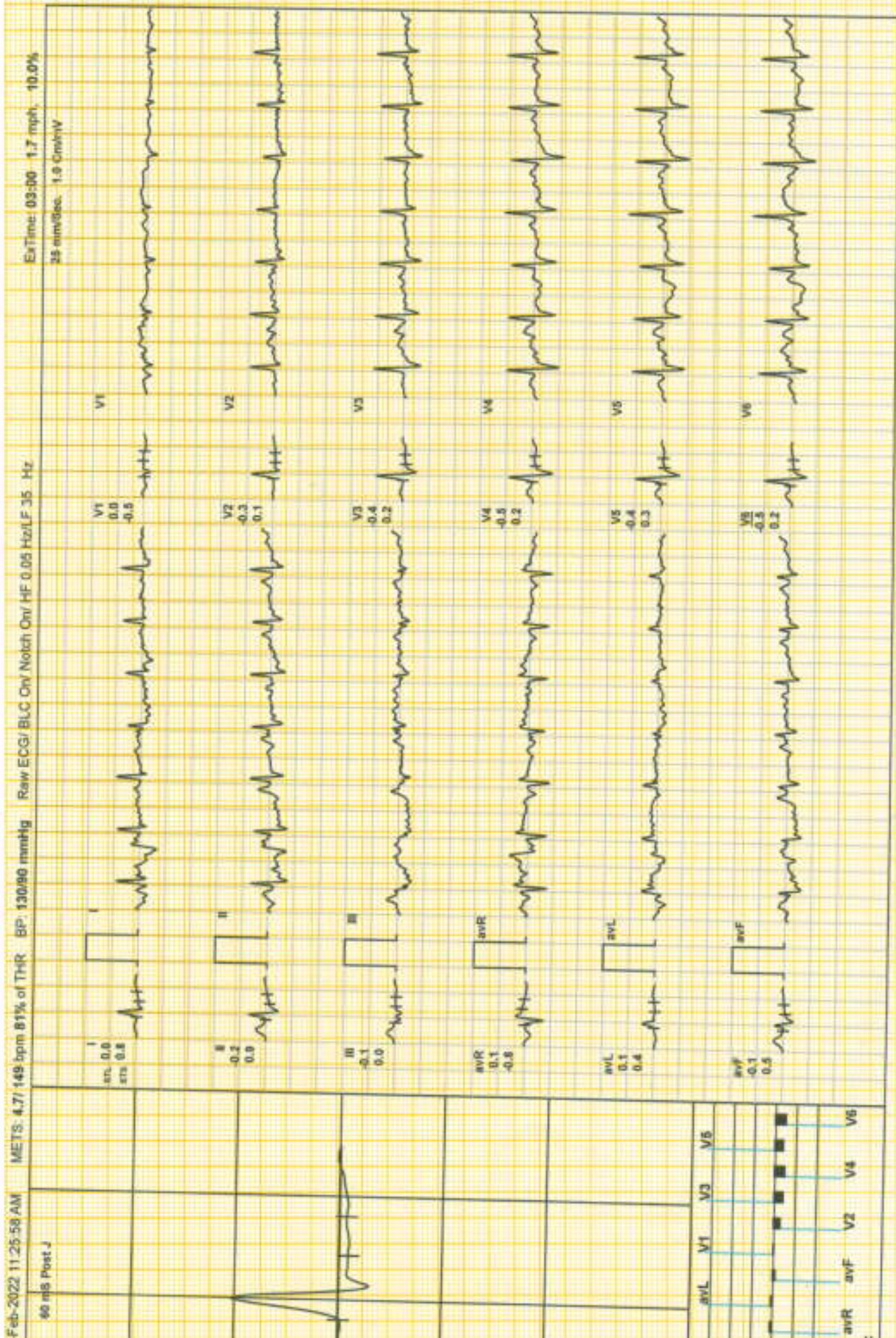




II SCANS & LABS

(162) / MRS. MEENA A / 35 Yrs / F / 160 Cms / 72 Kg / HR : 149

BRUCE : Stage 1 ( 03:00 )







BRUCE : Stage 2 ( 03:00 )

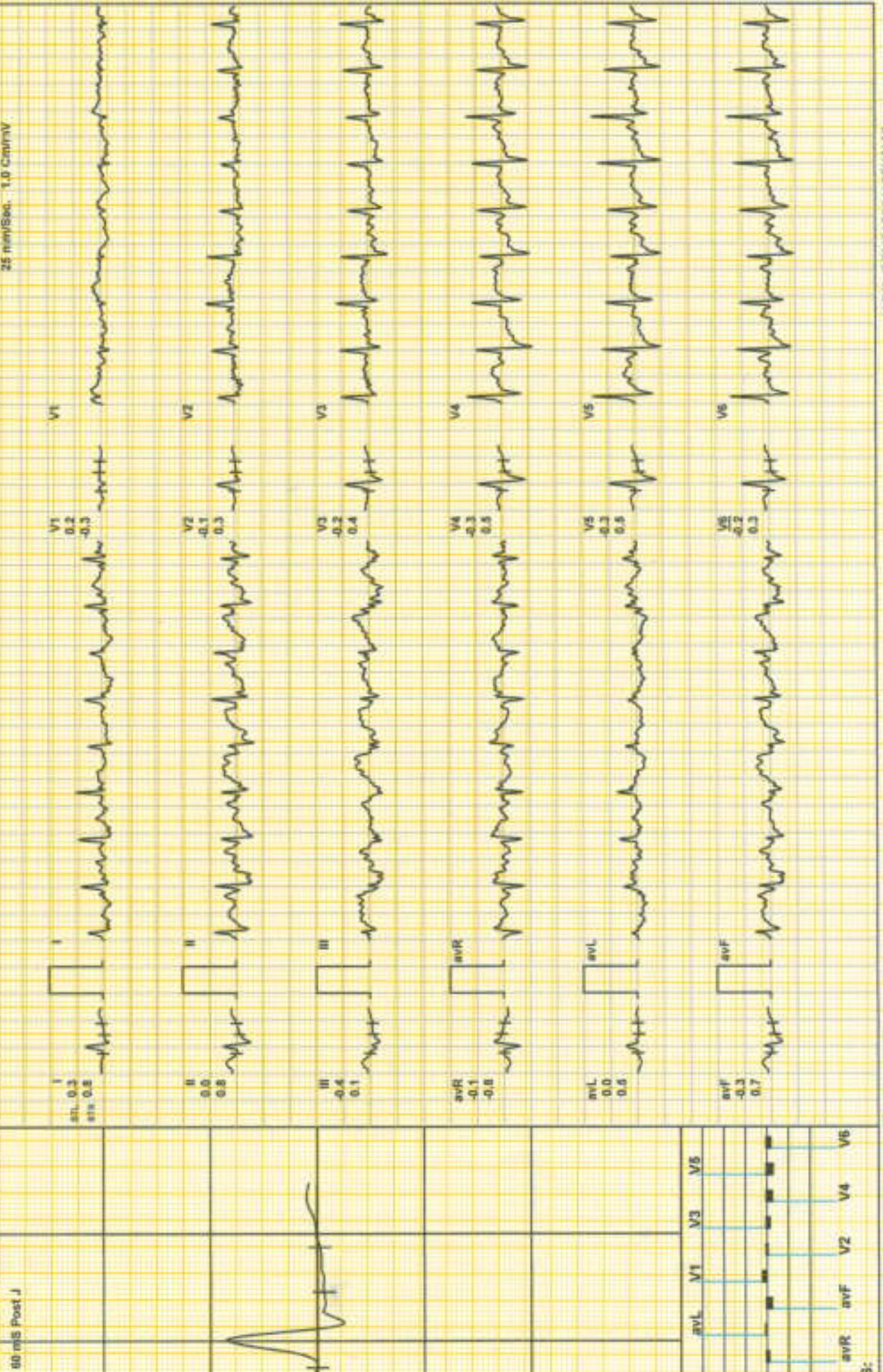
SCANS & LABS

52) / MRS. MEENA A / 35 Yrs / F / 160 Cms / 72 Kg / HR : 170

ExTime: 06:00 2.5 mph 12.0%

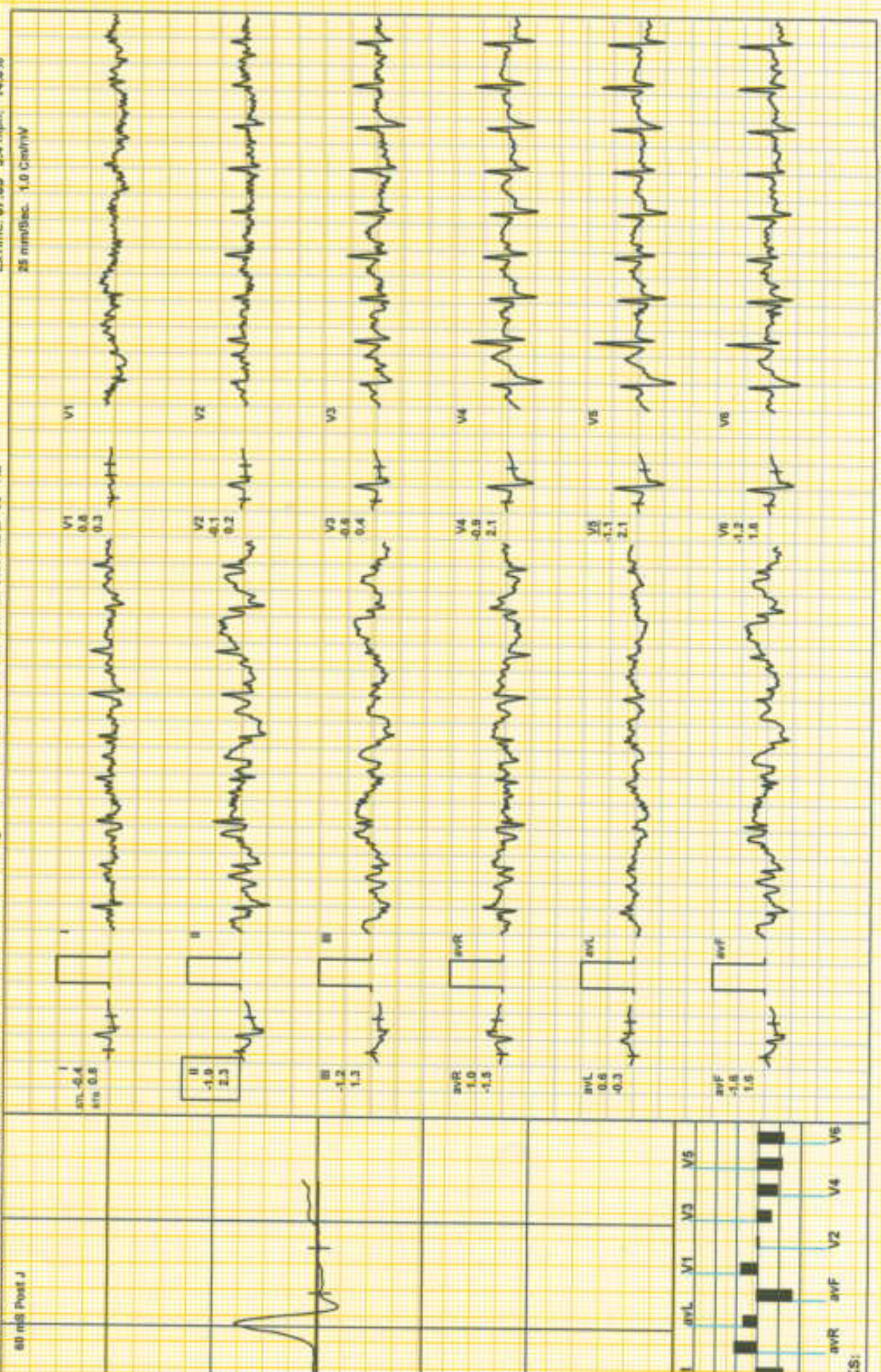
METS: 7.1/ 170 bpm 92% of THR BP 140/100 mmHg Raw ECG/ BLC On/ Notch On/ HF 0.05 Hz/LF 35 Hz

25 mm/Sec. 1.0 Cm/mV

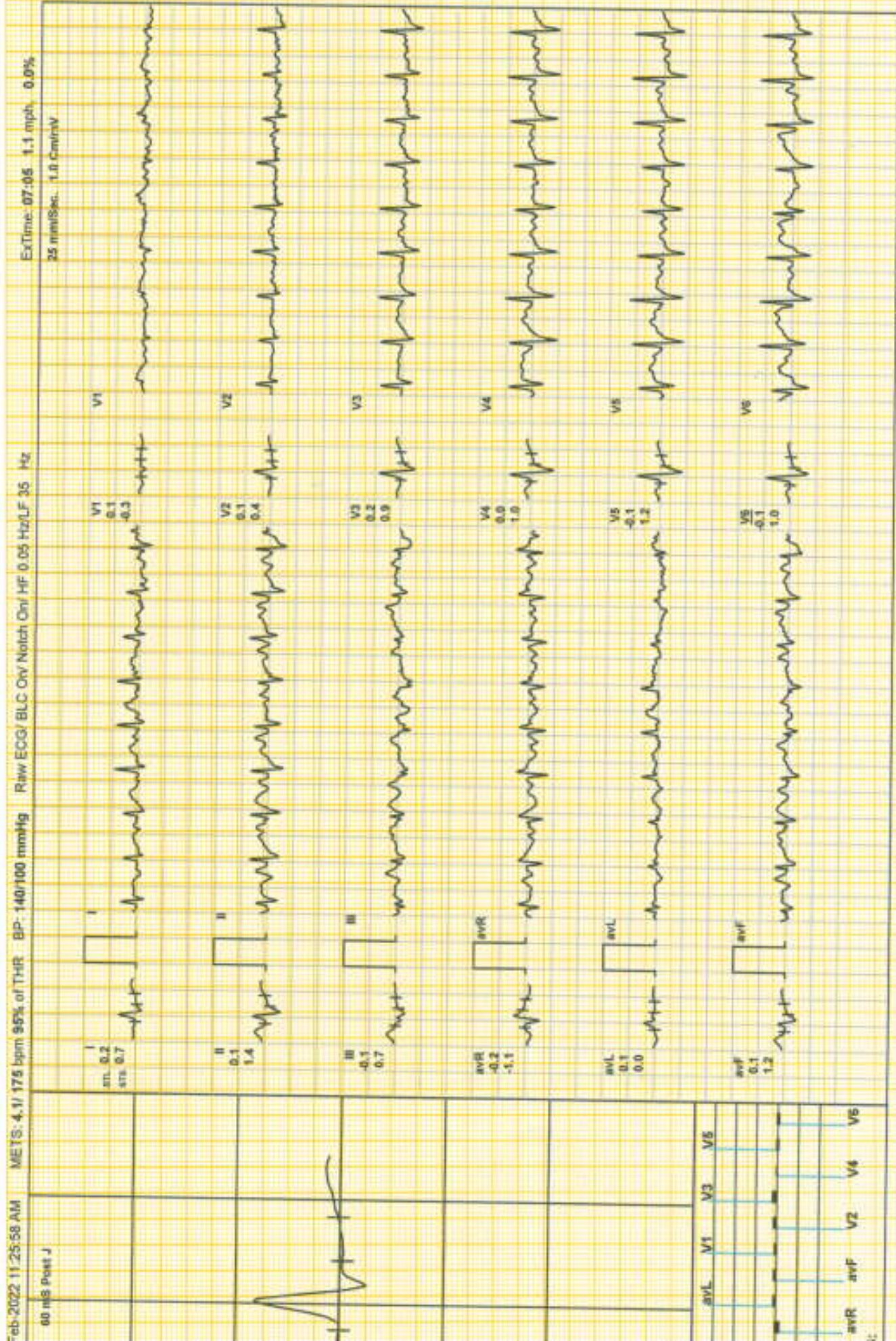
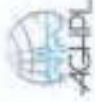



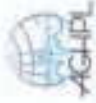Feb-2022 11:25:59 AM METS: 8.2/ 183 bpm 99% of THR BP: 140/100 mmHg Raw ECG/BLG On/ Notch On/ HF 0.05 Hz/F 35 Hz  
 25 mm/Sec. 1.0 Cm/mV  
 ExTime: 07:05 3.4 miph. 14.0%



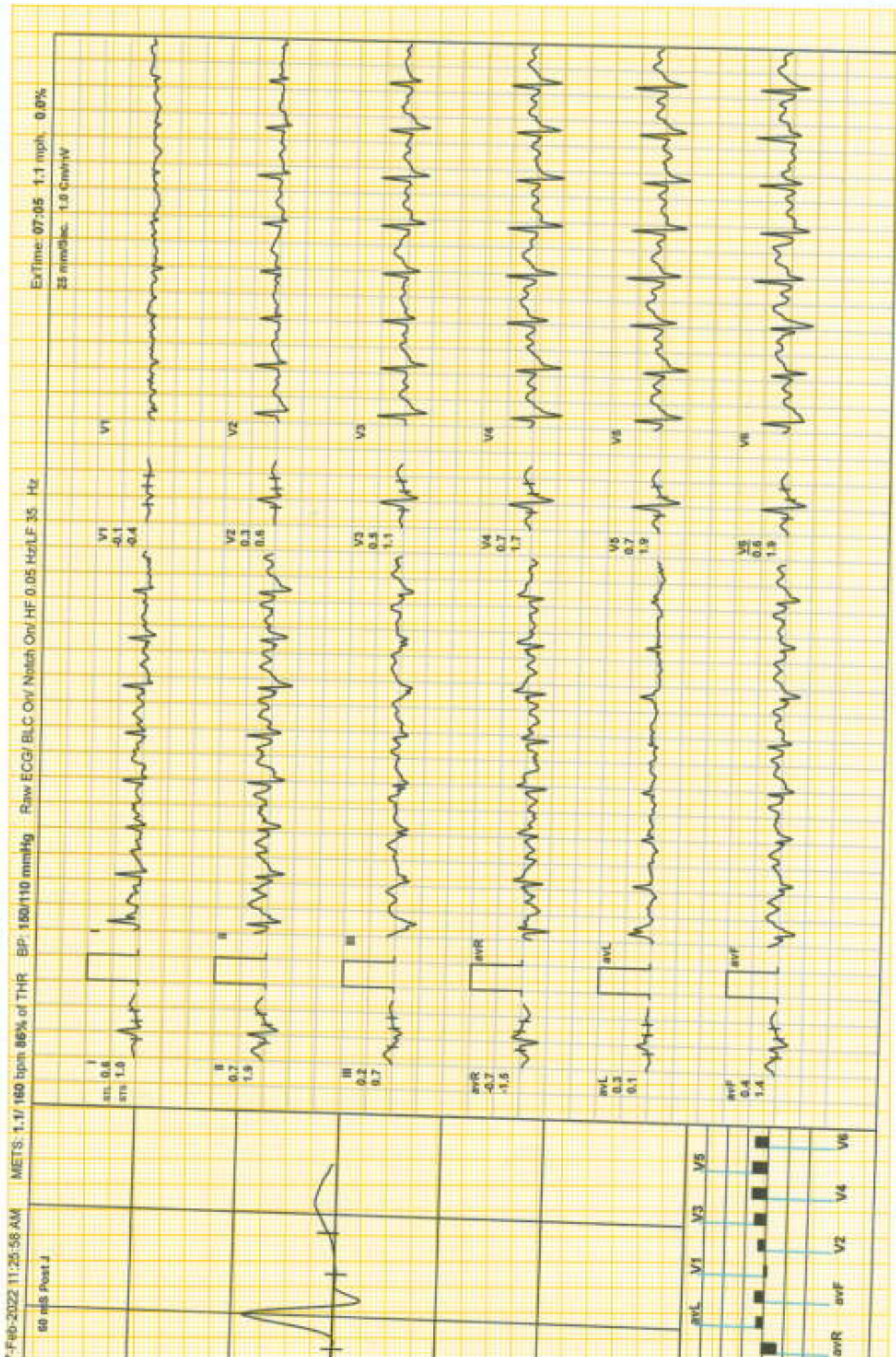




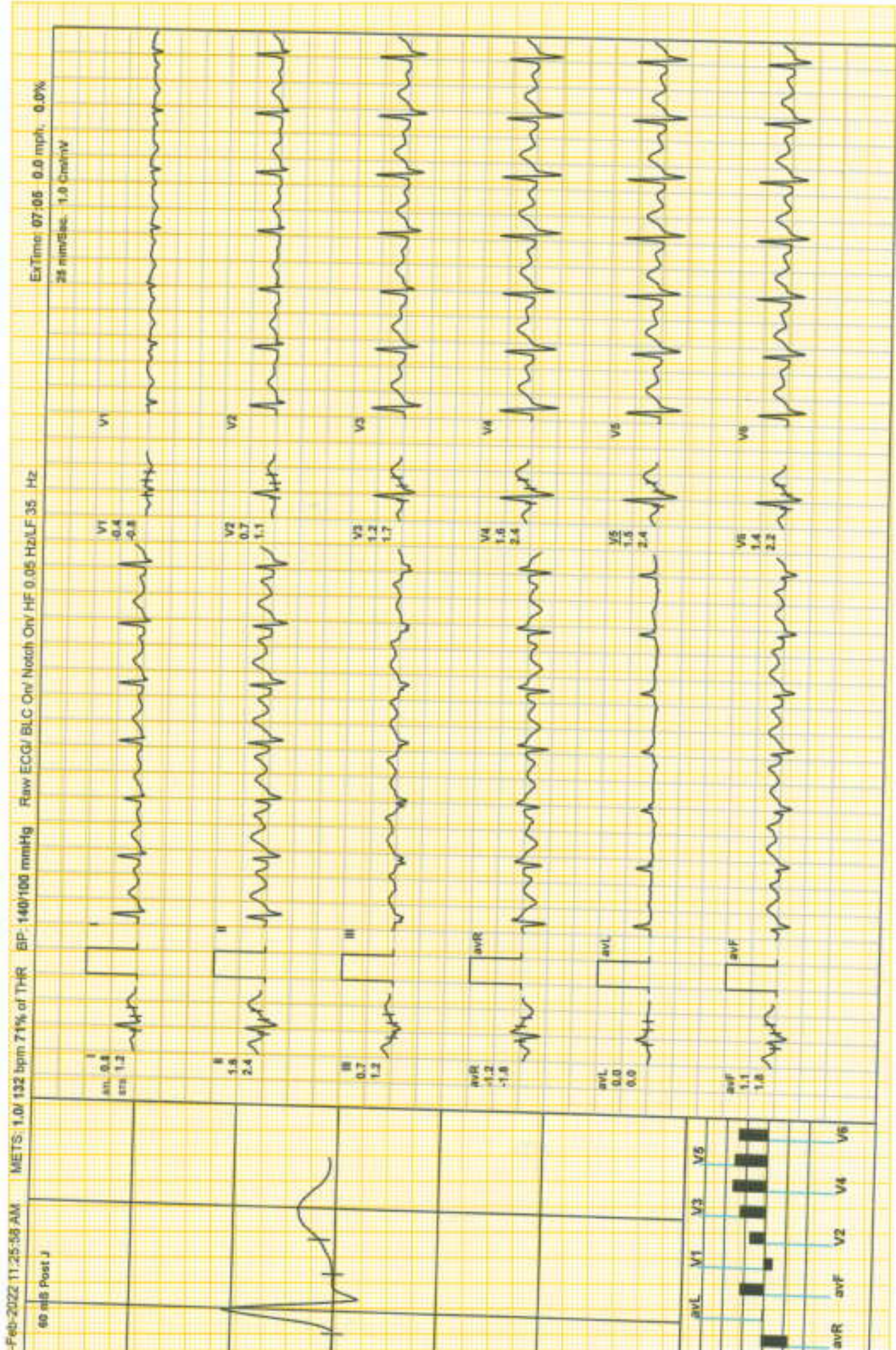
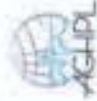



(162) / MRS. MEENA A / 35 Yrs / F / 160 Cms / 72 Kg / HR : 160





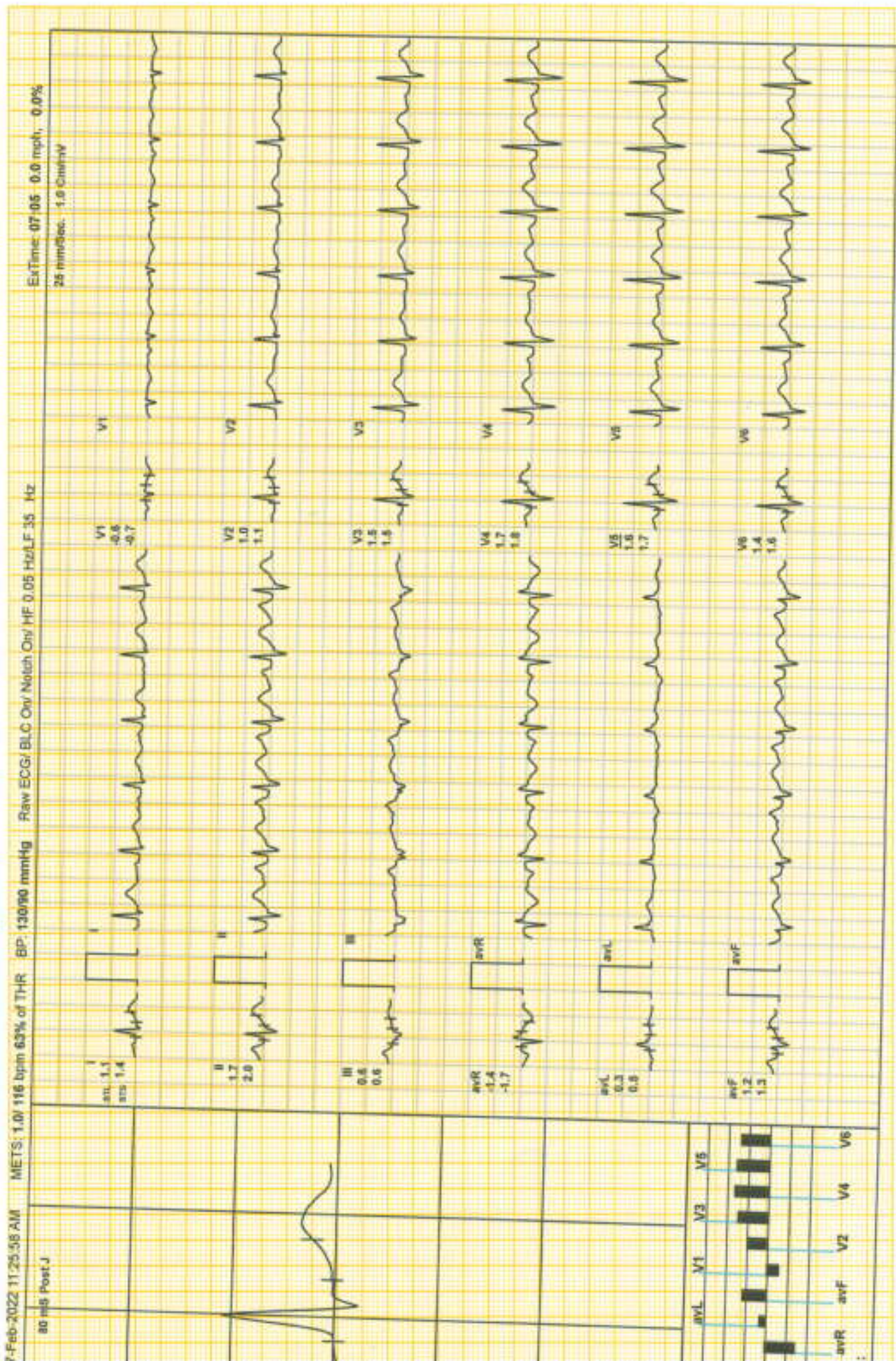
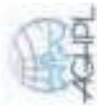



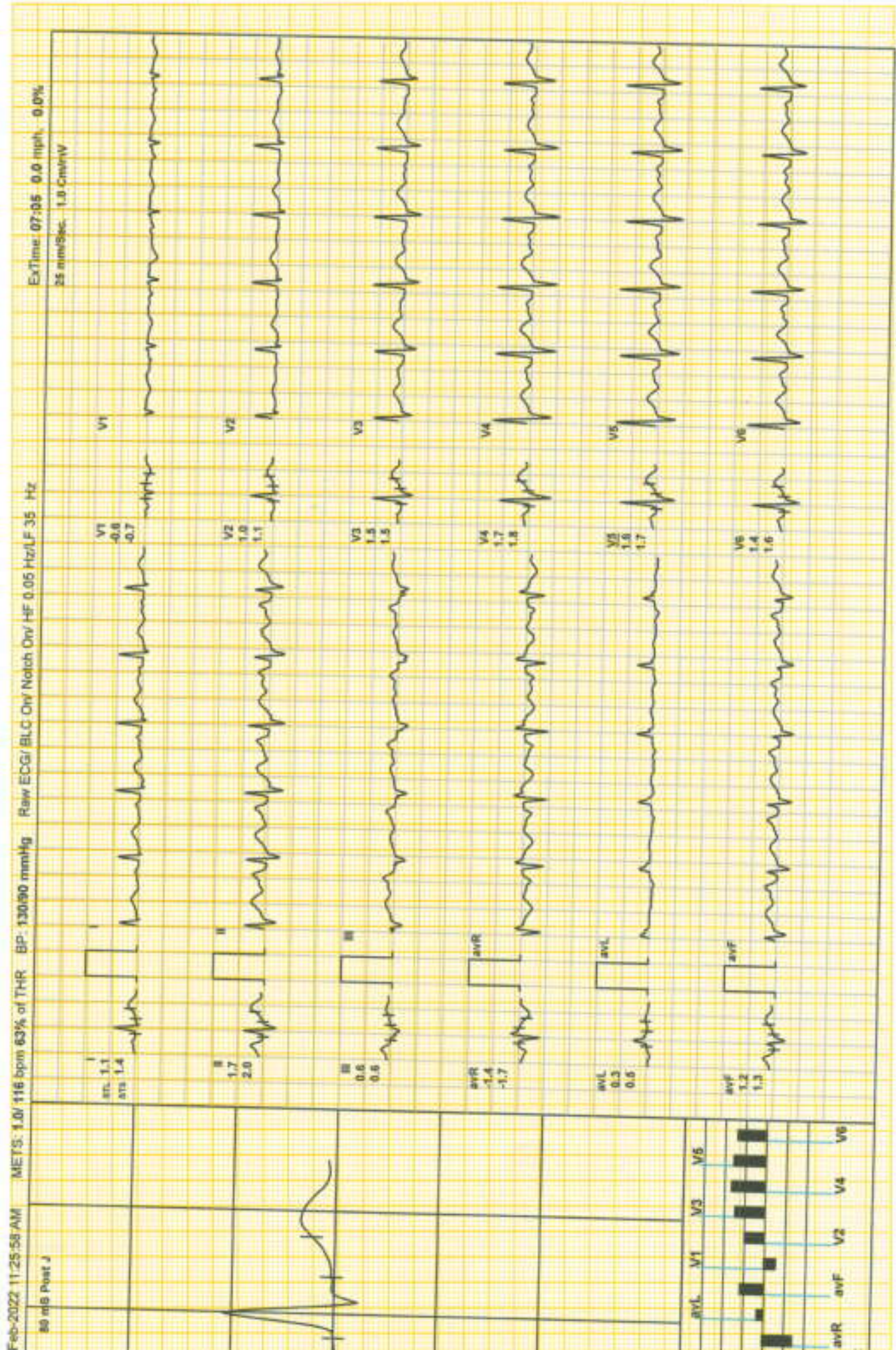
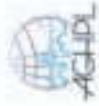HI SCANS & LABS

162 / MRS. MEENA A / 35 Yrs / F / 160 Cms / 72 Kg / HR : 116

Recovery : ( 03:00 )











162) / MRS. MEENA A / 35 Yrs / F / 160 Cms / 72 Kg Date: 27-Feb-2022 Refd By : SELF Examined By: ARTHI SCANS & LABS

Time	Duration	Speed(mph)	Elevation	METs	Rate	% THR	BP	RPP	PVC	Comments
00:10	0:10	00.0	00.0	01.0	079	43 %	120/80	094	00	
01:27	1:17	00.0	00.0	01.0	079	43 %	120/80	094	00	
01:37	0:10	00.0	00.0	01.0	081	44 %	120/80	097	00	
02:39	1:02	01.0	00.0	01.0	110	59 %	120/80	132	00	
05:39	3:00	01.7	10.0	04.7	149	81 %	130/90	193	00	
08:39	3:00	02.5	12.0	07.1	170	92 %	140/100	238	00	
09:44	1:05	03.4	14.0	08.2	183	99 %	140/100	256	00	
10:14	0:30	01.1	00.0	04.2	175	95 %	140/100	245	00	
10:44	1:00	01.1	00.0	01.2	160	86 %	150/110	240	00	
11:44	2:00	00.0	00.0	01.0	132	71 %	140/100	184	00	
12:44	3:00	00.0	00.0	01.0	116	63 %	130/90	150	00	
12:47	3:03	00.0	00.0	01.0	116	63 %	130/90	150	00	

GS :

- Exercise Time : 07:05
- Max HR Attained : 183 bpm 99% of Target 185
- Max BP Attained : 150/110
- Max WorkLoad Attained : 8.2 Fair response to induced stress
- Test Objective : NOW CHECKUP ONLY
- Test End Reasons : Patient Stopped Test





**REPORT :**

No Significant ST segment changes noted during exercise or recovery.

No angina /arrhythmia /S3/murmur.

Final Impression : Test Is Negative For Inducible Ischemia

**Dr. KARTHIK C.S.M.D.,PGD(CARDIOLOGY,UKR)**  
**CONSULTANT CARDIOLOGIST.**





இந்திய அரசாங்கம்  
Government of India

இந்திய தனித்துவ அடையாள ஆணையம்  
Unique Identification Authority of India

பதிவு அடையாளம் / Enrollment No. : 0648/05728/00005

To  
Meena  
பீனா  
CID: Aravind Kumar,  
Plot number 46 A 47 Meenuaravind Ilam,  
Airwin Garden,  
kadampadi,  
kadampadi,  
VTC: Kadampadi, PO: Kadampadi,  
Sub District: Sulur, District: Coimbatore,  
State: Tamil Nadu, PIN Code: 641401,  
Mobile: 9524488844

62496890



KF624568909F1



உங்கள் ஆதார் எண் / Your Aadhaar No. :

**2716 6323 7286**

எனது ஆதார். எனது அடையாளம்



இந்திய அரசாங்கம்  
Government of India



Issue Date: 06/07/2012



பீனா  
Meena  
பிள்ளை பெண் / DOB: 28/12/1988  
குடும்ப எண் / Family

**2716 6323 7286**

எனது ஆதார். எனது அடையாளம்


*Meena - 91*



मिलने पर निम्नलिखित को सूचित  
सहायक महाप्रबंधक (सुरक्षा)  
बैंक ऑफ बड़ोदा, बडोदा कॉर्पोरेट सेंटर  
सी-26, जी-ब्लॉक, बंदरा कुर्ता कॉम्प्लेक्स,  
मुंबई-400 051, भारत. - फोन: 91 22 6698 5196.

If found, please return to:  
Assistant General Manager (Security)  
Bank of Baroda, Baroda Corporate Centre  
C-26, G-Block, Bandra Kurla Complex  
Mumbai - 400 051, India. Phone: 91 22 6698 5196.

रक्त समूह / Blood Group : **O +ve**  
पहचान चिह्न / Identification Mark : **A mole in left leg small finger**

 बैंक ऑफ बड़ोदा  
Bank of Baroda

नाम : **मीना ए**  
Name : **MEENA A**

क.वू.सं.  
E.C. No. : **160186**

  
जारीकर्ता प्राधिकारी  
Issuing Authority



  
धारक के हस्ताक्षर  
Signature of Holder

