
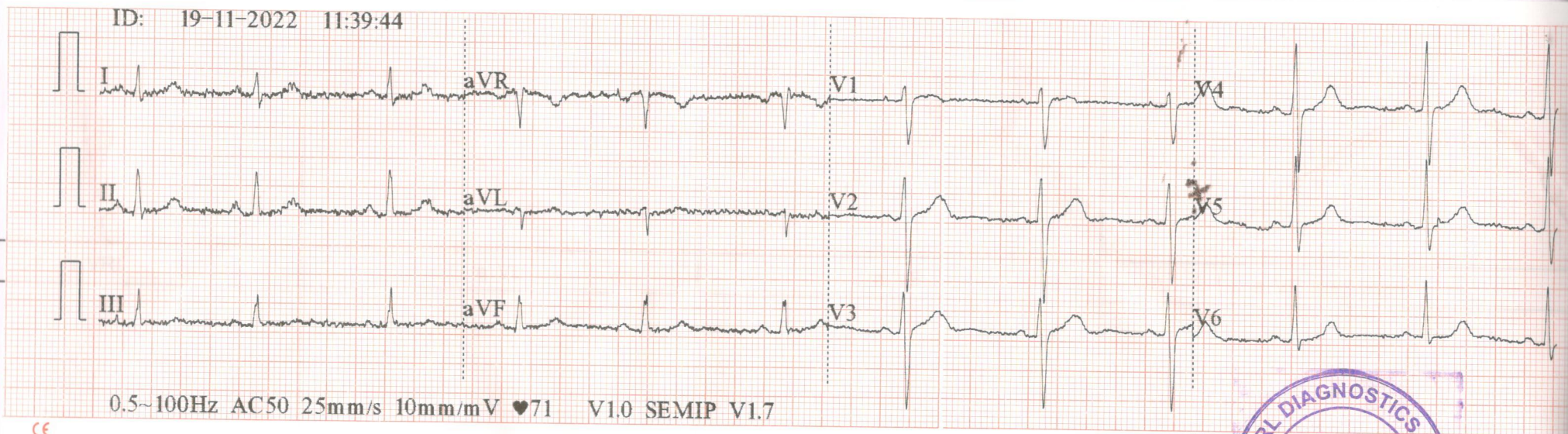


Standard	L I	L II	L III	L III Inspiration
----------	-----	------	-------	-------------------



L III

L III Inspiration

V1

V2


ID:
 SHILPA
 Female
 25Years
 cm
 mmHg
 kg

*Normal ECG
 Sinus rhythm*

HR : 67 bpm
 P : 108 ms
 PR : 156 ms
 QRS : 81 ms
 QT/QTc : 379/403 ms
 P/QRST : 50/70/51 °
 RV5/SV1 : 1.181/0.735 mV

ARROW CE

Dr. INDUSARATH.S, MBBS, MD, DM
 Regd. No: 41964
 DDRC SRL, KANNUR



V1

V4

V2

V5

V3

V6

V1.0 SEMIP V1.7



सत्यमेव जयते
भारत सरकार



आधार

भारत सरकार
Government of India

भारतीय विशिष्ट पहचान प्राधिकरण
Unique Identification Authority of India

Enrollment No. : 2003/39022/40753


To
SHILPA JAYAN

C/O Parth Madhu Nair,
Madathipadath House,
Kaniyarkode,
Thiruvilwamala,
VTC: Kaniyarkode, PO: Kaniyarkod,
Sub District: Talappilly, District: Thrissur,
State: Kerala, PIN Code: 680594,
Mobile: 7902377527

38916165



KF389161659FI



आपका आधार क्रमांक / Your Aadhaar No. :

6254 4720 8241

मेरा आधार, मेरी पहचान



भारत सरकार
Government of India



आधार


Issue Date: 25/12/2012



SHILPA JAYAN
DOB: 13/03/1997
Female

6254 4720 8241

मेरा आधार. मेरी पहचान



Shilpa
7902377527



CLIENT CODE : CA00010147
CLIENT'S NAME AND ADDRESS :
MEDIWHEEL ARCOFEMI HEALTHCARE LIMITED
F701A, LADO SARAI, NEW DELHI,
SOUTH DELHI, DELHI,
SOUTH DELHI 110030
DELHI INDIA
8800465156

DDRC SRL DIAGNOSTICS
KANNUR
KERALA, INDIA
Tel : 93334 93334
Email : customercare.ddrc@srl.in

PATIENT NAME : SHILPA JAYAN

PATIENT ID : **SHILF1911974053**

ACCESSION NO : **4053VK001844** AGE : 25 Years SEX : Female

DRAWN : RECEIVED : 19/11/2022 10:06 REPORTED : 20/11/2022 20:45

REFERRING DOCTOR : SELF

CLIENT PATIENT ID :

Test Report Status	Results	Biological Reference Interval	Units
--------------------	---------	-------------------------------	-------

MEDIWHEEL HEALTH CHECKUP BELOW 40(F)TMT

TREADMILL TEST

TREADMILL TEST COMPLETED

OPHTHAL

OPHTHAL COMPLETED

PHYSICAL EXAMINATION

PHYSICAL EXAMINATION COMPLETED



Scan to View Details



Scan to View Report



CLIENT CODE : CA00010147
CLIENT'S NAME AND ADDRESS :
 MEDIWHEEL ARCOFEMI HEALTHCARE LIMITED
 F701A, LADO SARAI, NEW DELHI,
 SOUTH DELHI, DELHI,
 SOUTH DELHI 110030
 DELHI INDIA
 8800465156

DDRC SRL DIAGNOSTICS
 KANNUR
 KERALA, INDIA
 Tel : 93334 93334
 Email : customercare.ddrc@srl.in

PATIENT NAME : SHILPA JAYAN

 PATIENT ID : **SHILF1911974053**

 ACCESSION NO : **4053VK001844** AGE : 25 Years SEX : Female

DRAWN : RECEIVED : 19/11/2022 10:06 REPORTED : 20/11/2022 20:45

REFERRING DOCTOR : SELF

CLIENT PATIENT ID :

Test Report Status	Results	Units
NON HDL CHOLESTEROL	93	Desirable-Less than 130 Above Desirable-130-159 Borderline High-160-189 High-190-219 Very High- >or =220 mg/dL
CHOL/HDL RATIO	3.0	Low 3.3 - 4.4 Low Risk 4.5 - 7.0 Average Risk 7.1 - 11.0 Moderate Risk > 11.0 High Risk
LDL/HDL RATIO	1.8	0.5-3 Desirable/Low risk 3.1-6 Borderline/Moderate risk >6.0 High Risk
VERY LOW DENSITY LIPOPROTEIN	12.5	</= 30 mg/dL
LIVER FUNCTION TEST WITH GGT		
BILIRUBIN, TOTAL	0.60	General Range : < 1.1 mg/dL
BILIRUBIN, DIRECT	0.17	General Range : < 0.2 mg/dL
BILIRUBIN, INDIRECT	0.43	0.00 - 0.60 mg/dL
TOTAL PROTEIN	7.5	Ambulatory : 6.4 - 8.3 Recumbant : 6 - 7.8 g/dL
ALBUMIN	4.2	20-60yrs : 3.5 - 5.2 g/dL
GLOBULIN	3.3	2.0 - 4.0 g/dL
ALBUMIN/GLOBULIN RATIO	1.3	1.0 - 2.0 RATIO
ASPARTATE AMINOTRANSFERASE (AST/SGOT)	11	Adults : < 33 U/L
ALANINE AMINOTRANSFERASE (ALT/SGPT)	9	Adults : < 34 U/L
ALKALINE PHOSPHATASE	51	Adult(<60yrs) : 35 - 105 U/L
GAMMA GLUTAMYL TRANSFERASE (GGT)	14	Adult(female) : < 40 U/L
TOTAL PROTEIN, SERUM		
TOTAL PROTEIN	7.5	Ambulatory : 6.4 - 8.3 Recumbant : 6 - 7.8 g/dL
URIC ACID, SERUM		
URIC ACID	5.8	Adults : 2.4-5.7 mg/dL
ABO GROUP & RH TYPE, EDTA WHOLE BLOOD		
ABO GROUP	TYPE A	
RH TYPE	POSITIVE	
BLOOD COUNTS		
HEMOGLOBIN	12.6	12.0 - 15.0 g/dL
RED BLOOD CELL COUNT	4.22	3.8 - 4.8 mil/ μ L
WHITE BLOOD CELL COUNT	9.02	4.0 - 10.0 thou/ μ L





INDIA'S LEADING DIAGNOSTICS NET WORK

CLIENT CODE : CA00010147
CLIENT'S NAME AND ADDRESS :
MEDIWHEEL ARCOFEMI HEALTHCARE LIMITED
F701A, LADO SARAI, NEW DELHI,
SOUTH DELHI, DELHI,
SOUTH DELHI 110030
DELHI INDIA
8800465156DDRC SRL DIAGNOSTICS
KANNUR
KERALA, INDIA
Tel : 93334 93334
Email : customercare.ddrc@srl.in**PATIENT NAME : SHILPA JAYAN**PATIENT ID : **SHILF1911974053**ACCESSION NO : **4053VK001844** AGE : 25 Years SEX : Female

DRAWN : RECEIVED : 19/11/2022 10:06 REPORTED : 20/11/2022 20:45

REFERRING DOCTOR : SELF

CLIENT PATIENT ID :

Test Report Status	Results	Units
--------------------	---------	-------

2. Gowenlock A.H. Varley's Practical Clinical Biochemistry, 6th Edition.

3. Behrman R.E. Kilegman R.M., Jenson H. B. Nelson Text Book of Pediatrics, 17th Edition

MICROSCOPIC EXAMINATION, URINE-

Routine urine analysis assists in screening and diagnosis of various metabolic, urological, kidney and liver disorders

Protein: Elevated proteins can be an early sign of kidney disease. Urinary protein excretion can also be temporarily elevated by strenuous exercise, orthostatic proteinuria, dehydration, urinary tract infections and acute illness with fever

Glucose: Uncontrolled diabetes mellitus can lead to presence of glucose in urine. Other causes include pregnancy, hormonal disturbances, liver disease and certain medications.

Ketones: Uncontrolled diabetes mellitus can lead to presence of ketones in urine. Ketones can also be seen in starvation, frequent vomiting, pregnancy and strenuous exercise.

Blood: Occult blood can occur in urine as intact erythrocytes or haemoglobin, which can occur in various urological, nephrological and bleeding disorders.

Leukocytes: An increase in leukocytes is an indication of inflammation in urinary tract or kidneys. Most common cause is bacterial urinary tract infection.

Nitrite: Many bacteria give positive results when their number is high. Nitrite concentration during infection increases with length of time the urine specimen is retained in bladder prior to collection.

pH: The kidneys play an important role in maintaining acid base balance of the body. Conditions of the body producing acidosis/ alkalosis or ingestion of certain type of food can affect the pH of urine.

Specific gravity: Specific gravity gives an indication of how concentrated the urine is. Increased specific gravity is seen in conditions like dehydration, glycosuria and proteinuria while decreased specific gravity is seen in excessive fluid intake, renal failure and diabetes insipidus.

Bilirubin: In certain liver diseases such as biliary obstruction or hepatitis, bilirubin gets excreted in urine.

Urobilinogen: Positive results are seen in liver diseases like hepatitis and cirrhosis and in cases of hemolytic anemia





CLIENT CODE : CA00010147
CLIENT'S NAME AND ADDRESS :
MEDIWHEEL ARCOFEMI HEALTHCARE LIMITED
F701A, LADO SARAI, NEW DELHI,
SOUTH DELHI, DELHI,
SOUTH DELHI 110030
DELHI INDIA
8800465156

DDRC SRL DIAGNOSTICS
KANNUR
KERALA, INDIA
Tel : 93334 93334
Email : customercare.ddrc@srl.in

PATIENT NAME : SHILPA JAYAN

PATIENT ID : SHILF1911974053

ACCESSION NO : 4053VK001844 **AGE :** 25 Years **SEX :** Female

DRAWN : **RECEIVED :** 19/11/2022 10:06 **REPORTED :** 20/11/2022 20:45

REFERRING DOCTOR : SELF

CLIENT PATIENT ID :

Test Report Status	Results	Units
--------------------	---------	-------

MEDIWHEEL HEALTH CHECKUP BELOW 40(F)TMT

ECG WITH REPORT

REPORT

COMPLETED

USG ABDOMEN AND PELVIS

REPORT

COMPLETED

CHEST X-RAY WITH REPORT

REPORT

COMPLETED

****End Of Report****

Please visit www.srlworld.com for related Test Information for this accession

JINSHA KRISHNAN
LAB TECHNICIAN

DR.INDUSARATH S
CONSULTANT PATHOLOGIST

NIMISHA K
LAB TECHNICIAN

SREENA A
LAB TECHNICIAN



Scan to View Details



Scan to View Report



OPHTHALMOLOGY REPORT

TO WHOM-SO-EVER IT MAY CONCERN

This is to certify that I have examined Miss. SHILPA JAYAN, 25 years Female on 19.11.2022 and her visual standards are as follows:

	OD	OS
UNCORRECTED DISTANCE VISUAL ACUITY	6/6(-1)	6/6(P)
UNCORRECTED NEAR VISUAL ACUITY	N6	N6
BEST CORRECTED VISUAL ACUITY	6/6	6/6
COLOUR VISION	NORMAL	NORMAL

NOTE: HISTORY OF SPECS, PG NOT USING PROPERLY (PG NOT BROUGHT)
NO RELEVANT MEDICAL HISTORY

VIMEGA .V
OPTOMETRIST




DATE: 19.11.2022

Respected Sir / Madam


This is for your kind information that
one of our client (Medhuel) - Mrs. SHILPA JAYANT
cannot perform TMT. Because she was pregnant.

NIMISHA

Kcho, TMT, Pehusian.



19/11/22.





Name	Mrs. SHILPA JAYAN	Age/Sex	25/Female
Ref: By:	MEDIWHEEL	Date	19.11.2022

ULTRASOUND SCAN OF ABDOMEN AND PELVIS

(With relevant image copies)

LIVER: Normal in size and echotexture. No e/o focal parenchymal lesions / IHBD. PV, HV & IVC are within normal limits.

GB: Normally distended, shows normal wall thickness. No e/o calculi/polyps/ pericholecystic collections.

CBD: Normal.

PANCREAS: Head and body visualized and are of normal size and echotexture. No e/o focal/diffuse parenchymal lesions/ductal dilatation/calculi. Tail cannot be visualized due to poor window.

SPLEEN: Normal in size and echotexture. Splenic vein shows normal diameter.

KIDNEY'S: Both kidneys are normal in size and echotexture. No e/o calculi/ hydronephrosis/ focal lesions/ perinephric collections.

RIGHT KIDNEY: Measures 105 x 38 mms

LEFT KIDNEY: Measures 111 x 43 mms

UB: Moderately distended, shows normal wall thickness. No e/o calculi/growth/diverticulae. Both UV junctions are within normal limits.

UTERUS: Gravid and shows a single intrauterine gestational sac corresponding to 5 weeks (GS: 15.5mm).

Fetal pole not seen

Yolk sac seen.

No subchorionic hemorrhage seen.

RIGHT OVARY: appears normal

LEFT OVARY: appears normal.

No e/o intraperitoneal free fluid/ abdominal lymphadenopathy/ mass lesion.

IMPRESSION

- SINGLE INTRAUTERINE GESTATION CORRESPONDING TO 5 WEEKS IN MATURITY.
- NO SONOLOGICALLY DETECTED ABNORMALITY IN THE ABDOMEN.

Dr. P. NIYAZI NASIR
MBBS, DMRD

(Because of technical and technological limitation complete diagnosis cannot be assured on imaging sonography. Clinical correlation, consultation if required repeat imaging required in the event of controversies. This document is not for legal purposes).

Dr. P. NIYAZI NASIR, MBBS, DMRD
 REG. No. 41419
 CONSULTANT RADIOLOGIST
 DDRC SRL DIAGNOSTIC (P) LTD.
 KANNUR

R

SHILPA JAYAN 25Y/F MEDIWHEEL VK001844 CHEST ,P-A 19-Nov-22 11:16 AM

DDRC SRL KANNUR



Name	SHILPA JAYAN	Age/Sex	25/Female
Ref: By:	MEDIWEEL	Date	19.11.2022

Thanks for referral

CHEST X-RAY – PA VIEW

Trachea is central. Carina and principal bronchi are normal.

Cardio-thoracic ratio is within normal limits.

Both lungs show normal Broncho-vascular markings. No definite focal opacities noted.

No volume loss in either hemithorax.

No definite mediastinal widening or other abnormalities noted.

CP angles, diaphragm, bony cage and soft tissue shadows - not remarkable.

IMPRESSION:

- Normal X-ray chest

**DR. P. NIYAZI NASIR,
MBBS, DMRD**

(Because of technical and technological limitation complete diagnosis cannot be assured on imaging sonography. Clinical correlation, consultation if required repeat imaging required in the event of controversies. This document is not for legal purposes).

Dr. P. NIYAZI NASIR, MBBS, DMRD
 REG. No. 41419
CONSULTANT RADIOLOGIST
 DDRC SRL DIAGNOSTIC (P) LTD.
 KANNUR