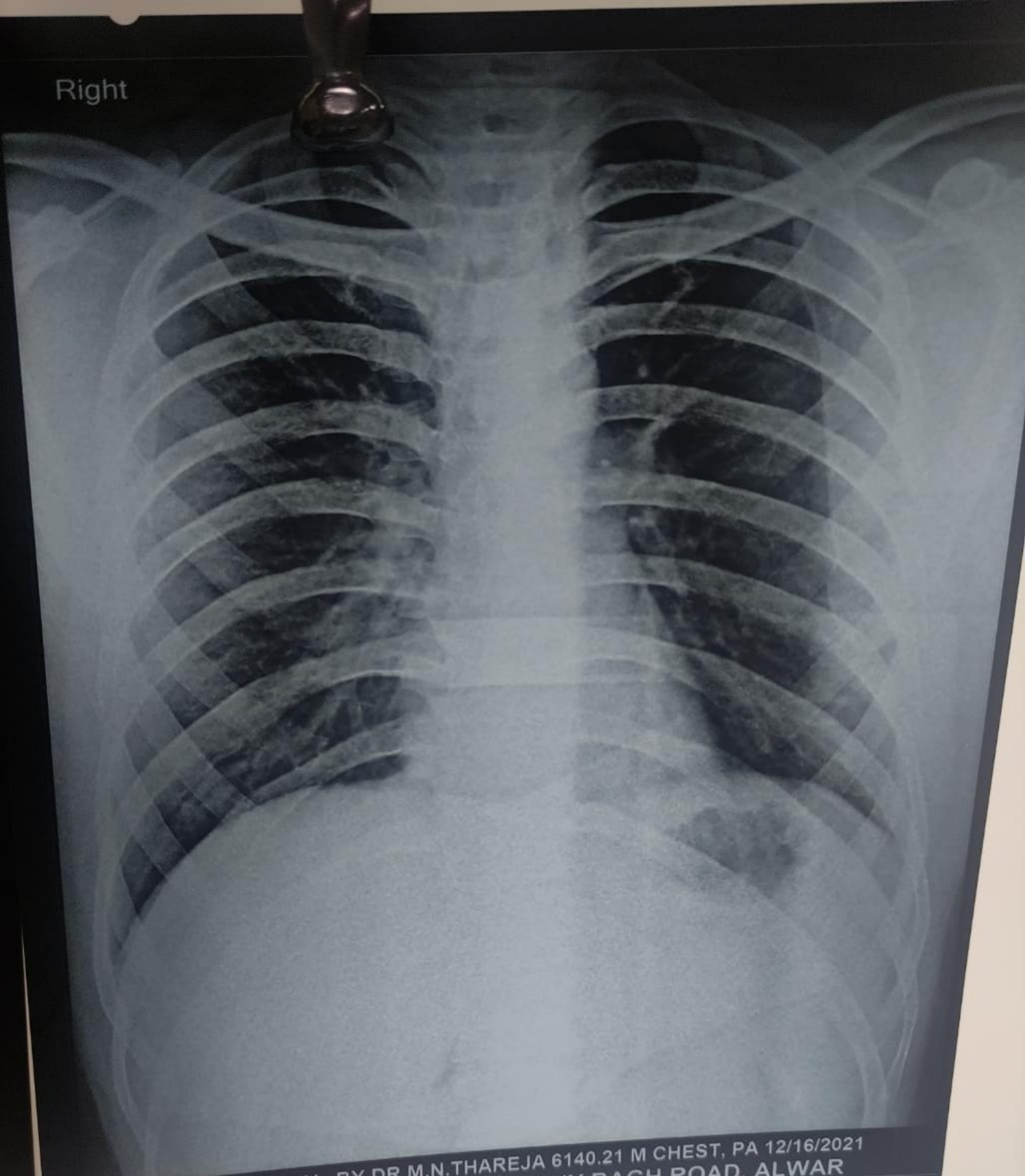


Right



HEMANT VERMA 29 Y BY DR M.N.THAREJA 6140.21 M CHEST, PA 12/16/2021
THAREJA NURSING HOME. COMPANY BAGH ROAD, ALWAR



THAREJA NURSING HOME



DIGITAL X-RAY, OPG, COMPUTERISED ECG & EEG, DIAGNOSTIC
LABORATORY EQUIPED WITH COMPUTERISED AUTO ANALYZER & CBC

1, Ram Kuteer, Company Bagh Road, ALWAR - 301001 (Raj.) Ph: 0144-2700184, 2331842

PROPOSAL NO. PKG10000227

Date 16/12/2021

Patient Name HEMANT VERMA

Age 29 Yrs.

Ref. By Dr. M. N. THAREJA

Sex M

PART - X-RAYED : X-RAY CHEST PA VIEW
REPORT : X-RAY CHEST P.A. VIEW
:- Chest is bilaterally symmetrical.
:- C.P. Angles are clear.

CONCLUSION: Normal Study

Signature of Technician


Signature of Doctor



THAREJA NURSING HOME

1, Ram Kuteer Company Bagh Road, ALWAR - 301001 (Raj.)
Mob. 9982111801, Ph. 0144-2700184, 2331842, Telefax: 0144-2342339
E-mail: drmnthareja@yahoo.com



Name Hemant Verma Age 29 Yr OPD/UHID 27007 Date 16/12/21

Address Mobile No. 7597361299

VITALS

B.P.

Pulse

Temp.

Wt.

Ht.

Allergies

Complaints

Routine Dental checkup

Findings

Patient maintains his dental hygiene

Investigation

Brushes twice daily

Treatment

Dr. Jayant Thareja
M.D.S.
Oral & Maxillofacial Surgery
Ex-Resident (AIIMS, TRAUMA CENTRE,
0144-2342339)

Dr. Jayant

DR. M.N. THAREJA

7233 (RMC)
Male Infertility Specialist

DR. SAVITA THAREJA

7600 (RMC)
Female Infertility Specialist

DR. JAYANT THAREJA

A-0824 (RSDC)
M.D.S.
Oral & Maxillo - Facial Surgery
Ex Resident Trauma Centre,
AIIMS, Delhi

DR. SHIVANI THAREJA

10807 / 31220 (RMC)
Ophthalmologist
Cornea Specialist

DR. PRERNA THAREJA

A-3574
MDS (Endodontics)
Root Canal Specialist
Ex Resident
AIIMS, Jodhpur

DR. H.R. GUPTA

1744 (RMC)
Senior Consultant
M.S. Gen Surgeon

DR. VARUN SAPRA

Reg. No. 70990 (DMC)
MBBS DNB ORTHO, D.ORTHO
Joint Replacement &
Arthroscopy Surgeon

Pain
Scale

0



No Pain

2



Mild Pain

4



Distressing

6



Disressing

8



Intense

10



Excruciating



THAREJA NURSING HOME

1, Ram Kuteer Company Bagh Road, ALWAR - 301001 (Raj.)
Mob. 9982111801, Ph. 0144-2700184, 2331842, Telefax: 0144-2342339
E-mail: drmnthareja@yahoo.com



Name Mr. Virena Hemant Age 29 Yr OPD/UHID..... Date 16/12/21
Address..... Mobile No.....

VITALS	B.P.	Pulse	Temp.	Wt.	Ht.	Allergies
--------	------	-------	-------	-----	-----	-----------

Complaints

*Routine eye checkup
operated R/E corneal tear repair (R/E)
Findings (20/20) for traumatic corneal tear R/E*

*VA - 6/6P
- 6/6P = glasses
- N6, N6
Investigation*



*R/E Corneal mark
Pupil*

*Color vision - WNL
- WNL*

Treatment

Adv

① Continue glasses

Shivani

- DR. M.N. THAREJA**
7233 (RMC)
Male Infertility Specialist
- DR. SAVITA THAREJA**
7600 (RMC)
Female Infertility Specialist
- DR. JAYANT THAREJA**
A-0824 (RSDC)
M.D.S.
Oral & Maxillo - Facial Surgery
Ex Resident Trauma Centre,
AIIMS, Delhi
- DR. SHIVANI THAREJA**
10807 / 31220 (RMC)
Ophthalmologist
Cornea Specialist
- DR. PRERNA THAREJA**
A-3574
MDS (Endodontics)
Root Canal Specialist
Ex Resident
AIIMS, Jodhpur
- DR. H.R. GUPTA**
1744 (RMC)
Senior Consultant
M.S. Gen Surgeon
- DR. VARUN SAPRA**
Reg. No. 70990 (DMC)
MBBS DNB ORTHO, D.ORTHO
Joint Replacement &
Arthroscopy Surgeon

Dr. Shivani Thareja
M.S. (OPHTHAL)
Fellow (CORNEA)
L.V. Prasad Eye Institute
CORNEA CONSULTANT


Pain Scale

0	2	4	6	8	10
No Pain	Mild Pain	Distressing	Disressing	Intense	Excruciating



Hemant

Dr. M. N. THAREJA
M.B.B.S
Thareja Nursing Home
Alwar-301001, (Raj.)





THAREJA NURSING HOME



DIGITAL X-RAY, OPG, COMPUTERISED ECG & EEG, DIAGNOSTIC
LABORATORY EQUIPED WITH COMPUTERISED AUTO ANALYZER & CBC

1, Ram Kuteer, Company Bagh Road, ALWAR - 301001 (Raj.) Ph: 0144-2700184, 2331842

PROPOSAL NO. PKG10000227

Patient Name MR HEMANT VERMA

Ref. By Dr. M. N. THAREJA

Date 16/12/2021

Age 29 Yrs.

Sex M

Details of packages		Patients report	Units	Normal value
HB		13.9	gm%	M-13.5-18, F-11.5-16.5
TRBC		4.82	million /cu mm	M-4.0-5.5, F-3.9-5.6
TWBC		8700	cu mm	4000-11000
DLC	Polymorphs	70	%	42-75
	Lymphocytes	28	%	20-50
	Eosinophil	02	%	1-6
ESR		03	mm 1 st Hr.	M-0-9, F-0-20
Platelets		232000	Lack / cu mm	1.5-4
PCV		39.6	%	37-54
MCV		82.2	Cubicmicrons	86-98
MCH		28.8	Picograms	26-34
MCHC		35.1	%	32-36
Blood Grouping & Rh Factor		AB-VE(NEGATIVE)		
BUN		13.0	mg %	M-7-20
S. Creatinine		0.85	Mg/100ml	0.9-1.4 mg /100 ml
HBsAg		-		
HIV I & II		-	Elisa Method	
HbA1C		5.0	%	4-6%
VDRL		-		

Details of packages		Patients report	Units	Normal value
LFT	GGT	23	U/L	5-60
	SGOT	16	Units / ml	Upto 40
S. Bilirubin	SGPT	21	Units / ml	Upto 40
	Total Bilirubin	0.5	mg%	Upto 1.2
	Direct Bilirubin	0.3	mg%	0-0.25
	Indirect Bilirubin	0.2	mg%	
	T. Protein	7.8	Gm%	6.2-8.3
	S. Albumin	4.6	Gm%	3.2-5.3
	Globulin	3.2	Gm%	
	Alkaline phosphate	108	IU/L	60 - 170
	S. Calcium	-	Gm%	8.5-10.5
	Uric Acid	4.1	Mg%	2.5-7 mg%
Blood Sugar Fasting		76	Mg%	60-110 mg %
Blood Sugar PP		110	Mg%	Upto 160
Lipid Profile	S. Cholesterol	210	mg%	120-220
	S. Triglycerides	130	mg/ml	Upto 170
	HDL Cholesterol	60	IU/L	
	LDL cholesterol	124	IU/L	450 at 37° C
	VLDL	26	mg %	Upto 35

Routine Urine Analysis

Physical/ Chemical		Microscopic:	
Appearance	Clear	RBCs	Nil
Specific Gravity	1010	WBCs	1-2/ HPF
Ph	ACIDIC	Epith. Cells	1-2/HPF
Albumin	Nil	Casts	Nil
Glucose F	NIL	Crystals	Nil
Ketones	-----	Bacteria	Nil
Blood	Nil	Glucose P.P.	NIL

Signature of Technician

Signature of Doctor

This Report is not Valid for Medical Legal Purpose

Patient Name:

Hemant V Sharma

Age: 39, M / F
..... cm / kg
..... / mmHg

16/12/21

HR 65/min

Intervals:
RR 903 ms
P 116 ms
PR 132 ms
QRS 96 ms
QT 358 ms
QTc 377 ms

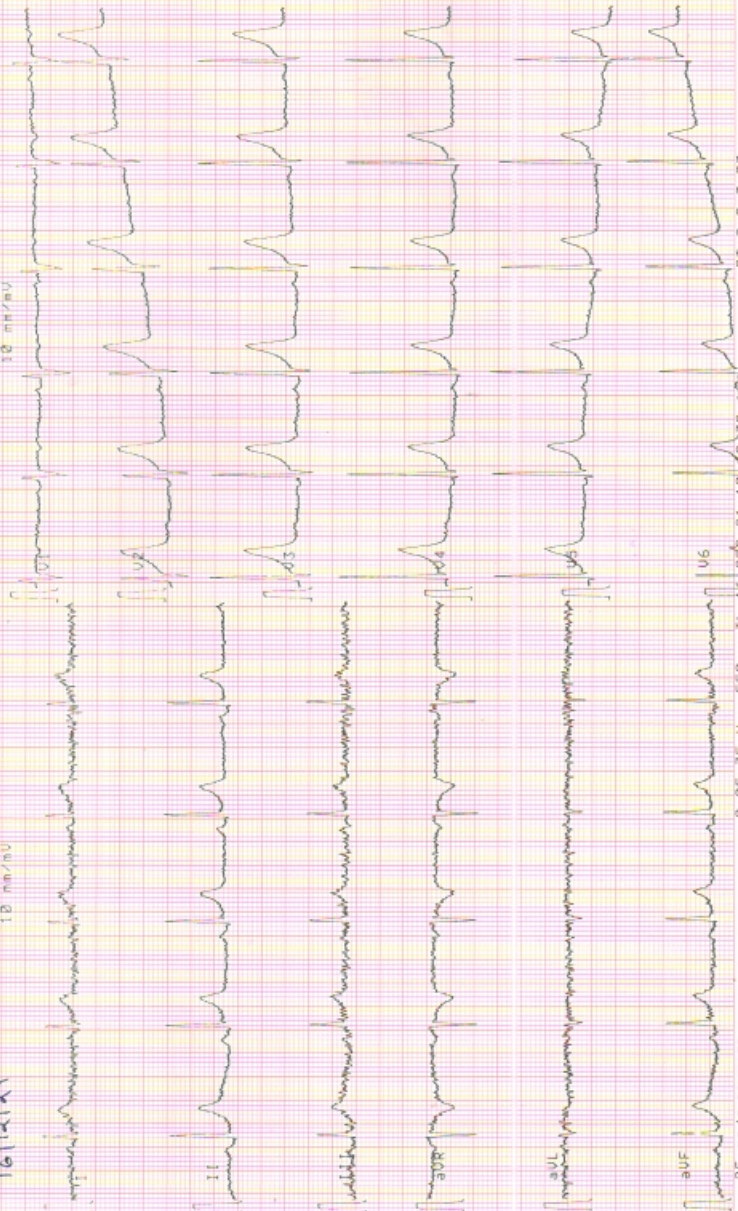
10 mm/mV

SINUS RHYTHM

UNCONFIRMED REPORT

Dr. M. N. THAREJA,
MBBS
Tharela Nursing Home
Alwar-301001, (Raj.)

[Handwritten signature]



25 mm/s SCHILLER

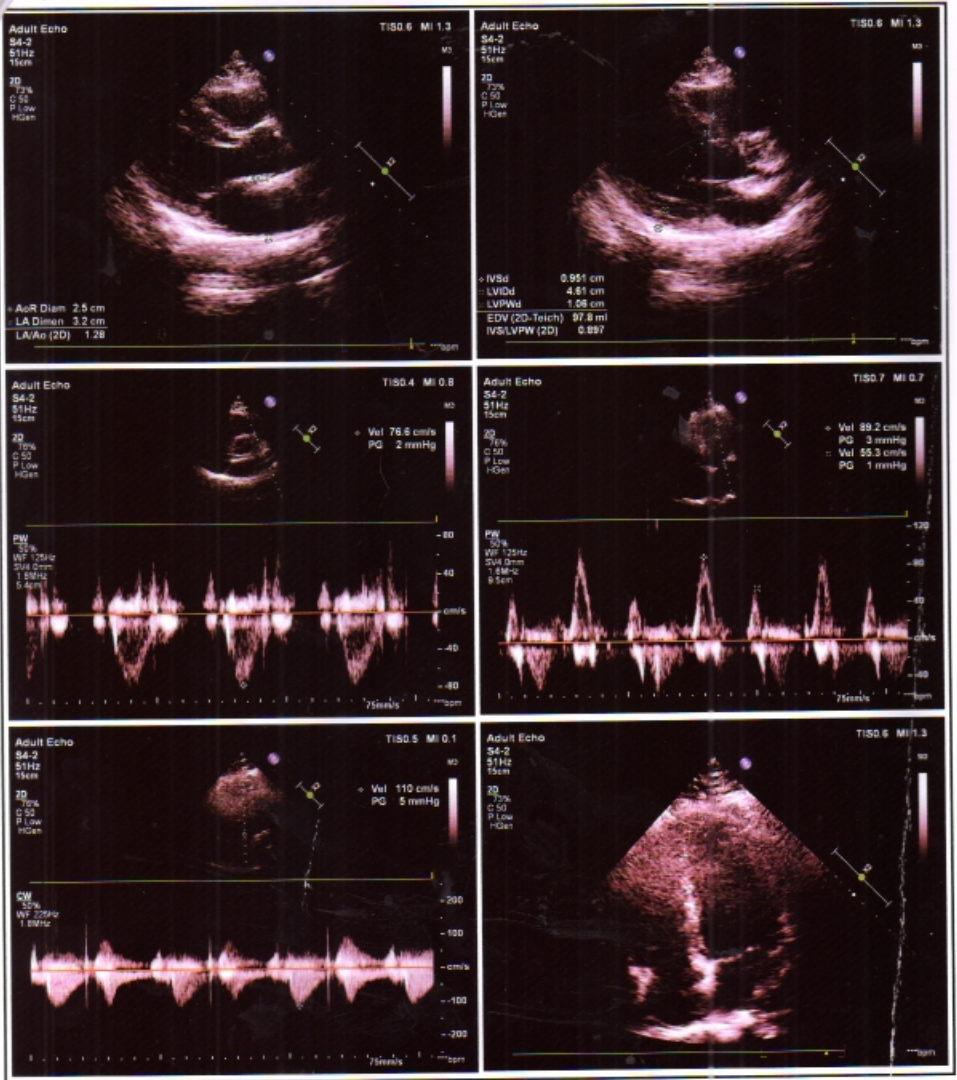
0.05-35 Hz F50

Th 16/12/21 18:49:32

Part R172-613A-03

S&A

Images





GUPTA ENT AND HEART CENTRE

Dayanand Marg, Nangli Circle, Alwar (Raj.) Ph. 0144-3591336 | M. 7378184427

Echocardiography Report

Name : Mr. Hemant Verma Refd by: Dr. M.N. Thareja
Age / Sex : 29yrs./male Date : 16 December 2021

Clinical Diagnosis : For Cardiac Evaluation
2D Echocardiography Findings
Mitral Valve : Normal
Aortic Valve : Normal
Tricuspid Valve : Normal
Pulmonary Valve : Normal
Left Atrium : 3.2cm: Normal
Left Ventricle : Normal LV size with normal LV systolic function. No RWMA

LVIDd	4.6cm.	IVSd	0.9cm.	EF	60%	Visual
LVIDs	2.5cm.	PWD	1.0cm.	EF	%	F.S.

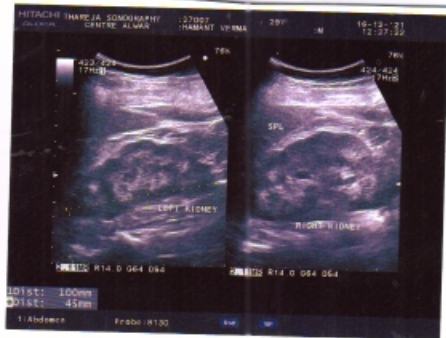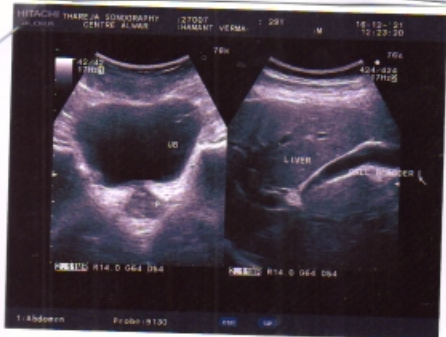Right Atrium : Normal
Right Ventricle : Normal
Aorta : 2.5cm: Normal
Pulmonary Artery : Normal
Pulmonary Veins : Normal
Superior Venacava : Normal
Inferior Venacava : Normal
Pericardium : Normal
Intracardiac Masses : No Intracardiac masses seen
IAS/IVS : Intact

Doppler Findings:

Valve	Peak Velocity (cm/s)	Peak Gradient (mmHg)	Mean Gradient (mmHg)	Regurgitation Grade	others/comments
Mitral Valve	E-/A-89/55			No MR	
Aortic Valve	110				
Tricuspid Valve				No TR, No PAH.	
Pulmonary Valve	76				

Diagnosis : Transthoracic echo done in supine position at resting heart rate of 70bpm, shows
**Normal LV size with normal LV systolic function. LVEF~60% (Visual).
No RWMA.**
Other cardiac chambers are normal in Size.
No MR, No TR, No PAH.
Normal MIP.
No pericardial effusion /Vegetation /Clot Intracardiac masses seen.
Normal left sided arch of aorta, No Coarctation.

Dr. Prachi Gupta
MBBS, PGDCC
(Non-invasive cardiologist)
Gupta ENT and Heart Centre
Nangli Circle, Alwar





THAREJA SONOGRAPHY CENTRE

1, Ram Kuteer, Company Bagh Road, ALWAR - 📞 (0144) 2700184



This report is not valid for MLC Purpose

Ref. No.

Date.....
16/12/2021

Name of Patient: MR.HEMANT VERMA Age : 28 Yrs. Sex: M
Ref.by: DR. THAREJA

Sonography Report – abdomen

LIVER:	Size: RL: 13.2 cm	L. L.: 6.3 Cm.
	Margins: Regular	I.H.B.R: ND
	Parenchyma : Echo	-
C. B. D.	Size: 3.4 mm	LUMEN: Clear
P.V.	Size: mm	LUMEN: Clear
GALL BLADDER :	Size 3.2 X 1.9 cm	
Wall thickness N		Lumen : Clear
PANCREAS: N		
SPLEEN: 6.7 cc		
KIDNEYS:	Right: 9.5 X 4.4 cm	Left: 9.7 X 4.2 cm


PELVICALYCAL SYSTEM: |
CORTICO – MEDU. DIFF: | N

RETROPERITONEUM :	 Not Seen
LYMPH – NODES	
PLEURAL EFFUSION :	
ASCITES	
URINARY BLADDER:	
Prevoiding Volume 198 cc	Residual Urine <u>C.C.</u>
Wall Thickness <u>N</u>	Lumen: Clear
PROSTATE:	
Size: 10.2 cc	Capsule: Intact
Parenchyma: Echo	

SEMINAL – VASICLES: Normal

Conclusion:- Normal Study

Thanks,



Dr. M. N. Thareja
Reg. No. 7600
Rajasthan Medical Council

Enclosed: Photo - 2

PLEASE NOTE: **INTESTINAL PATHOLOGY CAN NOT BE RULE OUT**

This is only an opinion, not a diagnosis, which should be clinically co-related. No procedure/surgery should be undertaken simply on the basis of this opinion because Ultrasound accuracy is only 70%.

* Subject to Alwar jurisdiction. * Not valid for medico-legal purposes.


Dr. M. N. THAREJA
MBBS
Thareja Nursing Home
Alwar-301001, (Raj.)



THAREJA NURSING HOME



DIGITAL X-RAY, OPG, COMPUTERISED ECG & EEG, DIAGNOSTIC
LABORATORY EQUIPED WITH COMPUTERISED AUTO ANALYZER & CBC

1, Ram Kuteer, Company Bagh Road, ALWAR - 301001 (Raj.) Ph: 0144-2700184, 2331842

Name : **HEMANT VERMA**

age **29**

Sex : **MALE**

Ref. By : **M.N.THAREJA**

Lab No. : **227**

Date : **December 16, 2021**

HORMONES & MARKERS

<u>Test</u>	<u>Value</u>	<u>Units</u>	<u>Biological Ref. Values</u>
T3 (Total Triiodothyronine)	1.25	ng/dL	0.60-1.81 ng/dL Adults
T4 (TotalThyroxine)	4.17	µg/dL	3.2-12.60 µg/dL : Adults
TSH (Thyroid Stimulating Hormone)	1.83	µIU/mL	Adults : 0.35-5.50 µIU/mL

Interpretation of TSH :-

Children

0 Days : 1.0-39.0 uIU/mL

5 days : 1.7-9.1 uIU/mL

1 year : 0.4-8.6 uIU/mL

2 years : 0.4-7.6 uIU/mL

3 years : 0.3-6.7 uIU/mL

4-19 years : 0.4-6.2 uIU/mL

Interpretation of TSH :-

Children

3.20 - 34.6 µIU/mL 1- 2 Days

0.70 - 15.4 µIU/mL 3 - 4 Days

0.70 - 9.10 µIU/mL 15 Days - 5 Months

0.70 - 6.40 µIU/mL 5 Months - 20 Years

Adults

20-54 years : 0.35-5.50 uIU/mL

55-87 years : 0.5-8.9 uIU/mL

Pregnancy

1st Trimester : 0.30 - 4.50 µIU/mL

2nd Trimester : 0.50 - 4.60 µIU/mL

3rd Trimester : 0.80 - 5.20 µIU/mL

Pregnancy

0.30 - 4.50 µIU/mL 1st Trimester

0.50 - 4.60 µIU/mL 2nd Trimester

0.80 - 5.20 µIU/mL 3rd Trimester

Method : **Fluorescence Immunoassay Technology**

Sample Type : **Fresh Blood Serum**

Remarks :

Primary malfunction of the Thyroid gland may result in excessive (hyper) or Low (hypo) release of T3 or T4. In addition, as TSH directly affect thyroid function, malfunction of the pituitary or the hypothalamus influences the thyroid gland activity.


Disease in any portion of the thyroid-pituitary-hypothalamus system may influence the level of T3 and T4 in the blood, in Primary Hypothyroidism,

TSH levels are significantly elevated, while in secondary and tertiary hypothyroidism, TSH levels may be low. In addition, in Euthyroid sick syndrome, multiple alterations in serum thyroid function test findings have been recognized.

Signature of Technician

Signature of Doctor

This Report is not Valid for Medical Legal Purpose



LETTER OF APPROVAL / RECOMMENDATION

To,

The Coordinator,
Mediwheel (Arcofemi Healthcare Limited)
Helpline number: 011- 41195959

Dear Sir / Madam,

Sub: Annual Health Checkup for the employees of Bank of Baroda

This is to inform you that the following employee wishes to avail the facility of Cashless Annual Health Checkup provided by you in terms of our agreement.

PARTICULARS	EMPLOYEE DETAILS
NAME	MR. VERMA HEMANT
EC NO.	125616
DESIGNATION	HEAD CASHIER "E" _II
PLACE OF WORK	TAPUKARA
BIRTHDATE	02-07-1992
PROPOSED DATE OF HEALTH CHECKUP	16-12-2021
BOOKING REFERENCE NO.	21D125616100008050E

This letter of approval / recommendation is valid if submitted along with copy of the Bank of Baroda employee id card. This approval is valid from **14-12-2021** till **31-03-2022** The list of medical tests to be conducted is provided in the annexure to this letter. Please note that the said health checkup is a **cashless facility** as per our tie up arrangement. We request you to attend to the health checkup requirement of our employee and accord your top priority and best resources in this regard. The EC Number and the booking reference number as given in the above table shall be mentioned in the invoice, invariably.

We solicit your co-operation in this regard.

Yours faithfully,

Sd/-

Chief General Manager
HRM Department
Bank of Baroda

(Note: This is a computer generated letter. No Signature required. For any clarification, please contact Mediwheel (Arcofemi Healthcare Limited))

