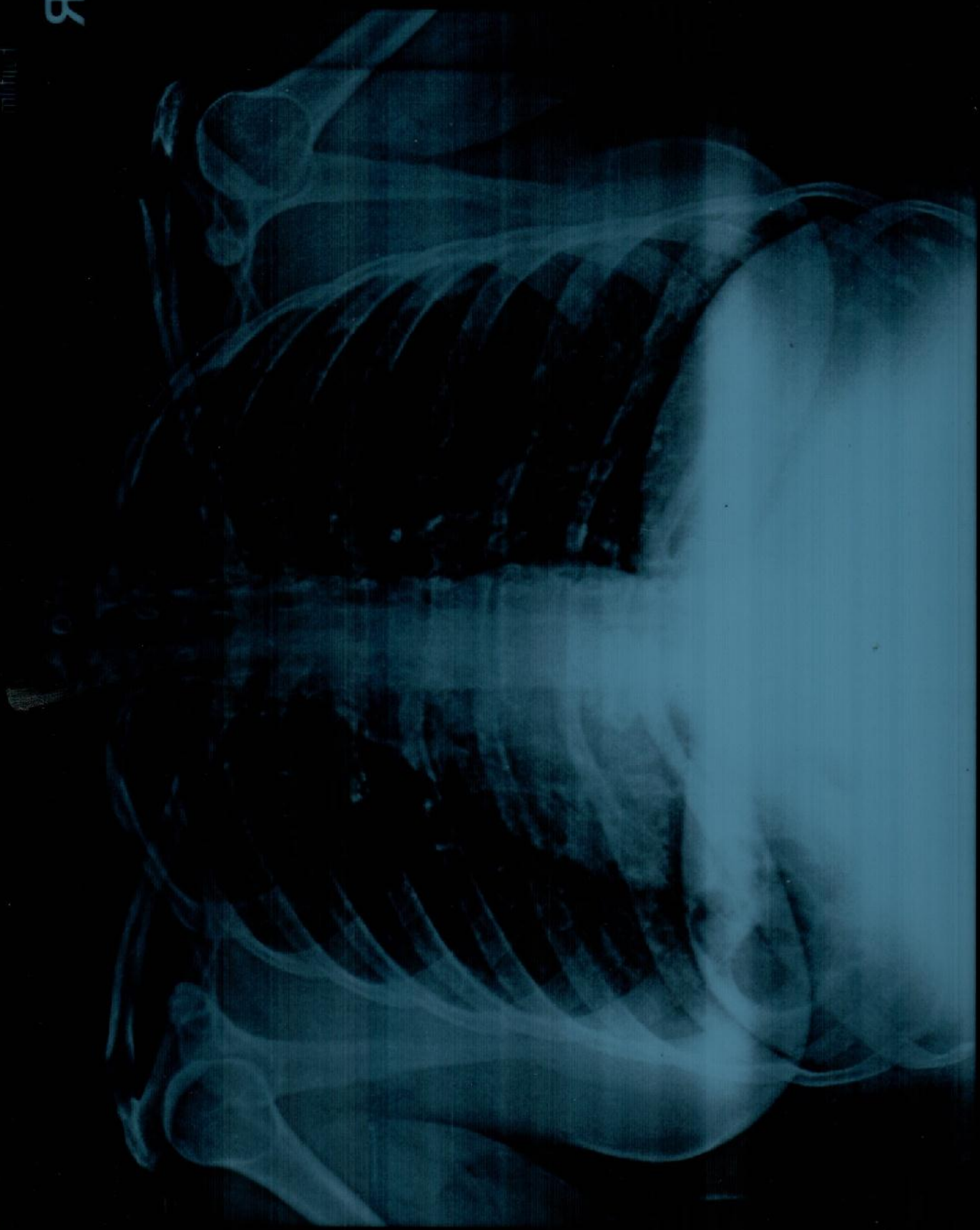


РАДНОСТРОЈНО ПОВЕЉИЈЕ

ПРИЈАВЉИВАЊЕ РАДНОСТРОЈНО ПОВЕЉИЈЕ - ЧЛАНЦИ 171 - 174



R

171/174

- MULTI SPECIALITY
- CRITICAL CARE
- TRAUMA CARE CENTER

Patient Name : MRS JAYASHREE CHAUDHARI	Patient ID : 0
Age : 42	Sex : Female
Referring Physician : Dr. SADGURU HOSPITAL	Date : July 10, 2021

X-RAY CHEST PA

MRS JAYASHREE CHAUDHARI's plain P.A. Radiograph of chest shows :-
 Both lung fields show normal and equal radiolucency.
 There is no pulmonary parenchymal abnormal density.
 The broncho vascular markings show normal size and distribution.
 The hilar shadows are normal in size, position and density.
 Both Cardiophrenic and Costophrenic angles are clear.
 The Cardiac silhouette is within normal limits.
 Aortic shadow is normal.
 Rest of the visualized mediastinum shadows are normal.
 Both domes of diaphragms are normal.
 The visualised bony thorax is normal.

CONCLUSION : NO SIGNIFICANT ABNORMALITY NOTED IN THE CHEST P.A. VIEW RADIOGRAPH.



DR. Jayesh B Shah
 MD (Radio-Diagnosis), DMRD Reg -52736



NOT FOR MEDICOLEGAL PURPOSE
 Radiological Findings should be correlated clinically to arrive at diagnosis. In case of any discrepancy between clinical and radiological findings kindly re-investigate the patient.