



VID :- E/13153

PID No. :- 202427117126891

Name :- Mrs Deepika Tirkey

Age/Sex :- 32 Y / F

Ref. By. :- ARCOFEMI HEALTHCARE LIMITED

Sample Received on/at :

27/01/2024 8:59AM

Reported on/at

27/01/2024 5:07PM

BIOCHEMISTRY

Investigation	Observed Value	Unit	Biological Reference Range
GGT/GammaGT			
Gamma GT Szasz method	18.4	U/L	11 - 34
BLOOD SUGAR F			
Glucose Fasting	63	mg/dl	60 - 110
BLOOD SUGAR PP			
Glucose PP	77	mg/dl	70 - 140
Lipid Profile (Fasting Sample Required)			
Cholesterol - Total	174	mg/dL	Desirable <200 Borderline High : 200-239 High :>=240
Triglycerides Level	141	mg/dL	Normal : <150 Borderline High :150-199 High : 200-499 Very High : >=500
HDL Cholesterol	38	mg/dl	Major risk factor for heart Disease :<40 Negative risk factor for heart Disease:>=60
LDL Cholesterol	107.80	mg/dL	
VLDL Cholesterol	28.20	mg/dL	6-38
LDL/HDL RATIO	2.84		2.5-3.5
CHOL/HDL RATIO	4.58		3.5 - 5

Note : Reference Interval as per National Cholesterol Education Program (NCEP) Adult Treatment Panel III Report.

RFT (RENAL FUNCTION TEST)

Renal (Kidney) Function Test

Urea (Serum)	26.4	mg/dL	15 - 43
Creatinine (Serum, Jaffe)	0.72	mg/dL	0.57 - 1.4
Sodium	142	mmol/L	135 - 145
Potassium	4.1	mmol/L	3.5 - 5.1
Uric Acid (Serum, Uricase)	4.61	mg/dL	2.6 - 6
Chlorides	102	mmol/L	98 - 107

----- End Of Report -----

Dr. Avishesh Kumar Singh
M.D. (Pathologist)



VID :- E/13153
PID No. :- 202427117126891
Name :- Mrs Deepika Tirkey
Age/Sex :- 32 Y / F
Ref. By. :- ARCOFEMI HEALTHCARE LIMITED

Sample Received on/at :
27/01/2024 8:59AM

Reported on/at
27/01/2024 5:07PM

The performance of the Roche cobas c 111 was evaluated using sigma metrics. The calculations were performed using James O. Westgard methodology.[2] This approach uses an assays total allowable error (TEa), accuracy (bias), and precision (SD) to calculate a Sigma metric to characterize the performance of that assay.

HBA1C

HbA1c Value	4.11	%	4-6=Normal Control	6-7=Good 7-8=Fair Control
-------------	------	---	-----------------------	---------------------------------

8-10=Unsatisfactory Control
>10%=Poor Control

Glycosylated Hemoglobin/Glycated Hemoglobin/GlycoHemoglobin/HbA1c. [1]

Its primary use is to monitor diabetic patient's compliance and long term blood glucose level control . It is an index of diabetic control (direct relationship between poor control and development of complications). It predicts development and progression of diabetic microvascular complications.

----- End Of Report -----

Dr. Avishesh Kumar Singh
M.D. (Pathologist)



VID :- E/13153

PID No. :- 202427117126891

Name :- Mrs Deepika Tirkey

Age/Sex :- 32 Y / F

Ref. By. :- ARCOFEMI HEALTHCARE LIMITED

Sample Received on/at :

27/01/2024 8:59AM

Reported on/at

27/01/2024 5:07PM

CLINICAL PATHOLOGY

Investigation	Observed Value	Unit	Biological Reference Range
URINE R/M			
<u>Physical Examination</u>			
Specific Gravity	1.030		1.003-1.030
Appearance	Clear		Clear
Colour	Pale Yellow		Pale Yellow
pH (Reaction)	Acidic		
<u>Chemical Examination</u>			
Protein	NIL		NIL
Glucose	NIL		NIL
<u>Microscopic Examination</u>			
PUS CELLS	4-5	/hpf	0-5
Epithelial Cells	1-2	/hpf	0-5
RBC	Absent	/hpf	Absent
Bacteria	Absent		Absent
Crystals	Absent		Absent
Casts	Absent		Absent

Test Done by Urisys 1100 (ROCHE) Fully Automatic.

----- End Of Report -----

Dr. Avishesh Kumar Singh
M.D. (Pathologist)



VID :- E/13153

PID No. :- 202427117126891

Name :- Mrs Deepika Tirkey

Age/Sex :- 32 Y / F

Ref. By. :- ARCOFEMI HEALTHCARE LIMITED

Sample Received on/at :

27/01/2024 8:59AM

Reported on/at

27/01/2024 5:07PM

Complete Blood Count (Haemogram)

Investigation	Observed Value	Unit	Biological Reference Range
CBC			
<u>Erythrocytes</u>			
Haemoglobin (Hb)	11.3	gm/dL	12.5 - 16.5
Erythrocyte (RBC) Count	4.94	mill/cu.mm	4.2 - 5.6
PCV (Packed Cell Volume)	35.9	%	36 - 47
MCV (Mean Corpuscular Volume)	73	fl	78 - 95
MCH (Mean Corpuscular Hb)	22.9	pg	26 - 32
MCHC (Mean Corpuscular Hb Concn.)	31.6	g/dL	32 - 36
RDW (Red Cell Distribution Width)	14.6	%	11.5 - 14
<u>Leucocytes</u>			
Total Leucocytes (WBC) Count	3900	cells/cu.mm	4000 - 11000
Neutrophils	54	%	40 - 75
Lymphocytes.	38	%	20 - 40
Monocytes	07	%	2-10
Eosinophils	01	%	1-6
Basophils	00	%	0 - 1
<u>Platelets-</u>			
Platelet count	253	x10 ⁹ /L	150 - 450
MPV (Mean Platelet Volume)	7.9	fL.	6 - 9.5
PCT (Platelet Haematocrit)	0.199	%	0.15 - 500
PDW (Platelet Distribution Width)	12.9	%	11 - 18

EDTA Whole Blood - Tests done on Automated ABX Micros ES60(HORIBA) Cell Counter. WBC, RBC & Platelet count by impedance method, WBC differential by VCS technology & other parameters calculated) All abnormal Haemograms are reviewed & confirmed microscopically. Differential count is based on approximately 10,000 cells.

----- End Of Report -----

Dr. Avishesh Kumar Singh
M.D. (Pathologist)



VID :- E/13153

PID No. :- 202427117126891

Name :- Mrs Deepika Tirkey

Age/Sex :- 32 Y / F

Ref. By. :- ARCOFEMI HEALTHCARE LIMITED

Sample Received on/at :

27/01/2024 8:59AM

Reported on/at

27/01/2024 5:07PM

Hematology

Investigation	Observed Value	Unit	Biological Reference Range
Blood Group & RH Type Screening			
ABO Group	"A"		
Rh Type	"POSITIVE"		

Method: Column agglutination technology (CAT) is an automated. System for blood grouping which is superior in sensitivity to conventional tube method.

ESR

ESR - Erythrocyte Sedimentation Rate (Citrate Blood) Method: Westergren	35	mm at 1hr	0 - 20
---	-----------	-----------	--------

Interpretation:

1. It indicates presence and intensity of an inflammatory process, never diagnostic of a specific disease. Changes are more significant than a single abnormal test.
2. It is a prognostic test and used to monitor the course or response to treatment of diseases like tuberculosis, bacterial endocarditis, acute rheumatic fever, rheumatoid arthritis, SLE, Hodgkins disease, temporal arteritis, polymyalgia rheumatica.
3. It is also increased in pregnancy, multiple myeloma.

----- End Of Report -----

Dr. Avishesh Kumar Singh
M.D. (Pathologist)



VID :- E/13153

PID No. :- 202427117126891

Name :- Mrs Deepika Tirkey

Age/Sex :- 32 Y / F

Ref. By. :- ARCOFEMI HEALTHCARE LIMITED

Sample Received on/at :

27/01/2024 8:59AM

Reported on/at

27/01/2024 5:07PM

PATHOLOGY

Investigation	Observed Value	Unit	Biological Reference Range
---------------	----------------	------	----------------------------

Urine Sugar Fasting

Urine Sugar (Fasting)

Absent

Absent

Thyroid Panel 1 (T3, T4, TSH)

T3

1.02

ng/dl

0.6-1.8

Remarks : 1. Decreased values of T3 (T4 and TSH normal) have minimal clinical significance and not recommended for diagnosis of hypothyroidism 2. Total T3 and T4 values may also be altered in other conditions due to changes in serum proteins or binding sites Pregnancy, Drugs (Androgens, Estrogens, O C pills, Phenytoin), Nephrosis etc. In such cases Free T3 and Free T4 give corrected values.

T4

7.14

ug/dl

4.5-12.6

Remark: 1. Total T3 and T4 values may also be altered in other conditions due to changes in serum proteins or binding sites Pregnancy, Drugs (Androgens, Estrogens, O C pills, Phenytoin) Nephrosis etc. In such cases Free T3 and Free T4 give corrected values.

TSH

2.91

uIU/ml

0.25 - 5.5

Remarks : 1. 4.51 to 15 μ IU/mL - Suggested clinical co-relation or repeat the test with new sample as physiological factors can give falsely high TSH.

2. TSH values may be transiently altered because of non thyroidal illness like severe infections, liver disease, renal and heart failure, severe burns, trauma and surgery etc

3. Drugs that decrease TSH values e.g: L-dopa, Glucocorticoids Drugs that increase TSH values e.g Iodine, Lithium, Amiodarone

Remark

Method Used : ELFA (Enzyme Linked Fluorescence Assay) on Mini Vidas most Efficient Analyzer Internationally accepted most advanced technology with high quality result.

----- End Of Report -----

Dr. Avishesh Kumar Singh

M.D. (Pathologist)




भारत सरकार
Government of India

भारतीय विशिष्ट पहचान प्राधिकरण
Unique Identification Authority of India

नामांकन क्रम/ Enrolment No.: 0013/18004/17939

To
दीपिका तिरकी
Deepika Tirkey
C/O: Deepak Tirkey
House no 40
Sector No-3
Shivanand Nagar
Khamtarai-2 (khamtarai)
Raipur Chhattisgarh - 492008
6264444526

Signatures Not Verified
Digitally signed by
UNIQUE IDENTIFICATION
AUTHORITY OF INDIA 05
Date: 2023.09.23 10:57:53
UTC



आपका आधार क्रमांक / Your Aadhaar No. :

6280 6397 8764

VID : 9138 3257 7617 9742

मेरा आधार, मेरी पहचान



भारत सरकार
Government of India



दीपिका तिरकी
Deepika Tirkey
जन्म तिथि/DOB: 22/09/1991
महिला/ FEMALE

6280 6397 8764

VID : 9138 3257 7617 9742

मेरा आधार, मेरी पहचान



Government of India



सूचना

- आधार पहचान का प्रमाण है, नागरिकता का नहीं।
- सुरक्षित QR कोड / ऑफलाइन XML / ऑनलाइन ऑथेंटिकेशन से पहचान प्रमाणित करें।
- यह एक इलेक्ट्रॉनिक प्रक्रिया द्वारा बना हुआ पत्र है।

INFORMATION

- Aadhaar is a proof of identity, not of citizenship.
- Verify identity using Secure QR Code/ Offline XML/ Online Authentication.
- This is electronically generated letter.

- आधार देश भर में मान्य है।
- आधार कई सरकारी और गैर सरकारी सेवाओं को पाना आसान बनाता है।
- आधार में मोबाइल नंबर और ईमेल ID अपडेट रखें।
- आधार को अपने स्मार्ट फोन पर रखें, mAadhaar App के साथ।

- Aadhaar is valid throughout the country.
- Aadhaar helps you avail various Government and non-Government services easily.
- Keep your mobile number & email ID updated in Aadhaar.
- Carry Aadhaar in your smart phone – use mAadhaar App.



भारतीय विशिष्ट पहचान प्राधिकरण
Unique Identification Authority of India




Issue Date: 19/01/2014

Download Date: 20/09/2023

पता:
द्वारा: दीपक तिरकी, हाउस न 40, सेक्टर न-3, शिवानंद
नगर, खमताराई २ (खमताराई), रायपुर,
छत्तीसगढ़ - 492008

Address:
C/O: Deepak Tirkey, House no 40, Sector No-
3, Shivanand Nagar, Khamtarai-2
(khamtarai), Raipur,
Chhattisgarh - 492008



6280 6397 8764

VID : 9138 3257 7617 9742

मेरा आधार, मेरी पहचान

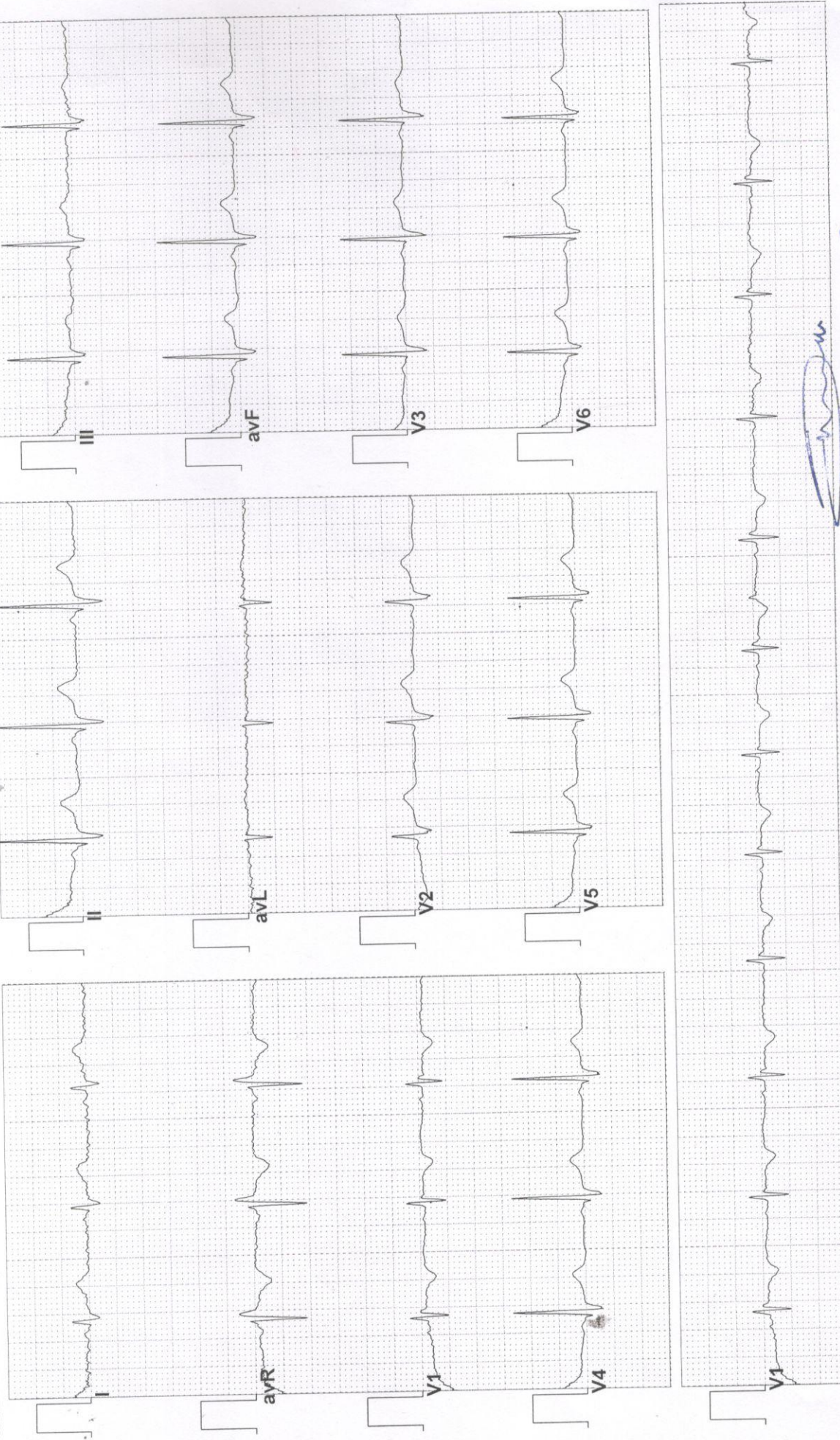
Dr. Shalendra Rupprela
MD, Medicine

Reg. No.: CG MC-511/2006

help@uidai.gov.in | www.uidai.gov.in

DR. RUPRELAS NMS DIAGNOSTICS AND IMAGING FAFADIH BILASPUR ROAD RAIPUR

5476549872; MRS DEEPIKA TIRKEY; Female; 32 Yrs 03 Mths
Ref.: HEALTHCARE; Date : 27-01-2024; Time : 11:56:55



FINDINGS: Normal Sinus Rhythm with Abnormal QTc Interval
Vent Rate : 73 bpm PR Interval : 98 ms QRS Duration: 124 ms QT/QTc Int : 417/460
P-QRS-T axis: 67° 101° 46° (Deg)
Comments :

Dr. Shailendra Ruprela
MD, Medicine
Reg. No.: CG MC-511/2006



Dr. Ruprela's
NMS Diagnostics & Imaging
"अचूक निदान" स्वस्थ जीवन की ओर...

TO WHOM SO EVER IT MAY CONCERN

**THIS IS TO DECLARE THAT MRS. DEEPIKA TIRKEY AGE 32 Y/F HAS UNDERGONE
DENTAL EXAMINATION ON 27.01.2024.**

**DURING HER INTRAORAL EXAMINATION NO HARD AND SOFT TISSUE
ABNORMALITIES WERE DETECTED.**

NO CAVITIES DETECTED.

CALCULUS +

STAINS +


HER EXTRAORAL EXAMINATION REVEALS NO ABNORMALITY.

ADVISE: ORAL PROPHYLAXIS,

MAINTAIN GOOD ORAL HYGIENE,

FOLLOW UP,

BRUSH TWICE DAILY.


Dr. Poonam Ruprela
Consultant Dental Surgeon
CGDCE 2169

FAFADIH, NEAR OVER BRIDGE, RUPRELA MARG (SINCE 1937), RAIPUR (C.G.)

Ph.: 0771-4048886, 2888800, Mob.: 9406396296, Email : nmsdiagnostic.service@gmail.com, Website : www.nmsdiagnostics.co.in

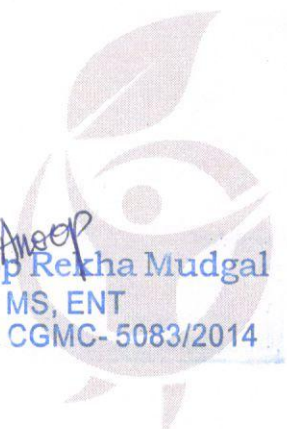
TO WHOM SO EVER IT MAY CONCERN

THIS IS TO DECLARE THAT MRS. DEEPIKA TIRKEY AGE-32/F HE UNDERGONE ENT EXAMINATION ON 27/01/2024. DURING HIS EXAMINATION NO SOFT AND HARD TISSUE ABNORMALITIES WERE DETECTED IN THE EAR, NOSE AND THROAT. NO DISCHARGE FOUND. NO SIGNIFICANT HISTORY.

NO LYMPH NODES WERE TENDER AND PALPABLE.

AIR AND BONE CONDUCTION TEST WERE NEGATIVE.

ADVISE: MAINTAIN GOOD HYGIENE AND FOLLOW UP


Anoop
Dr. Anoop Rekha Mudgal
MS, ENT
Reg. No.: CGMC- 5083/2014

TO WHOM SO EVER IT MAY CONCERN

THIS IS TO DECLARE THAT MRS. DEEPIKA TIRKEY AGE 32 YEAR/FEMALE HAS UNDERGONE MEDICAL EXAMINATION ON 27.01.2024 DURING HER GENERAL EXAMINATION NO ABNORMALITIES WERE DETECTED.

SHE WAS FULLY ORIENTED , NO DISABILITY WITH NORMAL GAIT.

NO SIGNS OF PALPABLE OR ENLARGED LYMPH NODES.

NO GROWTH / SWELLING OBSERVED.

HER VITALS PARAMETERS ARE HEIGHT: 143cms, WEIGHT:43kg, BP:110/72mmhg, HR: 73 bpm, BMI: 21

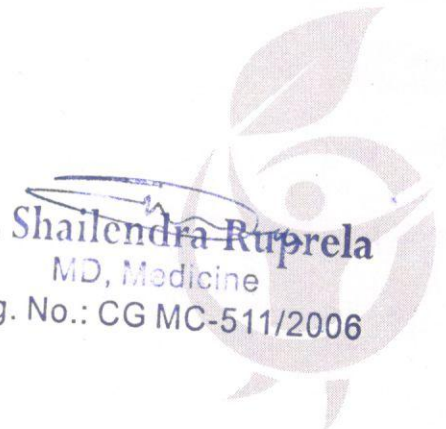
HER BOWEL HABITS ARE REGULAR. NO BURNING DURING MICTURITION.

ALL REFLEXES WERE NORMAL.

NO ABNORMALITIES WERE DETECTED DURING PALPATION, PERCUSSION AND AUSCULTATION OF VISCERA.

SHE DOES NOT CARRY ANY COMMUNICABLE/TRANSFERRABLE DISEASE.

SHE APPEARS TO BE **PHYSICALLY FIT** AND WE WISH HER ALL THE BEST.



Dr. Shailendra Ruprela
MD, Medicine
Reg. No.: CG MC-511/2006

FAFADIH, NEAR OVER BRIDGE, RUPRELA MARG (SINCE 1937), RAIPUR (C.G.)

Ph.: 0771-4048886, 2888800, Mob.: 9406396296, Email : nmsdiagnostic.service@gmail.com, Website : www.nmsdiagnostics.co.in



Dr. Ruprela's
NMS Diagnostics & Imaging
"अधुक्त निदान" स्वस्थ जीवन की ओर...

THIS IS TO DECLARE THAT MRS. DEEPIKA TIRKEY AGE 32 YEAR/FEMALE HAS UNDERGONE GYNAECOLOGICAL EXAMINATION ON 27.01.2024 DURING HER EXAMINATION NO ABNORMALITIES WERE DETECTED.

HEIGHT:143cms,

WEIGHT: 43kg,

BP: 110/72 mmhg,

NO MENSTRUATION IRRREGULARITIES.

NO DISCHARGE / ITCHING PER VAGINA.

SHE APPEARS TO BE HEALTHY.





DR.PRIYANKA JAIN

MD(OBS. & GYNAE.)



FAFADIH, NEAR OVER BRIDGE, RUPRELA MARG (SINCE 1937), RAIPUR (C.G.)

Ph.: 0771-4048886, 2888800, Mob.: 9406396296, Email : nmsdiagnostic.service@gmail.com, Website : www.nmsdiagnostics.co.in

 "HEALTH" +  "HUMAN" +  "COMPLETE SOLUTION" = 



Dr. Ruprela's
NMS Diagnostics & Imaging
"अचूक निदान" स्वस्थ जीवन की ओर...

MRS. DEEPIKA TIRKEY

DATE : 27.01.2024

AGE : 32

SEX : FEMALE

HEIGHT : 143 cms

WEIGHT : 43 kgs

BMI : 21

BLOOD PRESSURE : 110/72 mmhg

MEDICAL HISTORY : NOT SIGNIFICANT

ADVICE :

1. DRINK MINIMUM 10 GLASSES OF WATER.
2. EXERCISE/BRISK WALK FOR MINIMUM 50 MINS DAILY.
3. INCREASE INTAKE OF FIBRE LIKE SALAD, FRUIT, SPROUTS.
4. TAKE GOOD SLEEP FOR 7-8 HOURS DAILY.
5. AVOID SPICY AND DEEP FRIED FOOD.
6. AVOID ALCOHOL, SMOKING, NICOTINE.
7. AVOID STRESS.
8. RELAX AND BE HAPPY.


DR. RASHI SALUJA
CONSULTANT DIETICIAN

FAFADIH, NEAR OVER BRIDGE, RUPRELA MARG (SINCE 1937), RAIPUR (C.G.)

Ph.: 0771-4048886, 2888800, Mob.: 9406396296, Email : nmsdiagnostic.service@gmail.com, Website : www.nmsdiagnostics.co.in



NAME : MRS. DEEPIKA TIRKEY

AGE : 32 Y/SEX/F

Ref. By : ARCOFEMI HEALTHCARE LTD.

DATE : 27.01.2024

Complain Of : No Complaints

Ocular H/O: Nil

Family Ocular H/O: Nil

Drug Allergy (If Any): Not Aware

DISTANCE VISION:

(With / without PGP)

RE

6/9

LE

6/9

NEAR VISION:

(With / without PGP)

RE

N/6

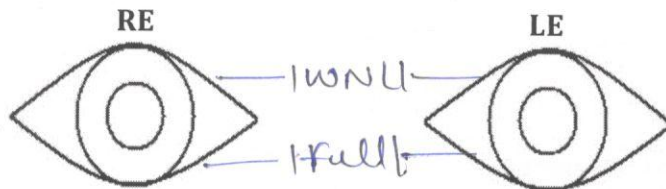
LE

N/6

REFRACTION:

EYE	SPH	CYL	AXIS	ADD	VISION
RE	-0.5	_____	_____	6/6	N/6
LE	-0.5	_____	_____	6/6	N/6

EXTERNAL EYE EXAMINATION:



EOM: NAD

SQUINT EVALUATION: ABSENT

NYSTAGMUS: ABSENT

COLOR VISION TEST: NORMAL

NYCTALOPIA (Night Blindness): ABSENT

Dr. Vaidhyanav Sharma
Ophthalmologist
Reg. No. MCI/10-37782

FAFADIH, NEAR OVER BRIDGE, RUPRELA MARG (SINCE 1937), RAIPUR (C.G.)

Ph.: 0771-4048886, 2888800, Mob.: 9406396296, Email : nmsdiagnostic.service@gmail.com, Website : www.nmsdiagnostics.co.in



Dr. Ruprela's
NMS Diagnostics & Imaging

"अचुक निदान" स्वस्थ जीवन की ओर...

Pap smear

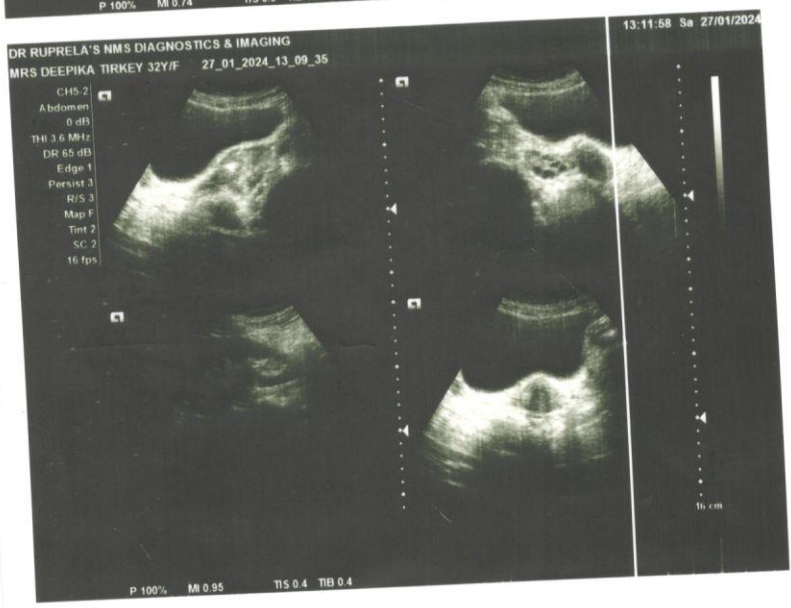
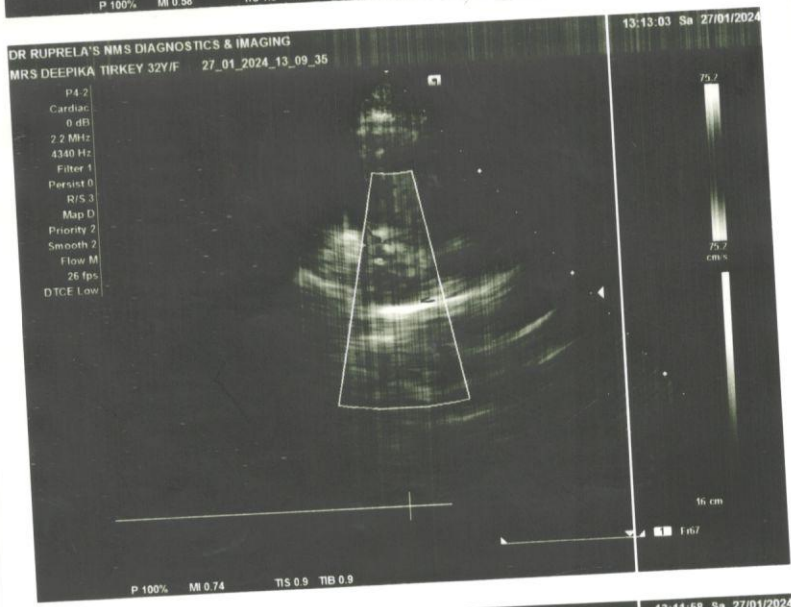
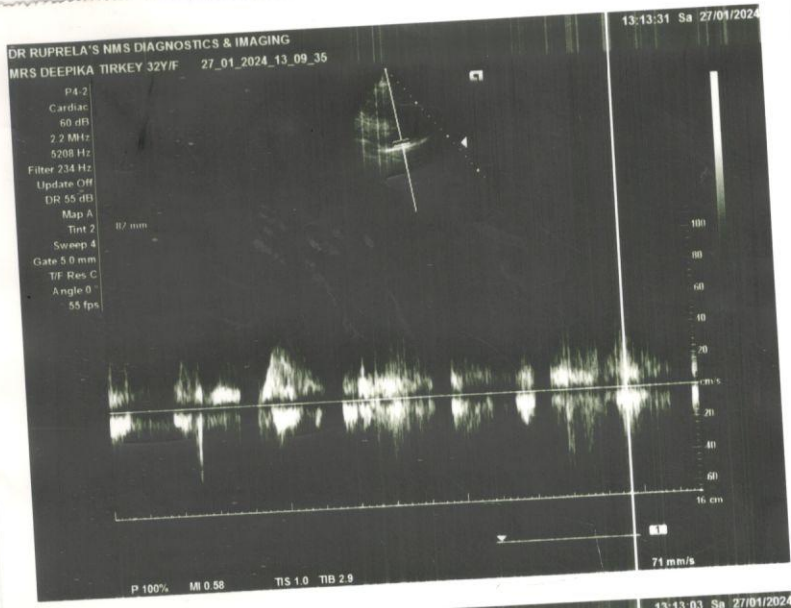
शु. नहीं करना चाहिए।

27/01/24



FAFADIH, RUPRELA MARG, BILASPUR ROAD, RAIPUR (C.G.)
Ph.: 0771-4048886, Mob.: 9406396296, Email : nmsdiagnostic.service@gmail.com, Website : www.rupreladiagnostics.in

“HEALTH” + “HUMAN” + “COMPLETE SOLUTION” =





NAME : MRS. DEEPIKA TIRKEY
REF. BY: ARCOFEMI HEALTHCARE LTD.

AGE : 32 Y/F
DATE : 27.01.2024

SONOGRAPHY OF WHOLE ABDOMEN & PELVIS

The Real time, B mode, gray scale sonography of the abdominal organs was performed.

LIVER :The liver is normal in size , shape and has smooth margins. It is uniformly isoechoic , has normally distributed and normal size biliary and portal radicles and is without solid or cystic mass lesion or calcification.

GALL BLADDER :The gall bladder is seen as a well distended, pear shaped bag with uniformly thin and regular walls, without, gall stones or mass lesions.

COMMON BILE DUCT :The common bile duct is normal in caliber.

PANCREAS :The pancreas is normal in size, shape, contours and echotexture.
No evidence of solid or cystic mass lesion is noted.

KIDNEYS :The kidneys are normal in size and have smooth renal margins.
Cortical echotexture is normal.

The central echocomplex does not show evidence of calculus or hydronephrosis.

URINARY BLADDER :The urinary bladder is well distended. No calculi/mass.

SPLEEN : The spleen is normal in size and shape. Its echotexture is homogeneous. No evidence of focal lesion is noted.

PELVIS :

The uterus is antetverted, & appears normal.

The uterine margins is smooth and does not reveal any contour abnormalities.

The uterine myometrium shows homogeneous echotexture.

The ovaries on the either side show normal echotexture.

The endometrial echo is in the midline.

No adnexal mass is seen.

No fluid is noted in the cul-de-sac.

IMPRESSION :

The sonography of abdomen and pelvis within normal limits.

Thanks for reference with regards.

Kindly Note!

- ✓ **Please Intimate us for any typing mistakes and send the report for correction within 7 days.**
- ✓ The science of Radiological diagnosis is based on the interpretation of various shadows produced by both the normal and abnormal tissues and are not always conclusive . Further biochemical and radiological investigation & clinical correlation is required to enable the clinician to reach the final diagnosis .

The report and films are not valid for medico – legal purpose

Chhavi
Dr. Chhavi Jangde
MD

Reg No : CGMC-5516/2014

FAFADIH, NEAR OVER BRIDGE, RUPRELA MARG (SINCE 1937), RAIPUR (C.G.)

Ph.: 0771-4048886, 2888800, Mob.: 9406396296, Email : nmsdiagnostic.service@gmail.com, Website : www.nmsdiagnostics.co.in



Dr. Ruprela's
NMS Diagnostics & Imaging
"अचूक निदान" स्वस्थ जीवन की ओर...

NAME : MRS. DEEPIKA TIRKEY
REF. BY: ARCOFEMI HEALTHCARE LTD.

AGE : 32 Y/F
DATE : 27.01.2024

X-RAY CHEST PA VIEW

- The lungs on the either side show equal translucency.
- The peripheral pulmonary vasculature is normal.
- No focal lung lesion is seen.
- The pleural spaces are normal.
- The cardiac size is normal.
- The domes of the diaphragms are normal in position, and show smooth outline.
- Both hila are normal in size, have equal density and bear normal relationship.
- The heart and trachea are central in position and no mediastinal abnormality is visible.
- **IMPRESSION** : No evidence of pulmonary, pleural or cardiac pathology is noted.
Radiograph of chest is within normal limits.



FAFADIH, NEAR OVER BRIDGE, RUPRELA MARG (SINCE 1937), RAIPUR (C.G.)

Ph.: 0771-4048886, 2888800, Mob.: 9406396296, Email : nmsdiagnostic.service@gmail.com, Website : www.nmsdiagnostics.co.in



Dr. Ruprela's
NMS Diagnostics & Imaging
"अचूक निदान" स्वस्थ जीवन की ओर...

NAME : MRS. DEEPIKA TIRKEY
AGE/SEX : 32 Y/F
REFERRED BY : ARCOFEMI HEALTHCARE LTD.
DATE : 27.01.2024

PERIPHERAL SMEAR EXAMINATION

RBC : Macrocytic normochromic .

WBC: Total counts within normal range. No toxic granulation seen.
Band cells-9%, Neutrophils-46%, Lymphocytes-43%, Monocytes-2%.

Platelets: Appears adequate on smear.

Haemoparasite: No haemoparasite seen.


Dr. Avishesh Kumar Singh
MD (Pathologist)



FAFADIH, NEAR OVER BRIDGE, RUPRELA MARG (SINCE 1937), RAIPUR (C.G.)

Ph.: 0771-4048886, 2888800, Mob.: 9406396296, Email : nmsdiagnostic.service@gmail.com, Website : www.nmsdiagnostics.co.in



NAME : MRS. DEEPIKA TIRKEY
REF. BY: ARCOFEMI HEALTHCARE LTD.

AGE/SEX : 32 Y/F
DATE: 27.01.2024

ECHO - CARDIOGRAPHY

M-MODE MEASUREMENTS:

	Patient value (cm)	normal value (cm)	
Aortic Root	2.1	2.0-3.7	
Left Atrial Dimension	3.2	1.9-4.0	
Left Ventricular ED	3.9	3.7-5.6	
Left Ventricular ES	2.8	2.2-4.0	
Interventricular Septal	ED : 0.8	ES : 0.9	0.6-1.2
LEFT VENT PW	ED : 0.8	ES : 0.9	0.6-1.2

2 D ECHO

CHAMBERS	- All cardiac chambers normal.
VALVE	- NORMAL
SEPTAE	- IVS/IAS INTACT
RWMA	- NO
EF (OVERALL)(LV)	- 60 %
CLOT/ VEGETATION	- NIL
PER. EFFUSION	- NIL

CONTINUOUS WAVE & PULSE WAVE DOPPLER

Valve	Regurgitation	Gradient(mm Hg)
Mitral Valve	NIL	Not Significant
Aortic Valve	NIL	Not Significant
Tricuspid Valve	NIL	PASP=
Pulmonary Valve	Nil	Not Significant

PULSE WAVE DOPPLER

MITRAL VALVE INFLOW > Waves DT m sec

IMPRESSION -

- NO RWMA AT REST, LVEF=60%
- NORMAL BIVENTRICULAR FUNCTION
- NORMAL CHAMBERS DIMENSION.
- NO CLOT/VEGETATION/PERICARDIAL EFFUSION.
- NORMAL VALVES

DR AJAY HALWAI
MBBS,MD,PGDCC

FAFADIH, NEAR OVER BRIDGE, RUPRELA MARG (SINCE 1937), RAIPUR (C.G.)

Ph.: 0771-4048886, 2888800, Mob.: 9406396296, Email : nmsdiagnostic.service@gmail.com, Website : www.nmsdiagnostics.co.in