

**आयकर विभाग**  
**INCOME TAX DEPARTMENT**  
 भारतीय लेखा संख्या कार्ड  
 Permanent Account Number Card  
**AXMPJ8158P**



**माता / Name**  
 VINA YD HAR DEEPAK JADHAV  
**पिता का नाम / Father's Name**  
 DEEPAK JADHAV

**जन्म की तारीख /**  
 Date of Birth  
 22/12/1992

**हस्ताक्षर / Signature**

**भारत**  
**GOVT. OF INDIA**



12082021

*Shephali*

**Dr. Shephali Bodkhe**  
**MBBS**  
 2006/03/1809

*[Handwritten signature]*

**SUBURBAN DIAGNOSTICS (I) PVT. LTD.**  
 Shop No 22, Ground Floor, Raikar Bhavan,  
 Sector-17, Vashi, Navi Mumbai - 400 703  
 Tel: 27884547 / 27864548

Date:- 19/11/21

CID: 2132327884

Name:- Vinaydhar Jadhav

Sex / Age: 28 / male

**EYE CHECK UP**

Chief complaints:

Systemic Diseases:

Past history:

} Pleam refer "physical examination form" attached

✓ Unaided Vision:

Aided Vision:

Refraction:

	(Right Eye)				(Left Eye)			
	Sph	Cyl	Axis	Vn	Sph	Cyl	Axis	Vn
Distance	-	-	-	6/12	-	-	-	6/6
Near	-	-	-	N6	-	-	-	N6

✓ Colour Vision: Normal / Abnormal

Remark:

As above  
Consult ophthalmologist

**SUBURBAN DIAGNOSTICS (I) PVT. LTD.**  
Shop No 22, Ground Floor, Raikar Bhavan,  
Sector-17, Vashi, Navi Mumbai - 400 703  
Tel 27884547 / 27864548.

*Shephali*  
**Dr. Shephali Bodkhe**  
MBBS  
2006/03/1809

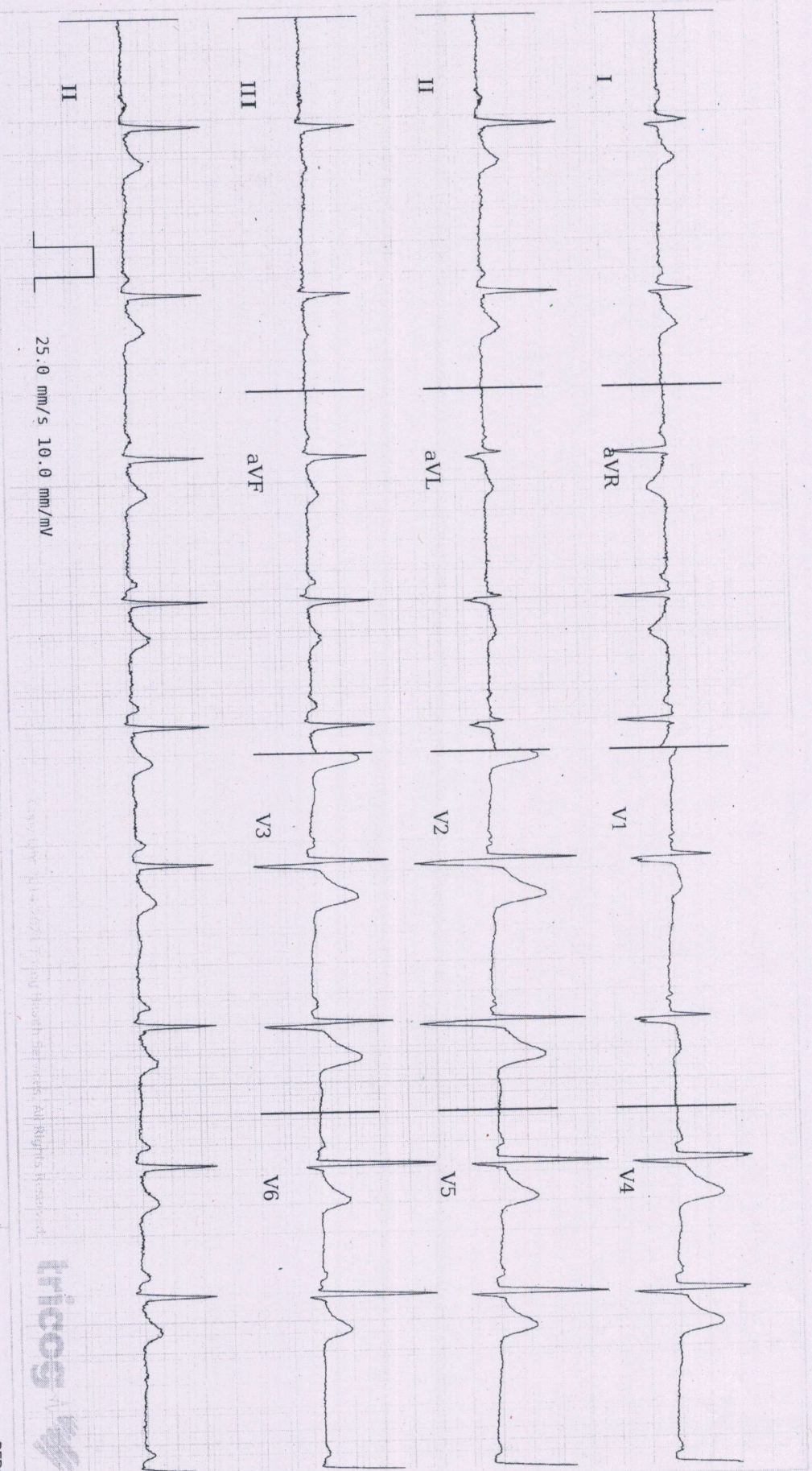
ADDRESS: 2<sup>nd</sup> Floor, Aston, Sundervan Complex, Above Mercedes Showroom, Andheri West - 400053

HEALTHLINE - MUMBAI: 022-6170-0000 | OTHER CITIES: 1800-266-4343

For Feedback - customerservice@suburbandiagnosics.com | www.suburbandiagnosics.com

**SUBURBAN DIAGNOSTICS - VASHI**

Patient Name: **JADHAV VINAYDHAR DEEPAK** Date and Time: **19th Nov 21 11:18 AM**  
 Patient ID: **2132327884**



25.0 mm/s 10.0 mm/mV



Age **28** 10 28  
 years months days

Gender **Male**

Heart Rate **60 bpm**

**Patient Vitals**

BP: **110/80 mmHg**  
 Weight: **86 kg**  
 Height: **180 cm**  
 Pulse: **NA**  
 SpO2: **NA**  
 Resp: **NA**  
 Others:

**Measurements**

OSRD: **96 ms**  
 QT: **380 ms**  
 QTc: **380 ms**  
 PR: **142 ms**  
 P-R-T: **69° 71° 45°**

REPORTED BY

*Dr. Anand N Motwani*

**Dr. Anand N Motwani**  
 M.D (General Medicine)  
 Reg No 39329 M.M.C

**ECG Within Normal Limits: Sinus Rhythm, Normal Axis, with Sinus Arrhythmia. Otherwise. Please correlate clinically.**

Disclaimer: 1) Analysis in this report is based on ECG alone and should be used as an adjunct to clinical history, symptoms, and results of other invasive and non-invasive tests and must be interpreted by a qualified physician. 2) Patient vitals are as entered by the clinician and not derived from the ECG.



CID : 2132327884  
Name : Mr JADHAV VINAYDHAR  
DEEPAK  
Age / Sex : 28 Years/Male  
Ref. Dr :  
Reg.Location : Vashi Main Centre



Reg. Date : 19-Nov-2021 / 11:24

Report Date : 20-Nov-2021 / 10:00

Printed : 20-Nov-2021 / 10:00

### X-RAY CHEST PA VIEW

Both lung fields are clear.

Both costo-phrenic angles are clear.

The cardiac size and shape are within normal limits.

The domes of diaphragm are normal in position and outlines.

The skeleton under review appears normal.

### IMPRESSION:

**NO SIGNIFICANT ABNORMALITY IS DETECTED.**

-----End of Report-----

Dr Shilpa Beri  
MBBS DMRE  
Reg No 2002/05/2302  
Consultant Radiologist



**CID** : 2132327884  
**Name** : Mr JADHAV VINAYDHAR DEEPAK  
**Age / Sex** : 28 Years/Male  
**Ref. Dr** :  
**Reg.Location** : Vashi Main Centre

**Reg. Date** : 19-Nov-2021 / 11:05

**Report Date** : 20-Nov-2021 / 09:52

**Printed** : 20-Nov-2021 / 09:52

## USG WHOLE ABDOMEN

### LIVER:

The liver is normal in size, shape and smooth margins. It shows normal parenchymal echo pattern. The intra hepatic biliary and portal radical appear normal. No evidence of any intra hepatic cystic or solid lesion seen. The main portal vein and CBD appears normal.

### GALL BLADDER:

The gall bladder fossa is empty, consistent with the history of cholecystectomy.

### PANCREAS:

The pancreas is well visualised and appears normal. No evidence of solid or cystic mass lesion.

### KIDNEYS:

Both the kidneys are normal in size shape and echotexture.

No evidence of any calculus, hydronephrosis or mass lesion seen.

Right kidney measures 10.2 x 3.6 cm. Left kidney measures 9.5 x 4.7 cm.

### SPLEEN:

The spleen is normal in size and echotexture. No evidence of focal lesion is noted.

There is no evidence of any lymphadenopathy or ascites.

### URINARY BLADDER:

The urinary bladder is well distended and reveal no intraluminal abnormality.

### PROSTATE:

The prostate is normal in size. It measures 3.6 x 2.6 x 2.3 cm and volume is 11.8 cc.

### IMPRESSION:

**No significant abnormality is seen.**

-----End of Report-----

Dr Shilpa Beri  
MBBS DMRE  
Reg No 2002/05/2302  
Consultant Radiologist