

[Handwritten signature]

DR. P. S. HEALTHCARE CENTRE
NATHAM (S. T. S. B-WING)
42, MUMBAI CENTRAL (S. S.)

R
DR. P. S. HEALTHCARE CENTRE
NATHAM (S. T. S. B-WING)
42, MUMBAI CENTRAL (S. S.)
MMO REG. NO. - 91702

43/F

 भारत सरकार
GOVERNMENT OF INDIA



पिंक्य रसिकलाल परमार
Pinky Rasiklal Parmar
जन्म तिथि/DOB: 30/07/1979
महिला/ FEMALE
Mobile No: 9819807544

8102 6621 0598
VID : 9107 9704 3700 0814



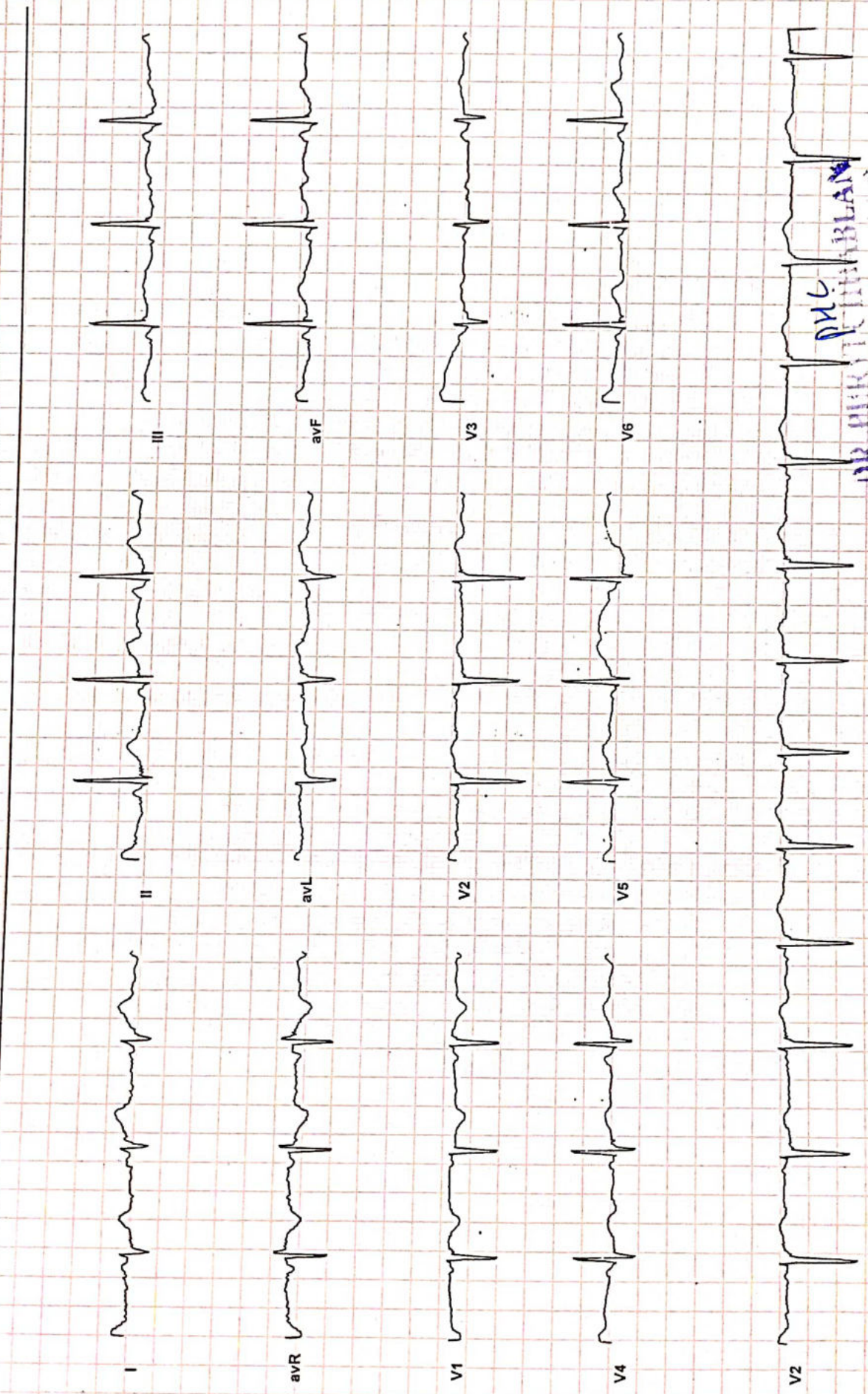
माझे आधार, माझी ओळख

2
Pinky

DR PLUS HEALTHCARE CENTRE- MUMBAI CENTRAL

2265 / PINKY PARMAR / 43 Yrs / F
Heart Rate : 80 bpm / Tested On : 14-Oct-22 10:13:38 / HF 0.05 Hz - LF 100 Hz / Notch 50 Hz / Sn 1.00 Cm/mV / Sw 25 mm/s

ECG



WML

V2 V3 V4 V5 V6
DR. PURV CHHABLANI
M.D. (General Medicine)
Reported By: DR. PURV CHHABLANI
Reg. No. 77607



Patient's Name : PINKY PARMAR

Report Date : 14/10/2022

Referred By : SELF

Age : 43 Years

Sex : FEMALE

X- RAY CHEST

BOTH THE LUNG FIELED ARE CLEAR.

THE HILAR SHADOWS APPEAR NORMAL.

THE COSTO-PHRENIC ANGELS ARE CLEAR.

THE CARDIAC SHADOWS APPEAR NORMAL.

THE TRACHEAL IS CENTRAL IN POSITION.

THE BONY CAGE APPEARS NORMAL.

IMPRESSION : THE ABOVE EXAMINATION IS WITHIN NORMAL LIMITS.

DR. A. J. MAZUMDAR

MD. DMRE, MDRD

DR. PLUS HEALTHCARE CENTRE
NATHANI HEIGHTS, B-WING,
42, MUMBAI CENTRAL (EAST)

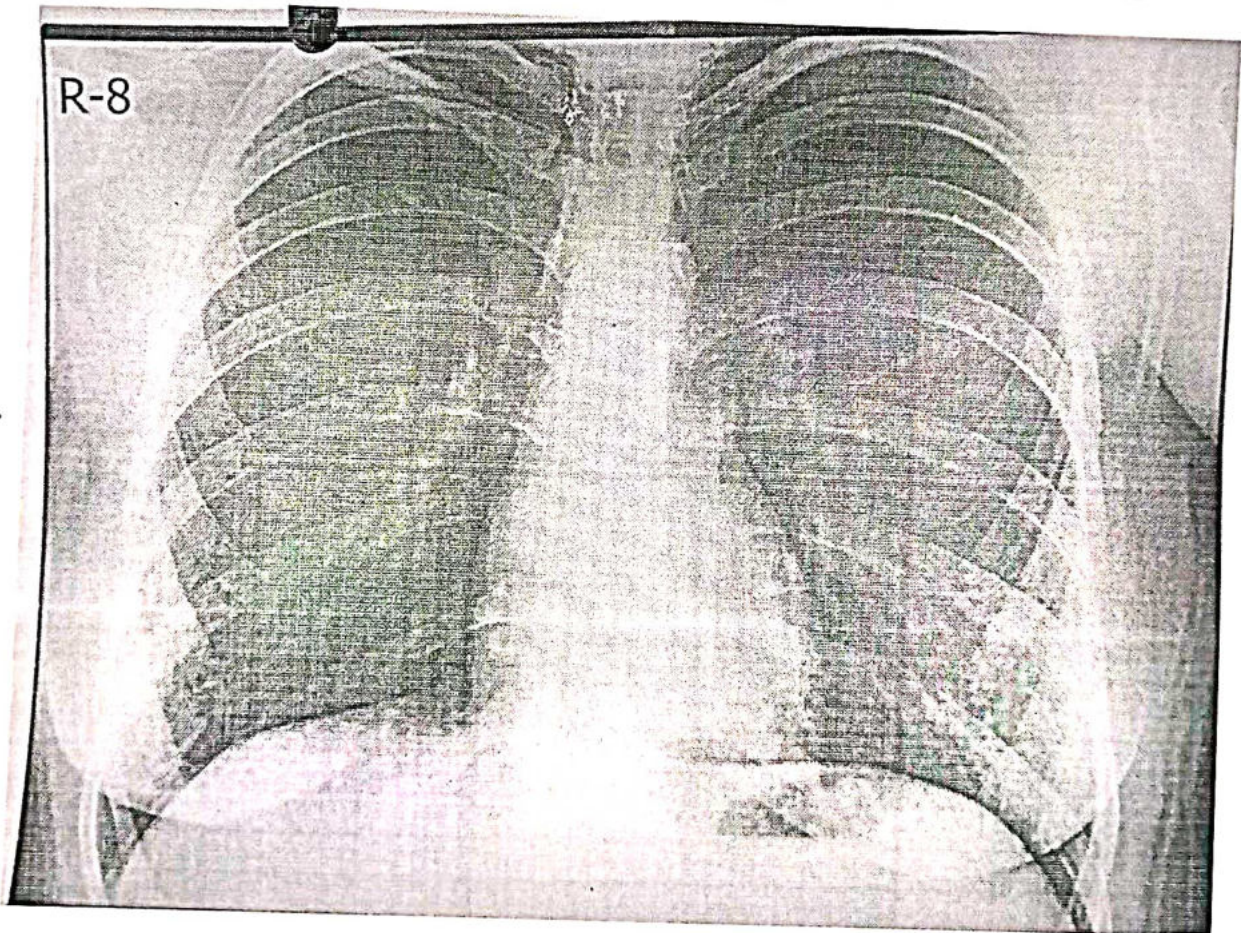
Patient's Name : PINKY PARMAR

Referred By : SELF

Report Date : 14/10/2022

Age : 43 Years

Sex : FEMALE



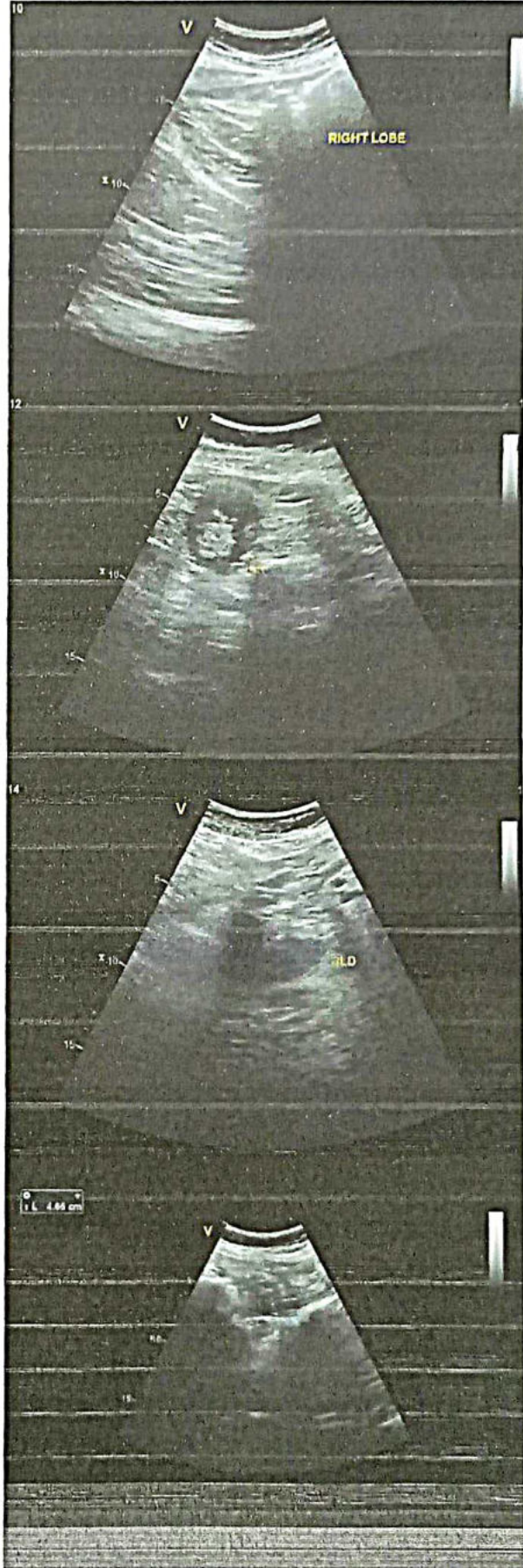
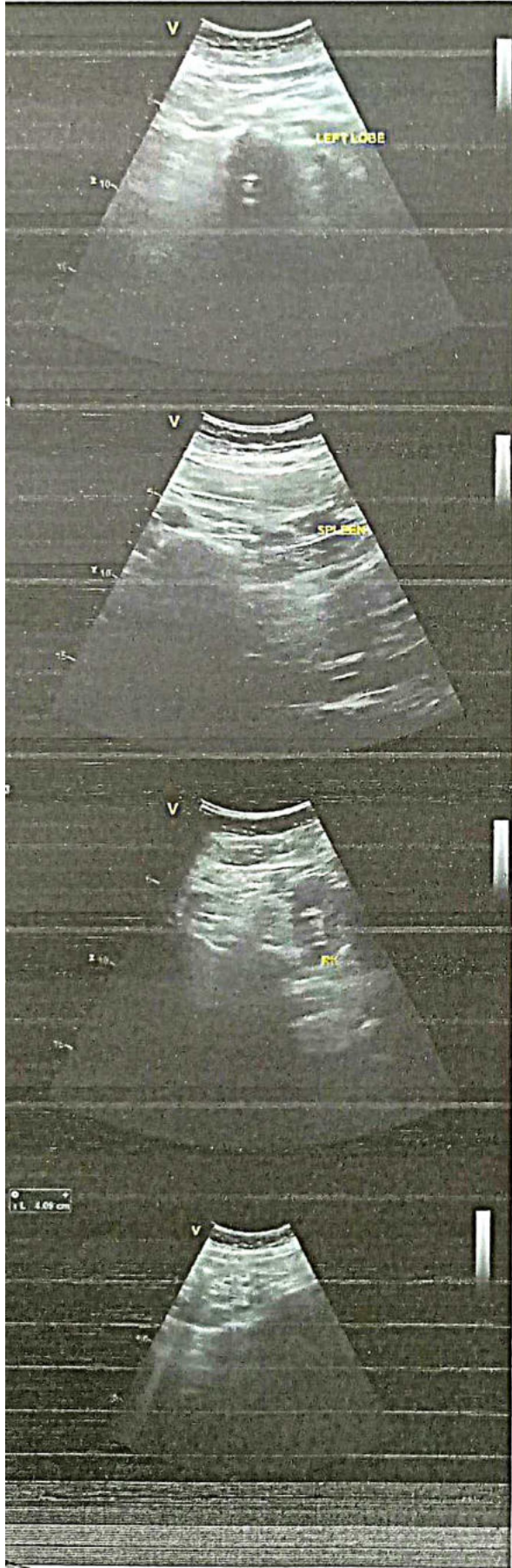
**"DR. PLUS HEALTHCARE CENTRE"
NATHANI HEIGHTS', B-WING,
42, MUMBAI CENTRAL (EAST)**

Jame PINKY PARMAR

Sex Female

Age 43

Date 14/10/2022





Dr-Plus Healthcare Centre

NATHANI HEIGHTS, B-Wing, Shop No. 51, Ground Floor, Opp. Mumbai Central Station (East), Mumbai - 400 008.

Patient Name	:	PINKY PARMAR	Sex:	FEMALE
Doctor's Name	:	DR. HARI CHHABLANI	Age:	43
Date	:	14/10/2022		

ULTRASONOGRAPHY OF THE ABDOMEN AND THE PELVIS:

The relevant sonographic findings include the following:

HEPATOBIILIARY APPARATUS

The liver is normal in size and echogenicity. No obvious focal parenchymal lesion is seen. Intrahepatic biliary radicals are not dilated.

The portal vein and the common bile duct are normal.

GALL BLADDER

The gall bladder is adequately distended. The wall thickness is normal.

No echogenic contents are noted in its lumen. There is no pericholecystic collection noted.

PANCREAS

The pancreas shows normal echogenicity and size.

No focal or diffuse lesions are noted. No evidence of calcification is noted.

SPLEEN

The spleen appears normal in size and echogenicity.

No focal or diffuse lesions are noted. No evidence of calcification is noted.

KIDNEYS

Right kidney measures 9.9 x 4.6 cm, Left kidney measures : 10.0 x 5.0 cm.

Both the kidneys appear normal in size, shape and echogenicity. Both the pelvicalyceal system is normal and both corticomedullary differentiations are well maintained. There is no obvious focal or diffuse lesion noted.

No evidence of any calculus seen in either kidney.

URINARY BLADDER

The urinary bladder shows anechoic contents. Its wall thickness appears normal.

UTERUS

Uterus measures = 5.8 x 2.6 x 3.3 cms.

The uterus is anteverted and normal in size. There are no focal or diffuse lesions noted.

The endometrium appears normal (6.2 mm).

OVARIES

Both the ovaries appear normal in size.

Right ovary measures :5.6 x 3.4 Cm, Left ovary measures :4.8 x 3.3 cm

There is no obvious evidence of abdominal or pelvic lymphadenopathy or ascites.

No other obvious pelvic mass is seen. No probe-tenderness is noted.

IMPRESSION: No significant abnormality is detected.


Dr. VICTOR X. COUTINHO
MBBS, DMRE
Radio-Sonologist

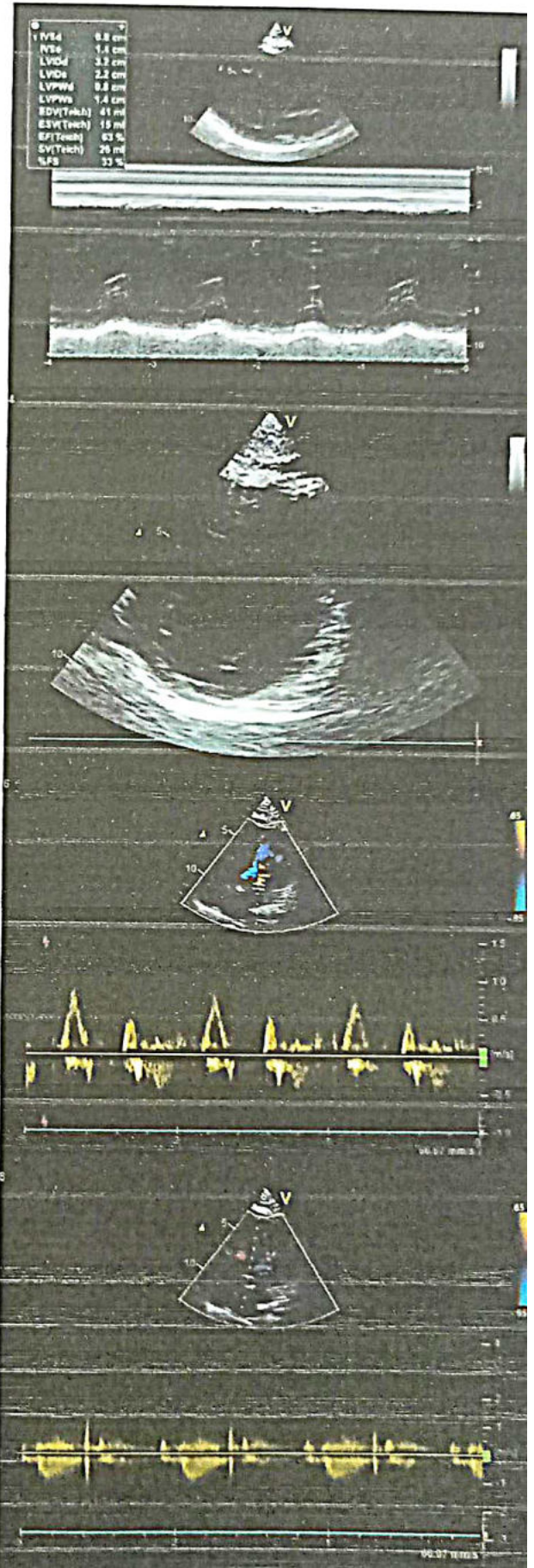
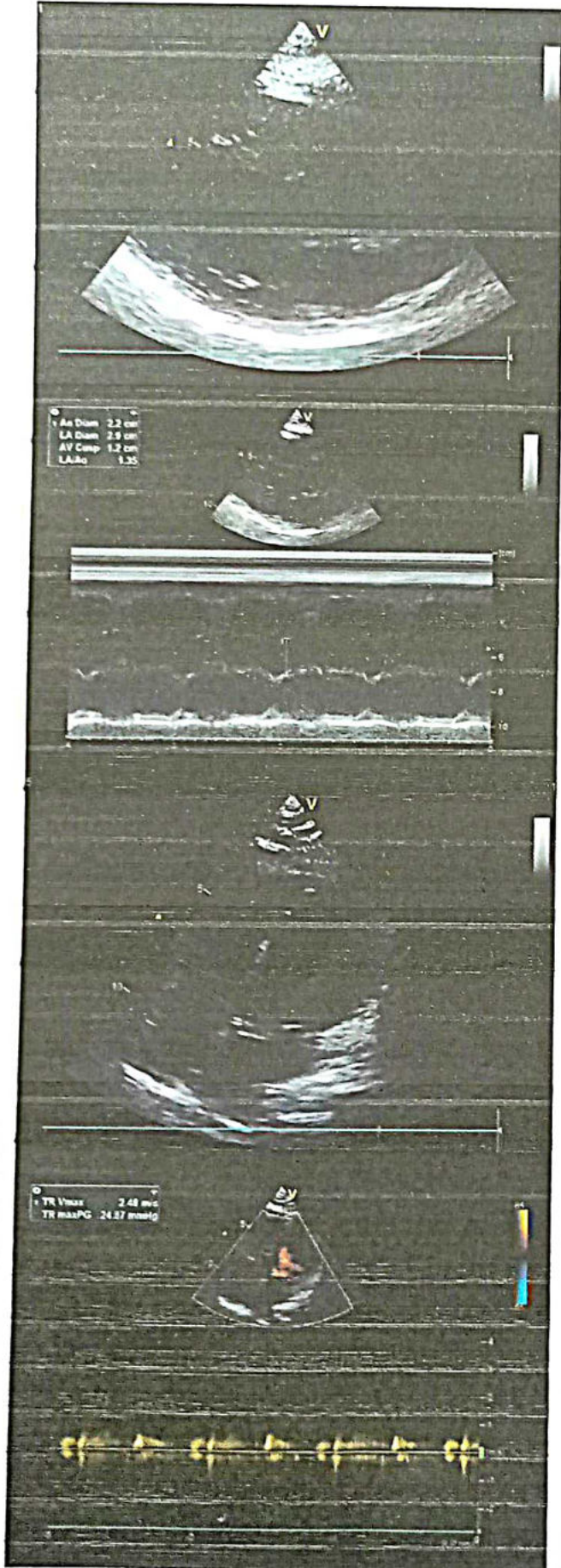
DR. PLUS HEALTHCARE CENTRE
NATHANI HEIGHTS, B-WING,
42, MUMBAI CENTRAL STATION

Name PINKY PARMAR

Sex Female

Age 43

Date 14/10/2022





NAME : PINKY PARMAR

43/F

DATE:14/10/2022

REF BY : SELF

2D-ECHO. AND COLOR DOPPLER REPORT

- NORMAL CARDIAC VALVES WITH TRIVIAL TR.
- NORMAL CARDIAC CHAMBERS
- NO E/O REGIONAL WALL MOTION ABNORMALITY. WITH NORMAL LVEF OF 58 %.
- E/O MILD PULMONARY HYPERTENSION .PASP 37 mmHg by TR jet.
- NO E/O LEFT VENTRICULAR HYPERTROPHY.
- NO E/O DIASTOLIC DYSFUNCTION.
- NO E/O PERICARDIAL EFFUSION.
- NO E/O INTRACARDIAC CLOT OR VEGETATION
- INTACT IAS / IVS

- CONVENTIONL DOPPLER :

E TO A RATIO IS MORE THAN ONE IN LV INFLOW.


THERE IS NO GRADIENT ACROSS AV,LVOT OR RVOT


PASP FROM TR JET IS 37 mm OF Hg.

- COLOUR DOPPLER:

TRIVIAL TR

EF Slope	111	85-120 mm/sec		
Opening Amplitude	21			
Posterior leaflet				
E.P.S.S	02	mm		
Mitral valve prolapse				
Vegetations				
TRICUSPID VALVE	OBSERVED	NORMAL VALUES		
PULMONARY VALVE	OBSERVED	NORMAL VALUES		
EF Slope				
'A' Wave				
Midsystolic notch				
Flutter				
Other Findings				
AORTIC VALVE	OBSERVE	NORMAL VALUES		
Cuspal opening	13	mm		
Closure line	Central			
Eccentricity index	1			
Other Findings				
DIMENSIONS	OBSERVED	NORMAL VALUES		
1. Lvd (Diastolic)	32	26-52		
2. Lvd (Systolic)	24	24-42mm		
3. RVD (Diastolic)	17	7-23mm		
4. IVST (Diastolic)	08	6-11mm		
5. IVST (Systolic)	14			
6. LVPWT (Diastolic)	08	6-11mm		
7. LVPWT (Systolic)	14			
8. Aortic root	22	22-37mm		
9. left Atrium	29	19-40mm		
	STRUCTURE	REGURG GRADING	VELOCITY m/sec	STENOSIS GRADIENT mm/Hg
			Max mean	Peak mean
MITRAL VALVE	NORMAL	0/3	/	/
TRICUSPID VELVE	NORMAL	TRIVIAL	/	/
PULMONARY VELVE	NORMAL	0/4	/	/
AORTIV VALVE	NORMAL	0/4	/	/


DR.P.H.CHHABLANI
M.B.B.S, DNB (MEDICINE)
CONSULTANT PHYSICIAN AND CARDIOLOGIST.


DR. P.H. CHHABLANI
M.B.B.S, DNB (Medicine)
Consultant Physician And Intensive
Reg No 7769F



Dr-Plus Healthcare Centre

NATHANI HEIGHTS, B-Wing, Shop No. 51, Ground Floor, Opp. Mumbai Central Station (East), Mumbai - 400 008.

Full Name PINKY PARMAR 43/F 14/10/2022
Life to be assured:

HAEMOGRAM Normal Range

1.	Red Blood Cell Count	3.8	[M : 4.5 – 5.6/ F : 3.5 – 5.5/cu.mm]
2.	Hb%	11.1	[M: 14-18 / F : 11-16%]
3.	Hematocrit	35.5	[M : 40-53 / F : 30-47 %]
4.	Indices:		
(a)	MCV(Mean Corpuscular Volume)	86.1	[79-101 cu.mi.]
(b)	MCH(Mean Corpuscular Hb)	29.6	[27-32 pg]
(c)	MCHC(Mean Corpuscular Hb Concentration)	33.4	[32-38%]
5.	Morphology		
	Macrocytes : --	Microcytes: --	Hypochromia: --
	Piokilocytosis: --	Anisocytosis: --	
6.	Target cells: --		
	Spherocytes: --	Elliptocytes: --	
7.	TOTALW.B.C.Count	5,400	{4000-1100/cu.mm}
	Differential Count		
a)	Neutrophils :	61	[45 -70%] c) Eosinophils: 04 [01 - 06%]
b)	Lymphocytes :	30	[20 - 45%] d) Monocytes: 05 [00 - 08%]
e)	Basophils :	00	[00 - 01%]
8.	Platelets :2.52		1.5-4.5 Lacks/cu.mm
9.	Erythrocyte Sedimentation Rate:-10	20 mm at end of 1 hour	Method : Westergrens

ROUTINE URINE EXAMINATION (RUA)

1. Physical Examination:

(i)	Colour :	PLAN YELLOW	(ii)	Sediment:	CLEAR
(iii)	Transparency:	CLEAR	(iv)	Reaction:	ACIDIC
(v)	Specific gravity	1.020			

2. Chemical Examination:

(i)	Protein :	NIL	(ii)	Sugar:	NIL
(iii)	Bile salt:	NIL	(iv)	Bile pigment:	NIL

3. Microscopic Examination:

(i)	Red Blood Cells:	ABSENT	(ii)	Epithelial Cells:	2 TO 3/ HPF
(iii)	Crystals:	ABSENT	(iv)	Pus Cells:	2 TO 3/HPF
(v)	Casts:	ABSENT	(vi)	Deposits:	ABSENT
(vii)	Bacteria's :	ABSENT			

DR. ANEESH PATKAR
M.B.B.S. (30.07.07)
No. 2019/03.1000



Dr-Plus Healthcare Centre

NATHANI HEIGHTS, B-Wing, Shop No. 51, Ground Floor, Opp. Mumbai Central Station (East), Mumbai - 400 008.

Full Name

PINKY PARMAR

43/F

14/10/2022

Life to be assured:

	Type of Test	Actual Reading	Normal Range
1	Fasting Blood Sugar	84.6	70-100 mg%
2	PPBS	118.1	110 TO 140 mg%
3	Total Cholesterol	168.0	120-200 mg%
4	VERY LOW DENSINTY LEVEL(VLDL)	20.1	10-30 mg/dl
5	High Density Lipid (HDL)	52.3	40-60 mg%
6	Low Density Lipid (LDL)	95.6	Upto 150
7	S. Triglycerides	127.5	50-150 mg%
8	CHOL/HDL	3.2	Upto 5
9	HDL/LDL	0.5	
10	S. Creatinine	0.9	0.5-1.2 mg%
11	Blood Urea Nitrogen (BUN)	15.4	7-21 mg%
12	BUN/CREAT RATIO	17.1	
13	S. Proteins	6.6	6.0-7.9 mg%
14	(a) Albumin	3.5	3.5-5.5 mg%
15	(b) Globulin	3.1	2.0-3.5 mg%
16	A/G RATIO	1.1	
17	S. Bilirubin	1.0	0.3-1.3mg%
18	(a) Direct	0.6	0.0-0.8 mg%
19	(b) Indirect	0.4	0.0-0.5 mg%
20	SGOT (AST)	24.6	05-34 IU
21	SGPT (ALT)	29.4	05-40 IU
22	GGTP (GGT)	34.5	05-50 IU
23	SGOT/SGPT	0.8	
24	HBA1C	5.4	UPTO 6.5
25	S. Alkaline Phosphatase	95.2	30-115 IU
26	T3	124.4	80-180ng/dl
27	T4	6.9	4.6-12 ug/dl
28	TSH	3.6	0.4-4.0 mIU/L
29	SERUM URIC ACID	6.6	2.5-7.2mg/dl
30	URINE SUGAR PP	ABSENT	
31	URINE SUGAR FASTING	ABSENT	
32	BLOOD GROUP	"O POSITIVE "	

DR. RAJESH PATKAR
M.D., D.N.B. (Pathology)
Reg. No. 2013/05/1660



ATTACHED TO : Wockhardt Hospital • Saifee Hospital • Apollo Spectra Hospital

NATHANI HEIGHTS, B-Wing, Shop No. 42, Ground Floor, Opp. Mumbai Central Station (East),
Mumbai - 400 008. • Cell : 98206 46163 • E : drharichhablani@gmail.com

PHYSICIAN REPORT

DATE : 14/10/2022

NAME : PINKY PARMAR 43/F

PRESENTING COMPLAINS : NIL .

PAST HISTORY :NIL

FAMILY HISTORY: NOT SIGNIFICANT.

TREATMENT : NIL

HABITS: NIL

HT.- 159 CM. WT.- 59 Kg. BMI.-23

P: 80 MIN ., REGULAR BP: 120/80

EYE EXAMINATION : NEAR VISION -B/E- N6 , DISTANT VISION -B/E -6/6 COLOR VISION : NORMAL

RS: CLEAR

CVS: S1,S2 REGULAR

PA: SOFT

CNS: CLINICALLY NAD

ENT EXAMINATION : WNL

LABS: ATTACHED

2-D- ECHO : ATTACHED

ECG: ATTACHED


X-RAY : ATTACHED

USG : ATTACHED

IMPRESSION : : FIT ON CLINICAL MEDICAL EXAMINATION .


DR. HARI CHHABLANI
M.B.B.S., F.C.C.P. (RESP. MED.), PGDHHM, PGDMLS
FELLOW INTENSIVE CARE
MRC REG. NO. - 91702



 GPS Map Camera

Mumbai, Maharashtra, India

Shop No 65, Nathani Heights, Marzban Parsi Colony, Dalal Estate, Mumbai Central, Mumbai, Maharashtra 400008, India

Lat 18.968779°

Long 72.819972°

14/10/22 09:22 AM GMT +05:30

