

MRS. ARCHANA PATEL

33 YEARS /FEMALE

BOB

10-12-2022

Height: 160 Cms

Weight: 64 Kg

BP: - 104/70 mmhg

Pulse: - 97/- Regular

BMI: - 25 kg/m²

EYE: - NORMAL

The Medical Examiner should record the findings under one of the following categories:-

1. FIT
2. UNFIT on account of



Dr. P. S. Chhabra
M.B.B.S., M.D.
Reg. No. 5097

P. S. CHHABRA

MBBS. MD.

4D SONOGRAPHY • COLOR DOPPLER • ECHO • PATHOLOGY • DIGITAL X-RAY & OPG • TMT • ECG • HOLTER

MRS. ARCHANA PATEL
BANK OF BARODA34 Years /F
10-12-2022**LIPID PROFILE**

Test Name	Results	Normal Range
TOTAL LIPIDS	490	400 - 700 mg/dl
CHOLESTROL	151.0	<200 mg/dl- Desirable 200 - 239 mg/dl - Borderline High >240 Mg/dl High
HDL CHOLESTROL	40.0	35- 60 mg/dl
TRIGLYCERIDE	138.0	<150 mg/dl Normal 150 - 199 mg/dl Borderline High 200 - 499 mg/dl High
LDL CHOLESTROL	83.4	<100 mg/dl Optimal 100- 129 mg/dl Borderline high 160 - 189 mg/dl High
VLDL CHOLESTROL	27.6	<40 mg/dl
RISK RATIO	3.78	3 - 6

Dr. POOJA PRAPANNA
MD
DR. POOJA PRAPANNA
M.D.

MRS. ARCHANA PATEL

34 Years /F

BANK OF BARODA

10-12-2022

HEAMOGRAM

Test Name	Results	Normal Range
Haemoglobin (HB)	12.3	11 - 16 gm%
R.B.C. Count	4.93	3.8 - 4.8 milli./cu.mm
PCV	36.9	36 - 46 %
MCV	74.85	80 - 98 fl
MCH	24.95	27 - 32 pg
MCHC	33.33	31.5 - 34.5 %
TOTAL WBC COUNT	6,600	4,000 to 11,000 /cu.mm
DIFFERENTIAL WBC COUNT	.	
Neutrophils	69	40 - 75 %
Lymphocytes	27	20 - 40 %
Monocytes	02	02 - 08 %
Eosinophils	02	01 - 05 %
Basophils	00	00 - 01 %
PLATELET COUNT	2.71	1.5 - 4 Lacs/cu.mm.
E.S.R	9	M- 0-10 at the end of 1 hr. F- 0-20 at the end of 1 hr

Dr. POOJA PRAPANNAMD
DR. POOJA PRAPANNA

M.D.

Pt. Name: **MRS. ARCHANA PATEL**
Ref. By: **BANK OF BARODA**

Age/Sex: **34 Yrs /F**
Date: **10/Dec/2022**

CYTOPATHOLOGY

Material Received :- 1 Pap Smear Prepared.

Smear adequacy :- Satisfactory.

Fair number of superficial and intermediate squamous epithelial cells

Endocervical cells: Seen, with squamous metaplastic cells

Organism: Altered flora (coccobacilli seen)

Inflammatory cells :- Moderate Acute inflammatory cells seen.

Negative for intraepithelial lesion or malignancy

Impression: Features are suggestive of Bacterial Vaginosis

Advise: Follow up

Dr. POOJA PRAPANNA
MD

MRS. ARCHANA PATEL

34 Years /F

BANK OF BARODA

10-12-2022

BIOCHEMISTRY

Test Name	Results	Normal Range
SERUM BILIRUBIN	:-	
TOTAL BILIRUBIN	0.83	0 - 1 mg/dl
DIRECT BILIRUBIN	0.14	<0.25 mg/dl
INDIRECT BILIRUBIN	0.69	< 1.0 mg/dl
S.G.O.T	16.0	0 - 45 IU\L
S.G.P.T	20.0	0 - 45 IU\L
ALKALINE PHOSPHATE	97.0	Adult - 42 - 128 IU/L Child - 150 - 630 IU/L
TOTAL PROTEIN	7.21	6.0 to 8.0 g/dl
ALBUMIN	4.35	3.2 to 5.0 g/dl
GLOBULIN	2.86	1.9 to 3.5
A:G RATIO	1.52	1.2 TO 2.3
GAMA GT	13.0	5 - 43 Iu/l

Dr. POOJA PRAPANNA
MD
DR. POOJA PRAPANNA
M.D.

4D SONOGRAPHY • COLOR DOPPLER • ECHO • PATHOLOGY • DIGITAL X-RAY & OPG • TMT • ECG • HOLTER

MRS. ARCHANA PATEL

34 Years /F

BANK OF BARODA

10-12-2022

Test Name	Results	Normal Range
-----------	---------	--------------

SEROLOGY PROFILE

HBsAg Non Reactive

* Test done by screening methods.
Requires confirmation at referral
centre.

BIOCHEMISTRY

FASTING BLOOD SUGAR	228.0	70 - 110 mg/dl
P.P. BLOOD SUGAR	277.0	upto 140 mg/dl
BUN	14.0	5 - 21 Mg/dl
URIC ACID	4.65	2.5 - 6.8 mg/dl
CREATININE	0.91	0.6 - 1.4 mg/dl

Dr. POOJA PRAPANNA
MD
DR. POOJA PRAPANNA
M.D.

4D SONOGRAPHY • COLOR DOPPLER • ECHO • PATHOLOGY • DIGITAL X-RAY & OPG • TMT • ECG • HOLTER

MRS. ARCHANA PATEL

34 Years /F

BANK OF BARODA

10-12-2022

URINE EXAMINATION

Test Name	Results	Normal Range
PHYSICAL EXAMINATION		
Quantity	30 ml	.
Colour	Pale Yellow	.
Appearance	Clear	.
Deposits	Absent	.
Specific Gravity	1.015	.
Reaction	Acidic	.
CHEMICAL EXAMINATION		
Albumin	Nil	.
Sugar	Present +++	.
Ketones	Absent	.
Bile Pigments	Negative	.
Bile Salt	Negative	.
Hematuria	Negative	.
MICROSCOPIC EXAMINATION		
Pus Cells	1- 2 /hpf	.
Red Blood Cells	Nil/hpf	.
Epithelial Cell	1 - 2 /hpf	.
Crystals	Nil	.
Casts	Absent	.

Dr. POOJA PRAPANNA
MD
DR. POOJA PRAPANNA
M.D.

4D SONOGRAPHY • COLOR DOPPLER • ECHO • PATHOLOGY • DIGITAL X-RAY & OPG • TMT • ECG • HOLTER

MRS. ARCHNA PATEL

34 Yrs./F.

BOB

10th Dec, 2022

X-RAY CHEST PA VIEW

Bony cage is normal.

Trachea is central.

C.P. angles are clear.

Cardiac contour and cardiothoracic ratio are normal.

Lung fields are clear.

DR.D.S.CHHABRA.

M.D.

MRS. ARCHANA PATEL

34 Yrs./F.

BOB

10th Dec, 2022

ABDOMINAL SONOGRAPHY

Liver is of normal size, shape, has smooth margins & regular contours and the parenchyma is mildly hyperechoic in echostructure, **fatty changes (Grade I)**. No focal lesion.

Gall bladder is of normal size, shape, has thin walls & the contents are clear fluid. No evidence of any calculus. Biliary tree is undilated.

Pancreas is normal, no focal / diffuse pathology. Spleen is normal. The Portal and splenic veins are normal in calibre.

Both Kidneys are normal in size [measure about 10.5 cms. in length], shape and echostructure. No calculus in both. The collecting system and ureter on both side are undilated.

Urinary bladder is normal in size, shape and has thin walls.

Uterus is of multiparous size [measures about 9 x 5.5 x 4 cms. in diam.] and is normal in shape. The uterine outlines are smooth & regular and the myometrial & endometrial echopattern is normal. No mass.

Both ovaries are normal in size, shape and echostructure.

No adnexal / pelvic mass or cyst. No localised or free pelvic collection.

There is no ascitis. No obvious abdominal lymphadenopathy. No sub / supra diaphragmatic pathology on either side.

IMPRESSION:

Fatty changes in liver (Grade I).



DR.D.S.CHHABRA.

M.D.




आर्यना पटेल
 Archana Patel
 जन्म तिथि/DOB: 03/07/1988
 महिला/ FEMALE

Issue Date: 14/03/2011





7273 9393 7039
 VID : 9115 6121 8426 5718
 मेरा आधार, मेरी पहचान

Archana Patel

7030291546

Dr. D. S. Chhabra
 Dr. Mahesh B. Bis. M.D. (Cardio)
 Reg. No. 5007





भारतीय विशिष्ट पहचान प्राधिकरण
 Unique Identification Authority of India

पता: नरेश सिंह पटेल, 296, 13, यादव कालोनी, कामथ
 वार्ड, नरसिंहपुर, नरसिंहपुर,
 मध्य प्रदेश - 487001

Address:
 C/O: Naresh Singh Patel, 296, 13, yadav
 colony, kamth ward, Narsinghpur,
 Madhya Pradesh - 487001

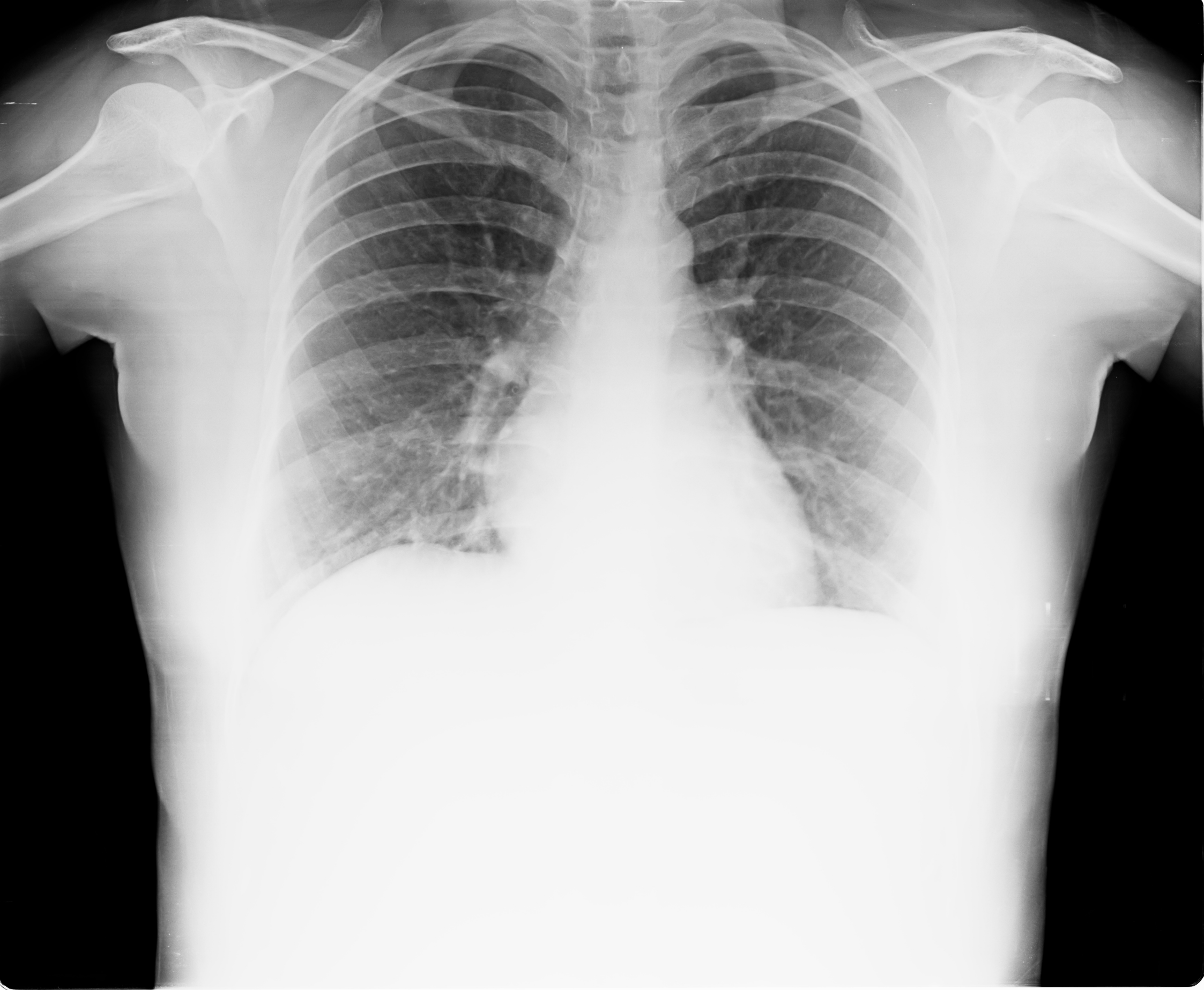Download Date: 29/05/2022



7273 9393 7039
 VID : 9115 6121 8426 5718

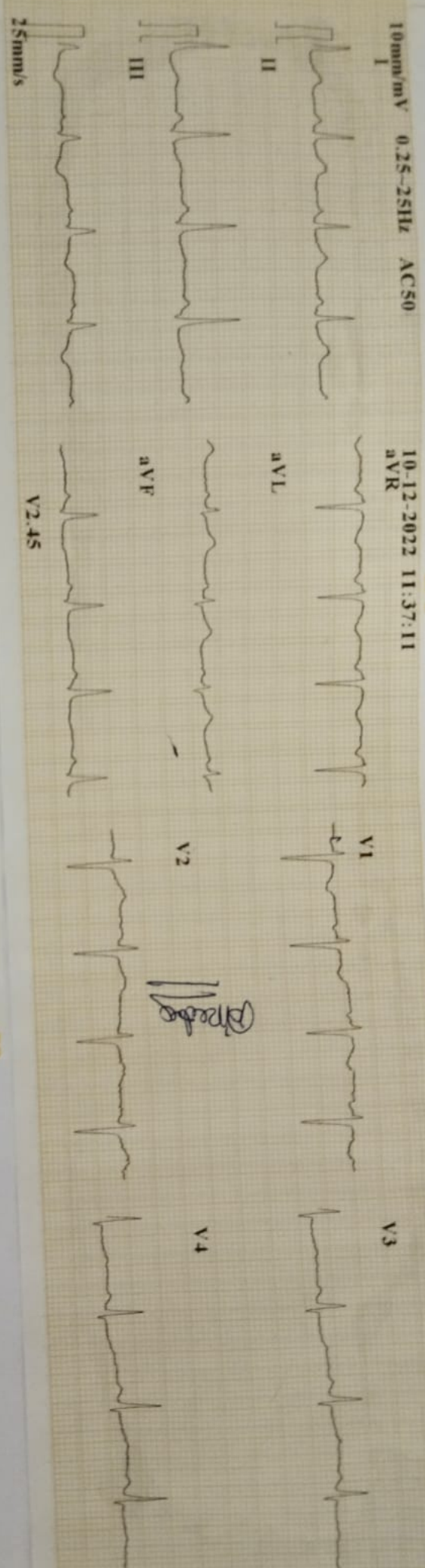
1947 | help@uidai.gov.in | www.uidai.gov.in





10-12-2022 11:37:11
aVR

BpL



33 IF

ID : 221210-1137
 Name :
 Age : 33 yr
 Sex : Female
 BP :
 Height : cm
 Weight : kg

HR : 94 bpm
 P Dur : 91 ms
 PR int : 128 ms
 QRS Dur : 95 ms
 QT/QTc int : 357/447 ms
 P/QRS/T axis : 39/52/-4 °
 RV5/SV1 amp : 0.881/0.931 mV
 RV6/SV2 amp : 1.812 mV
 : 1.013/0.852 mV

Minnesota Code:
 5-5-0(II,V6)
 9-4-1(V3)

Diagnosis Information:
 800: Sinus Rhythm
 Normal ECG

Report Confirmed by:

Handwritten signature
 Dr. Mahendra Chourasiya
 M.D., D.M. (Cardio)



Mrs. Archana