

NAME: MR. SACHIN JAWARKAR	DATE: 14/04/2023
AGE/ SEX: 36 YEARS/ MALE	REFERRED BY: HEALTH CHECKUP
<u>ULTRASOUND ABDOMEN &amp; PELVIS</u>	

**Clinical profile- Health checkup**

**Liver:** Normal in size (11.4 cm), shape and shows normal echotexture. No evidence of any space occupying lesion seen. Intrahepatic biliary radicals are not dilated. Portal vein is normal in caliber.

**Gallbladder:** GB is partially distended. No evidence of any calculus seen. No wall thickening/pericholecystic fluid collection noted. CBD is normal in caliber.

**Pancreas:** Head & part of the body is visualized, appears normal in bulk & echotexture. Rest of the pancreas is obscured by bowel gases.

**Spleen:** Appears normal in size (8.4 cm), shape and echotexture. No calcification or mass is seen. Splenic vein is not dilated.

**Kidneys:** Right kidney – 9 x 3.4 cm. Left kidney – 9.7 x 5.5 cm.

Both kidneys are normal in size, shape, positions and echotexture. Bilateral corticomedullary differentiation appears normal. No hydronephrosis seen. No evidence of any calculus or mass lesion seen.

**Urinary Bladder:** is well distended. No evidence of calculus/ wall thickening noted.

**Prostate** is normal in size and echotexture.

**Free fluid:** No evidence of any free fluid in peritoneal cavity.

**IMPRESSION:**

No significant abnormality seen.

Clinical correlation is suggested.

DR TRIPTI PAREEK  
(DNB RADIOLOGIST)

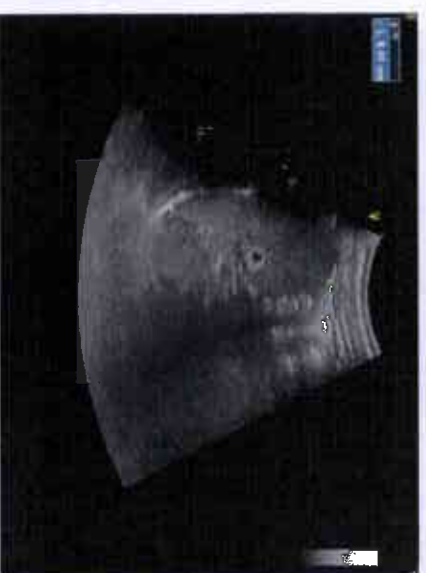
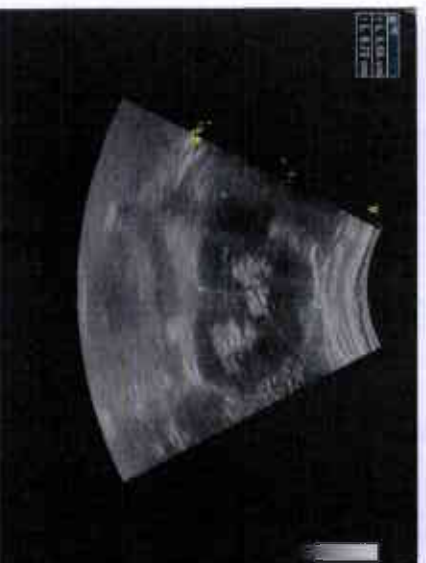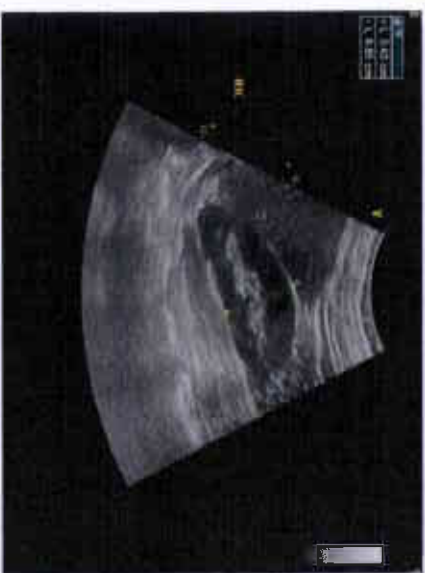
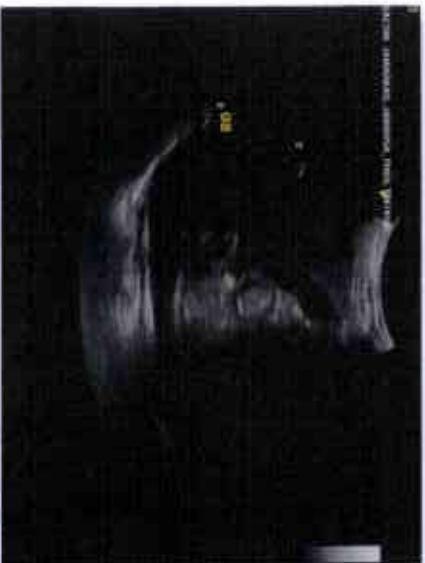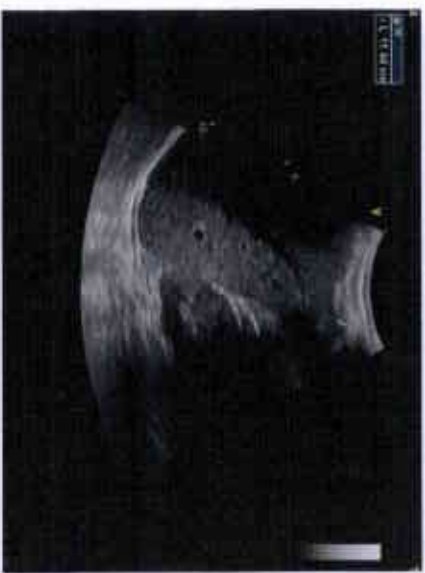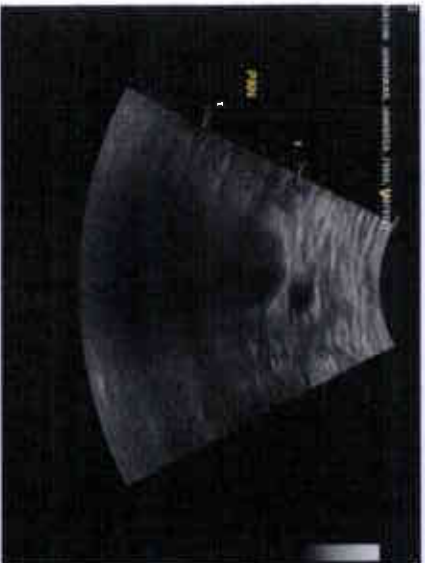
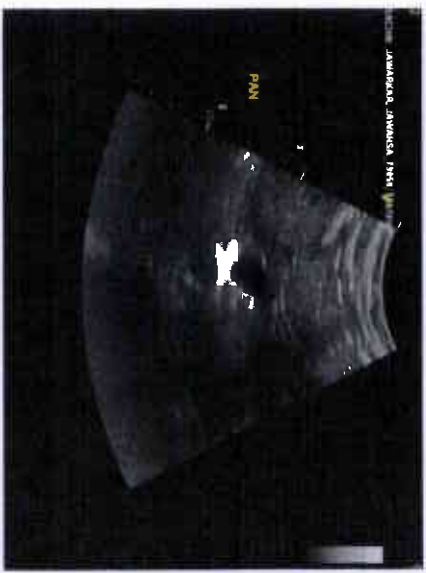
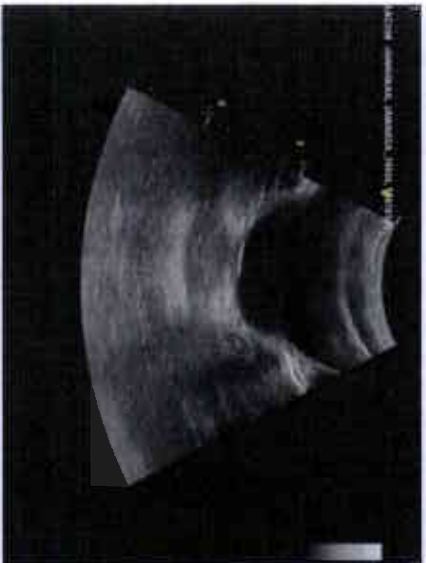
**MAGNUM MULTISPECIALTY HOSPITAL  
NASIK ROAD, NASHIK**

**Name JAWARKAR, SACHIN**

**Sex Male**

**Age 36**

**Date 14/04/2023**



DATE :-

HEIGHT -

WEIGHT:-

S/B DR. JAYDEEP BHAMBARE

veg predominant

PATIENT NAME :- Sachin Jambekar

AGE /SEX:- 36 / m



dermat opinion

\_\_\_\_\_

80% | 100% flc.

②

Eye disease.

keratosis (1A) x 15x  
 100% — m — 100%

30% — 70% — kind.

Tupid IT of

15x .x } Paronychia DR. of

diel

**PATIENT NAME: - SACHIN JAWARKAR**

**AGE/SEX- 36 YRS / M**

**DATE :-14/04/2023**

**REF:- MEDIWHEEL HEALTH-CHECK UP**

Normal LV Size & Function

No regional wall motion abnormality.

**Normal LV & RV systolic function. LVEF-60%.**

No S/o Diastolic Dysfunction.

Left atrium is normal.

Normal RA and RV size and shape.

Normal RV systolic function.

PASP - 20mmHg


No Pulmonary Hypertension.

IVC Collapsing with respiration. No Clot/Vegetation.

IVS and IAS are intact.

Normal pericardium. No effusion.

**IMPRESSION:- Good LV Function with LVEF- 60%**



**DR. RAHUL SHEWALE**  
M.D. (Medicine)  
D.M. (Cardiology)  
Consultant Cardiologist  
Regd. No. 2010041390



NAME: MR. SACHIN JAVARKAR	DATE: 14/04/2023
AGE/ SEX: 36 YEARS / MALE	REFERRED BY: HEALTH CHECKUP

**XRAY CHEST PA (VIEW)**

Both the lungs are clear and do not show any obvious focal lesion.

Bilateral costo-phrenic and cardio-phrenic angles appear clear.

There is no evidence of pleural effusion or pneumothorax on either side.

Both the hilum appear normal.

Dornes of diaphragm have normal contours and positions.

Visualised bones and soft tissues reveal no abnormality.

**CONCLUSION:**

No significant abnormality is seen.

Advise clinical correlation.

  
**DR TRIPTI PAREEK**  
(DNB RADIOLOGIST)