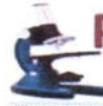

**Facilities:**

All clinical Biomedical & Hematology Investigations including Bone Marrow Examination  
VPT, Podiascan & Complete Foot Care (First Time in Purvanchal)  
All Hormonal Investigation by Chemiluminescent Method  
Visceral Fat by (AB-140) Ambulatory BP Monitoring  
CGMS & Insulin Pump Available  
PFT, 2D-ECHO (Color Doppler), Holter, TMT, Cardiac-3 available  
VIA, VILI, Colposcopy available  
Special Endocrinological Investigation Protocols.

ISO 9001:2008 Certified  
Mobile: 9389994334, 9554572190, 9453837595



# Panacea Pathology

## Clinical Reference Lab

Persistence, Preparedness and Precision  
EQAS (CMC Vellore Attached) & IQAS System  
पूर्वाचल की सर्वोत्तम गुणवत्ता वाली पैथोलॉजी

PATIENT NAME : HARSHWARDHAN JAISWAL

AGE/GENDER : 35YRS/MALE

REFD BY DR. : ARCO FEMI HEALTHCARE LTD.

RECEIVED DATE : 14-04-2023 (12:00PM)

SAMPLE : BLOOD & URINE

REPORT DATE : 15-04-2023 (05:00PM)

### PATHOLOGY REPORT

#### COMPLETE BLOOD COUNT (CBC)

TEST	LAB TEST VALUES	NORMAL RANGE
<b>HEMOGRAM</b>		
HEMOGLOBIN (FLOW CYTOMETRY)	13.1	13 – 16 gm/dl
TOTAL LEUCOCYTE COUNT (TLC)	5,000	4000 – 11000
RBC COUNT	4.64	3.5 – 5.5
PCV (HCT)	42.4	37 – 47
MCV	91.5	80 – 95
MCH	28.2	28 – 34
MCHC	30.8	30 – 36
PLATELET COUNT	1,50,000	1,50,000 – 4,00,000
E.S.R. (WINTROBE FIRST HOURS)	18.0	20 mm/1 <sup>st</sup> hr
<b>DIFFERENTIAL LEUCOCYTE</b>		
NEUTROPHILS	59	40 – 75%
LYMPHOCYTES	33	20 – 45%
EOSINOPHILS	04	1 – 6%
MONOCYTES	04	2 – 8%
BASOPHILS	00	< 2%

#### RANDOM/FASTING BLOOD SUGAR

TEST	LAB TEST VALUES	NORMAL RANGE
<b>RBS/FBS</b>		
FASTING BLOOD SUGAR	95.0	70-125 mg/dl
RANDOM BLOOD SUGAR	108.0	125-140 mg/dl

#### GLYCOSYLATED HEMOGLOBIN (HBA1C)

TEST	LAB TEST VALUES	NORMAL RANGE
HBA1C	5.0	Normal : <5.97 % Good Control : 5.97 – 6.81% Fair Control : 6.81 – 7.65% Poor Control : >7.65%

PAGE 1

Lab Technician

**PANACEA HOSPITAL**  
(A UNIT OF M.D. Pathology PVT. LTD.)  
REG. NO. : AL-1500

Timing : 8.00 a.m. to 9.00 p.m. (Sunday 8.00 a.m. to 3.00 p.m.)

This Report is not valid for medico-legal purpose

**Note:** These tests have technical limitations. Clinico-pathological interpretation is necessary. In case of any disparity test



# PANACEA HOSPITAL

B 36/44 F.K KABIR NAGAR, DURGAKUND  
TOLLFREE NO-18001233070.  
Whatsapp No - 8795832852  
www.piire.org



## OP Slip

Print Date : 14-Apr-2023 01:46PM



<b>UHID No</b> :- UD-23240000205	<b>OP No</b> :- OP-23240000678	<b>OP Date</b> :- 14 Apr 2023 12:08PM
<b>Patient Name</b> :- Mr HARSHWARDHAN JAISWAL BOB	<b>Age/Sex</b> :- 35 Y/Male	<b>Mobile No</b> :- 8707716491
<b>Father</b> :- AJIT KUMAR JAISWAL	<b>Department</b> :- DIABETES, ENDOCRINOLOGY & METABOLIC PHYSICIAN	
<b>Pay Type</b> :- Cash	<b>Consultant</b> :- Dr ASHUTOSH MISHRA (MD(MEDICINE), IMS, BHU)	
<b>Token No</b> :- NOR. - 25	<b>Paid/Bal</b> :- 0.00 /500.00	
<b>Patient Type</b> :- Normal		
<b>Address</b> :- B 16/14 PANDEY HAVELI ,varanasi		

BP :- 110/80  
height :- 177  
Weight (kg) :- 89.9  
BMI :-

SPO2 - 96  
PR - 68  
WC - 105  
NC - 39

### Rx

Pre-Diabetes  
COPD

As. wt loss diet involved.

Tab. Diabemus (10) OH

Rev. Amlu PR (20)

Tab. Rosuvastatin (20) OH

R/A 1 month

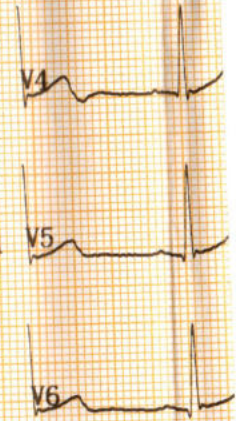
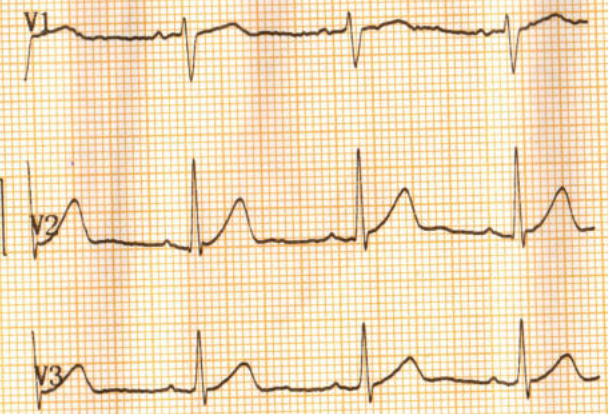
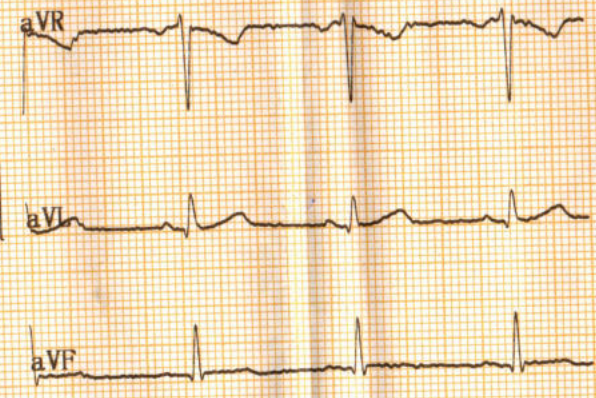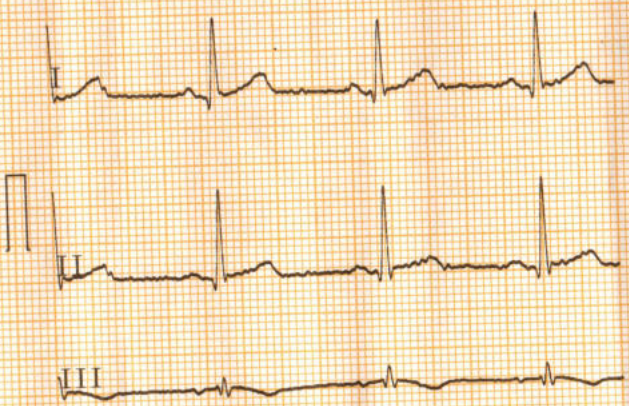Printed By : Mr NITIN YADAV  
Created By : Mr NITIN YADAV

AUTO 10mm/mV

10mm/mV

10mm/mV

10mm/mV



25mm/s AC50Hz+EMG35Hz+DFT

CARDIART



# PANACEA HOSPITAL

*A shelter for many hearts A Home for many lives*

(An ISO 9001:2008 Certified Organisation)  
Lab Attached with CMC Vellore Under EQAS Scheme

PATIENT'S NAME : HARSHWARDHAN JAISWAL

AGE/SEX: 35 Y/M

REF. BY : Dr. ASHUTOSH MISHRA (MD)

Friday, April 14, 2023

## Echo - Cardiography

MITRAL VALVE Doppler	AML - normal morphology MV Flow - E - 0.6 A-0.4 E/A=1.69	PML - normal morphology MVA - 3.0 cm <sup>2</sup> Mitral Regurgitation - <b>No</b>
TRICUSPID VALVE Doppler	Normal TV Flow -No	Tricuspid Regurgitation - <b>No</b>
PULMONARY VALVE Doppler	Normal PV Flow -No	Pulmonary Regurgitation - No
AORTIC VALVE Doppler	Trileaflet-No AV Flow - no	Aortic Regurgitation - no
MEASUREMENT	Aorta - 38.8 (20-38) mm IVS ed - 14.8 (6-12) mm LVID ed -49.7 (35 - 55) mm LVPW ed - 14.8 (6-12) mm, OA - 7 (> 5) mm	LA - 34.3 (24-32) mm IVS es -13.1 (6 - 12) mm LVID es - 37.1 (24 - 40) mm LVPW es -10.3 (6-12) mm EPSS - 4 (< 9) mm

**CONCLUSION**

All cardiac chamber dimensions are WNL  
No valvular abnormalities  
Normal LV systolic function present Modified Simpson's method (4C, 2C) (LVEF=50%)  
No diastolic dysfunction present (E/A = 1.69) by tissue Doppler (E/e'=6.2)  
No RWMA  
No pericardial effusion  
Intact IAS / IV  
No PAH  
No intra cardiac mass /thrombus /vegetation

**IMPRESSION** **Normal Echocardiogram**

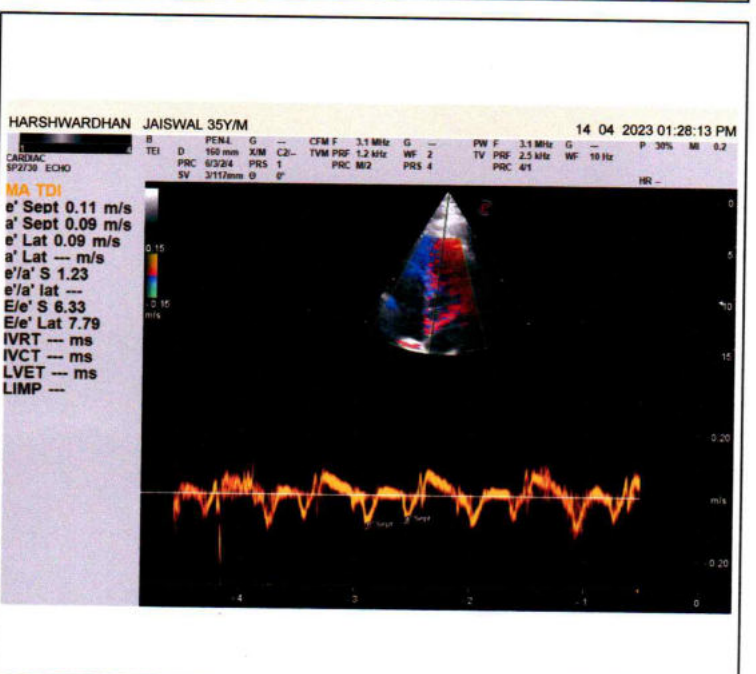
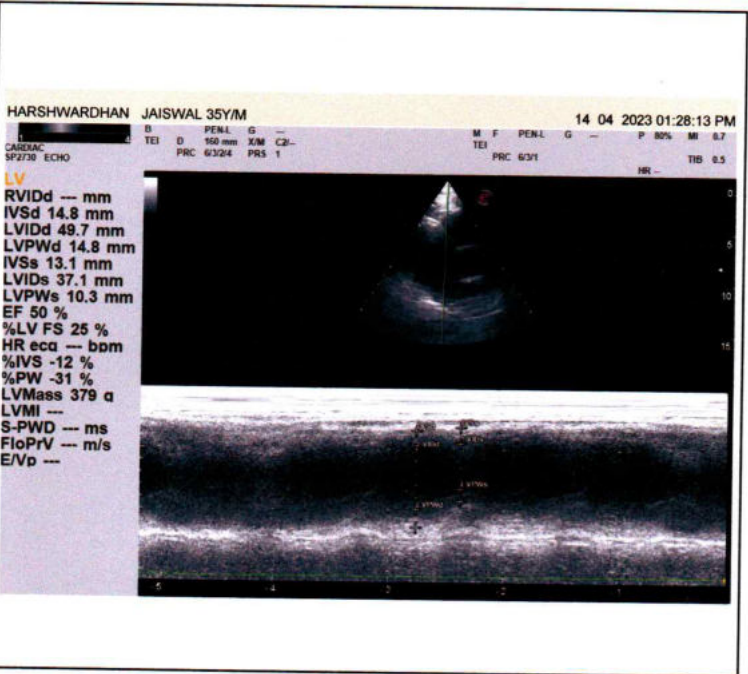
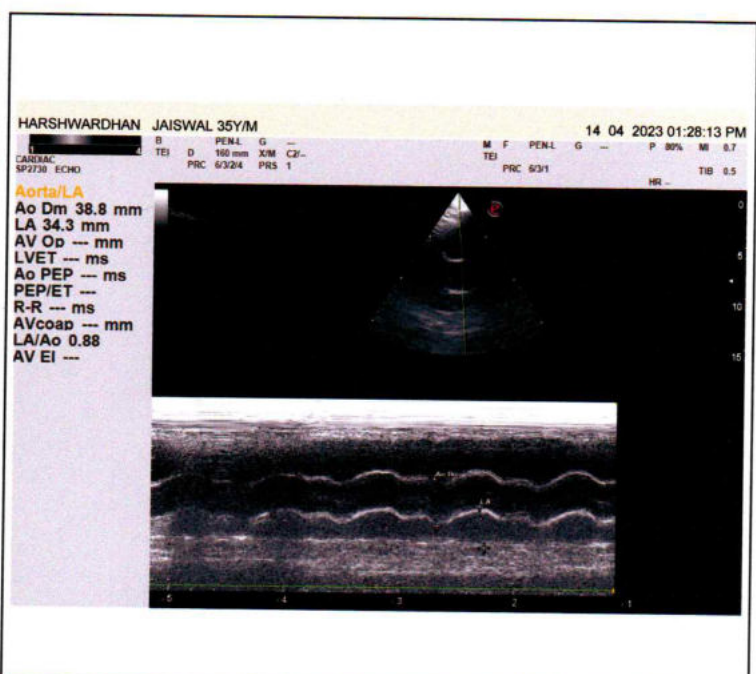
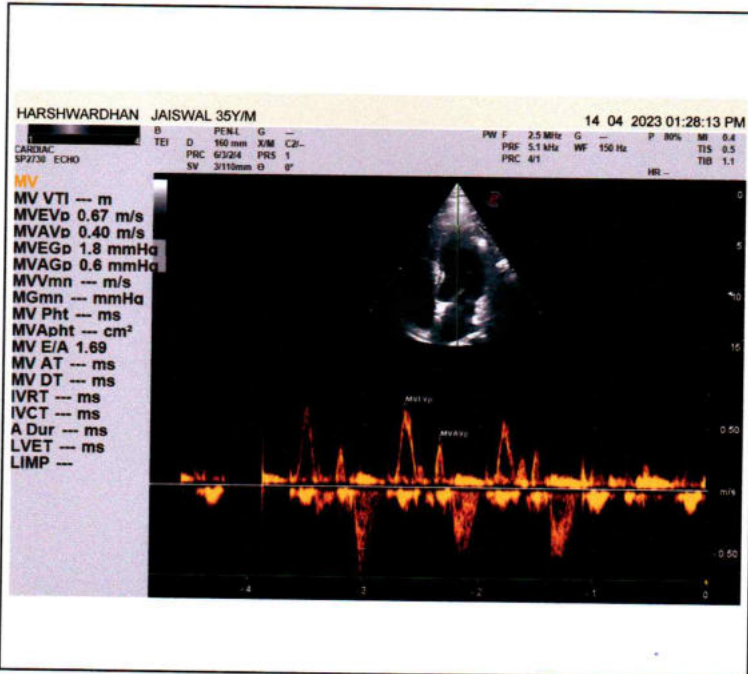
  
Niraj Mishra  
Physician Assistant  
(PIIRE)

Dr. Pallavi Mishra  
MBBS, MD (MED) Lucknow  
Echocardiography Specialist, MIAE  
Non-invasive cardiologist  
Women Cardiologist  
Diabetocardiologist

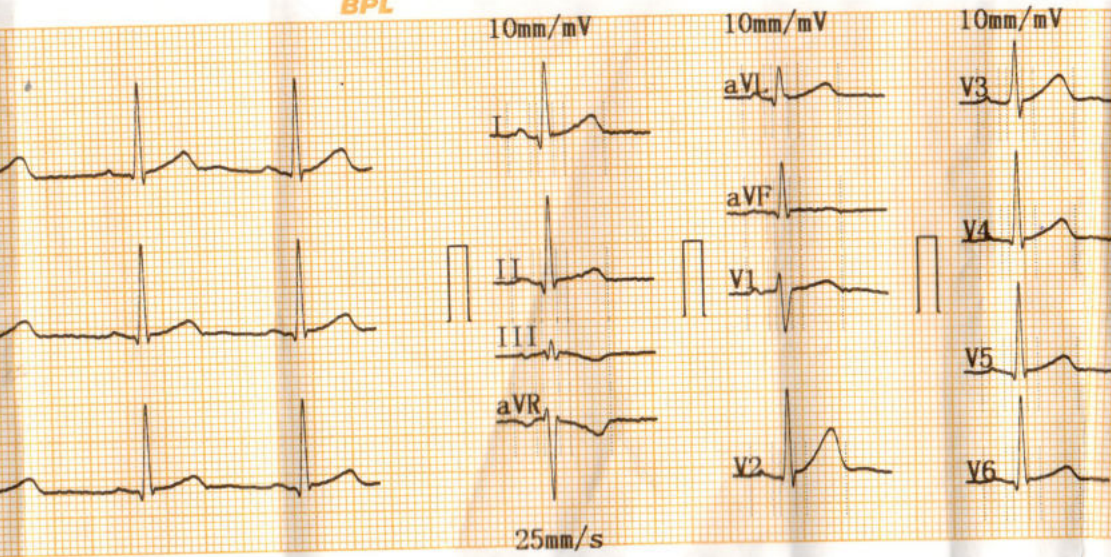
Address : Kabir Nagar (Near Sanjay Shiksha Niketan), Durgakund, Varanasi

Mobile : 9554572190 / 9453837595 / Recpn. 9389994334

E-mail : dramishra@gmail.com, drpallaviojha@gmail.com, Website: www.piire.org



BPL



2023-04-14 13:00

<< Conclusions >>

ID : \_\_\_\_\_  
 Name : HARSHWARDHAN JAISWAL  
 Sex : MALE Age : 35 YRS  
 Height : \_\_\_\_\_ Weight : \_\_\_\_\_  
 SYS : \_\_\_\_\_  
 DIA : \_\_\_\_\_

Normal Sinus Rhythm;  
 Cardiac electric axis normal;  
 \*\*Report need physician confirm\*\*

HR [bpm] : 70  
 PR Interval [ms] : 161  
 P Duration [ms] : 120  
 QRS Duration [ms] : 88  
 T Duration [ms] : 218  
 QT/QTc [ms] : 365/394  
 P/QRS/T Axis [deg] : 8.6/32.3/10.2  
 R(V5)/S(V1) [mV] : 1.21/0.54  
 R(V5)+S(V1) [mV] : 1.75

**PAIACEA HOSPITAL**  
 (A UNIT OF AMBON HEALTH CARE PVT. LTD.)  
 REG. NO.: AL-1500  
 B-35/41 B-4, KABIR NAGAR  
 DURGAKUND, VARANASI

Physician \_\_\_\_\_

CARDIART



# PANACEA HOSPITAL

*A shelter for many hearts A Home for many lives*

(An ISO 9001:2008 Certified Organisation)  
Lab Attached with CMC Vellore Under EQAS Scheme

<b>PATIENT'S NAME</b> : HARSHWARDHAN JAISWAL	<b>AGE/SEX:</b> 35 Y/M
<b>REF. BY</b> : Dr. ASHUTOSH MISHRA (MD)	<b>Friday, April 14, 2023</b>

## U/S. WHOLE ABDOMEN

- LIVER** : Liver is normal in size, shape & echotexture. Intra hepatic biliary radicals are normal. Portal venous channels are normal.
- G. B.** : Gall bladder is normal in size, lumen is clear. Wall thickness normal.
- C.B.D.** : C.B.D. is normal in caliber.
- PANCREAS** : Pancreas is normal in size, shape and echotexture. No evidence of any inflammatory disease or mass.
- SPLEEN** : Spleen is normal in size, shape and echotexture.
- Rt. KIDNEY** : Normal in size, shape and echotexture. Renal sinus is normal  
Cortico medullary differentiation is normal. P. C. system is normal.
- Lt. KIDNEY** : Normal in size, shape and echotexture. Renal sinus is normal  
Cortico medullary differentiation is normal. P. C. system is normal.
- URI. BLADDER** : Urinary bladder is normal in size, position. Wall thickness normal.
- PROSTATE** : Prostate is normal in size.  
No ascites & retro peritoneal lymphadenopathy seen.
- IMPRESSION** : **NO OBVIOUS SONOLOGICAL ABNORMALITY SEEN.**

  
**DR. R. K. TIWARI**

Consultant radiologist  
MBBS MD (GOLD MEDALIST)

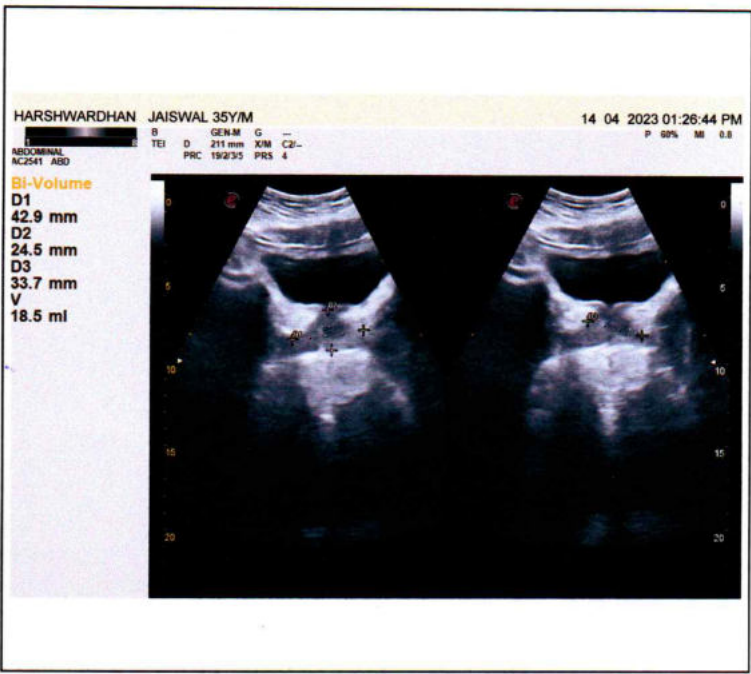
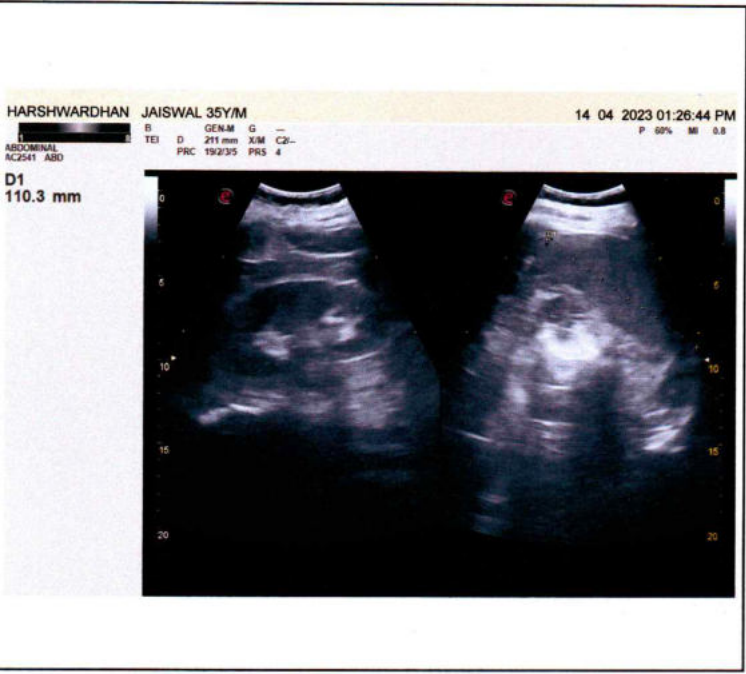
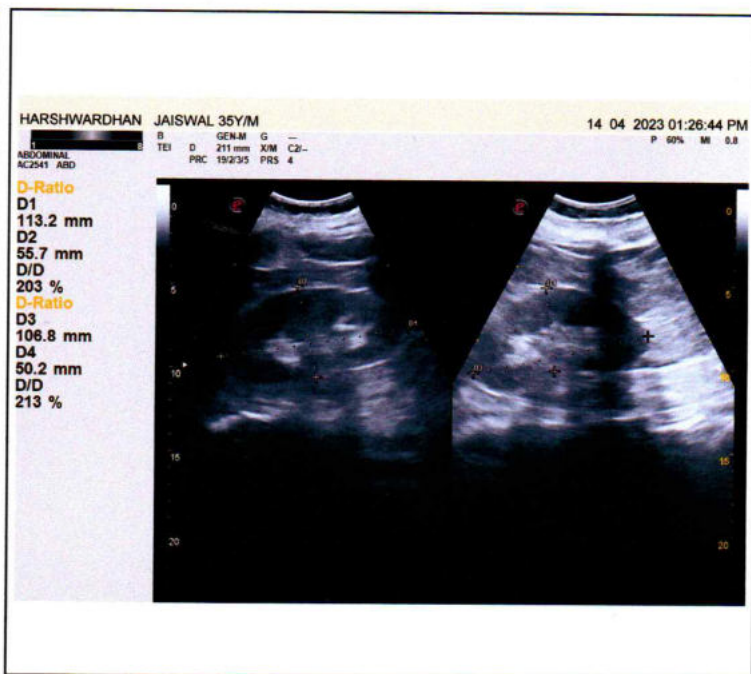
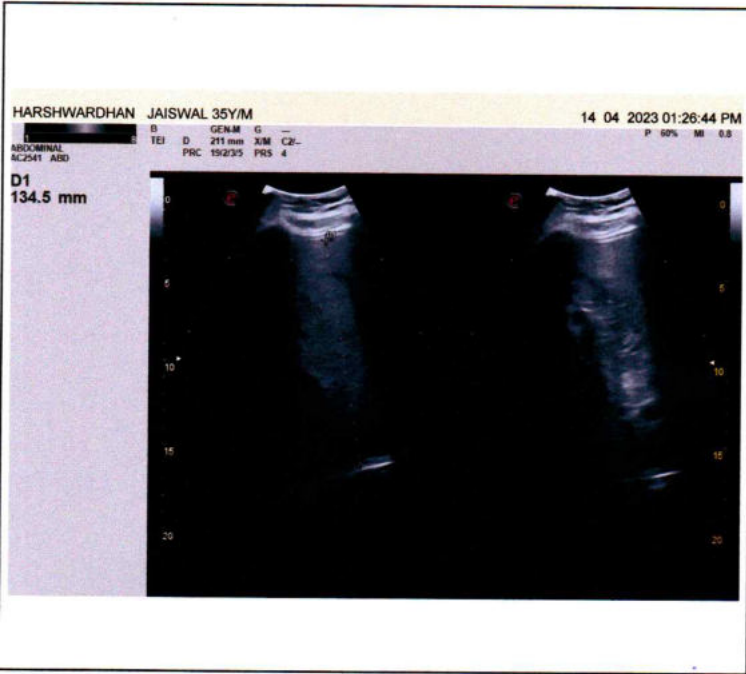King George Medical University, Lucknow

*Thanks for reference.*

Address : Kabir Nagar (Near Sanjay Shiksha Niketan), Durgakund, Varanasi

Mobile : 9554572190 / 9453837595 / Recpn. 9389994334

E-mail : dramishra@gmail.com, drpallaviojha@gmail.com, Website: www.piire.org





Call Now - 1800-123-3070



# PANACEA HOSPITAL

*A shelter for many hearts A Home for many lives*

(An ISO 9001:2008 Certified Organisation)  
Lab Attached with CMC Vellore Under EQAS Scheme

PATIENT'S NAME : HARSHWARDHAN JAISWAL  
REF. BY : Dr. ASHUTOSH MISHRA (MD)

AGE/SEX: 35 Y/M  
Friday, April 14, 2023

## X-RAY CHEST (PA VIEW)

### BOTH LUNG FIELDS AND PLEURAE:

Both lungs show normal bronchovascular pattern.

Right & left hila are normal

No focal mass or calcification is seen

There is no evidence of any fluid in the both the pleural cavities.

Both domes of diaphragms are normal in position.

### MEDIASTINUM:


Trachea is central in position.

Cardiac silhouette is of normal size and configuration.

No evidence of pericardial effusion.

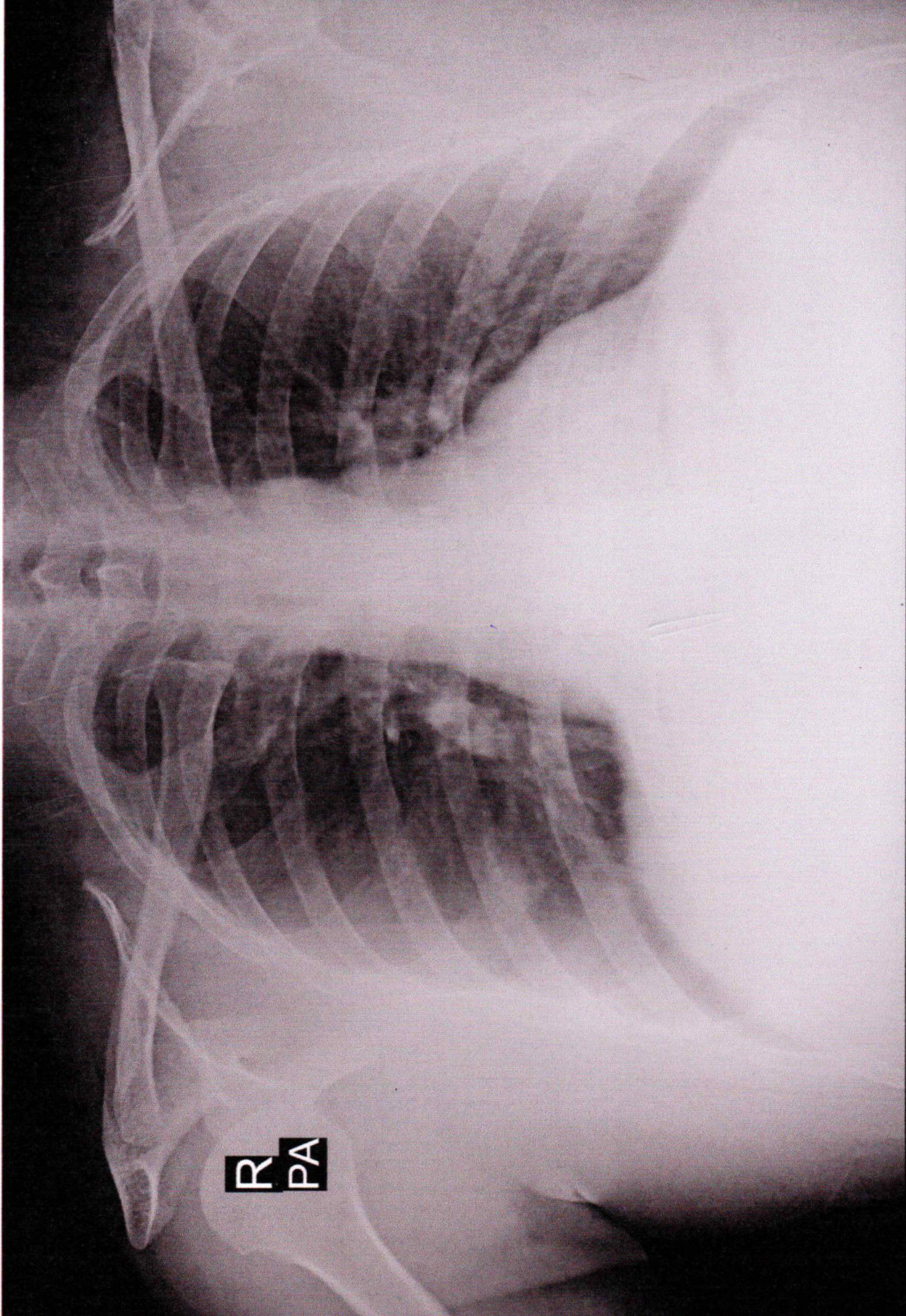
No significant lymphadenopathy is seen.

Visualized skeleton is normal.

  
DR. R. K. TIWARI  
M.B.B.S, M.D.(KGMU, LKO)  
(RADIODIAGNOSIS)

*Thanks for reference.*

Address : Kabir Nagar (Near Sanjay Shiksha Niketan), Durgakund, Varanasi  
Mobile : 9554572190 / 9453837595 / Recpn. 9389994334  
E-mail : dramishra@gmail.com, drpallaviojha@gmail.com, Website: www.piire.org



R  
PA

HARSHWARDHAN JAISWAL 35Y/M 0205 O CHEST P.A. 14-Apr-23 03:45 PM

PANACEA HOSPITAL, KABIR NAGAR, DURGAKUND, VARANASI