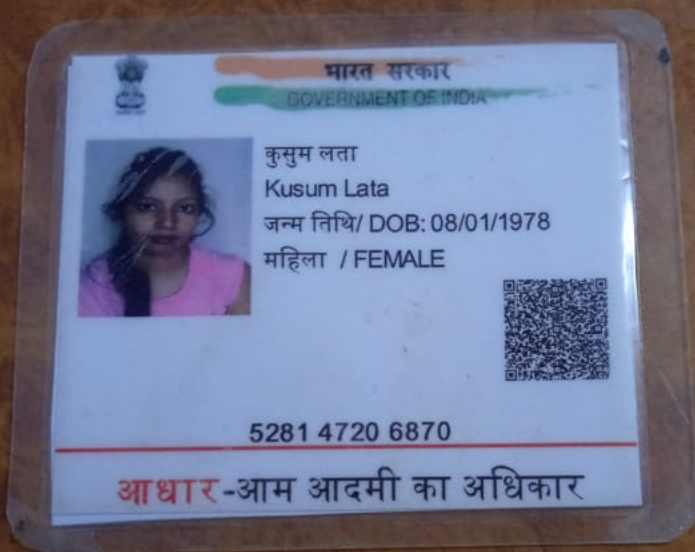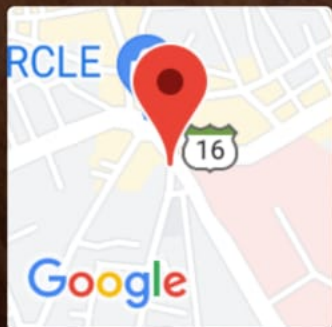




GPS Map Camera



**Jodhpur, Rajasthan, India**


4, Eidgah Rd, opposite oxford school, Jalori Bari, gate,  
Jodhpur, Rajasthan 342001, India

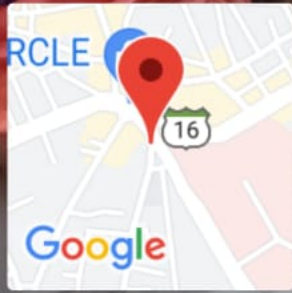
Lat 26.283772°

Long 73.016546°

10/09/22 11:10 AM



 GPS Map Camera



## Jodhpur, Rajasthan, India

4, Eidgah Rd, opposite oxford school, Jalori Bari, gate, Jodhpur, Rajasthan 342001, India

Lat 26.283773°

Long 73.016546°

10/09/22 11:10 AM



भारत सरकार  
GOVERNMENT OF INDIA



कुसुम लता  
Kusum Lata  
जन्म तिथि/ DOB: 08/01/1978  
महिला / FEMALE



6870

आधार-आम आदमी का अधिकार

*(Handwritten signature)*

*Nk Desu  
Dhangani*

Dr. Namd Kishore Chhangani  
MB-Physician & Cardiologist  
RMC No: 2087  
JODHPUR





 **SRD**  
Complete Diagnostic Solution



Pt Name : KUSUM LATA  
Ref By. : Dr.  
Serial No : 15762

Age : 44 Yrs.  
Sex : Female  
Date : 10/09/2022

TEST	RESULT	NORMAL RANGE
BLOOD GROUP (ABO) (RH)	B POSITIVE	

### HAEMOGRAM COMPLETE

W.B.C (WHITE BLOOD CELL COUNT)	5,200	4000 - 11000 /CUMM
DLC (DIFFERENTIAL LEUCOCYTE COUNT)		
NEUTROPHILS	63.4	40 - 70 %
LYMPHOCYTES	31.0	20 - 40 %
EOSINOPHILS	3.0	00 - 06 %
MONOCYTES	2.6	00 - 10 %
BASOPHILS	00	1 %
HB (HEMOGLOBIN)	12.5	12-16 GM%
PLATELET COUNT	1.97	1.5 - 4.5 LACS/CUMM
R.B.C (RED BLOOD CELL COUNT)	4.48	3.2 - 5.5
H.C.T. (HEMATOCRIT)	39.4	34-48 %
M.C.V(MEAN CORPUSCULAR VOLUME)	87.95	80 - 100 fL
MCH (MEAN CORPUSCULAR HEMOGLOBIN)	27.90	27 - 32 pg
MCHC (MEAN CORP.Hb CONCENTRATION)	31.73	L 32-36 g/dl
ERYTHROCYTE SEDIMENTATION RATE	16	02-20 MM FALL 1ST HOUR.

[ TECHNOLOGIST ]

\_\_\_\_\_ END OF REPORT \_\_\_\_\_

[ PATHOLOGIST ]

**Dr. V. K. Malhotra**  
MD - Path & Micro.  
RMC No. : 977

ई.सी.जी. | डिजिटल एक्सरे | टी. एम. टी. | ई. ई. जी. | ई. एम. जी. | एन. सी. वी. | बेरा | पी. एफ. टी. | ऑडियोमैट्री

ब्रह्म बाग, पुष्पक कोरियर के पास, ईदगाह रोड़, जालोरी गेट, जोधापुर (राज.)

फोन : 0291-2620214 E-mail : srdmedical@gmail.com

THIS REPORT IS NOT VALID FOR MEDICO LEGAL PURPOSES





Pt Name : KUSUM LATA  
Ref By. : Dr.  
Serial No : 15762

Age : 44 Yrs.  
Sex : Female  
Date : 10/09/2022

### BIO - CHEMISTRY EXAMINATION REPORT

Test	Result	Normal Value
BLOOD SUGAR - (F)	: 102.0	70-110 mg/dl
BLOOD SUGAR - (PP)	: 126.7	<140 mg/dl
BLOOD UREA	: 20.1	12-40 mg/dl
BLOOD UREA (BUN)	: 20	10-20mg/dl
S.CREATININE	: 0.90	0.6-1.2 mg/dl
S.URIC ACID	: 5.1	3.5 - 7.2 mg/dl

### LIPID PROFILE

S.CHOLESTEROL	: 210.3	130-250 mg/dl
S.TRIGLYCERIDES.	: 131.9	60-170 mg/dl
S.HDL CHOLESTEROL [ DIRECT ]	: 49.50	30-85 mg/dl
S.LDL CHOLESTEROL [ DIRECT ]	: 134	65-160 mg/dl
S.VLDL CHOLESTEROL	: 26	up to 35 mg/dl
CHOLESTEROL/HDL RATIO	: 4.25 :1	LESS THEN 4.5
LDL/HDL RATIO	: 2.71 :1	1.5 - 3.5

### LIVER FUNCTION TEST

S.BILIRUBIN TOTAL	: 0.67	0-1.2 mg/dl
S.BILIRUBIN DIRECT	: 0.18	0-0.3 mg/dl
S.BILIRUBIN INDIRECT	: 0.49	0-0.9 mg/dl
S.GOT	: 21.7	0-40 U/L
S.GPT	: 19.0	0-40 U/L
S.ALKALINE PHOSPHATASE	: 109.7	25-140 (adult) 37 c IU/L
S.TOTAL PROTEIN	: 6.85	6-8 gm/dl
S.ALBUMIN	: 3.91	3.7-5.3 gm/dl
S.GLOBULIN	: 2.94	2.5-3.5 gm/dl

[ TECHNOLOGIST ]

\_\_\_\_ END OF REPORT \_\_\_\_

Dr. V. K. Malhotra  
MD [ Pathology & Micro. ]  
RMC No.: 977

ई.सी.जी. | डिजिटल एक्सरे | टी. एम. टी. | ई. ई. जी. | ई. एम. जी. | एन. सी. वी. | बेरा | पी. एफ. टी. | ऑडियोमैट्री

ब्रह्म बाग, पुष्पक कोरियर के पास, ईदगाह रोड़, जालोरी गेट, जोधापुर (राज.)

फोन : 0291-2620214 E-mail : srdmedical@gmail.com

THIS REPORT IS NOT VALID FOR MEDICO LEGAL PURPOSES





Pt Name : KUSUM LATA  
Ref By. : Dr.  
Serial No : 15762

Age : 44 Yrs.  
Sex : Female  
Date : 10/09/2022

**GLYCOSYLATED HEMOGLOBIN ( HbA1C )**

<u>INVESTIGATION</u>	<u>RESULT</u>	<u>UNIT</u>
Glycosylated Hemoglobin ( HbA1C )	5.5	%

**INTERPRETATION**

<u>HBA1c (%)</u>	<u>Interpretation</u>
> 8 %	Action Suggested
7-8 %	Good Control
< 7 %	Goal
6 - 7 %	Near Normal Glycemia
< 6 %	Normal Level

[ TECHNOLOGIST ]

END OF REPORT

Dr. V. K. Malhotra  
MD - Path & Microbiology  
RMC No. : 977  
[ PATHOLOGIST ]

Complete Diagnostic Solution

ई.सी.जी. | डिजिटल एक्सरे | टी. एम. टी. | ई. ई. जी. | ई. एम. जी. | एन. सी. वी. | बेरा | पी. एफ. टी. | ऑडियोमैट्री

ब्रह्म बाग, पुष्पक कोरियर के पास, ईदगाह रोड़, जालोरी गेट, जोधपुर (राज.)

फोन : 0291-2620214 E-mail : srdmedical@gmail.com

THIS REPORT IS NOT VALID FOR MEDICO LEGAL PURPOSES





Pt Name : KUSUM LATA  
Ref By. : Dr.  
Serial No : 15762

Age : 44 Yrs.  
Sex : Female  
Date : 10/09/2022

## HORMONES & MARKERS (T3 T4 TSH)

NAME OF THE TEST :- THYROID FUNCTION TEST

TEST	RESULT	BIOLOGICAL REFERENCE INTERVAL
T3	0.92 ng/ml	0.60 to 1.81 ng/ml
T4	7.25 ug/dl	4.5 to 12.6
TSH	1.09 uIU/ml	Adult 0.35 to 5.50 >20 years

### IMPRESSION :

REMARK :-Primary malfunction of the thyroid gland may result in excessive (hyper) or low (hypo) release of T3 or T4. In addition, as TSH directly affect thyroid function, malfunction of the pituitary or the hypothalamus influences the thyroid gland activity. Disease in any portion of the thyroid-hypothalamus system may influence the level of T3 and T4 in the blood, in primary hypothyroidism, TSH levels are significantly elevated, while in secondary and tertiary hypothyroidism, TSH levels may be low. In Euthyroid sick Syndrom, multiple alterations in serum thyroid function test findings have been recognized.

[ TECHNOLOGIST ]

\_\_\_\_\_ END OF REPORT \_\_\_\_\_

Dr. V. K. Malhotra  
MD - Path & Micro.  
RMG No. 1977  
[ PATHOLOGIST ]

ई.सी.जी. | डिजिटल एक्सरे | टी. एम. टी. | ई. ई. जी. | ई. एम. जी. | एन. सी. वी. | बेरा | पी. एफ. टी. | ऑडियोमैट्री

ब्रह्म बाग, पुष्पक कोरियर के पास, ईदगाह रोड़, जालोरी गेट, जोधापुर (राज.)

फोन : 0291-2620214 E-mail : srdmedical@gmail.com

THIS REPORT IS NOT VALID FOR MEDICO LEGAL PURPOSES





Pt Name : KUSUM LATA  
Ref By. : Dr.  
Serial No : 15762

Age : 44 Yrs.  
Sex : Female  
Date : 10/09/2022

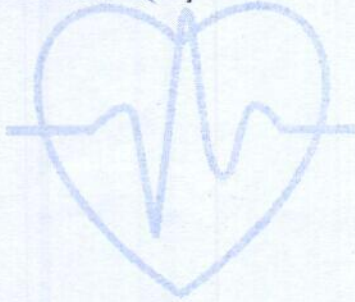
### STOOL EXAMINATION REPORT

Test	Result
<b>PHYSICAL</b>	
COLOUR	BROWN
CONSISTENCY	SOLID
<b>MICROSCOPIC</b>	
PUS CELLS	NIL
RED BLOOD CELLS	NIL
EPITHELIAL CELLS	NIL
BACTERIAL FLORA	NORMAL
HELMINTHIC OVA	NIL

  
[ TECHNOLOGIST ]

\_\_\_\_\_ END OF REPORT \_\_\_\_\_

Dr.  [ PATHOLOGIST ]  
MD - Path & Micro.  
RMC No. : 977



Complete Diagnostic Solution

ई.सी.जी. | डिजीटल एक्सरे | टी. एम. टी. | ई. ई. जी. | ई. एम. जी. | एन. सी. वी. | बेरा | पी. एफ. टी. | ऑडियोमैट्री

ब्रह्म बाग, पुष्पक कोरियर के पास, ईदगाह रोड़, जालोरी गेट, जोधापुर (राज.)

फोन : 0291-2620214 E-mail : srdmedical@gmail.com

THIS REPORT IS NOT VALID FOR MEDICO LEGAL PURPOSES





Pt Name : KUSUM LATA  
Ref By. : Dr.  
Serial No : 15762

Age : 44 Yrs.  
Sex : Female  
Date : 10/09/2022

### URINE EXAMINATION REPORT

Test	Result(s)
<b>PHYSICAL</b>	
COLOUR	PALE YELLOW
APPEARANCE	CLEAR
<b>CHEMICAL</b>	
REACTION pH	6.0
SPECIFIC GRAVITY	1.030
ALBUMIN	NIL
SUGAR - (F)	NIL
SUGAR - (PP)	NIL
<b>MICROSCOPIC</b>	
PUS CELLS	0-1 /HPF
RED BLOOD CELLS	NIL
EPITHELIAL CELLS	NIL
CASTS	NIL
CRYSTALS	NIL
BACTERIA	NIL

[ TECHNOLOGIST ]

END OF REPORT

Dr. [ PATHOLOGIST ]  
MD - Path & Micro.  
RMC No. : 977

Complete Diagnostic Solution

ई.सी.जी. | डिजिटल एक्सरे | टी. एम. टी. | ई. ई. जी. | ई. एम. जी. | एन. सी. वी. | बेरा | पी. एफ. टी. | ऑडियोमैट्री

ब्रह्म बाग, पुष्पक कोरियर के पास, इंदगाह रोड़, जालोरी गेट, जोधापुर (राज.)

फोन : 0291-2620214 E-mail : srdmedical@gmail.com

THIS REPORT IS NOT VALID FOR MEDICO LEGAL PURPOSES





Complete Diagnostic Solution

Client Name	Mrs. KUSUM LATA	Sex/Age	44 Year / Female
C Name	REF By.	TPA Name	
Date	10 Sep 2022	Lab No.	17578
Reporting Date	10 Sep 2022	Remark	

Test Name	Result	Unit	Ref-Range
<b>BIO - CHEMISTRY</b>			
BUN/SR.CREATININE RATIO	22.21	Ratio	6-25 Ratio

\*\*\*\*\*End Of Report\*\*\*\*\*



TECHNOLOGIST	Lab. INCHARGE	Dr. V. K. Malhotra PATHOLOGIST/Micro. RMC No. 977
--------------	---------------	---

ई.सी.जी. | डिजिटल एक्सरे | टी. एम. टी. | ई. ई. जी. | ई. एम. जी | एन. सी. वी. | बेरा | पी. एफ. टी. | ऑडियोमैट्री

ब्रह्म बाग, पुष्पक कोरियर के पास, ईदगाह रोड़, जालोरी गेट, जोधपुर (राज.)

फोन : 0291-2620214 E-mail : srdmedical@gmail.com

THIS REPORT IS NOT VALID FOR MEDICO LEGAL PURPOSES





## MEDICAL CERTIFICATE

NAME :KUSUM LATA  
AGE/SEX: 44Yrs/FEMALE

DATE-10-09-2022

HEIGHT-153CMS  
BP -110/70

WEIGHT-60KG  
PULSE- 76

BMI- 25.63

EYE SIGHT- BOTH EYESIGHT NORMAL.

THIS IS TO CERTIFY THAT MRS.KUSUM LATA IS MEDICALLY & PHYSICALLY FIT & FINE FOR PERFORMING ALL TYPE OF PROFESSIONAL WORK.

*NK Chhangani*

Dr. Nand Kishore Chhangani  
MD-Physician & Cardiologist  
RMC No.-2087  
JODHPUR

ई.सी.जी. | डिजिटल एक्सरे | टी. एम. टी. | ई. ई. जी. | ई. एम. जी. | एन. सी. वी. | बेरा | पी. एफ. टी. | ऑडियोमैट्री

ब्रह्म बाग, पुष्पक कोरियर के पास, ईदगाह रोड़, जालोरी गेट, जोधापुर (राज.)

फोन : 0291-2620214 E-mail : srdmedical@gmail.com

THIS REPORT IS NOT VALID FOR MEDICO LEGAL PURPOSES





**SRD**  
X-RAY CHEST PA-VIEW  
Complete Diagnostic Solution



NAME :KUSUM LATA  
REF.BY:BOB

AGE- 44Yrs

SEX : FEMALE

DATE :10-09-2022

BOTH LUNG -

PARENCHYMA.

BOTH C.P ANGLES -

NORMAL.

CARDIAC SHADOW IS WITHIN -

NORMAL LIMITS.

DOMES OF DIAPHRAGM -

NORMAL.

BONY CAGE -

NORMAL.

MEDIA STERNUM CENTRAL

/'L'/

THORACIC INLET -

NORMAL.

IMPRESSION :-

NORMAL CHEST PA-VIEW.

DR.RAKESH GAUR (M.D)

(RADIO LOGIST) R.M.C NO. 5698

**Dr. Rakesh Gaur**  
MD. Radiology  
RMC No. 5698

ई.सी.जी. | डिजीटल एक्सरे | टी. एम. टी. | ई. ई. जी. | ई. एम. जी | एन. सी. वी. | बेरा | पी. एफ. टी. | ऑडियोमैट्री

ब्रह्म बाग, पुष्पक कोरियर के पास, ईदगाह रोड, जालोरी गेट, जोधापुर (राज.)

फोन : 0291-2620214 E-mail : srdmedical@gmail.com

THIS REPORT IS NOT VALID FOR MEDICO LEGAL PURPOSES





Kusum Lata / 8191 / 10.09.2022

Ref by: Dr. Lakshman Lal Suthar

## Transabdominal sono screening scan – whole abdomen

Extensive bowel gases precluded optimal examination.

### Hepato-biliary system:

Liver is mildly enlarged in size. Hepatic parenchymal echotexture is bright, homogenous and uniform. No focal lesion seen. Intrahepatic biliary radicles are not dilated. Portal vein and cbd are normal in caliber. Gall bladder is seen in normal distension. Walls are normal in thickness and are smooth. No mass is seen. Lumen is anechoic. Pancreas is normal in size and echotexture. Pancreatic duct is not dilated. No area of calcification is seen in pancreas.

### Uro-genital system:

Both the kidneys are normal in size. Parenchymal echotexture is normal. Corticomedullary differentiation is maintained. Central echo-complexes are normal. Urinary bladder is seen in minimal distension [47 ml] [patient not willing to hold urine]. Lumen is anechoic. Uterus and ovaries are not seen clearly.

### Spleen & retroperitonium:

Spleen is normal in size. Parenchymal echotexture is normal. Most of the retroperitonium is not seen clearly, obscured by bowel gases.

No free fluid is seen in cul de sac.

### Sonographic findings are suggestive of:-

- Mild Hepatomegaly with fatty changes grade – I.
- Scan done in minimal distended bladder. Patient not willing to hold urine.

This is only professional opinion based on imaging finding and not the diagnosis  
It should be correlated clinically, to arrive at proper conclusion.

**Dr. Rakesh Middha**

M.D.

Consultant Radiologist

[R.M.C. No 017628]



KUSU LATA  
E33942 22 09 10 48

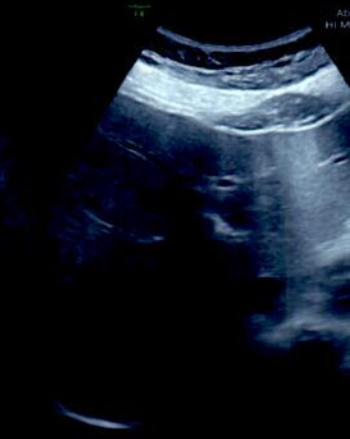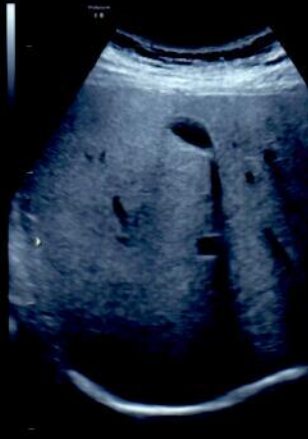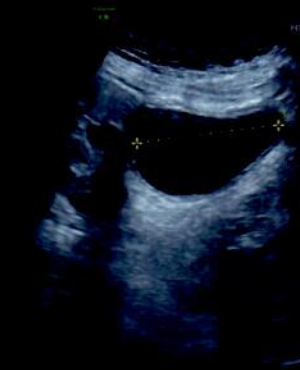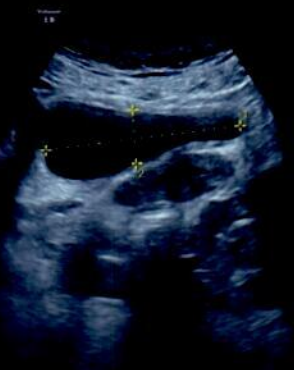ROG JANCH SEWA, JODHPUR

Tis 0.1 10 09 2022  
Tib 0.1 2:36:52 PM  
MI 1.0 C1 6 D  
22Hz/16.3cm  
64/12  
Abd Sharp ABD  
Hi M Pl 6.50 4 10  
Gr 4  
CB/M7  
FF2/E2

KUSU LATA  
E33942 22 09 10 48

ROG JANCH SEWA, JODHPUR

Tis 0.1  
Tib 0.1  
MI 1.0



1 D1 7.66cm  
2 D2 2.10cm  
3 D3 5.60cm  
Vol 47.167cm<sup>3</sup>

KUSU LATA  
E33942 22 09 10 48

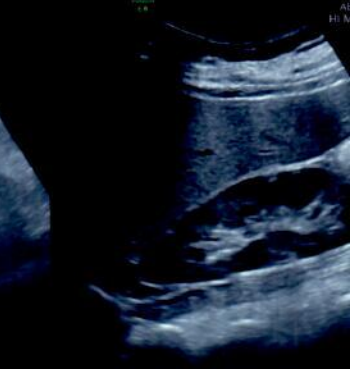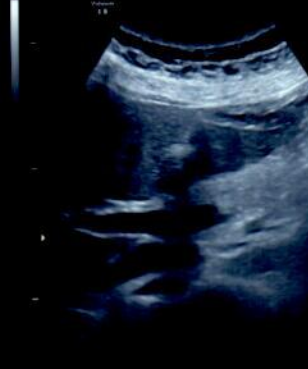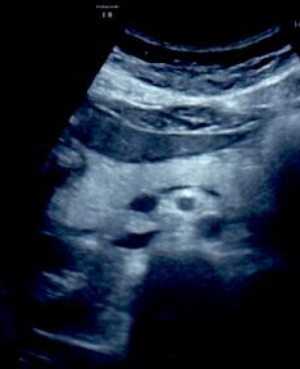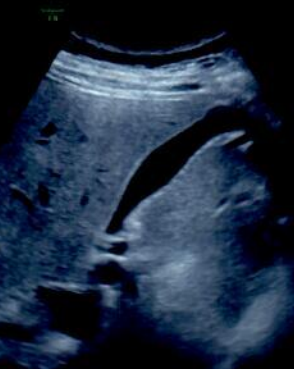ROG JANCH SEWA, JODHPUR

Tis 0.1 10 09 2022  
Tib 0.1 2:37:29 PM  
MI 1.0 C1 6 D  
22Hz/16.3cm  
64/12  
Abd Sharp ABD  
Hi M Pl 6.50 4 10  
Gr 4  
CB/M7  
FF2/E2

KUSU LATA  
E33942 22 09 10 48

ROG JANCH SEWA, JODHPUR

Tis 0.1  
Tib 0.1  
MI 1.0



KUSU LATA  
E33942 22 09 10 48

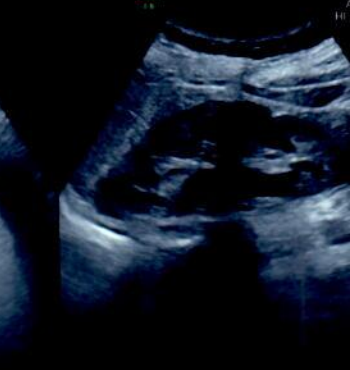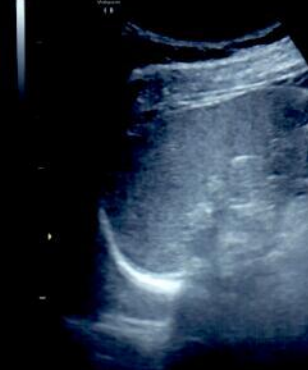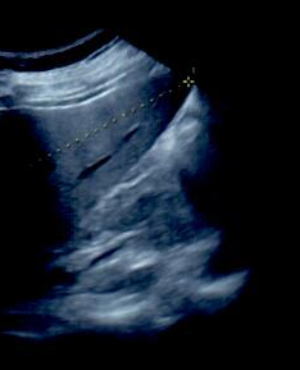ROG JANCH SEWA, JODHPUR

Tis 0.1 10 09 2022  
Tib 0.1 2:37:48 PM  
MI 1.0 C1 6 D  
17Hz/16.3cm  
33/12  
Abd Sharp ABD  
Hi M Pl 6.50 4 10  
Gr 5  
CB/M7  
FF2/E2

KUSU LATA  
E33942 22 09 10 48

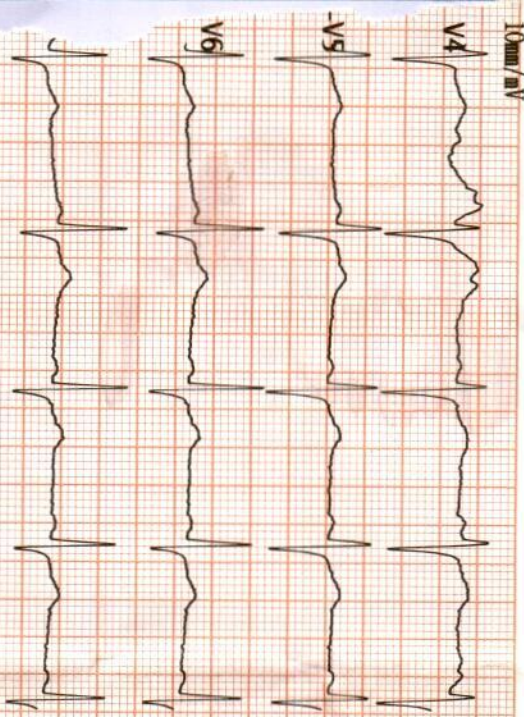
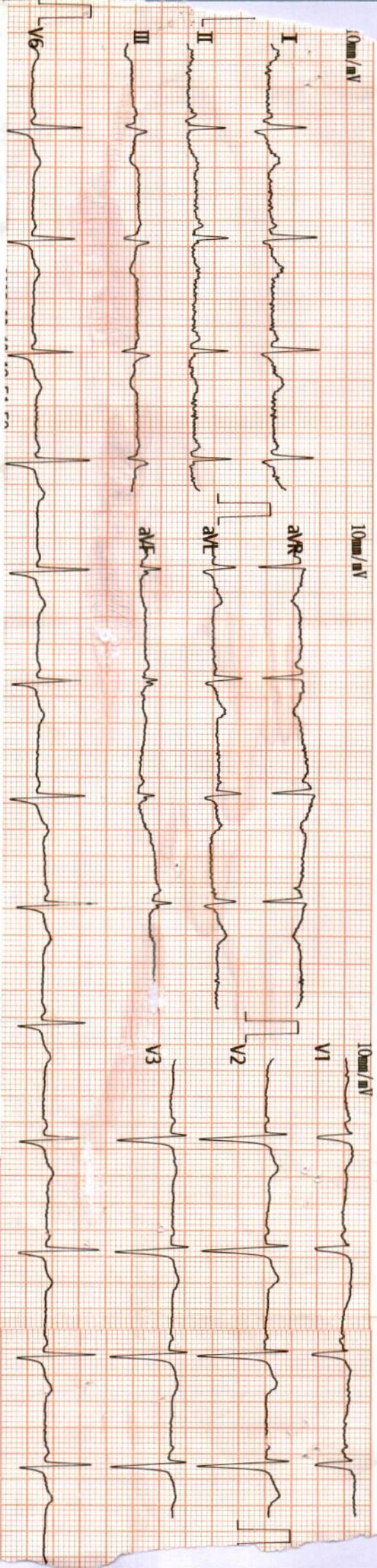
ROG JANCH SEWA, JODHPUR

Tis 0.1  
Tib 0.1  
MI 1.0



1 D 15.46cm





Vent. Rate (bpm): 71  
 PR Int. (ms): 128  
 P/QRS/T Int. (ms): 96 108 186  
 QT/QTc Int. (ms): 386 424  
 P/QRS/T Axis (Deg.): 54 35 20  
 RV1/SV5 Amp. (mV): 0.05 0.65  
 RV5/SV1 Amp. (mV): 0.46 0.57

ECG Analysis Results:  
 800 Normal Sinus Rhythm  
 121 Clockwise Rotation  
 \*\*\* Normal ECG \*\*\*  
 10/9/22

Technician: *TOPAL*  
 Dr. Nand KISHORE  
 MD-Physician & Cardiologist  
 RMC No.-2087  
 JODHPUR

999900004653 --Y / cm/Kg / mltg