

Mr. Anubhav Yadav

ID : 99

HTW : 169/68
Recorded : 23-10-2023 : 5:21

TREADMILL TEST SUMMARY REPORT

Age/Sex : 30M
Ref by : Meerul Histo Pathology Centre
Indication1 : Diagnostic
Indication2 : Diagnostic
Indication3 : Diagnostic

Protocol: BRUCE
History:
Medication1: Nil
Medication2: Nil
Medication3: Nil

PHASE	PHASE TIME	STAGE TIME	SPEED (Km/Hr.)	GRADE (%)	H.R (BPM)	B.P (mmHg)	RPP X100	TI	ST LEVEL (mm) V2	V5	METs
SUPINE											
STANDING	0:07	0:07			79	122/72	96	0.6	2.4	0.9	
HYPERVENT					81	124/74	100	0.8	2.5	1.0	
					81	126/76	102	0.8	2.5	1.1	
STAGE 1	2:59	2:59	2.73	10.00	110	129/75	140	1.1	2.3	1.2	4.20
STAGE 2	5:59	5:59	4.01	12.00	132	126/75	179	0.3	1.9	1.0	7.10
STAGE 3	8:59	8:59	5.41	14.00	154	128/78	187	0.3	2.1	1.5	10.00
STAGE 4	9:32	9:32	6.70	16.00	187	130/80	243	1.0	2.1	0.5	10.72
PEAK EXER	9:36	9:36			188	130/80	244	0.7	2.1	0.4	
RECOVERY	2:59	2:59	0.00	0.00	98	128/78	125	0.1	1.8	0.6	10.80

RESULTS

Exercise Duration : 9:36 Minutes
Max Heart Rate : 188 bpm (98 % of target heart rate 190 bpm)
Max Blood Pressure : 130/80 mmHg
Max Workload : 10.90 METs
Reason of Termination :

ECGPHI early T.M.T is Negative

IMPRESSIONS

Adh

Dr. S.M. JAIN
MBBS, MD, DNB (Cardiology)
Senior Cardiologist
Reg. No. : 22158 U.P.M.C.
Cardiologist

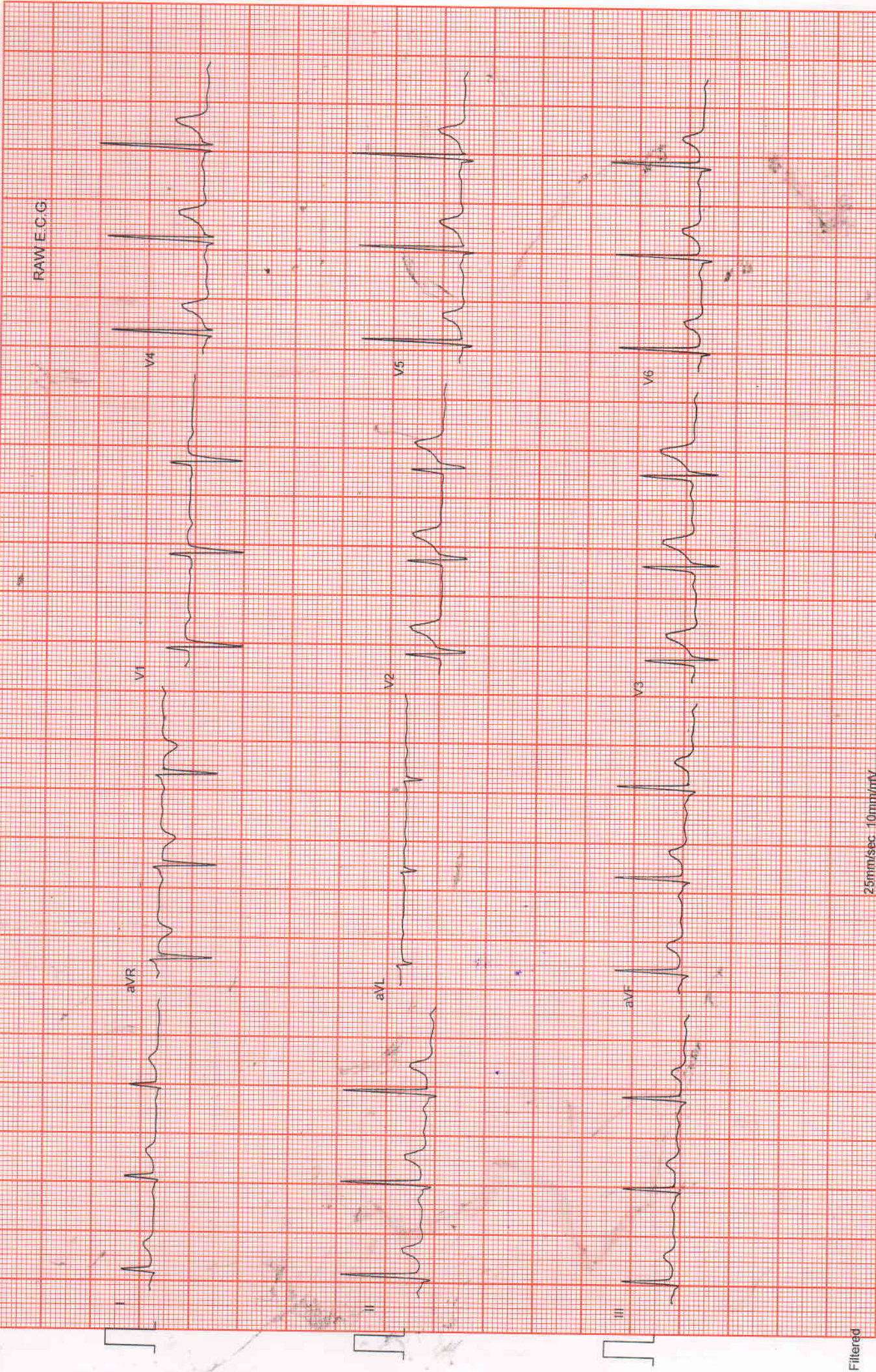
MEERUT ECG, TMT AND SPIROMETRY CENTRE

Dr. Anubhav Yadav
I.D. : 99
AGE/SEX : 30/M
RECORDED : 23-10-2023 15:21

SUPINE
PRETEST

RATE : 79 BPM
B.P. : 122/72 mmHg

ST @ 10mm/mV
80ms PostJ



Filtered

25mm/sec 10mm/mV

CardiCom, INDIA

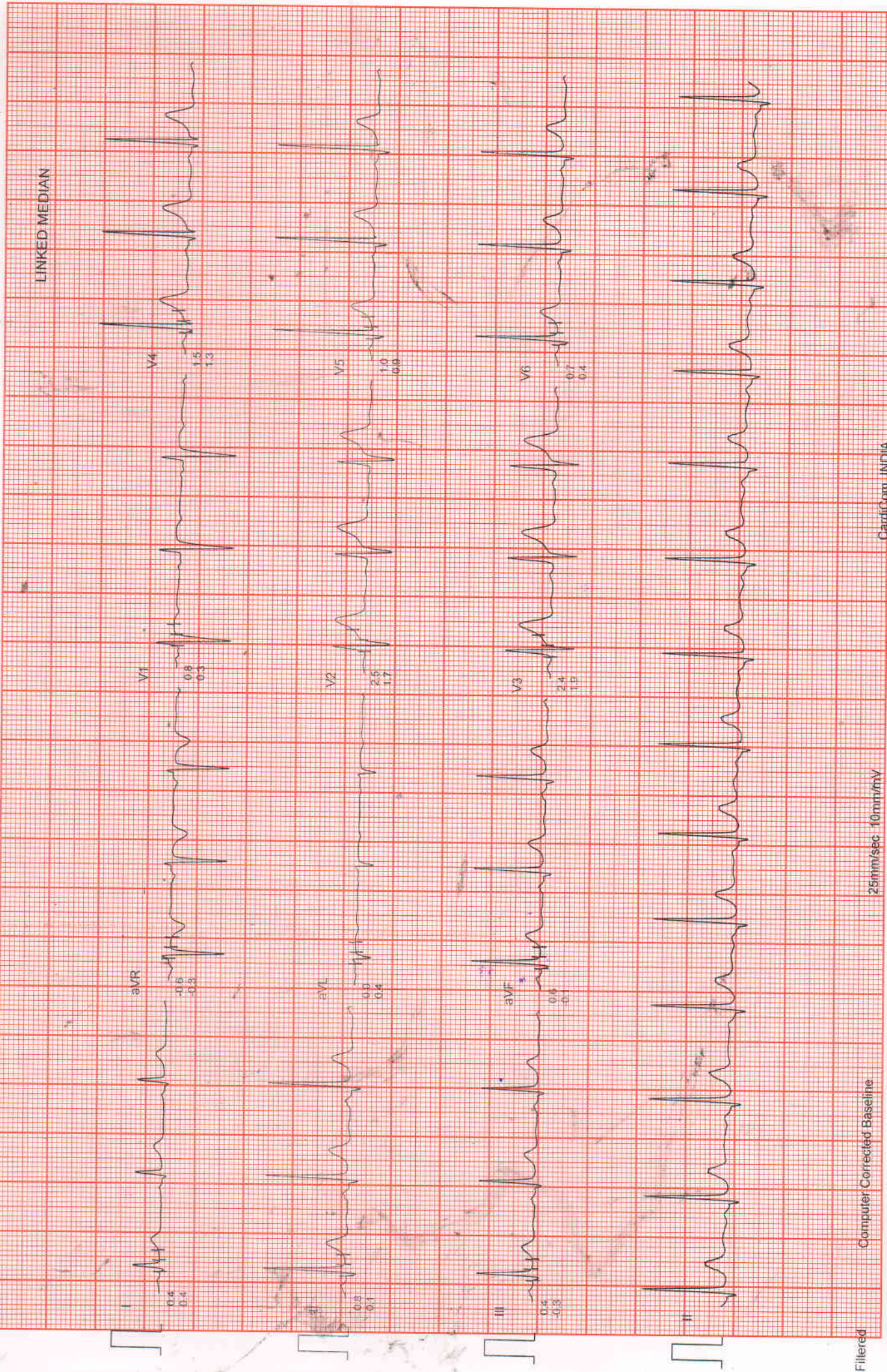
MEERUT ECG, TMT AND SPIROMETRY CENTRE

Patient Name: Anubhav Yadav
ID: 99
AGE/SEX: 30/M
RECORDED: 23-10-2023 15:21

STANDING
PRETEST

RATE: 81 BPM
B.P.: 124/74 mmHg

ST @ 10mm/mV
80ms PostJ



Filtered

Computer Corrected Baseline

25mm/sec 10mm/mV

CardiCorr INDIA

MEERUT ECG, TMT AND SPIROMETRY CENTRE

ST @ 10mm/mV
80ms Postd

HYPERVENTILATION
PRETEST

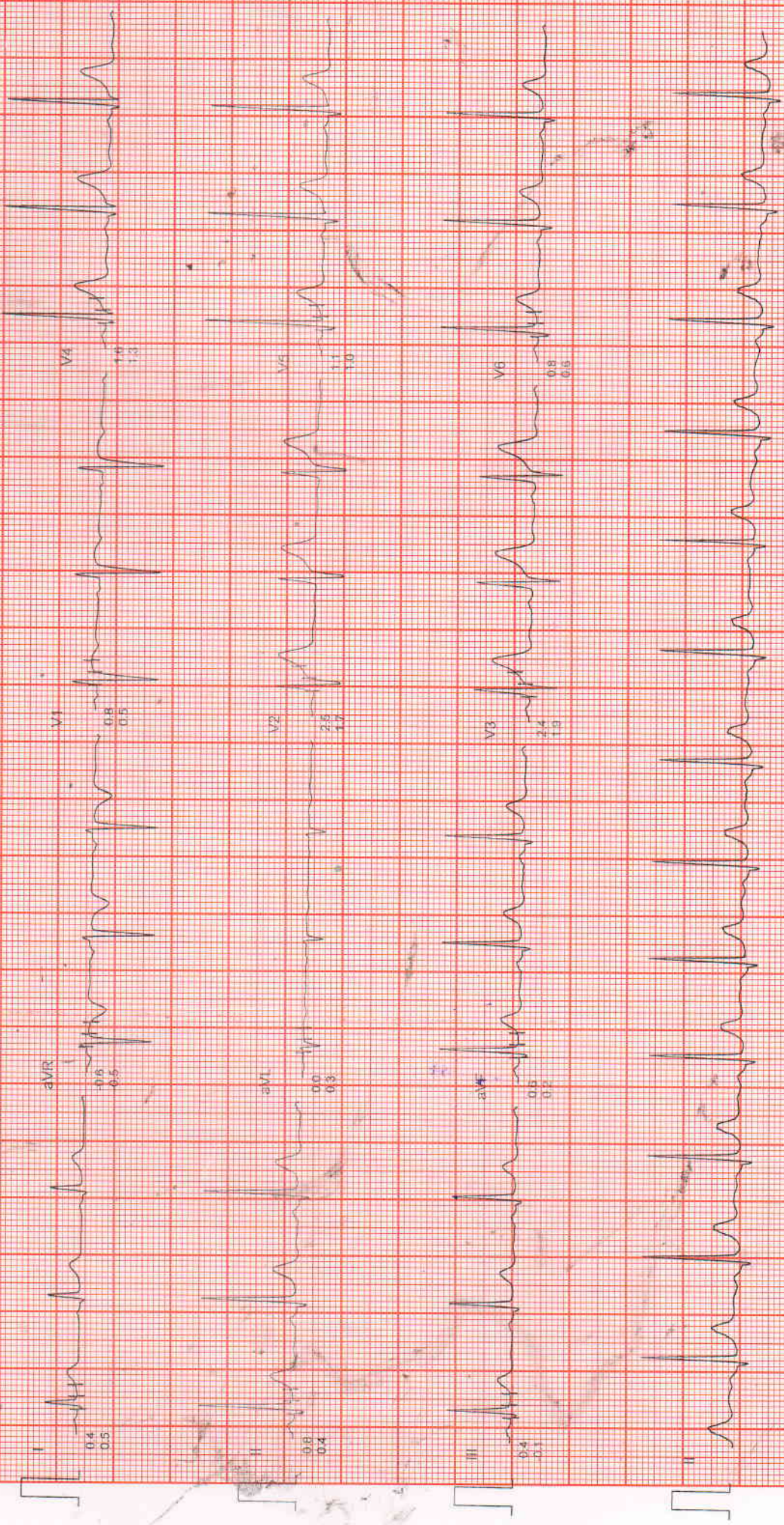RATE : 81 BPM
B.P. : 126/76 mmHg

RECORDED : 23-10-2023 15:21

Dr. Anubhav Yadav
I.D. : 99
AGE/SEX : 30/M

STAGE TIME : 0:07

LINKED MEDIAN



MEERUT ECG, TMT AND SPIROMETRY CENTRE

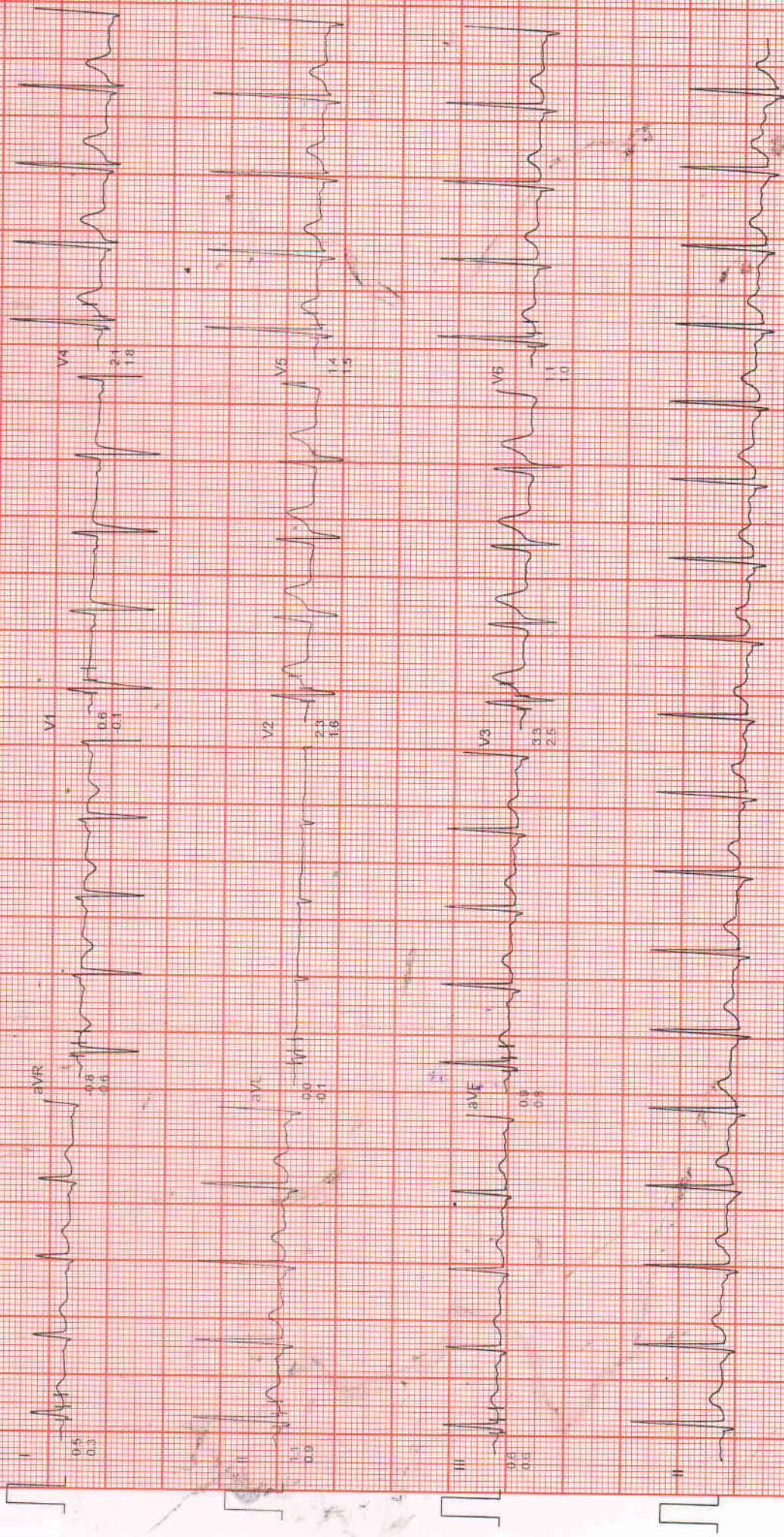
Dr. Anubhav Yadav
I.D. : 99
AGE/SEX : 30/M
RECORDED : 23-10-2023 15:21

RATE : 110 BPM
B.P. : 128/78 mmHg

BRUCE
EXERCISE 1
PHASE TIME : 2:59
STAGE TIME : 2:59

ST @ 10mm/mV
80ms PostJ
SPEED : 2.7 Km./Hr.
GRADE : 10.0 %

LINKED MEDIUM



MEERUT ECG, TMT AND SPIROMETRY CENTRE

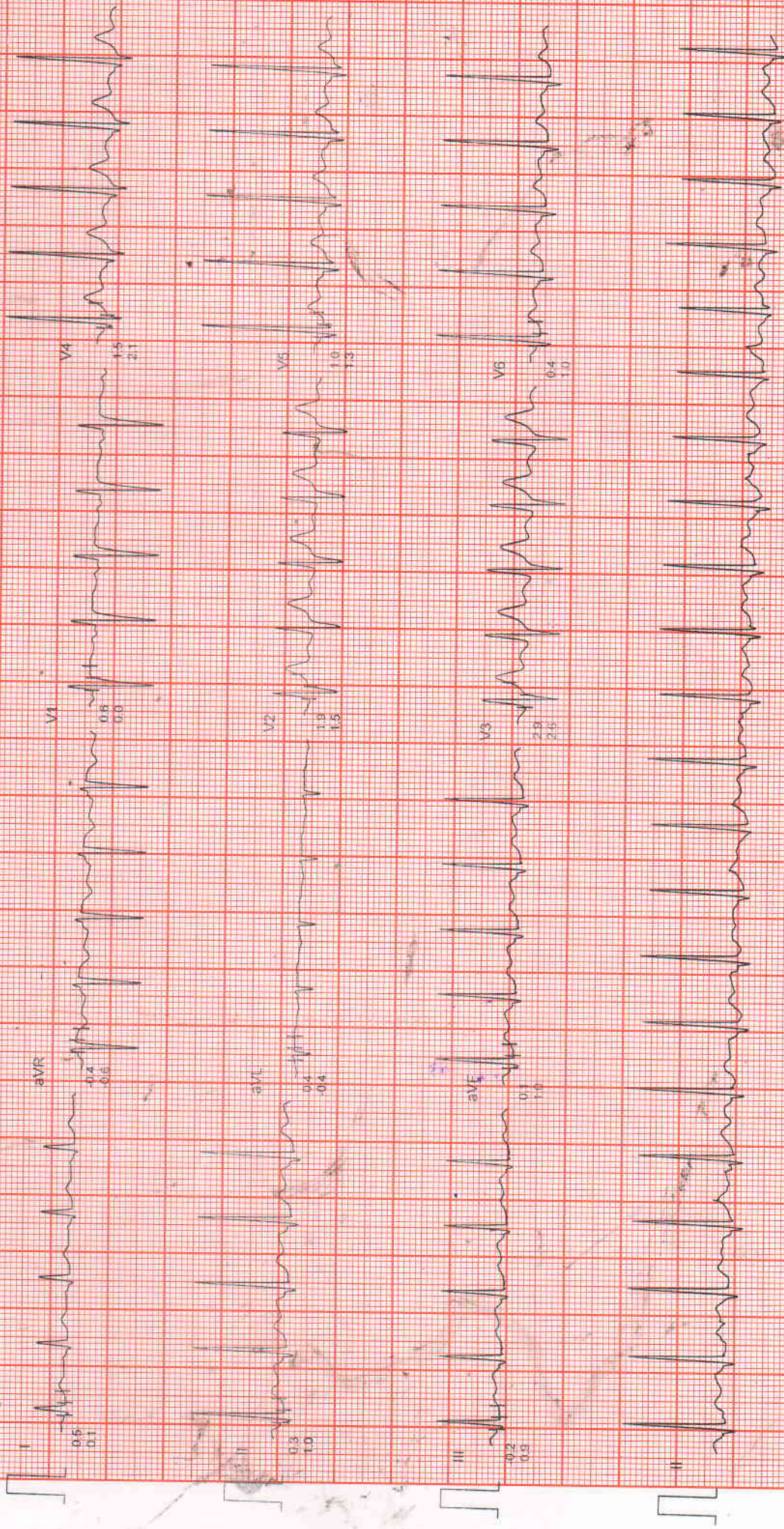Dr. Anubhav Yadav
I.D. : 99
AGE/SEX : 30/M
RECORDED : 23-10-2023 15:21

RATE : 133 BPM
B.P. : 128/78 mmHg

BRUCE
EXERCISE 2
PHASE TIME : 5:59
STAGE TIME : 2:59

ST @ 10mm/mV
80ms PostJ
SPEED : 4.0 Km./Hr
GRADE : 12.0 %

LINKED MEDIAN



MEERUT ECG, TMT AND SPIROMETRY CENTRE

Mr. Anubhav Yadav
I.D. : 99

AGE/SEX : 30/M

RECORDED : 23-10-2023 15:21

RATE : 154 BPM

B.P. : 128/78 mmHg

BRUCE

EXERCISE 3

PHASE TIME : 8:59

STAGE TIME : 2:59

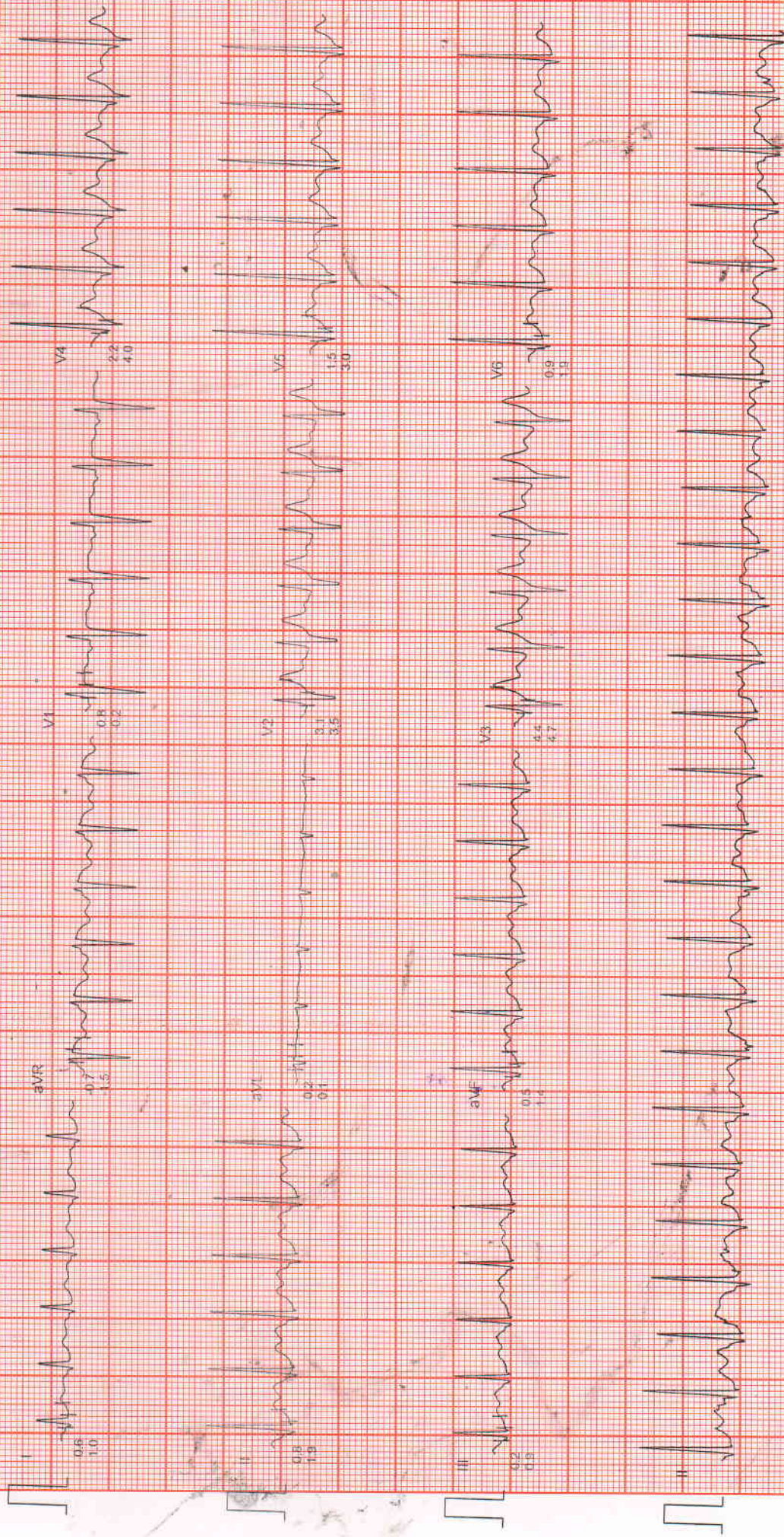ST @ 10mm/mV

80ms PostJ

SPEED : 5.4 Km./Hr

GRADE : 14.0 %

LINKED MEDIAN



MEERUT ECG, TMT AND SPIROMETRY CENTRE

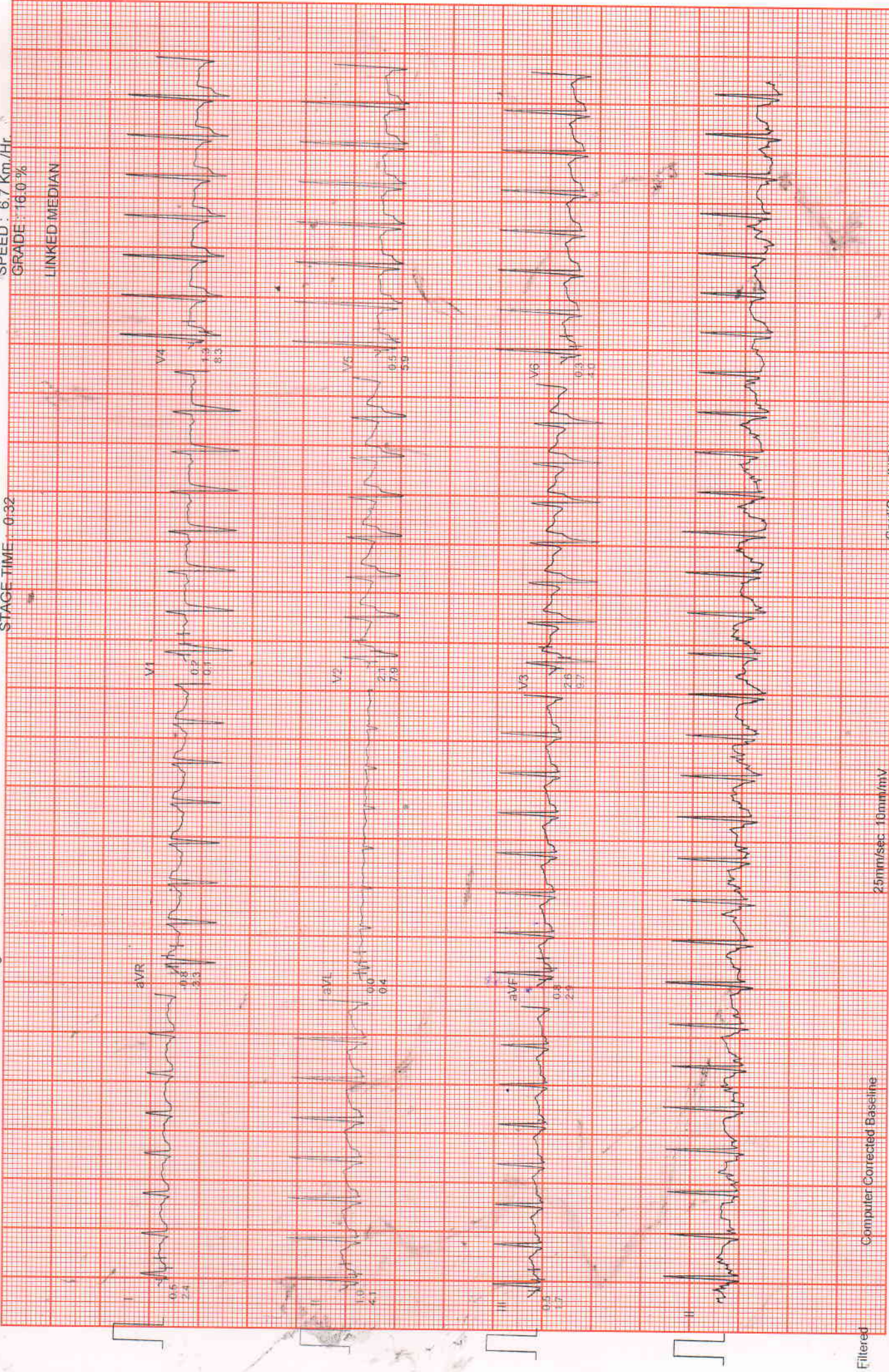Mr. Anubhav Yadav
I.D. : 99
AGE/SEX : 30/M
RECORDED : 23-10-2023 15:21

RATE : 187 BPM
B.P. : 130/80 mmHg

BRUCE
EXERCISE 4
PHASE TIME : 9:32
STAGE TIME : 0:32

ST @ 10mm/mV
80ms PostJ
SPEED : 6.7 Km./Hr.
GRADE : 16.0 %

LINKED MEDIAN



Filtered

Computer Corrected Baseline

25mm/sec 10mm/mV

CardiCam INDI

MEERUT ECG, TMT AND SPIROMETRY CENTRE

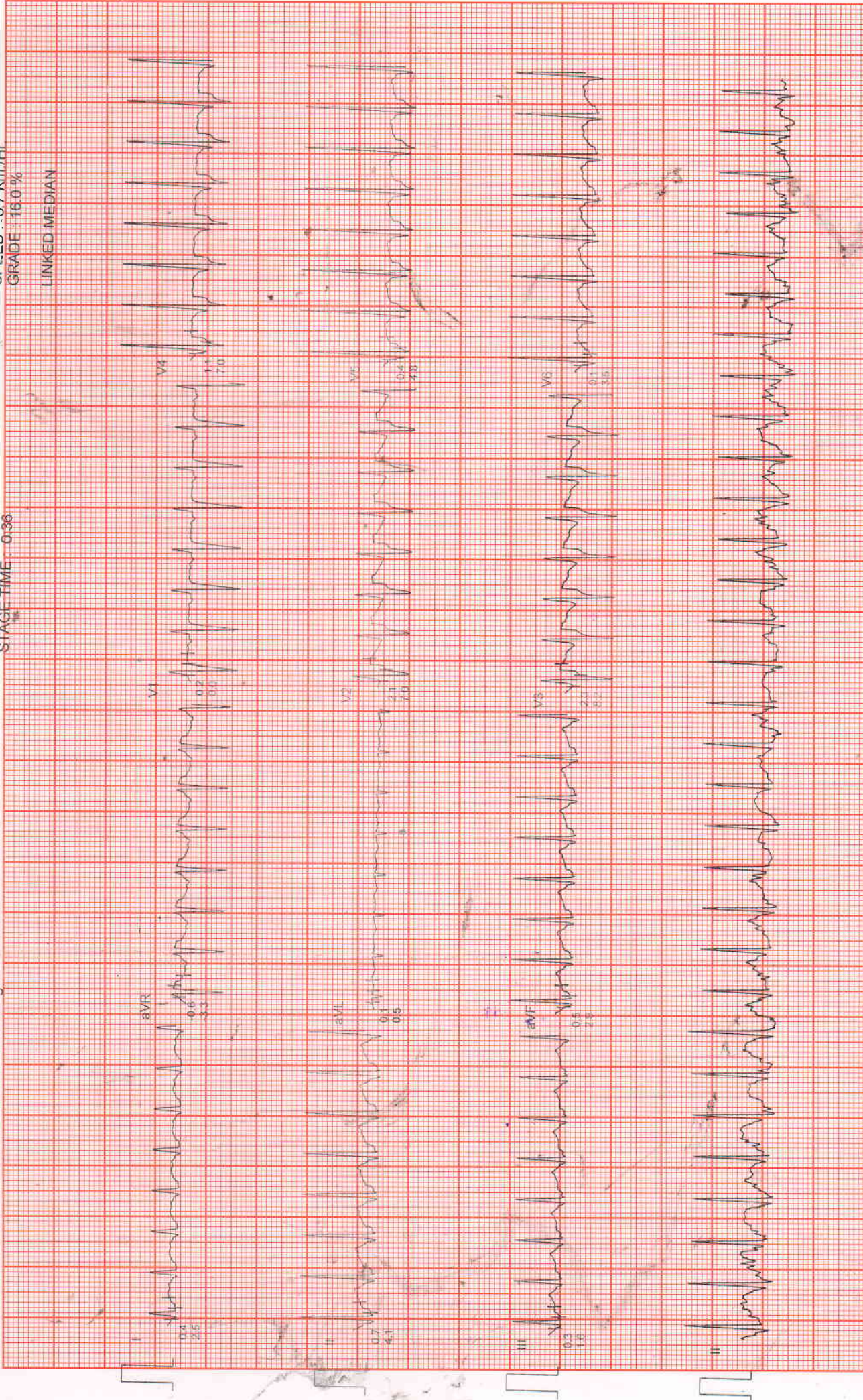
Mr. Anubhav Yadav
I.D. : 99
AGE/SEX : 30/M
RECORDED : 23-10-2023 15:21

RATE : 188 BPM
B.P. : 130/80 mmHg

BRUCE
PEAK EXER
PHASE TIME : 9:36
STAGE TIME : 0:36

ST @ 10mm/mV
80ms PostJ
SPEED : 6.7 Km/Hr
GRADE : 16.0 %

LINKED MEDIAN



MEERUT ECG, TMT AND SPIROMETRY CENTRE

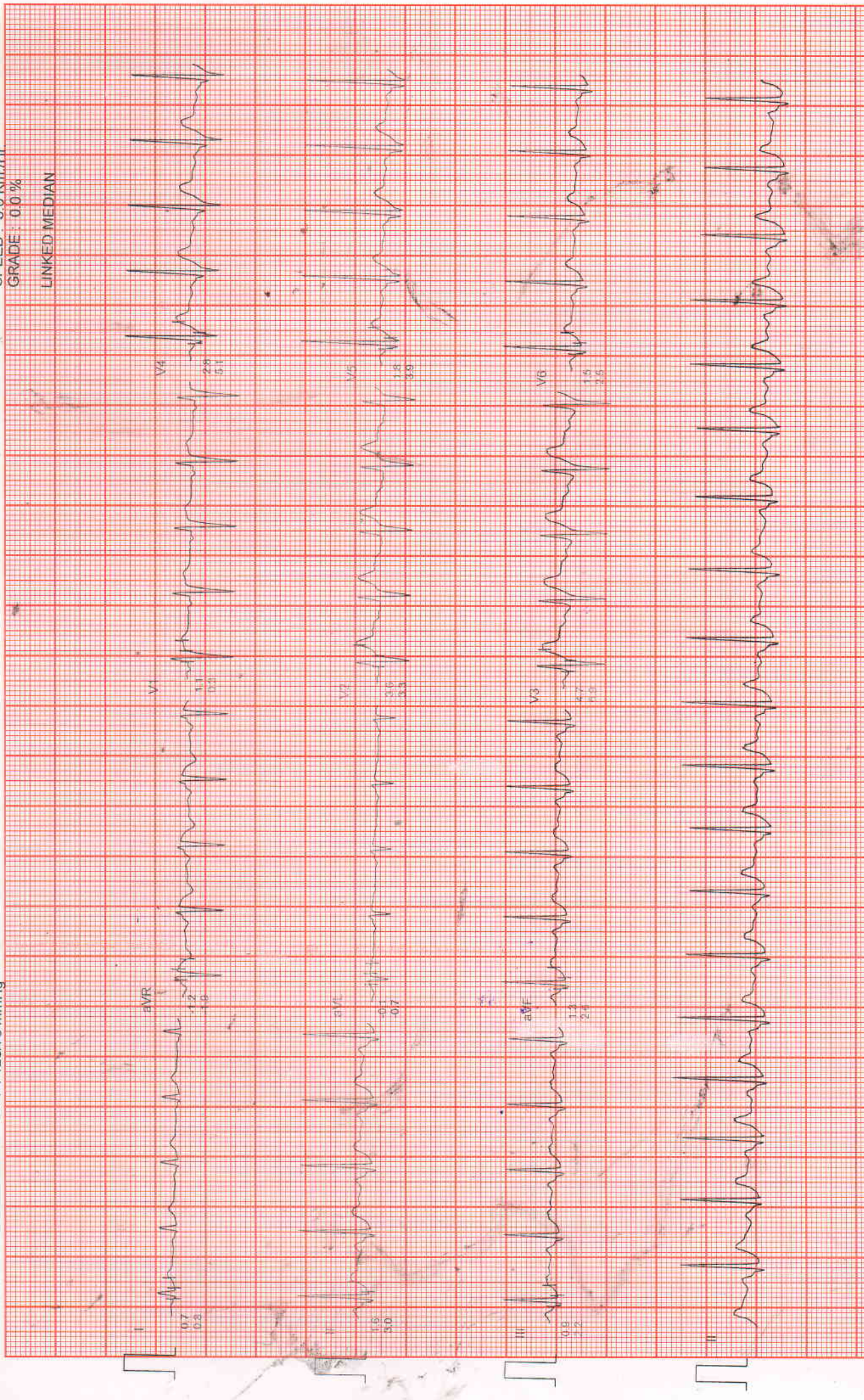
Mr. Anubhav Yadav
ID : 99
AGE/SEX : 30/M
RECORDED : 23-10-2023 15:21

RATE : 113 BPM
B.P. : 128/78 mmHg

BRUCE
RECOVERY
PHASE TIME : 1:00

ST @ 10mm/mV
80ms PostJ
SPEED : 0.0 Km./Hr.
GRADE : 0.0 %

LINKED MEDIAN



MEERUT ECG, TMT AND SPIROMETRY CENTRE

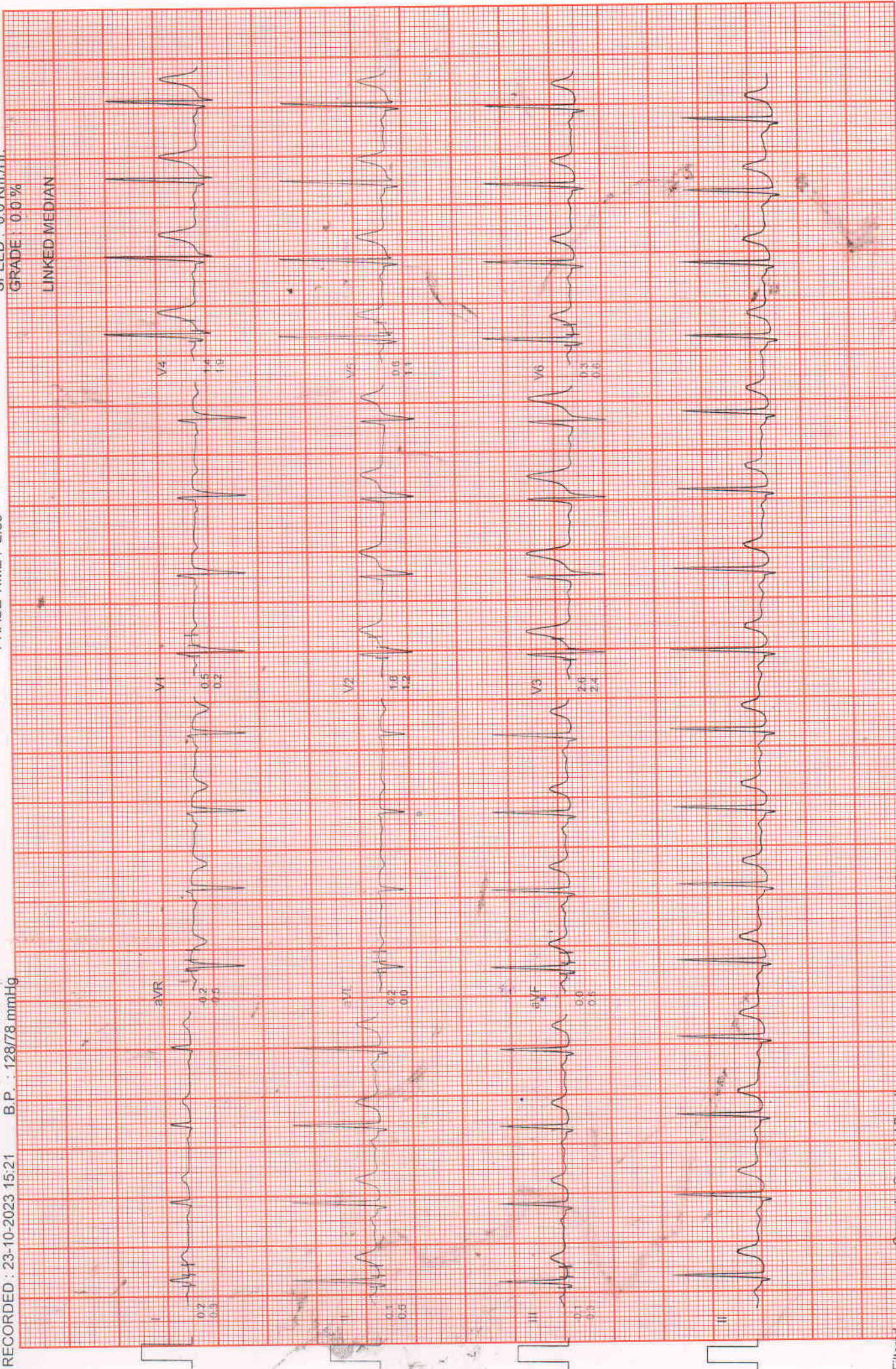
Mr. Anubhav Yadav
I.D. : 99
AGE/SEX : 30/M
RECORDED : 23-10-2023 15:21

RATE : 98 BPM
B.P. : 128/78 mmHg

ST @ 10mm/mV
80ms PostJ
SPEED : 0.0 Km/Hr.
GRADE : 0.0 %

BRUCE
RECOVERY
PHASE TIME : 2:59

LINKED MEDIAN





Quality Management Services
ISO-9001:2015 Certified Lab

MEERUT HISTOPATHOLOGY CENTRE

Laboratory Test-Report

NAME : **Mr. Anubhav Yadav**
REFERRED BY : Dr. BOB
SAMPLE : Blood, Urine

DATE : **23/10/2023**
AGE :
SEX : Male

TEST NAME	RESULTS	UNITS	REF.-RANGE
-----------	---------	-------	------------

HAEMATOLOGY

Complete Blood Counts			
HAEMOGLOBIN	12.0	GM%	13.5 - 17.5
TOTAL LEUCOCYTE COUNT :	7,300 cells	/Cu mm	4,500-11,000
DIFFERENTIAL LEUCOCYTE COUNT :			
Neutrophils :	63	%.	50-70
Lymphocytes :	28	%.	25-40
Eosinophils :	04	%.	1-4
Monocytes :	05	%.	3-8
Basophils :	00	%.	0-1
TOTAL R.B.C. COUNT	4.5	million/cu mm	4.5 - 6.5
PLATELET COUNT :	180	thousand/cum	150-450
P.C.V.	38.6	%.	35 - 54
MCV	85.7	fL	76-98
M C H	26.6	pg	27 - 32
M C H C	31.0	g/dl	31-35
E.S.R. (Westergren Method) :	08	mm in 1st Hr	0-15

BLOOD GROUP :

Major Blood Group : O
Rh Blood Group : Positive
(Comment)

Forward grouping by SLIDE METHOD.

All NEGATIVE blood groups to be confirmed at an authorized blood - bank.

--{End of Report}--

Dr. Medha Jain

M.B.B.S., (M.D. Path)
Consultant Pathologist
Reg. No. - G-33290 Gujrat
CMO. Reg. No. - MRT 869, Meerut

DR. KUMKUM DEEPAK MEMORIAL CENTRE, 302, W.K. ROAD, MEERUT

CALL : 0121-4009679, 9639688806, 09927286318, 7906584952, 9639251854 24 Hour Service, Home Visit

All Investigations have their limitation which are imposed by the limits of sensitivity and specificity of individual assay procedures as well as the specimen received by the laboratory.
Isolated laboratory investigation never confirm the final diagnosis of the disease. They only help in arriving at a diagnosis in conjunction with clinical presentation and other related investigation.

NOT FOR MEDICO LEGAL PURPOSE



Quality Management Services
ISO-9001:2015 Certified Lab

MEERUT HISTOPATHOLOGY CENTRE

Laboratory Test-Report

NAME : Mr. Anubhav Yadav
REFERRED BY : Dr. BOB
SAMPLE : Blood, Urine

DATE : 23/10/2023
AGE :
SEX : Male

TEST NAME	RESULTS	UNITS	REF.-RANGE
BIOCHEMISTRY			
BLOOD SUGAR (FASTING)	72.3	mg/dL	70 - 100
BLOOD SUGAR PP(2 Hrs after Meal)	110.2	mg/dl	70-140
BLOOD UREA NITROGEN :	15.4	mg/dL.	5 - 25
SERUM CREATININE :	1.3	mg/dL.	0.8 - 1.5
LIPID PROFILE :			
SERUM TRIGLYCERIDE:	143.4	mg/dl	50-160
SERUM CHOLESTEROL :	253.7	mg/dL.	130 - 200
HDL CHOLESTEROL :	50.8	mg/dL.	30 - 70
VLDL CHOLESTEROL :	28.6	mg/dL.	25 - 40
LDL CHOLESTEROL :	174.3	mg/dL.	85 - 150
CHOL/HDL CHOLESTROL RATIO	5.0	Low Risk Mod.Risk High Risk	0.0 - 3.5 3.5 - 5.0 > 5.0
LDL/HDL RATIO	3.4	Normal Range High Risk	2.5 - 3.0 > 3.0
SERUM URIC ACID :	4.5	mg/dL.	2.5 - 7.0

--{End of Report}--

Dr. Medha jain

M.B.B.S. (M.D. Path)

Consultant Pathologist

Reg. No. - G-33290 Gujrat

CMO. Reg. No. - MRT 869, Meerut

DR. KUMKUM DEEPAK MEMORIAL CENTRE, 302, W.K. ROAD, MEERUT

CALL : 0121-4009679, 9639688806, 09927286318, 7906584952, 9639251854 24 Hour Service, Home Visit

All Investigations have their limitation which are imposed by the limits of sensitivity and specificity of individual assay procedures as well as the specimen received by the laboratory.
Isolated laboratory investigation never confirm the final diagnosis of the disease. They only help in arriving at a diagnosis in conjunction with clinical presentation and other related investigation.

NOT FOR MEDICO LEGAL PURPOSE



Quality Management Services
ISO-9001:2015 Certified Lab

Laboratory Test-Report

MEERUT HISTOPATHOLOGY CENTRE

NAME : Mr. Anubhav Yadav
REFERRED BY : Dr. BOB
SAMPLE : Blood, Urine

DATE : 23/10/2023
AGE :
SEX : Male

TEST NAME	RESULTS	UNITS	REF.-RANGE
BIOCHEMISTRY			
LIVER FUNCTION TEST	-		
SERUM BILIRUBIN :			
TOTAL:	0.89	mg/dL.	0.2 - 1.0
DIRECT:	0.30	mg/dL.	0.1 - 0.3
INDIRECT:	0.59	mg/dL.	0.2 - 0.7
S.G.P.T. :	50.7	U/L	5 - 45
S.G.O.T. :	44.6	U/L	5 - 45
G.G.T.P. :	19.3	U/L	5.0-35.0 (37 C)
SERUM ALK. PHOSPHATASE :	84.5	IU/L.	25-100
SERUM PROTEINS :			
TOTAL PROTEINS:	7.3	Gm/dL.	5.5 - 8.5
ALBUMIN:	4.1	Gm/dL.	3.5 - 5.5
GLOBULIN:	3.2	Gm/dL.	2.3 - 3.5
A : G RATIO:	1.2		

--{End of Report}--

Dr. Medha Jain

M.B.B.S., (M.D. Path)

Consultant Pathologist

Reg. No. - G-33290 Gujrat

CMO. Reg. No. - MRT 869, Meerut

DR. KUMKUM DEEPAK MEMORIAL CENTRE, 302, W.K. ROAD, MEERUT

CALL : 0121-4009679, 9639688806, 09927286318, 7906584952, 9639251854 24 Hour Service, Home Visit

All Investigations have their limitation which are imposed by the limits of sensitivity and specificity of individual assay procedures as well as the specimen received by the laboratory. Isolated laboratory investigation never confirm the final diagnosis of the disease. They only help in arriving at a diagnosis in conjunction with clinical presentation and other related investigation.

NOT FOR MEDICO-LEGAL PURPOSE



Quality Management Services
ISO-9001:2015 Certified Lab

MEERUT HISTOPATHOLOGY CENTRE

Laboratory Test-Report

NAME : Mr. Anubhav Yadav
REFERRED BY : Dr. BOB
SAMPLE : Blood, Urine

DATE : 23/10/2023
AGE :
SEX : Male

TEST NAME	RESULTS	UNITS	REF.-RANGE
-----------	---------	-------	------------

HORMONE

THYROID PROFILE :			
Triiodothyronine (T3) :	1.25	nmol/litre.	0.95 - 2.5
Thyroxine (T4) :	102.3	nmol/litre.	60 - 120
THYROID STIMULATING HORMONE(TSH)	2.76	micro Iu/ml	0.20 - 5.0

Low Levels of T3 & T4 are seen in Non-Thyroidal illness
High Levels of T3 & T4 are found in and T3 Thyrotoxicosis
TSH Levels are raised in
TSH Levels are Low in

- Primary, Secondary & Tertiary Hypothyroidism and some
- Grave's Disease, Hyperthyroidism, Thyroid hormone resistance
- Primary Hypothyroidism
- Hyperthyroidism, Secondary Hypothyroidism.

CLINICAL PATHOLOGY

URINE EXAMINATION REPORT :

PHYSICAL EXAMINATION :

Volume : 30 ml
Colour : Pale Yellow
Appearance : Clear
Odour : Aromatic
Sediments : Nil
Sp. Gravity: 1020

BIOCHEMICAL EXAMINATION :

Sugar : Nil
Albumin : Nil
Reaction : Acidic

MICROSCOPIC EXAMINATION :

Red Blood Cells : Nil /H.P.F.
Pus Cells : 1-2 /H.P.F.
Epithelial Cells : 3-4 /H.P.F.

--{End of Report}--

Dr. Medha jain

M.B.B.S., (M.D. Path)

Consultant Pathologist

Reg. No. - G-33290 Gujrat

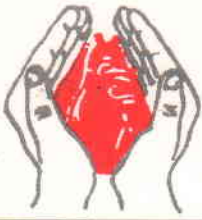CMO. Reg. No. - MRT 869, Meerut

DR. KUMKUM DEEPAK MEMORIAL CENTRE, 302, W.K. ROAD, MEERUT

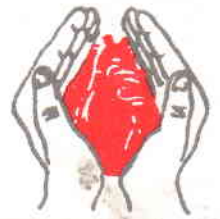CALL : 0121-4009679, 9639688806, 09927286318, 7906584952, 9639251854 24 Hour Service, Home Visit

All Investigations have their limitation which are imposed by the limits of sensitivity and specificity of individual assay procedures as well as the specimen received by the laboratory.
Isolated laboratory investigation never confirm the final diagnosis of the disease. They only help in arriving at a diagnosis in conjunction with clinical presentation and other related investigation.

NOT FOR MEDICO LEGAL PURPOSE



Shiva Cardiac Lab. & Diagnostic Research Centre Pvt. Ltd.



Near Chaurasia Nursing Home, Chhipi Tank, Meerut.

Ph.: 2664558, 9412578957

7669508292, 8449796280

MR. ANUBHAV YADAV
30 YRS/ MALE
OCT: 23. 2023

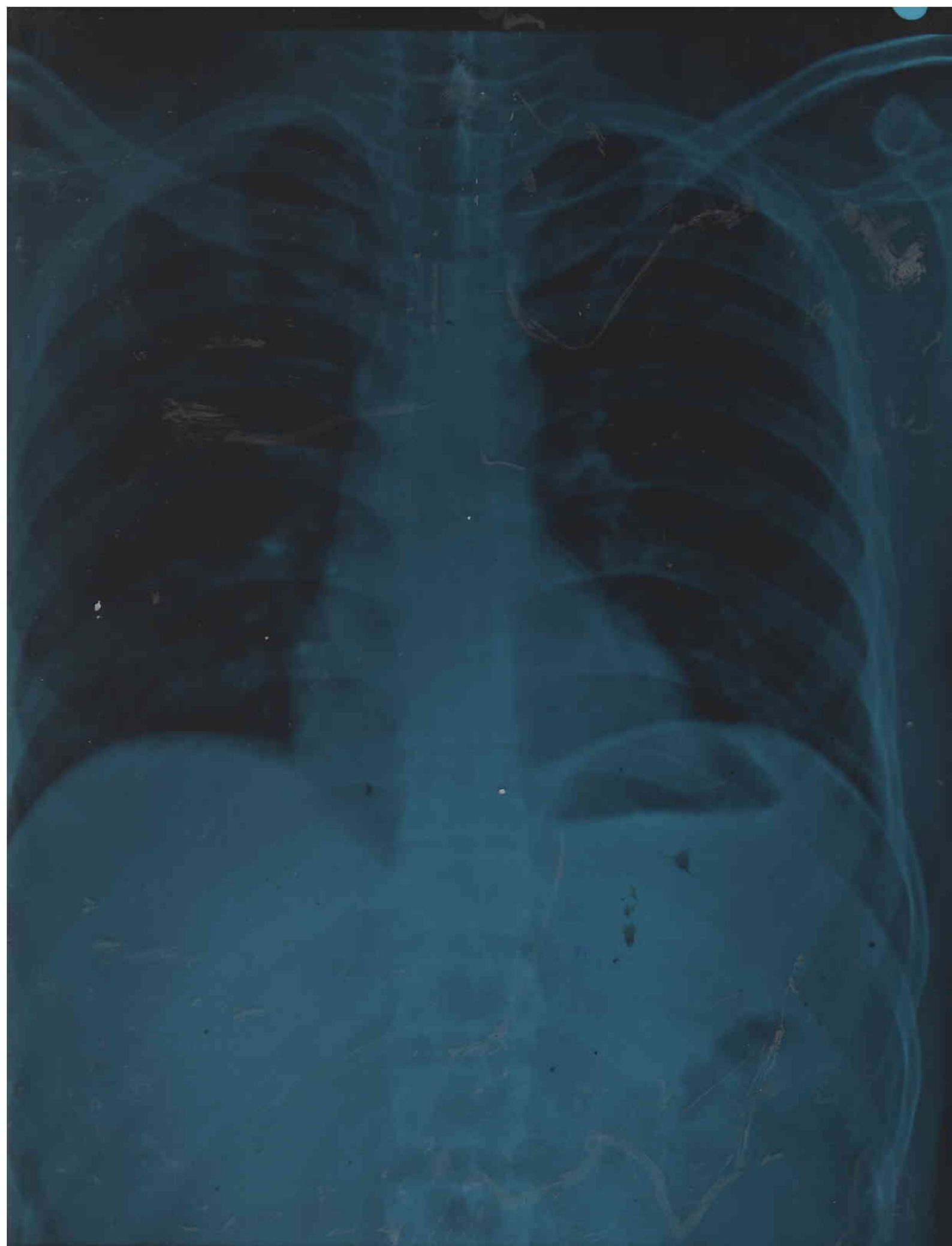
X.-RAY CHEST PA VIEW

- * Bony cage and soft tissues are normal.
- * Trachea is central.
- * Both hila are normal.
- * Both C.P. angles are clear.
- * Cardiac size is normal.
- * Both Domes of diaphragm are normal.
- * Faint shadow is seen in Right paracardiac region.

CONSULTANT
DR. TANUJ GARG
MD.(RAD.)

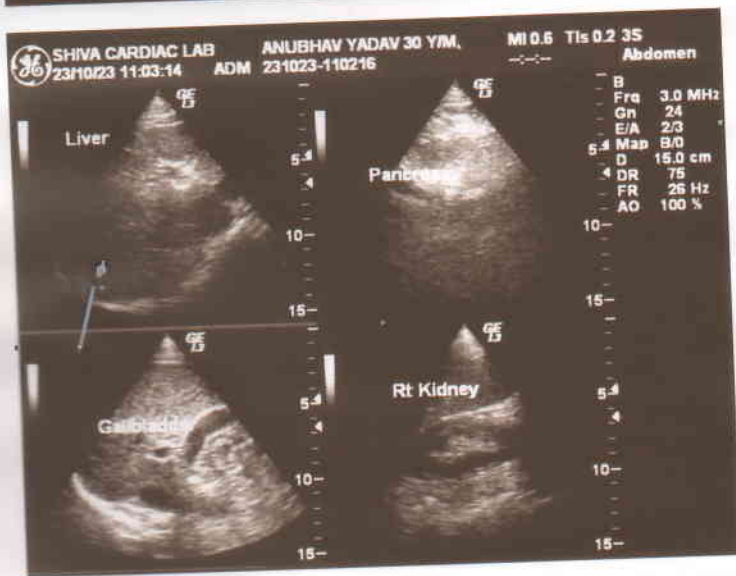
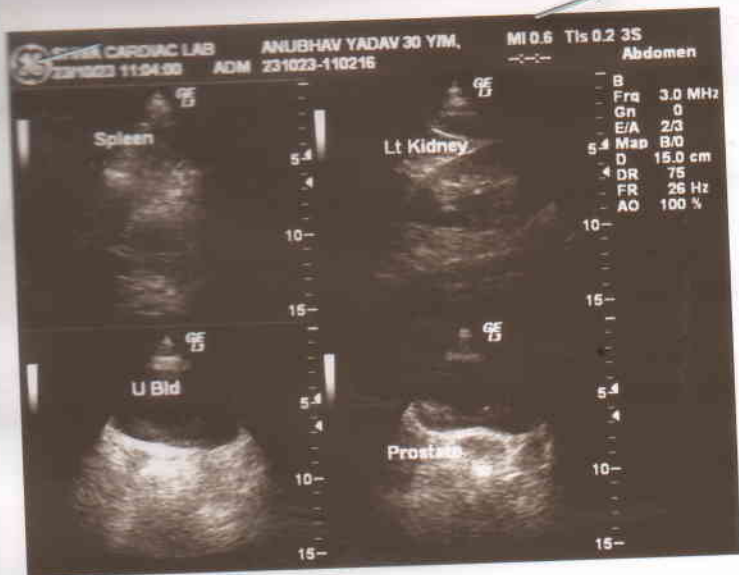
NOTE : All modern Machines/Procedures have their limitation, if there is a variance clinically, this examination may be repeated or re-evaluated by other investigations.

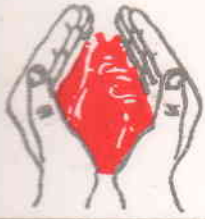NOT FOR MEDICO-LEGAL PURPOSE



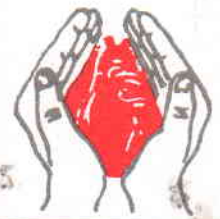
01541 ANIRBHAR, ANAND 30 Y.M. 20100023

SHIVA CARDIAC LAB 3445996280





Shiva Cardiac Lab. & Diagnostic Research Centre Pvt. Ltd.



Near Chaurasia Nursing Home, Chhipi Tank, Meerut.

Ph.: 2664558, 9412578957

7669508292, 8449796280

Name : MR. ANUBHAV YADAV
Age/sex : 30 YRS / MALE
Date : 23.10.2023

ULTRASOGRAPHY WHOLE ABDOMEN

LIVER – is normal in size. Echotexture and position is also normal.

No focal / diffuse abnormal echogenic lesion seen.

CBD is normal. Portal vein also normal.

I.H. Biliary channels are not dilated. Dome movements are not restricted.

GALL BLADDER –

Is normal in size shape and echotexture.

Wall thickness normal. No stone or mass seen.

KIDNEYS –

Both kidneys are normal in size shape & echo texture

Cortico-medulary distinction normal on Both side.

No stone seen in both kidneys

No hydronephrosis seen both side

PANCREAS is normal in size & shape and echo texture.

Head body and tail normal.

SPLEEN is normal in size. No evidence of focal lesion.

PROSTATE is normal in size

Echotexture is normal

URINARY BLADDER

Is well distended with normal wall thickness and contour.

No calculus / growth seen

No lymph nodes , pleural effusion , or ascites is seen.

IMP- NO SONOLOGICAL ABNORMALITY SEEN.

CONSULTANT:

DR S.CHARAN

MD.(SONOLOGIST)

NOTE : All modern Machines/Procedures have their limitation, if there is a variance clinically, this examination may be repeated or re-evaluated by other investigations.

NOT FOR MEDICO-LEGAL PURPOSE