

**Health Check up Booking Request(bobS16823),Package Code(PKG1000241),Beneficiary Code(38322)**

1 message

Mediwheel &lt;customercare@policywheel.com&gt;

20 September 2022 at 10:54

To: "vidhidiagnostics@gmail.com" &lt;vidhidiagnostics@gmail.com&gt;

Cc: Mediwheel CC &lt;customercare@mediwheel.in&gt;, Mediwheel CC &lt;mediwheelwellness@gmail.com&gt;

**011-41195959****Email:wellness@mediwheel.in**

Dear Vidhi Diagnostics,  
City : Ahmedabad . Location : .New Wadaj,

We have received the following request for Health Check up from

**Name** : Vaishali Jignesh Rajpal  
**Age** : 38  
**Gender** : Female  
**Member Relations** : Spouse  
**Package Name** : Medi-Wheel Metro Full Body Health Checkup Female Below 40  
**Package Code** : PKG1000241  
**User Location** : Gujarat,AHMEDABAD,380001  
**Contact Details** : 9909028003  
**Booking Date** : 20-09-2022  
**Appointment Date** : 24-09-2022

Member Information			
Booked Member Name	Age	Gender	Cost(In INR)
Vaishali Jignesh Rajpal	38	Female	Cashless
Total amount to be paid			Cashless

Please login to your account to confirm the same. Also you mail us for confirmation

**Package Name** : Medi-Wheel Metro Full Body Health Checkup Female Below 40 - Includes (37 )Tests

**Tests included in this Package** : Ecg, TSH, X-ray Chest, Stress Test (tmt)/ 2d Echo, Blood Sugar Postprandial, A:g Ratio, Blood Group, Total Cholesterol, Triglycerides, Fasting Blood Sugar, Ultrasound Whole Abdomen , Glycosylated Haemoglobin (hba1c), Hdl, Vldl, Urine Analysis, LDL, Total Protine, General Consultation, HDL/ LDL ratio, GGT(Gamma-glutamyl Transferase), Eye Check-up consultation, ALP (ALKALINE PHOSPHATASE), Uric Acid, AST/ALT Ratio, Serum Protein, CBC with ESR, Stool Analysis, Urine Sugar Fasting, Urine Sugar PP, T3, T4, Cholesterol Total / HDL Ratio, BUN, BUN/Creatinine Ratio, Bilirubin Total & Direct and Indirect, Albumin, Globulin



### Medical Examination Report

Date : 24/09/2022

#### 1. Personal Particulars

Name : Vaishali Rautpal

Age : 39 years

Gender : Male / Female

Marital Status : Married

Past & Present Medical History : H/O LSCS in 2013

#### 2. Clinical Medical Examination

Height : 151cm cm

Weight : 52kg kg

Blood Pressure : 118/84 mmHg

Pulse : 74 p/min

General Condition : (N)

Skin : (N)

Central Nervous System : (N)

Head & Neck : (N)

Cardiovascular System : (N)

Chest : (N)

Abdomen : (N)

Limbs : (N)

Last menstrual period : —

Vision: Right: (N)

Left: (N)

Colour vision : Normal/Colour Blind

Personal Habit : (N)

Remarks : Fit / Unfit for employment

Dr. Vidhi D. Modh

Dr's name, signature & chop  
Reg. No: G-74540

**Vidhi Diagnostics**

L-88, Swatantra-Senani Nagar,  
Opp. Akhbarnagar Bus Terminals,  
Nr. Akhbarnagar Circle,  
New Wadaj, Ahmedabad-13.



## Dr. Dinesh S. Modh

M.D., D.M.R.E. (Radiodiagnosis)  
Consultant Radiologist & Sonologist  
Ex. Junior Lecturer, B.J. Medical College, Civil Hospital, A'bad.  
Panel Doctor of L.I.C.



Patient's name: VAISHALI RAJPAL  
Reg. ID : R-7211-21  
Referred by : Dr. MEDIWHEEL

Age/Sex : 39 Years/Female  
Accession : 22744  
Date : 24/09/2022

### 2D- ECHO REPORT

#### FINAL CONCLUSION:

LV IS NORMAL SIZE. GOOD LV SYSTOLIC FUNCTION NO RWMA.  
LVEF - 60%. NO CONCENTRIC LVH.  
NORMAL LV COMPLIANCE.  
LA IS NORMAL SIZE. NO LA CLOT.  
RV IS NORMAL SIZE. GOOD RV SYSTOLIC FUNCTION.  
RA IS NORMAL SIZE.  
MITRAL VALVE IS NORMAL. NO MS. NO MR . NO MVP.  
AORTIC VALVE IS NORMAL. NO AS. NO AR.  
TRICUSPID VALVE IS NORMAL. NO TR. RVSP-26 mmHg. NO PAH.

NO CLOT, NO VEGETATION, NO PERICARDIAL EFFUSION.

#### DIMENSIONS:

AORTA	2.6 C.M
LEFT ATRIUM	2.7 C.M
LVDD	4.1 C.M.
IVSD	1.0 C.M
PWD	1.0 C.M
LVDS	2.6 C.M.

#### COLOUR DOPPLER FINDING:

STRUCTURE	VELOCITY m/sec
	Max
PULMONARY VALVE	0.7
MITRAL VALVE	E : 0.7 A: 0.4
AORTIC VALVE	1.0

*Dr. Avinash Bhaskar*  
Dr. Avinash Bhaskar  
MBBS, D Cardio  
Reg. No.: G-45946

**DR AVINASH BHASKAR**

ISO 9001:2015 Certified Diagnostics Center

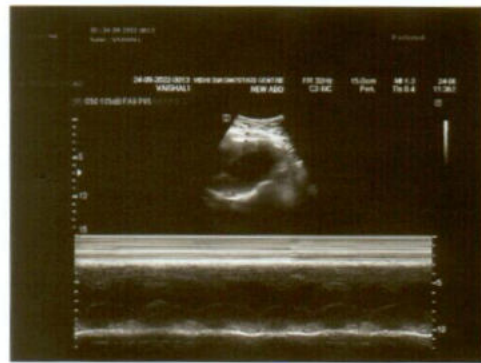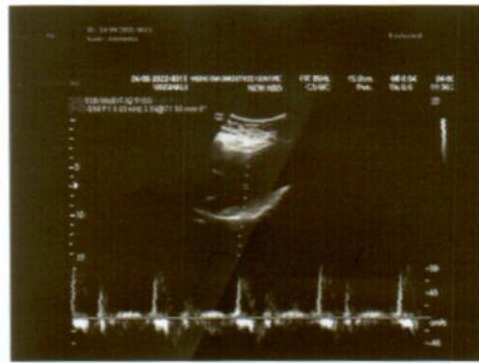
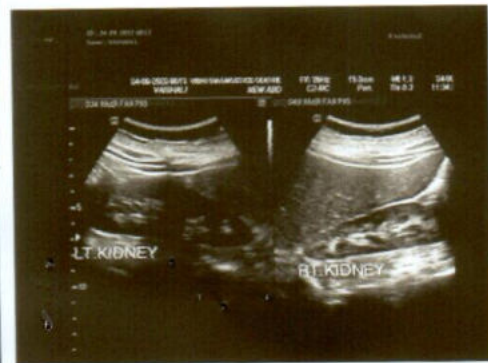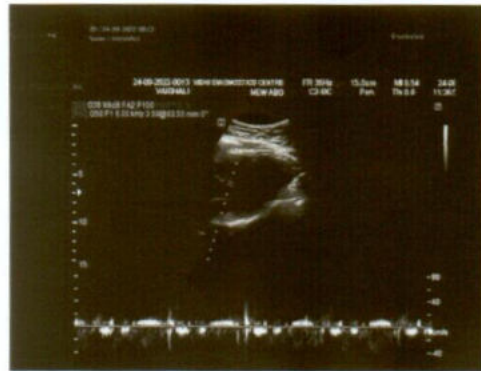
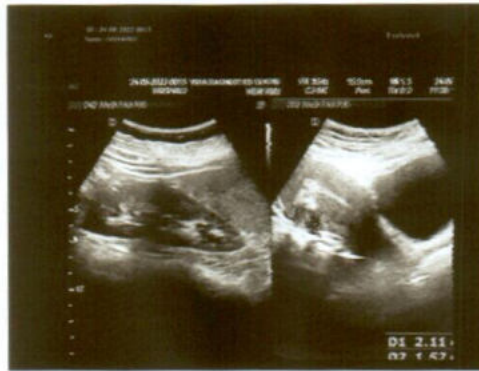
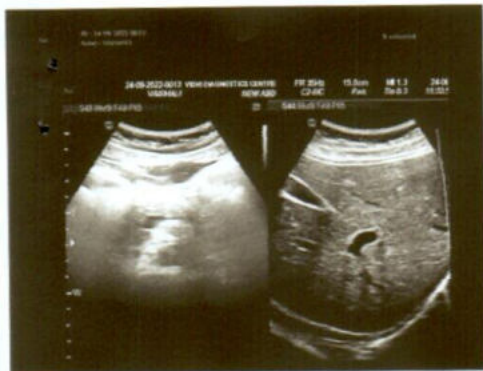Vidhi Imaging Center

L-86, Swatantra Senani Nagar, Opp. Akhbaragar Petrol Pump, Nr. Akhbaragar Circle, Nava-Vadaj, Ahmedabad - 380 013.

Phone : 079-2762 1406, Mobile : 98799 29406, 98250 09406, E-mail : vidhidiagnostics@gmail.com, Website : www.vidhidiagnostics.com

Time : Mon. to Sat. 9.00 am to 2.00 pm, 5.00 pm to 9.00 pm, Sunday 9.00 am to 12.00 Noon

FACILITIES : Live 3D-4D Sonography | Colour Doppler | Echo Cardiography | Interventional Radiology | Fetal Medicine | Digital X-Ray  
Digital Mammography | Digital OPG / TMJ | ECG / TMT / PFT / EEG / EMG | Pathology Laboratory | Health Check Up Plans | Pre Employment Check Up





## Dr. Dinesh S. Modh

M.D., D.M.R.E. (Radiodiagnosis)  
Consultant Radiologist & Sonologist  
Ex. Junior Lecturer, B.J. Medical College, Civil Hospital, A'bad.  
Panel Doctor of L.I.C.



Patient's name : VAISHALI RAJPAL  
Reg. ID : R-7211-21  
Referred by : Dr. MEDIWHEEL

Age/Sex : 39 Years/Female  
Accession : 22744  
Date : 24/09/2022

### **USG ABDOMEN**

**LIVER:** - Liver appears normal in size & show normal echotexture. No evidence of diffuse or focal lesion is seen. Intrahepatic biliary radicals appear normal. Portal vein and CBD appear normal. No e/o calculus is seen in bile duct.

**GALL BLADDER:** - Gall bladder is distended & appears normal. No evidence of calculus or cholecystitis is seen. No evidence of pericholecystic fluid is seen.

**SPLEEN:** - Spleen appears normal in size & shows normal echotexture. No evidence of diffuse or focal lesion is seen.

**PANCREAS:** - Pancreas appears normal size and echopattern. No e/o diffuse or focal lesion is seen. Main pancreatic duct appears normal.

**KIDNEY:** - Both Kidneys appear normal in size & echotexture.

**No e/o calculus or hydronephrosis or hydroureter is seen in either side.**

Cortico-medullary differentiation is maintained on either side.

Both suprarenal regions appear normal.

**RIF & BOWEL LOOPS (By high frequency probe):** - Normal.

No evidence of pre & para aortic lymphadenopathy is seen.

No evidence of free fluid is seen in abdomen.

No evidence of dilated or thickened bowel loops is seen.

**Urinary bladder:** - appears normal. No e/o calculus or mass lesion is seen in bladder.

**Uterus appears normal in size and shows 20x15mm sub-serous fibroid in posterior wall of body of uterus.**

Cervical region appears normal.

Endometrial thickness is 6.4mm.

Both adnexal regions appear normal.

No e/o free fluid is seen in pouch of Douglas.

Thanks for reference.

*Dr. Dinesh S. Modh*  
MD DMRE (Radiodiagnosis)  
G-23825

DR DINESH S. MODH

M.D. DMRE(RADIODIAGNOSIS)

ISO 9001:2015 Certified Diagnostics Center

Vidhi Imaging Center

L-86, Swatantra Senani Nagar, Opp. Akharnagar Petrol Pump, Nr. Akharnagar Circle, Nava-Vadaj, Ahmedabad - 380 013.

Phone : 079-2762 1406, Mobile : 98799 29406, 98250 09406, E-mail : vidhidiagnostics@gmail.com, Website : www.vidhidiagnostics.com

Time : Mon. to Sat. 9.00 am to 2.00 pm, 5.00 pm to 9.00 pm, Sunday 9.00 am to 12.00 Noon

FACILITIES : Live 3D-4D Sonography | Colour Doppler | Echo Cardiography | Interventional Radiology | Fetal Medicine | Digital X-Ray  
Digital Mammography | Digital OPG / TMJ | ECG / TMT / PFT / EEG / EMG | Pathology Laboratory | Health Check Up Plans | Pre Employment Check Up



## Dr. Dinesh S. Modh

M.D., D.M.R.E. (Radiodiagnosis)

Consultant Radiologist & Sonologist

Ex. Junior Lecturer, B.J. Medical College, Civil Hospital, A'bad.

Panel Doctor of L.I.C.



Patient's name: VAISHALI RAJPAL  
Reg. ID : R-7211-21  
Referred by : Dr. MEDIWHEEL

Age/Sex : 39 Years/Female  
Accession : 22744  
Date : 24/09/2022

### X-RAY CHEST (PA VIEW)

Both lung fields appear normal.  
No e/o consolidation or cavitations is seen.  
Both costo-phrenic angles appear clear.  
Cardiac size is with in normal limits.  
Both domes of diaphragm appear normal.  
Bony thoracic cage appears normal.

Thanks for reference.

Dr. Dinesh S. Modh  
MD DMRE (Radiodiagnosis)  
G-23825  
DR DINESH S. MODH  
M.D. DMRE(RADIODIAGNOSIS)

ISO 9001:2015 Certified Diagnostics Center

Vidhi Imaging Center

L-86, Swatantra Senani Nagar, Opp. Akharnagar Petrol Pump, Nr. Akharnagar Circle, Nava-Vadaj, Ahmedabad - 380 013.

Phone : 079-2762 1406, Mobile : 98799 29406, 98250 09406, E-mail : vidhidiagnostics@gmail.com, Website : www.vidhidiagnostics.com

Time : Mon. to Sat. 9.00 am to 2.00 pm, 5.00 pm to 9.00 pm, Sunday 9.00 am to 12.00 Noon

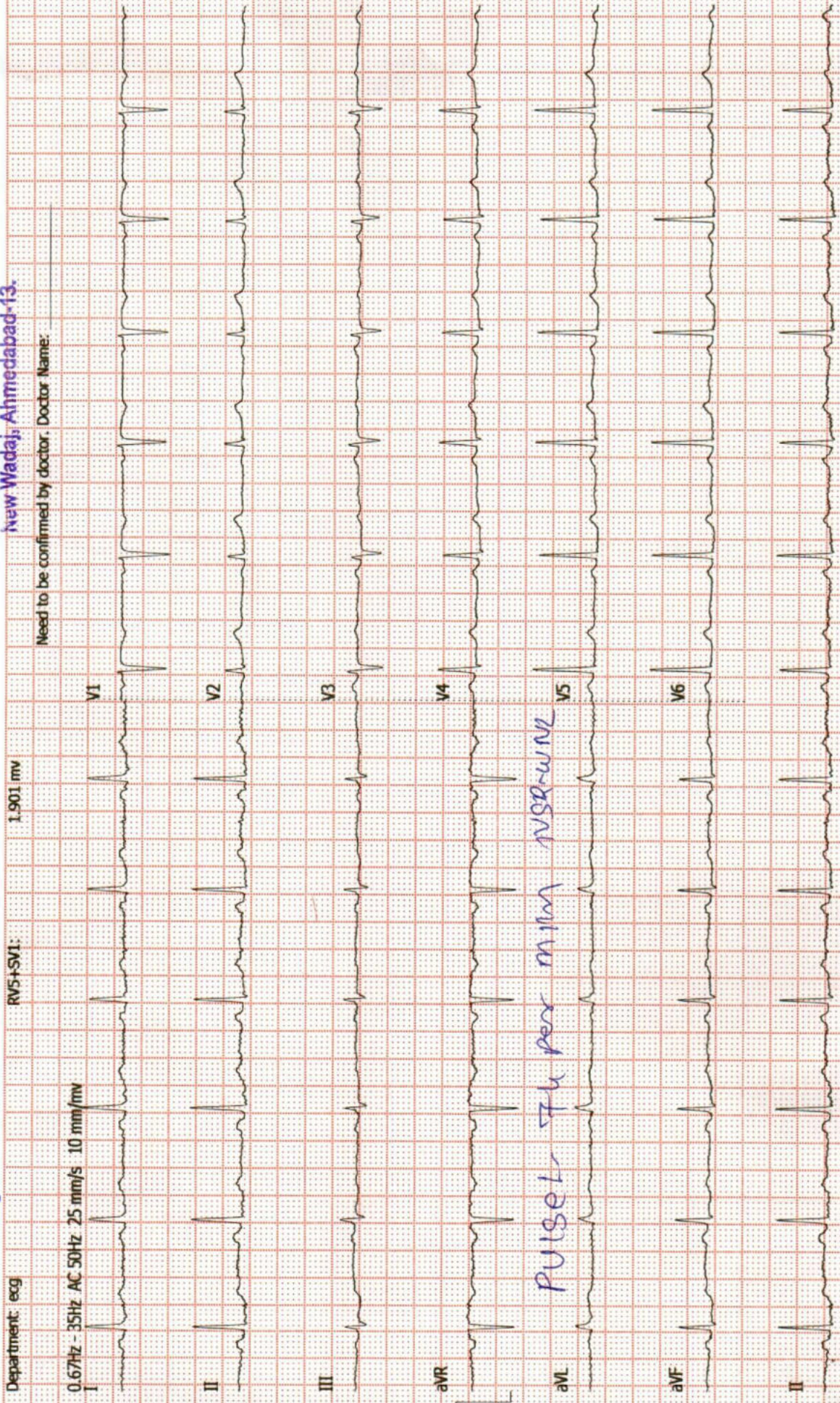
FACILITIES : Live 3D-4D Sonography | Colour Doppler | Echo Cardiography | Interventional Radiology | Fetal Medicine | Digital X-Ray  
Digital Mammography | Digital OPG / TMJ | ECG / TMT / PFT / EEG / EMG | Pathology Laboratory | Health Check Up Plans | Pre Employment Check Up



ID: 6201  
 Name: vaishali rajpal  
 Age: 39yrs  
 Sex: Female  
 Hospital: vidhidiagnostics Reg. No.: G-45946  
 HR : 74 bpm  
 PR : 146 ms  
 QRS : 72 ms  
 QT/QTc: 352/390 ms  
 P/QRS/T: 54/38/0 deg.  
 RV5/SV1: 1.062/-0.839 mv  
 RV5+SV1: 1.901 mv

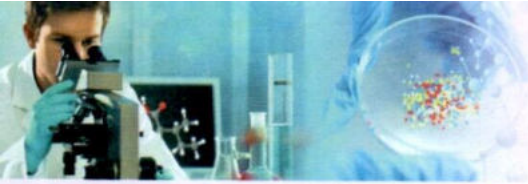**Vidhi Diagnostics**  
 86, Swatantra-Senani Nagar,  
 P. Akhbarnagar Bus Terminal,  
 Nr. Akhbarnagar Circle,  
 New Wadaj, Ahmedabad-13.

Need to be confirmed by doctor. Doctor Name: \_\_\_\_\_



Pulset 74 per min NSR-WNL





Pathology Department



Patient's name : VAISHALI JIGNESH RAJPAL  
Age/Sex : 39 Years/Female  
Referred by : Dr. MEDIWHEEL  
Collection Time : 09:48

Reg. ID : P-4267-21  
Accession : 22715  
Order Dt/time : 24/09/2022 09:48

### Complete Blood Count

Sample Type: EDTA

Test Name	Result	Units	Biological Reference Interval
<b><u>Blood Counts</u></b>			
Haemoglobin :	13.3	Gms%	12.5 - 16.0
Total R.B.C. :	<b>4.04</b>	mill/c.mm	4.2 - 5.4
Total W. B. C. :	7,240	/cu mm	4000 - 10500
Platelet Count :	2,65,000	/cu.mm	1,50,000 - 4,50,000
<b><u>Differential Count</u></b>			
Neutrophils :	66	%	40 - 70
Lymphocytes :	28	%	20 - 40
Eosinophils :	02	%	1 - 4
Monocytes :	04	%	2 - 6
Basophils :	00	%	0 - 01
<b><u>Blood Indices</u></b>			
P. C. V :	39.5	%	37 - 47
M. C. V. :	97.9	fl	78 - 100
M.C.H :	<b>32.8</b>	pg	27 - 31
M. C. H. C :	33.6	%	32 - 36
R.D.W :	14.0	%	11.5 - 14.0

### E.S.R.( Westergren Method )

After one hour : 08 mm/hr 3 - 12

TESTS DONE ON FULLY AUTOMATED HEMATOLOGY ANALYZER.

*Dr. Gayatri M. Mehta*  
M. D. (Patho)

Reg. No G-32215  
DR GAYATRI MEHTA  
MD(PATHOLOGY)

DR. ANAND D. PARIKH  
MD(PATHOLOGY)

LAB USE ONLY (Entered by :GM Enter Date/Time:24/09/2022 11:45:00 AM) (Verify by :GM Verify Date/Time:24/09/2022 5:39:00 PM)

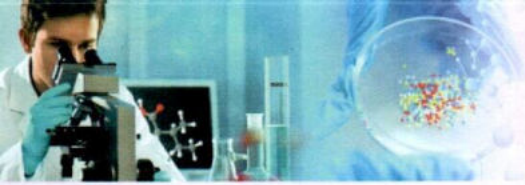ISO 9001:2015 Certified Diagnostics Center  
Vidhi Imaging Center | Pathology Department

L-86, Swatantra Senani Nagar, Opp. Akhbarnagar Petrol Pump, Nr. Akhbarnagar Circle, Nava-Vadaj, Ahmedabad - 380 013.  
Ph. (Pathology) : 079-2764 5405, 8849893954 M. 98799 29406, 98250 09406, E-mail : vidhidiagnostics@gmail.com, Web. : www.vidhidiagnostics.com  
Time (Pathology) : Mon. to Sat. 8.30 am to 8.00 pm, Sunday 9 am to 12 Noon

*Pathology means science behind medicine*

**CT SCAN & CBCT FACILITY NOW AVAILABLE**





Pathology Department



Patient's name : VAISHALI JIGNESH RAJPAL  
Age/Sex : 39 Years/Female  
Referred by : Dr. MEDIWHEEL  
Collection Time : 09:48

Reg. ID : P-4267-21  
Accession : 22715  
Order Dt/time : 24/09/2022 09:48

**Blood Group**

Sample Type: EDTA sample.

Test Name	Result
BG :	" A "
RH :	POSITIVE
Remarks	Done by forward grouping method.

**Blood Glucose**

Sample Type: Serum

Test Name	Result	Units	Biological Reference Interval
Fasting Blood Glucose : GOD-POD Method.	90.7	mg/dl	70 - 110

**Blood Glucose**

Sample Type: Serum

Test Name	Result	Units	Biological Reference Interval
Post Prandial Blood Glucose After 2hr. : GOD-POD Method.	107.4	mg/dl	80 - 140

*Dr. Gayatri M. Mehta*

M. D. (Patho)

Recd No. G-32215

DR GAYATRI MEHTA  
MD(PATHOLOGY)

DR. ANAND D. PARIKH  
MD(PATHOLOGY)

LAB USE ONLY (Entered by :GM Enter Date/Time:24/09/2022 2:02:00 PM) (Verify by :GM Verify Date/Time:24/09/2022 5:39:00 PM)

ISO 9001:2015 Certified Diagnostics Center

Vidhi Imaging Center | Pathology Department

L-86, Swatantra Senani Nagar, Opp. Akhbarnagar Petrol Pump, Nr. Akhbarnagar Circle, Nava-Vadaj, Ahmedabad - 380 013.

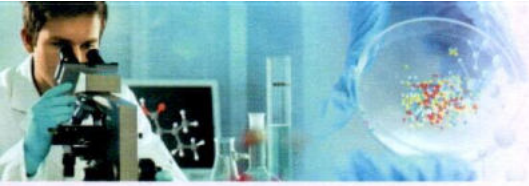Ph. (Pathology) : 079-2764 5405, 8849893954 M. 98799 29406, 98250 09406, E-mail : vidhidiagnostics@gmail.com, Web. : www.vidhidiagnostics.com

Time (Pathology) : Mon. to Sat. 8.30 am to 8.00 pm, Sunday 9 am to 12 Noon

*Pathology means science behind medicine*

**CT SCAN & CBCT FACILITY NOW AVAILABLE**





Pathology Department



Patient's name : VAISHALI JIGNESH RAJPAL  
Age/Sex : 39 Years/Female  
Referred by : Dr. MEDIWHEEL  
Collection Time : 09:48

Reg. ID : P-4267-21  
Accession : 22715  
Order Dt/time : 24/09/2022 09:48

### HbA1C

Sample Type: Serum

Test Name	Result	Units	Biological Reference Interval
HbA1C :	4.5	%	Non-diabetic: 4.2-6.2 Pre-diabetic : 6.3-7.2 Diabetic : 7.3-8.2
Mean Blood Glucose of Last 03 months.	82.45	mg/dl	

#### Comment

\*As per the new 2009 update of American Diabetes Association regarding HbA1C & Mean Blood Glucose relationship.

#### NOTE:

This test is used to monitor diabetic patients compliance with the therapeutic regimen and logo It's level is proportional to both the average blood glucose concentration and the life span of the red blood cells (RBC) in circulation. HbA1c values are free of day to day glucose fluctuations and are unaffected by exercise or recent food intake.

*Dr. Gayatri M. Mehta*  
M. D. (Patho)  
Reg. No. G-32215

DR GAYATRI MEHTA  
MD(PATHOLOGY)

DR. ANAND D. PARIKH  
MD(PATHOLOGY)

LAB USE ONLY (Entered by :GM Enter Date/Time:24/09/2022 2:02:00 PM) (Verify by :GM Verify Date/Time:24/09/2022 5:39:00 PM)

ISO 9001:2015 Certified Diagnostics Center

Vidhi Imaging Center | Pathology Department

L-86, Swatantra Senani Nagar, Opp. Akharnagar Petrol Pump, Nr. Akharnagar Circle, Nava-Vadaj, Ahmedabad - 380 013.

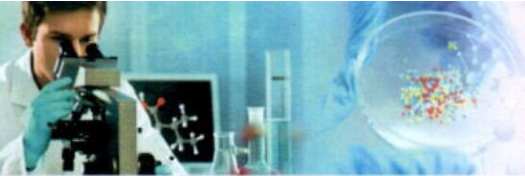
Ph. (Pathology) : 079-2764 5405, 8849893954 M. 98799 29406, 98250 09406, E-mail : vidhidiagnostics@gmail.com, Web. : www.vidhidiagnostics.com

Time (Pathology) : Mon. to Sat. 8.30 am to 8.00 pm, Sunday 9 am to 12 Noon

*Pathology means science behind medicine*

**CT SCAN & CBCT FACILITY NOW AVAILABLE**





Pathology Department



Patient's name : VAISHALI JIGNESH RAJPAL  
 Age/Sex : 39 Years/Female  
 Referred by : Dr. MEDIWHEEL  
 Collection Time : 09:48

Reg. ID : P-4267-21  
 Accession : 22715  
 Order Dt/time : 24/09/2022 09:48

**Urine Analysis**

Sample Type: Urine

Test Name	Result	Units	Biological Reference Interval
<b><u>Physical Examination</u></b>			
Quantity :	30	ml	0 - 500 ml
Colour :	Pale Yellow		Pale Yellow
Transparency :	Slight Turbid.		Clear
Reaction :	Acidic		4.6 - 8.0
Specific Gravity :	1.010		1.016 - 1.022
Sediment :	Present		
<b><u>Chemical Examination</u></b>			
Albumin :	Present (Faint Trace)		Absent
Sugar :	NIL		Absent
Acetone :	Absent		Absent
Bile Salts :	Absent		Absent
Bile Pigments :	Absent		Absent
Urobilogen :	Absent		Absent
Nitrites :	Absent		Absent
<b><u>Microscopic Examination</u></b>			
Red blood Cells :	1-2	/h.p.f	Absent
Pus Cells :	2-3	/h.p.f	Absent
Epithelial Cells :	1-2	/h.p.f	< 10.0
Amorphous :	Absent	/h.p.f	Absent
Bacteria :	Absent	/h.p.f	Absent
Crystals :	Absent	/h.p.f	Absent
Casts :	Absent	/h.p.f	Absent
Fungus :	Not seen	/h.p.f	Absent

*Dr. Gayatri M. Mehta*  
 M. D. (Patho)  
 No. G-32215

DR GAYATRI MEHTA  
 MD(PATHOLOGY)

DR. ANAND D. PARIKH  
 MD(PATHOLOGY)

LAB USE ONLY (Entered by : GM Enter Date/Time: 24/09/2022 2:03:00 PM) (Verify by : GM Verify Date/Time: 24/09/2022 5:39:00 PM)

L-86, Swatantra Senani Nagar, Opp. Akhbarnagar Petrol Pump, Nr. Akhbarnagar Circle, Nava-Vadaj, Ahmedabad - 380 013.

Ph. (Pathology) : 079-2764 5405, 8849893954 M. 98799 29406, 98250 09406, E-mail : vidhidiagnostics@gmail.com, Web. : www.vidhidiagnostics.com

Time (Pathology) : Mon. to Sat. 8.30 am to 8.00 pm, Sunday 9 am to 12 Noon

*Pathology means science behind medicine*

**CT SCAN & CBCT FACILITY NOW AVAILABLE**



*Dr. Vidhi*

મારી આધાર, મારી આભાર

9156 0489 2940



ભારત સરકાર  
Government of India

રાજપાલ વૈશાલી  
Rajpal Vaishali  
જન્મ તારીખ / DOB : 10/06/1983  
સ્ત્રી / Female

Dr. Vidhi D. Modh  
MBBS  
Reg. No. G-74540

**Vidhi Diagnostics**  
L-88, Swatntra-Senani Nagar,  
Opp. Akhbarnagar Bus Terminals,  
Nr. Akhbarnagar Circle,  
New Wadaj, Ahmedabad-13.




EMAIL ID  
VIDHIDIAGNOSTICS@  
GMAIL.COM



GPS Map Camera

AKHBAR



Ahmedabad, Gujarat, India

15, Pragatinagar, Nirnay Nagar,

Ahmedabad, Gujarat 380061, India

Lat 23.068108°

Long 72.561757°

24/09/22 09:35 AM GMT +05:30

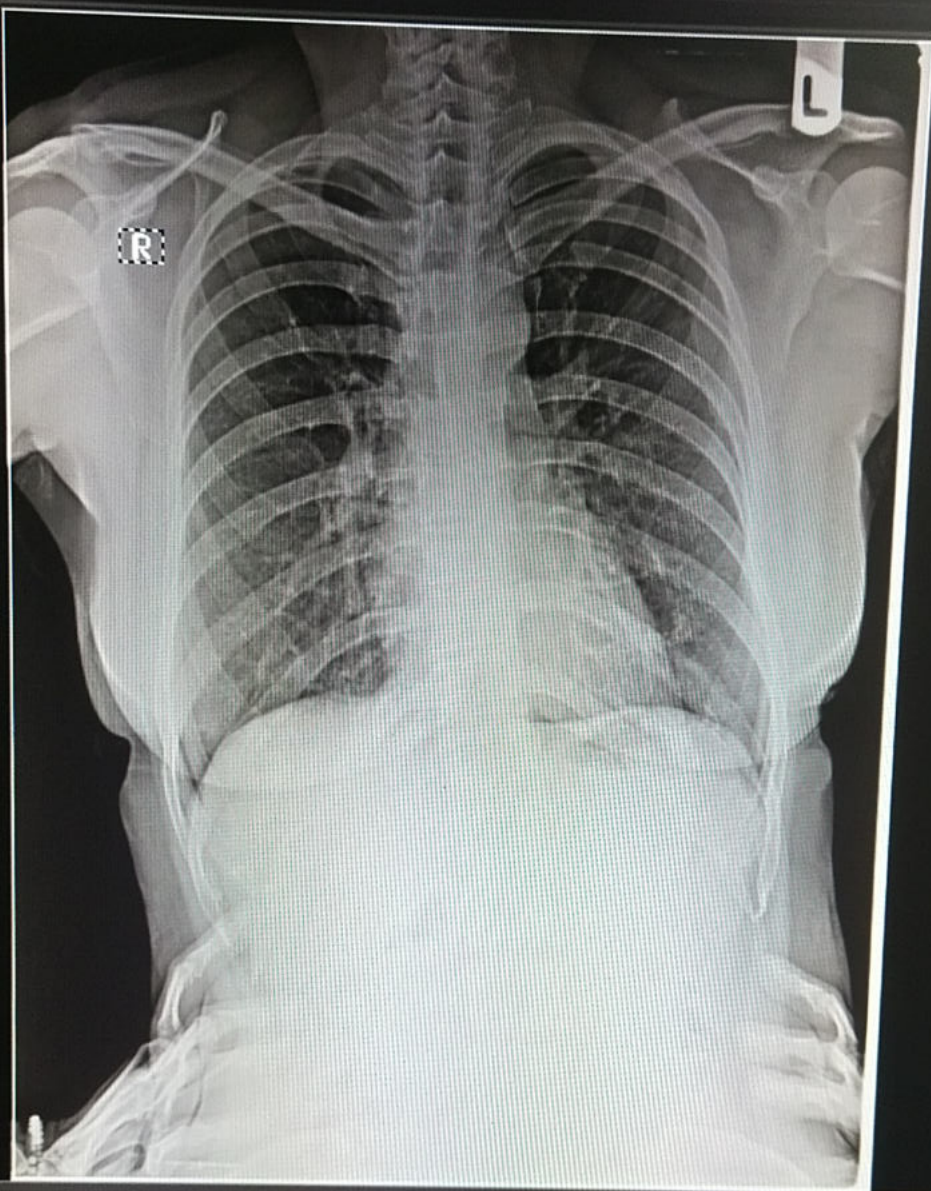
Dr. Vidhi D. Modh  
MBBS  
Reg. No. G-74540

Vidhi Diagnostics  
L-86, Swatantra-Senani Nagar,  
Opp. Akhbarnagar Bus Terminals,  
Nr. Akhbarnagar Circle,  
New Wadaj, Ahmedabad-13.



24092212

VAISHALI RAJPAL 39 YR



DELL