

ID: 45
AMIT KUMAR
Male 38 Years

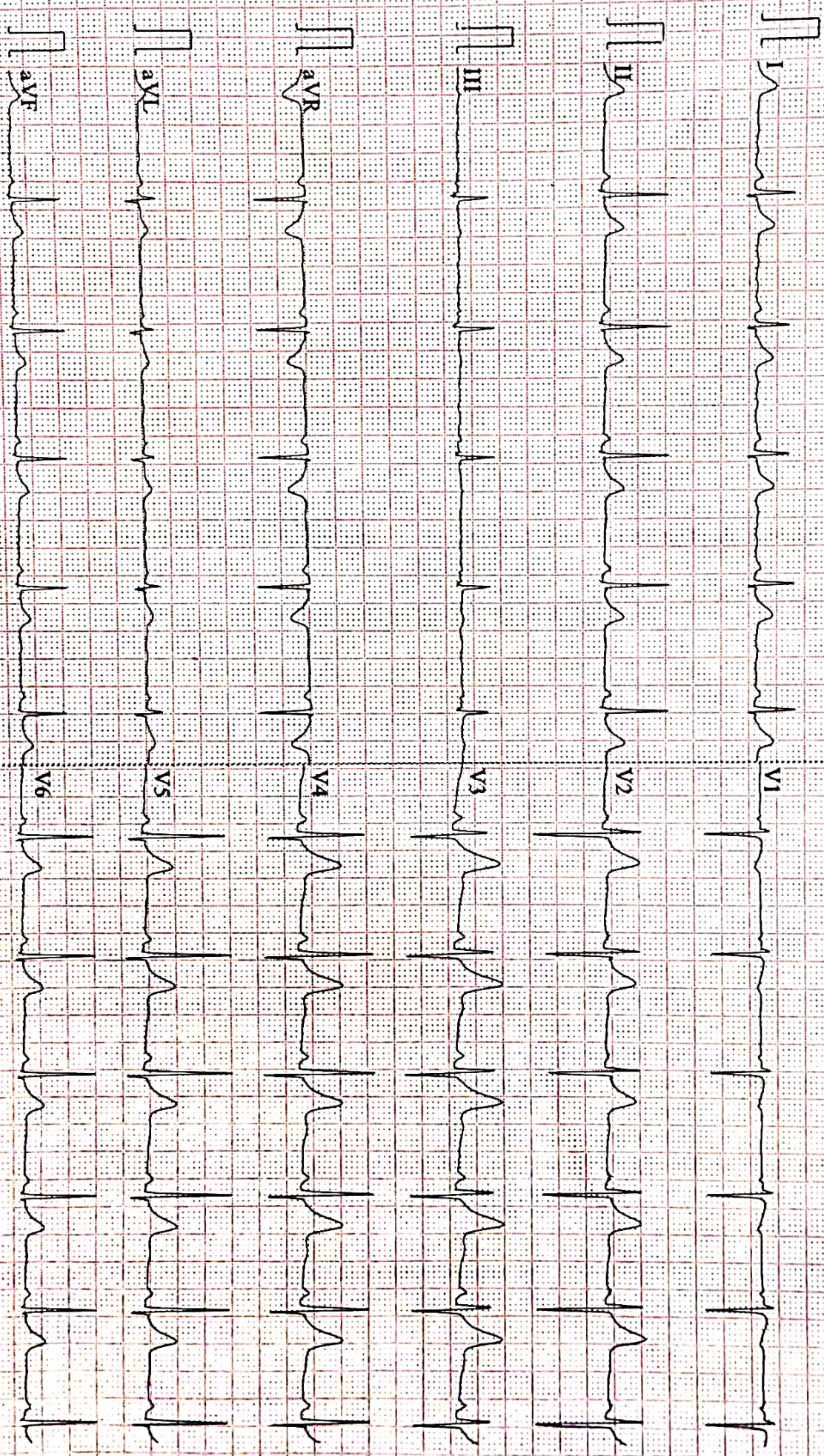
19-09-2021 10:30:42 PM

BPL

Diagnosis Information:
Sinus Rhythm
Normal ECG

HR : 67 bpm
P : 82 ms
PR : 129 ms
QRS : 73 ms
QT/QTc : 344/364 ms
PQRST : 31/56/37 °
RV5/SV1 : 1.56/4.09/72 mV

Report Confirmed by:



0.67~100Hz AC50 25mm/s 10mm/mV 2=5.0s V2.2 SEMIP V1.61 DAIGNOSTIC



Name :- Amit Kumar
Refd by :- BOB

Age/Sex:- Yrs/M
Date :-19/09/21

Thanks for referral.

REPORT OF USG OF WHOLE ABDOMEN

- Liver** :- Normal in size (14.0cm) with normal echotexture. No focal or diffuse lesion is seen. IHBR are not dilated. PV is normal in course and calibre with echofree lumen
- G. Bladder** :- It is normal in shape, size & position. It is echofree & shows no evidence of calculus, mass or sludge.
- CBD** :- It is normal in calibre & is echofree.
- Pancreas** :- Normal in shape, size & echotexture. No evidence of parenchymal / ductal calcification is seen. No definite peripancreatic collection is seen.
- Spleen** :- Normal in size with normal echotexture. No focal lesion is seen. No evidence of varices is noticed.
- Kidneys** :- Both kidneys are normal in shape, size & position. Sinus as well as cortical echoes are normal. No evidence of calculus, space occupying lesion or hydronephrosis is seen.
- Right Kidney** measures 10.3x4.7cm and **Left Kidney** measures 10.0x4.6cm.
- Ureters** :- Ureters are normal.
- U. Bladder**:- It is echofree. No evidence of calculus, mass or diverticulum is seen.
- Prostate** :- Normal in size & echotexture.
- Others** :- No ascites or abdominal adenopathy is seen.
- No free subphrenic / basal pleural space collection is seen.

IMPRESSION:- Normal Scan of USG -Whole Abdomen.

Dr Anju Kumari
MBS, DMRD(Radio-Diagnosis)
Consultant Radiologist