



A.L.C. Advance Imaging Diagnostics

ISO 9001:2015 Certified center

(A Unit of P.K.Arogyam Health & Wellness Center)

E-95, P.C. Colony, Near Sai Netryalaya Transformer, Kankarbagh, Patna - 20

alcdiagnostics@gmail.com

www.pkarogayamhealthcheckup.com

7050037694, 8271206196

OPINION MUST BE CORRELATES WITH CLINICALLY & OTHER INVESTIGATION FOR FINAL DIAGNOSIS. NOT FOR MEDICO LEGAL PURPOSE

PATIENT NAME : Mrs. SUDHA RANI

PATIENT ID: 4076

COL DATE : 12/03/2022 REPORTING DATE: 13/03/2022 AGE SEX : 53 YRS/F

REF.BY : DR./ MEDIWHEEL.

Total Triiodothyronin T3	1.01 ng/mL	0.80 -2.00 ng/mL
Total Thyroxin T4	6.90 µg/dL	5.10 -14.10 µg/dL
Serum TSH	3.11 µIU/mL	0.27 – 4.20 µIU/mL

THYROID DISORDER (>: Increase: < Decrease: n Normal

1. T3(n) T4(n) TSH(n) :EUTHYROID STATE:
2. T3(>) T4(>) TSH(<): HYPERTHYROIDISM:
3. T3(<)T4(<) TSH(>): HYPOTHYROIDISM:
4. T3(n)T4(n) TSH(>) : SUB-CLINICAL HYPO-THYROIDISM:
5. T3(n)T4(n) TSH(<): SUB-CLINICAL HYPER-THYROIDISM:
6. T3(>) T4(n) TSH(<): T3 THYROTOXICOSIS:

Total T3/T4 level is dependent on Level:

So determination of free T3/T4is a better MARKER of Thyroid Function.



Dr. Ankur Kumar
MBBS, MD
Consultant Pathology
Reg. No 39540

Consultant Radiologist

ESTD BY:-

Dr. P. K. Tiwari
MD, M Sc (Radio Imaging)
Ph D (Ait Nuclear Medicine)
Consultant Imaginologist & Sonologist

Dr. S. Kumar
MD (Pat)
Consultant Pathologist

Dr. Abhishek Kumar
MBBS, MD
Consultant Neuropatho Physiologist

Dr. Anjali
MBBS, MD
Consultant(TMT,EEG Specialist)

Dr. Kumari Suman
MBBS, DGO, MD
Consultant (TVS & HSG Specialist)

PRINTING MISTAKE SHOULD BE REPORTED BACK IMMEDIATELY/यहाँ जन्म से पहले भ्रुण का लिंग जाँच नहीं होता है ।



A.L.C. Advance Imaging Dignostics

ISO 9001:2015 Certified center

(A Unit of P.K.Arogyam Health & Wellness Center)

E-95, P.C. Colony, Near Sai Netryalaya Transformer, Kankarbagh, Patna - 20

alcdiagnostics@gmail.com

www.pkarogyamhealthcheckup.com

7050037194, 8271206196

OPINION MUST BE CORRELATES WITH CLINICALLY & OTHER INVESTIGATION FOR FINAL DIAGNOSIS. NOT FOR MEDICO LEGAL PURPOSE

PATIENT NAME : Mrs. SUDHA RANI

PATIENT ID: 4076

COL DATE : 12/03/2022 REPORTING DATE: 12/03/2022 AGE SEX : 53 YRS/F

REF.BY : DR. /MEDIWHEEL.

TEST NAME	RESULT	Unit	REF.RANGE
BLOOD SUGAR (F)	79.0 mg/dl		70 - 110 mg/dl

LIPID PROFILE:-

TOTAL CHOLESTROL	162.4 mg/dl		130 -250 mg/dl
TRIGLYCERIDE	126.4 mg/dl		50 -160 mg/dl
HDL CHOLESTROL	42.0 mg/dl		30 - 60 mg/dl
LDL CHOLESTROL	95.5 mg/dl		80 -130 mg/dl
VLDL CHOLESTROL	25.3 mg/dl		15 - 40 mg/dl
T.CH./HDL RATIO	3.8:1		Upto 5:1
LDL/HDL RATIO	2.2:1		2 - 4:1



Dr. Ankur Kumar
MBBS, MD
Consultant Pathologist
Reg. No 39540
Consultant Radiologist

ESTB BY:-

Dr. P. K. Tiwari
MD, M.Sc (Radio Imaging)
Ph.D (Ab Nuclear Medicine)
Consultant Imagingologist & Technologist

Dr. S. Kumar
MD (Path)
Consultant Pathologist

Dr. Abhishek Kumar
MBBS, MD
Consultant Neuropathologist

Dr. Anjali
MBBS, MD
Consultant (TMT, EEG Specialist)

Dr. Kumari Suman
MBBS, DGO, MD
Consultant (TVS & HSG Specialist)

PRINTING MISTAKE SHOULD BE REPORTED BACK IMMEDIATELY/ यहाँ जन्म से पहले ब्रुग का लिंग जॉय नहीं होता है ।



A.L.C. Advance Imaging Dignostics

ISO 9001:2015 Certified center

(A Unit of P.K.Arogyam Health & Wellness Center)

E-95, P.C. Colony, Near Sai Netryalaya Transformer, Kankarbagh, Patna - 20

alcdiagnostics@gmail.com

www.pkarogyamhealthcheckup.com

7050037694, 8271206196

OPINION MUST BE CORRELATES WITH CLINICALLY & OTHER INVESTIGATION FOR FINAL DIAGNOSIS. NOT FOR MEDICO LEGAL PURPOSE

PATIENT NAME : Mrs. SUDHA RANI

PATIENT ID: 4076

COL DATE : 12/02/2022 REPORTING DATE: 12/03/2022 AGE SEX:- 53 YRS/F

REF.BY : DR./ MEDIWHEEL.

TEST NAME	RESULT	Unit	REF.RANGE
LFT:-			
SGPT	15.0	IU/L	5 - 48 IU/L
S G O T	18.2	IU/L	5 - 40 IU/L
ALKALINE PHOSPHATASE	79.0	IU/L	25 - 147 IU/L
TOTAL PROTIIN	7.4	g/dl	6.0 - 8.7 g/dl
SERUM ALBUMIN	4.6	g/dl	3.5 - 5.4 g/dl
SERIUM GLUBLINE	2.8	g/dl	2.3 - 3.6 g/dl
AG RATIO	1.6 : 1		1.0 - 2.3 g/dl
BILIRUBIN			
TOTAL	0.54	mg/dl	0.1 - 1.1 mg/dl
IRECT	0.24	mg/dl	0.0 - 0.32 mg/dl
INDIRECT	0.30	mg/dl	0.0 - 0.78 mg/dl
KFT/RFT			
URIC ACID	5.2	mg/dl	3.2 - 7.0 mg/dl
SERUM CREATNINE	0.9	mg/dl	0.6 - 1.5 mg/dl
BLOOD URIA	30.1	mg/dl	5 - 45 mg/dl
BLOOD URIA NITROZEN(BUN).	14.0	mg/dl	13 - 39 mg/dl



Dr. Ankur Kumar
 MBBS, MD
 Consultant Pathologist
 Reg. No. 39540
 Consultant Radiologist

ESTB BY:-

Dr. P. K. Tiwari
 MD, M.Sc (Radio Imaging)
 Ph D (Ali Nuclear Medicine)
 Consultant Imagonologist & Sonologist

Dr. S. Kumar
 MD (Pat)
 Consultant Pathologist

Dr. Abhishek Kumar
 MBBS, MD
 Consultant Neuropatho Physiologist

Dr. Anjali
 MBBS, MD
 Consultant (TMT, EEG Specialist)

Dr. Kumari Suman
 MBBS, DGO, MD
 Consultant (TVS & HSG Specialist)

PRINTING MISTAKE SHOULD BE REPORTED BACK IMMEDIATELY/ यहाँ जन्म से पहले भ्रुण का लिंग जाँच नहीं होता है ।



A.L.C. Advance Imaging Dignostics

ISO 9001:2015 Certified center

(A Unit of P.K.Arogyam Health & Wellness Center)

E-95, P.C. Colony, Near Sai Netryalaya Transformer, Kankarbagh, Patna - 20

alcdiagnostics@gmail.com

www.pkarogayamhealthcheckup.com

7050037694, 8271206196

OPINION MUST BE CORRELATES WITH CLINICALLY & OTHER INVESTIGATION FOR FINAL DIAGNOSIS. NOT FOR MEDICO LEGAL PURPOSE

PATIENT NAME : Mrs. SUDHA RANI PATIENT ID: 4076
 COL DATE : 12/03/2022 REPORTING DATE: 13/03/2022 AGE SEX : 53 YRS/F
 REF.BY : DR./ MEDIWHEEL

GLYCOSYLATED HEMOGLOBIN

TEST NAME	RESULT	Unit	REF.RANGE
HbA1c	4.4 %		Below 5.7 % : Normal 5.7 – 6.4 % : Prediabetic > = 6.5 % : Diabetic
AVERAGE PLASMA GLUCOSE	95.0 mg/dl		90 – 120 mg/dl : Good Control 121– 150 mg/dl : Fair Control 151- 180 mg/dl: Unsatisfactory Control >180 mg/dl : Poor Control



Dr. Ankur Kumar
 MBBS, MD
 Consultant Pathologist
 Reg. No 39540

Consultant Radiologist

ESTB BY:-

Dr. P. K. Tiwari
 MD, M.Sc (Radio Imaging)
 Ph.D (Ab Nuclear Medicine)
 Consultant Imaginologist & Sonologist

Dr. S. Kumar
 MD (Pat)
 Consultant Pathologist

Dr. Abhishek Kumar
 MBBS, MD
 Consultant Neuropatho Physiologist

Dr. Anjali
 MBBS, MD
 Consultant (TMT, EEG Specialist)

Dr. Kumari Suman
 MBBS, DGO, MD
 Consultant (TVS & HSG Specialist)

PRINTING MISTAKE SHOULD BE REPORTED BACK IMMEDIATELY/ यहाँ जन्म से पहले म्रुण का लिंग जाँच नहीं होता है ।



A.L.C. Advance Imaging Dignostics

ISO 9001:2015 Certified center

(A Unit of P.K.Arogyam Health & Wellness Center)

E-95, P.C. Colony, Near Sai Netryalaya Transformer, Kankarbagh, Patna - 20

alcdiagnostics@gmail.com

www.pkarogyamhealthcheckup.com

7050037694, 8271206196

OPINION MUST BE CORRELATES WITH CLINICALLY & OTHER INVESTIGATION FOR FINAL DIAGNOSIS. NOT FOR MEDICO LEGAL PURPOSE

PATIENT NAME : Mrs. SUDHA RANI PATIENT ID: 4076
 COL DATE : 12/03/2022 REPORTING DATE: 12/03/2022 AGE SEX:- 53 YRS/F
 REF.BY : DR. / MEDIWHEEL.

TEST NAME	RESULT	Unit	REF.RANGE
ESR	15 mm/hr		<20 mm/hr
CBC			
Total W.B.C. Count	8000 /cumm		4000-11,000 /cumm
R B C COUNT	4.2 Million/ CUmm		4 - 7 Million/ CUmm
Platelets count	1.74 Lakh/ cumm		1.5-5.0 Lakh/ cumm
Differential Count of W.B.C.			
Neutrophils	69 %		40-70%
Lymphocytes	27 %		25-40%
Eosinophils	03 %		01-05%
Mnonocytes	01 %		00-02%
Basophiles	00 %		00-0%
HAEMOGLOBIN	12.2 gm/dl (83.5 %)		14.6 gm/dl = 100%
PCV	39.0 %		35-47 %
MCV	84.5 fl		76-96 fl
MCH	29.0 pg		29-35 pg
MCHC	32.4 %		30-38 %



Dr. Ankur Kumar
 MBBS, MD
 Consultant Pathologist
 Reg. No. 39540
 Consultant Radiologist

ESTD BY:-

Dr. P. K. Tiwari
 MD, M Sc (Radio Imaging)
 Ph. D (Ab Nuclear Medicine)
 Consultant Inogonologist & Sonologist

Dr. S. Kumar
 MD (Pat)
 Consultant Pathologist

Dr. Abhishek Kumar
 MBBS, MD
 Consultant Neuropatho Physiologist

Dr. Anjali
 MBBS, MD
 Consultant(TMT, EEG Specialist)

Dr. Kumari Suman
 MBBS, DGO, MD
 Consultant (IVS & HSG Specialist)

PRINTING MISTAKE SHOULD BE REPORTED BACK IMMEDIATELY/ यहाँ जन्म से पहले भुग का सिग जींच नहीं होता है ।



A.L.C. Advance Imaging Diagnostics

ISO 9001:2015 Certified center

(A Unit of P.K.Arogyam Health & Wellness Center)

E-95, P.C. Colony, Near Sai Netryalaya Transformer, Kankarbagh, Patna - 20

alcdiagnostics@gmail.com

www.pkarogayamhealthcheckup.com

7050037694, 8271206196

OPINION MUST BE CORRELATES WITH CLINICALLY & OTHER INVESTIGATION FOR FINAL DIAGNOSIS. NOT FOR MEDICO LEGAL PURPOSE

PATIENT NAME : Mrs. SUDHA RANI PATIENT ID: 4076
COL DATE : 12/03/2022 REPORTING DATE: 12/03/2022 AGE SEX:- 53 YRS/F
REF.BY : DR. / MEDIWHEEL.

TEST NAME	RESULT	Unit	REF.RANGE
BLOOD GROUP	: 'A'		
Rh Typing	: POSITIVE		

Note: Do always cross – matching before blood transfusion



Dr. Ankur Kumar
MBBS, MD
Consultant Pathologist
Reg. No 39540

Consultant Radiologist

ESTD BY-

Dr. P. K. Tiwari
MD, M.Sc (Radio Imaging)
Ph.D (Ab Nuclear Medicine)
Consultant Imaginologist & Sonologist

Dr. S. Kumar
MD (Pat)
Consultant Pathologist

Dr. Abhishek Kumar
MBBS, MD
Consultant Neuropatho Physiologist

Dr. Anjali
MBBS, MD
Consultant (TMT, EEG Specialist)

Dr. Kumari Suman
MBBS, DGO, MD
Consultant (TVS & HSG Specialist)

PRINTING MISTAKE SHOULD BE REPORTED BACK IMMEDIATELY/ यहाँ जन्म से पहले भुण का लिग जाँच नहीं होता है ।



A.L.C. Advance Imaging Diagnostics

ISO 9001:2015 Certified center

(A Unit of P.K.Arogyam Health & Wellness Center)

E-95, P.C. Colony, Near Sai Netryalaya Transformer, Kankarbagh, Patna - 20

alcdiagnostics@gmail.com

www.pkarogyamhealthcheckup.com

7050037694, 8271206196

OPINION MUST BE CORRELATES WITH CLINICALLY & OTHER INVESTIGATION FOR FINAL DIAGNOSIS. NOT FOR MEDICO LEGAL PURPOSE

ECHOCARDIOGRAPHY & COLOR DOPPLER REPORT

Patient's Name : Mr.SUDHA KUMARI

Age/Sex : 53 Yrs /F

Ref. by : B O B

Date : 14-Mar-22

ECHOCARDIOGRAPHIC WINDOW: Fair

2D & M MODE ECHOCARDIOGRAPHY

Left ventricle

EDD:	43	mm (20 - 28 mm / m ²)	ESD:	30	mm(13 - 21 mm / m ²)
IVS :	9	mm (6 - 11 mm)	PW:	10	mm(6 - 11 mm)
Ejection fraction:	55% (61 ± 8%)		FS:	25	%(34 - 44 %)
IVS:	Intact		LV clot	Absent	

Left atrium/ Aorta 28/26 mm

Right ventricle Normal

Right atrium Normal

Pericardium Normal with no pericardial effusion

2D:

Normal LA/LV Size and normally contracting left ventricle. No RWMA, concentric LVH

Mitral valve

AML/ PML: Normal

Tricuspid valve Normal

Aortic valve Normal

Pulmonary valve Normal

Continuous & Pulse Wave Doppler study

Valve	Velocity (m/sec)			Gradient (mmHg)			Valve area (PHT Method)	Regurg.
	Peak	Mean	EDV	Peak	Mean	EDG		
Mitral	E=1.0 A=0.7			4.2	2.0			Nil
Tricuspid	E=0.7 A=0.5			2.2	0.2			Nil
Aortic	0.9			5.0	2.5			Nil
Pulmonary	3.4			3.5	1.7			Nil

ESTD BY:-

Dr. P. K. Tiwari
MD, M.Sc (Radio Imaging)
Ph.D (Air Nuclear Medicine)
Consultant Imaginologist & Sonologist

Dr. S. Kumar
MD (Pat)
Consultant Pathologist

Dr. Abhishek Kumar Anjali
MBBS, MD
Consultant Neurophysiology & EEG Specialist



Consultant Radiologist

Dr. Kumari Suman
MBBS, DGO, MD
Consultant (GYN & G-IMG Specialist)

PRINTING MISTAKE SHOULD BE REPORTED BACK IMMEDIATELY/ यहों जन्म से पहले भ्रूण का लिंग ज्ञान नहीं होता है ।

A.L.C. Advance Imaging Dignostics

ISO 9001:2015 Certified center

(A Unit of P.K.Arogyam Health & Wellness Center)

E-95, P.C. Colony, Near Sai Netryalaya Transformer, Kankarbagh, Patna - 20

alcdiagnostics@gmail.com

www.pkarogayamhealthcheckup.com

7050037694, 8271206196

OPINION MUST BE CORRELATES WITH CLINICALLY & OTHER INVESTIGATION FOR FINAL DIAGNOSIS. NOT FOR MEDICO LEGAL PURPOSE

Colour Flow Imaging

No TR, No MR/PR, No AR

No flow shunt

COMMENTS :

- ◆ Normal size all chamber
- ◆ Normal LV filling Pressure
- ◆ No RWMA
- ◆ Normal LV systolic function
- ◆ Grade I LV diastolic dysfunction.
- ◆ Global LVEF = 60%
- ◆ All cardiac valves are normal
- ◆ No PAH, Mild concentric LVH
- ◆ No MS / TS / AS / PS / PR
- ◆ No clot / vegetation / pericardial effusion.

IMPRESSION:

All chambers are normal

No RWMA, No PAH

Grade I LV diastolic dysfunction.

Normal LV systolic function, LVEF – 60%

Please correlate clinically

DR. SANDEEP KUMAR MBBS MD

DR. SANDEEP KUMAR
M.B.B.S., M.D. (Med.)
Reg. No. -BCMR33225

ESTD BY:-

Dr. P. K. Tiwari
MD, M.Sc (Radio Imaging)
Ph.D (All Nuclear Medicine)
Consultant Inagronologist & Seronologist

Dr. S. Kumar
MD (Pat)
Consultant Pathologist

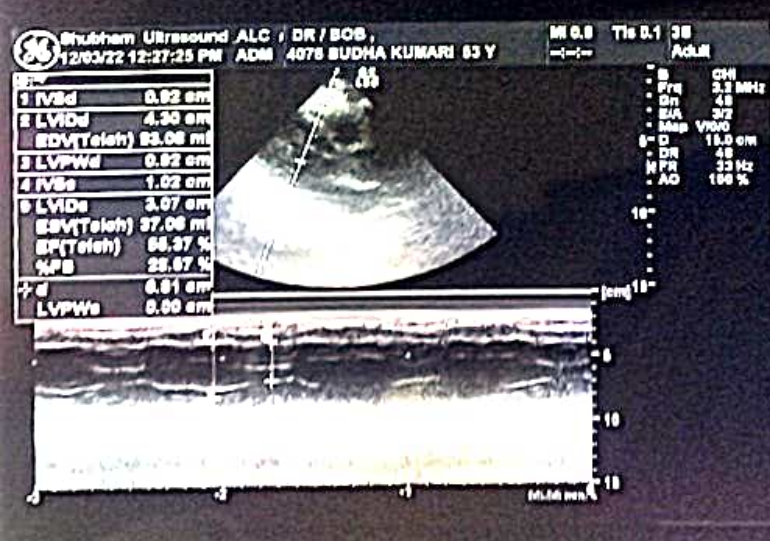
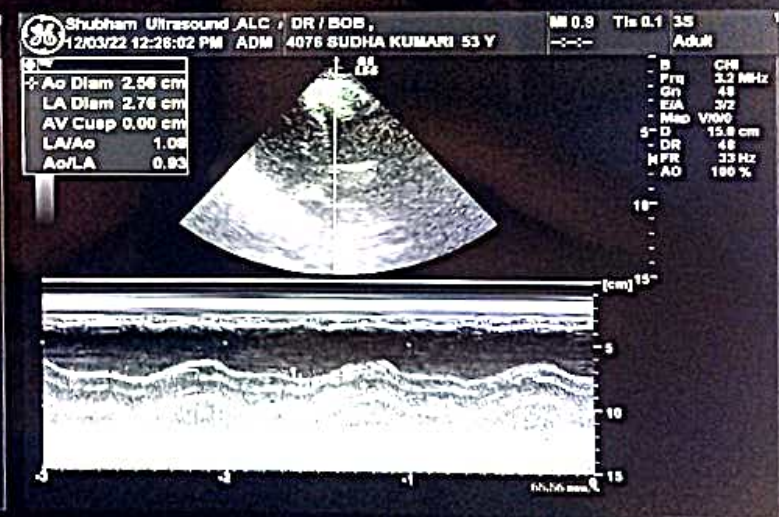
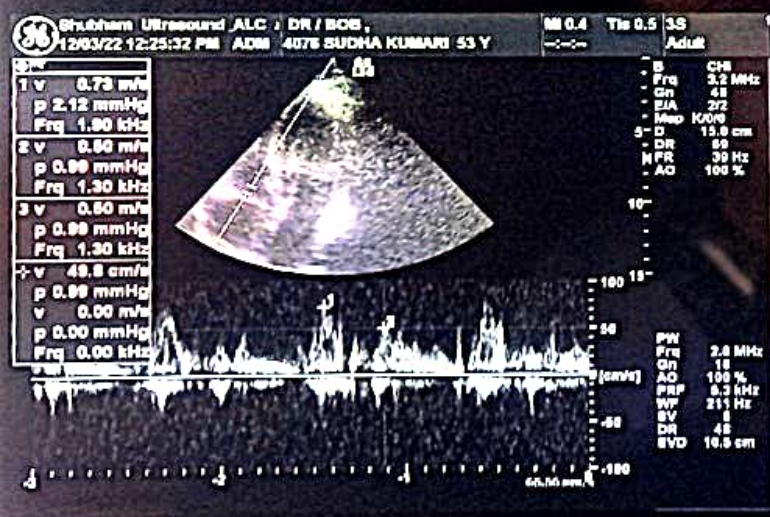
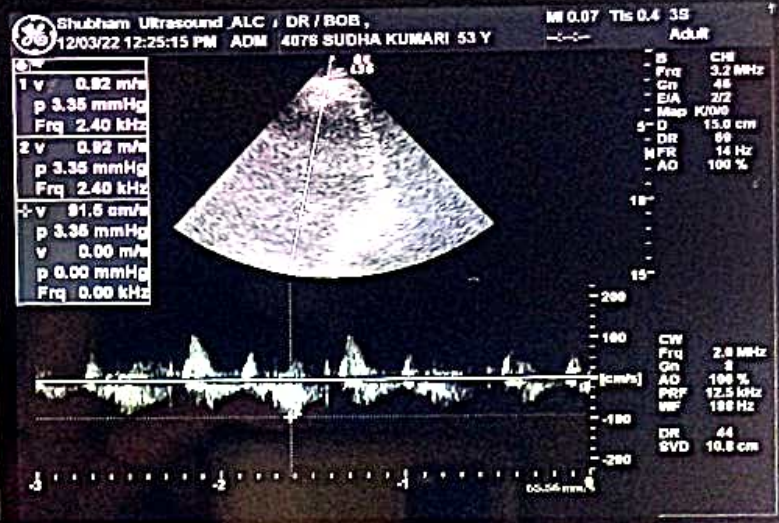
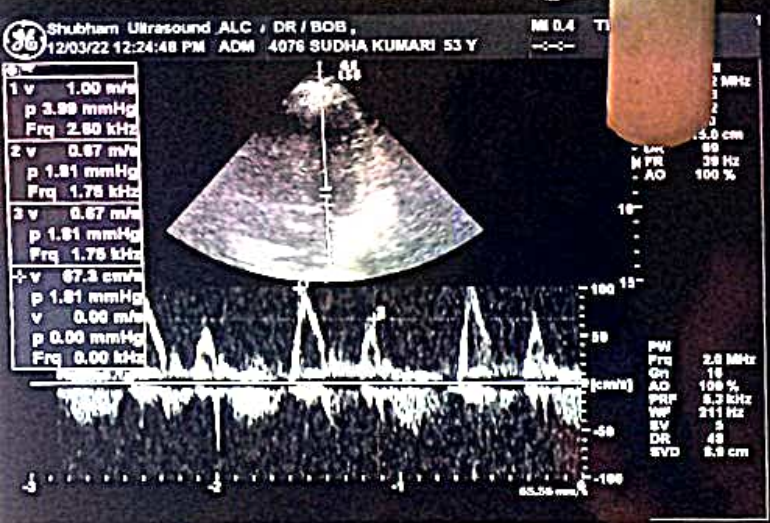
Dr. Abhishek Kumar
MBBS, MD
Consultant Neuropathio Physiologist

Dr. Anjali
MBBS, MD
Consultant (TMT, EEG Specialist)

Consultant Radiologist

Dr. Kumari Suman
MBBS, DGO, MD
Consultant (TNS & HSG Specialist)

PRINTING MISTAKE SHOULD BE REPORTED BACK IMMEDIATELY/यहाँ जन्म से पहले भुण का लिग जाँच नहीं होता है ।



Shubham Ultrasound ALC / DR / BOB,
12/03/22 12:22:50 PM ADM 4076 SUDHA KUMARI 53 Y

Parameter	Value	Unit	Ref
Height			
Weight			
BIA			
Page 1/2			
MI-Meas			
LAAo			
LAAe			
Ao Diam	2.56 cm	Avg	2.50
LA Diam	2.78 cm	Avg	2.70
LAAe	1.08		1.08
Ao/LA	0.93		0.93
Dimension			
IVSd	0.82 cm	Avg	0.80
LVIDd			
LVIDs	4.30 cm	Avg	4.30
EDV(Totah)	83.08 ml		83.08
LVPWd	0.82 cm	Avg	0.82
IVSs	1.02 cm	Avg	1.02
LVIDe			
LVIDe	3.07 cm	Avg	3.07
ESV(Totah)	37.08 ml		37.08



SUBHAM IMAGING & A.L.C. DIAGNOSTICS CENTRE

H.O. : Ajay Market, Bank of Baroda Building, East Ashok Nagar, Kankarbagh, Patna - 20

B.O. : Khanpura Road (Below Gyan Sharowar School), Paliganj, Patna.

e-mail : shubham.pat.usg@gmail.com # website : www.pkarogayamhealthcheckup.com

OPINION MUST BE CORRELATES WITH CLINICAL & OTHER INVESTIGATION FOR DIAGNOSIS NOT FOR MEDICO LEGAL PURPOSE

Pt. Name :- SUDHA KUMARI
Ref. By :- DR. B O B

Date:- 12-Mar-22
Age / Sex - 53 Yrs. F

REAL TIME U.S.G. OF WHOLE ABDOMEN Thanks for your kind referral

(Report.)

- LIVER :- Measures 11.79 cm. Normal in shape, size and echo texture. I.H.B.R. are not dilated. Hepatic veins are normal. No SOL seen.
- G.BL. :- Lumen is echo free. Wall thickness appears normal.
- C.B.D. :- Measures 3.3 mm in diameter with echo free lumen. No calculi or mass seen.
- P.V. :- Measures 7.2 mm in diameter. Appears normal. No thrombus seen.
- PANCREAS :- Normal in shape, size and echo texture. No calcification mass seen.
- SPLEEN :- Measures 11.21 cm. Normal in shape, size and echo texture. No SOL seen.
- KIDNEY :- Both kidney shows normal shape, size & echotexture. C.M.D.intact. P.C.S.is not dilated. No calculi, cyst or hydronephrosis seen on either side.
Right Kidney :- Measures 10.47 X 4.1 cm.
Left Kidney :- Measures 10.51 X 4.2 cm.
- URETER :- Not dilated. No apparent calculi seen.
- U.BLADDER:- Shows normal in outline with echo free lumen. No calculi or mass seen.
Pre void - 280 ml. Post void - is in significant
- UTERUS :- Is small Atrophic I in size, shape & in position measuring 6.90 X 3.50 cm. No focal mass lesion seen cervix appear normal.
- ADNEXA :- Both ovary not visualized
- P.O.D :- No collection seen in P.O.D.
- R.I.F. :- Son graphically no appendicular mass or collection seen.
- OTHERS :- No Ascites. no Lymph Adenopathy. No pleural effusion seen on either side.

IMPRESSION

➤ *Son graphically normal scan no detectable lesion seen*

Dr. A. K. Singh
MBBS, PGDMCH 22
Consultant Radiologist
Consultant Radiologist

ESTD BY:-

Dr. P. K. Tiwari
MD, M.Sc (Radio Imaging)
Ph.D (Art Nuclear Medicine)
Consultant Imagiologist & Sonologist

Dr. S. Kumar
MD. (Pat)
Consultant Pathologist

Dr. A. K. Singh
MBBS, PGDMCH
Consultant Radiologist & Sonologist

PRINTING MISTAKE SHOULD BE REPORTED BACK IMMEDIATELY/ यहाँ जन्म से पहले भुण का लिंग जाँच नहीं होता है ।



SUBHAM IMAGING & A.L.C. DIAGNOSTICS CENTRE

H.O. : Ajay Market, Bank of Baroda Building, East Ashok Nagar, Kankarbagh, Patna - 20

B.O. : Khanpura Road (Below Gyan Sharowar School), Paliganj, Patna.

e-mail : shubham.pat.usg@gmail.com # website : www.pkarogayamhealthcheckup.com

OPINION MUST BE CORRELATES WITH CLINICAL & OTHER INVESTIGATION FOR DIAGNOSIS NOT FOR MEDICO LEGAL PURPOSE

Pt. Name :- SUDHA RANI
Ref. By :- DR. B O B

Date:- 14-Mar-22
Age / Sex - 53 Yrs. F.

Thanks for your kind referral

X-RAYCHEST (P.A.VIEW)

The lungs on the either side show equal translucency.

The peripheral pulmonary vasculature is normal.

No focal lung lesion is seen.

The pleural spaces are normal.

Both hila are normal in size, have equal density and bear normal relationship.

The heart and trachea are central in position and no mediastinal abnormality is visible.

The cardiac size is normal.

The domes of the diaphragms are normal in position, and show smooth outline.

IMPRESSION

- NO EVIDENCE OF PULMONARY OR CARDIAC PATHOLOGY IS NOTED.



Dr. A. K. Singh
MBBS, PGDMCH
Consultant Radiologist

Consultant Radiologist

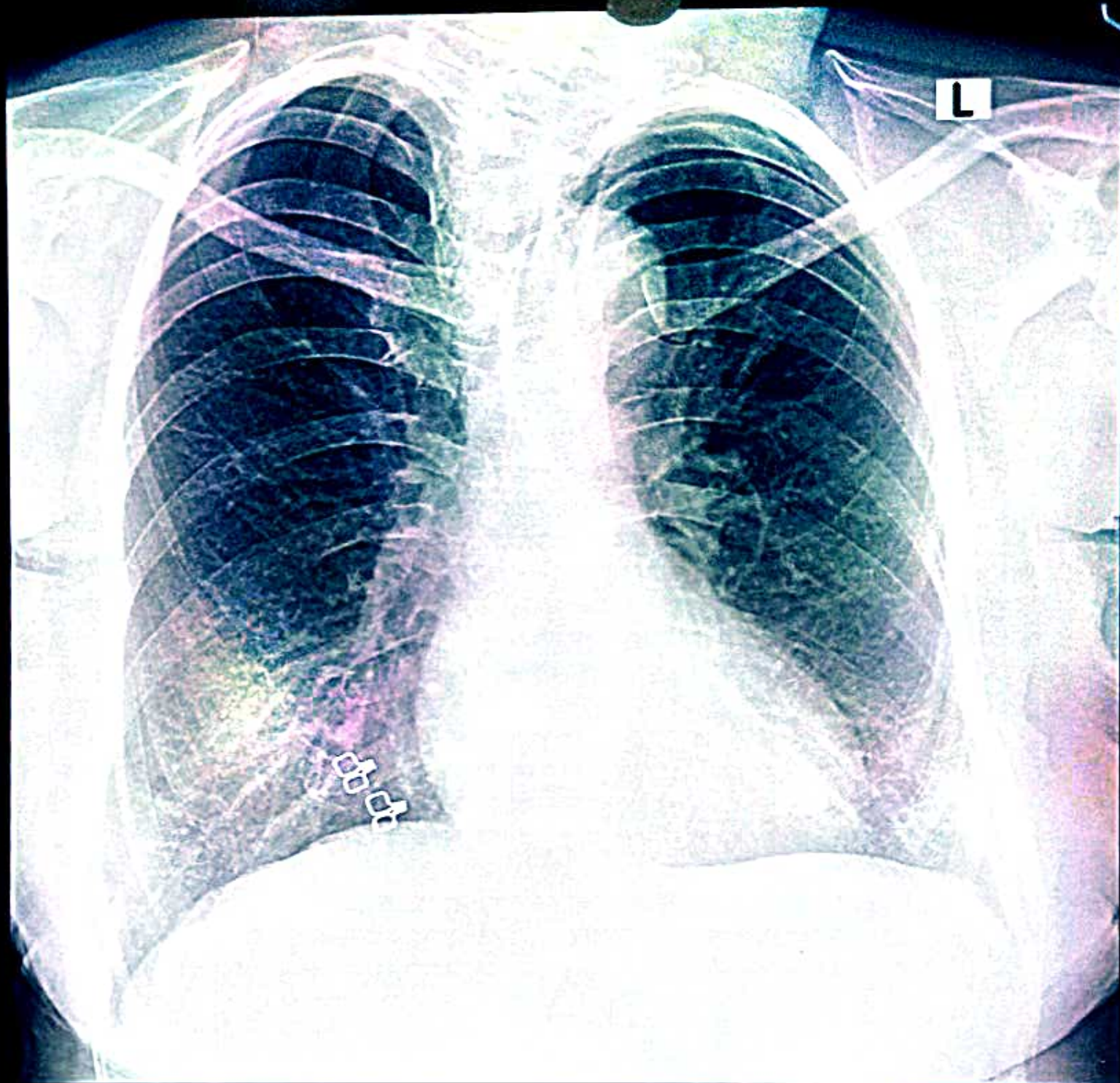
ESTD BY:-

Dr. P. K. Tiwari
MD, M.Sc (Radio Imaging)
Ph.D (AI Nuclear Medicine)
Consultant Imaginationologist & Sonologist

Dr. S. Kumar
MD. (Pat)
Consultant Pathologist

Dr. A. K. Singh
MBBS, PGDMCH
Consultant Radiologist & Sonologist

PRINTING MISTAKE SHOULD BE REPORTED BACK IMMEDIATELY/ यहाँ जन्म से पहले भुण का लिंग जाँच नहीं होता है ।



SUDHA RANI AGE 53 YEARS 4076 BY DR. BOB CHEST,FRN P->A 3/12/2022
A.L.C. Advance Imaging Diagnostics Centre PATNA - 20

TD 4070 CASE 1
AGE 53Y OM 08D
158Cms 64kg

SUDHA RANI
FEMALE

12/03/2022 12 19 49
ALC ADVANCE IMAGING DIAGNOSTICS
E95 PC COLONY KANKARBAGH PATNA

RHR 70 bpm SINUS RHYTHM
R-R 851 ms
P-R 148 ms
QRS 86 ms
QT 390 ms
QTc 409 ms

PRAXIS
P 71°
QRS 71°
T 47°
NORMAL ECG

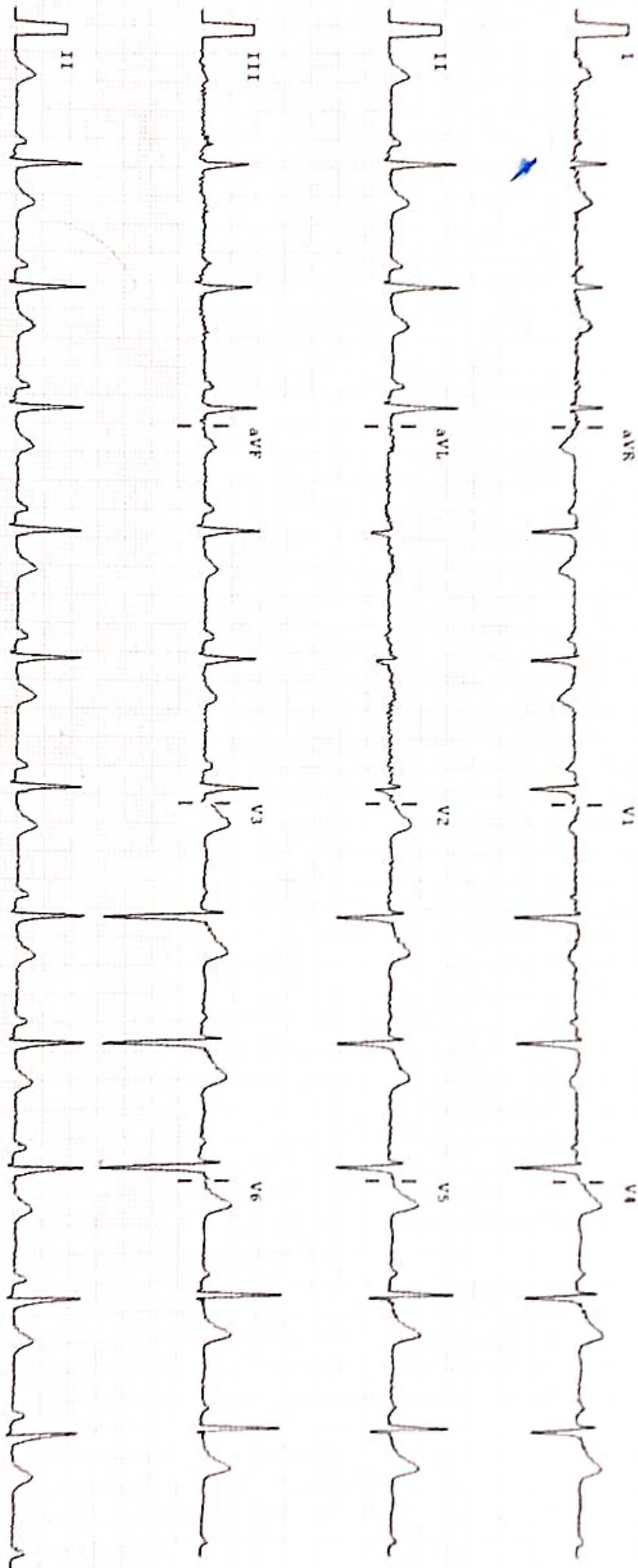
12 SL. REPORT FORMAT J44.1L.SQ

REF: DR. HCH

Dr. Dr. ABHISHEK KUMAR MBBS, MD



Dr. Abhishek Kumar
MBBS, MD



25mm/sec 10mm/mV Notch: ON BLC:ON 0.05-35Hz

ALLENGERS PISCES 10121VER.--- 1.80

CLINICALLY CORRELATE THE FINDINGS.

GP2