

OP CASE SUMMARY
DOCTOR PRESCRIPTION

farheen
28/f

10/12/2022

No Ocular complaint
stain in eyes

OLG

V 6/9 (V-a)
A 6/6P

(A) C - 0.5 1 - 0.5 at 90° 6/6
- 0.25 1 - 0.25 D at 140°

A/s conjugate eye BE

Ms OK OD

Acular ds roof
o o o x 15 days



Dr. Kenika Sharma
DOMS, (Ophthalmology)
Reg.No: CGMC-2434/2003
NHMMI Raipur (C.G.)

CONSULTATION SUMMARY

Patient MRN : 17540000317609
Patient Name : Farheen Kazi
Gender/Age/Dob : Female , 28 Years , 08/02/94
Patient Phone No : 7415448496
Patient Address : 365/2K Nrea of glorious school
borliya road krishna nagar,
Raipur, Chhattisgarh, India

Consultation Date: 13/12/2022 04:21 PM
Consultant : Dr. Mukesh Kumar Sharma
(GENERAL MEDICINE)
Consultation Type : OP , FOLLOW UP



CHIEF COMPLAINTS & HISTORY OF PRESENT ILLNESS

- CAME FOR HEALTH CHECK UP :
- NO COMPLAIN :
- NO H/O CO-MORBIDITIES :

VITALS

Blood Pressure: 110/70 mmHg Heart Rate: 88 /bpm

NOTES

- LIFE STYLE MODIFICATIONS AS ADVISED
LOW SALT DIET, AVOID SPICY N JUNK FOODS
REGULAR EXERCISE

CONSULTANT DETAILS



Dr. Mukesh Kumar Sharma , CONSULTANT , GENERAL MEDICINE
Registration No : 5549/2014

Printed By: Dr. Mukesh Kumar Sharma | Printed On: 13.12.2022 16:52

CONSULTATION SUMMARY

Patient MRN : 17540000317609
Patient Name : Farheen Kazi
Gender/Age/Dob : Female , 28 Years , 08/02/94
Patient Phone No : 7415448496
Patient Address : 365/2K Nrea of glorious school
boriya road krishna nagar,
Raipur, Chhattisgarh, India

Consultation Date: 10/12/2022 10:52 AM
Consultant : Dr. Manisha Sharma
(OBSTETRICS & GYNAECOLOGY)
Consultation Type : OP , NEW VISIT



CHIEF COMPLAINTS & HISTORY OF PRESENT ILLNESS

- p212 prv 2 lscs lcb 2.5.22 : in lactoal amenorrea

INVESTIGATION ORDER

PAP SMEAR - SMVDNSH

MEDICATION ORDER

DRUG NAME

- CLINDAMYCIN+CLOTRIMAZOLE+TINIDAZOLE-
SUPPOSITORY-100MG+100MG+100MG-
CLINGEN FORTE (3/42)
- THERAPY LIQUID SOAP-SOLUTION-100ML-
INTIWASH

(3) CCM-100.0 x (3) mlt.

PATIENT INSTRUCTION

Once Daily (0 - 0 - 0 - 1) Vaginal At Bed Time For 7
Days For vaginal insertion only , Qty: 1 , Start Date:
Dec 10, 2022 , End Date: Dec 16, 2022

, Qty: 1 , Start Date: Dec 10, 2022

CONSULTANT DETAILS



Dr. Manisha Sharma , VISITING CONSULTANT , OBSTETRICS & GYNAECOLOGY

ms
MANISHA SHARMA
D.G.O.D.N.B
(15/2010
(18/12/2022)

One free consultation with the same doctor within next 6 days.

Printed By: Dr. Manisha Sharma | Printed On: 10.12.2022 11:29

DEPARTMENT OF LABORATORY MEDICINE Unit of Narayana Health

MRN : 17540000317609 Department : OBSTETRICS & GYNAECOLOGY
 Name : Farheen Kazi Specimen : WHOLE BLOOD
 Age / Sex : 28 Year(s) / Female Visit Type : OP
 Sample No : 22212100124 Collected On : 10/12/2022 10:05 AM
 Consulting DR : Dr. Manisha Sharma Referred DR : Dr. Manisha Sharma
 Patient Address : 365/2K Nrea of glorious school boriya road Received On : 10/12/2022 10:30 AM
 krishna nagar Raipur null Chhattisgarh,India Reported On : 10/12/2022 11:31 AM
 Report Type : Final

HAEMATOLOGY LAB

Test	Result	Unit	Biological Reference Interval
EHP MEDIWHEEL FULL BODY HEALTH CHECK PACKAGE FEMALE BELOW 40 YRS			
ERYTHROCYTE SEDIMENTATION RATE (ESR)	15.00	mm/hr	0-19

Galipulawia



Dr. SMRITI RATHOREMBBS MD
PATHOLOGY



NHMMI Narayana Superspeciality Hospital

(A unit of Narayana Hrudayalaya Limited) CIN: L051106A2000PLC027497

Registered Office: 25B/A, Bommasandra Industrial Area, Anekal, Bangalore 560099

Hospital Address: New Dhamtari Road, Lalpur, Raipur 492001

Tel +91 771 4210901 / 902 | Fax +91 771 408 1106 | Email: info.rpr@narayanahealth.org | www.narayanahealth.org

Appointments

1800-309-0309

Emergencies

8821-818181

DEPARTMENT OF LABORATORY MEDICINE Unit of Narayana Health

MRN : 17540000317609	Department : OBSTETRICS & GYNAECOLOGY
Name : Farheen Kazi	Specimen : SERUM
Age / Sex : 28 Year(s) / Female	Visit Type : OP
Sample No : 1R2212100232	Collected On : 10/12/2022 10:05 AM
Consulting DR : Dr. Manisha Sharma	Referred DR : Dr. Manisha Sharma
Patient Address : 365/2K Nrea of glorious school boriya road krishna nagar Raipur null Chhattisgarh,India	Received On : 10/12/2022 10:30 AM
	Reported On : 10/12/2022 12:21 PM
	Report Type : Final

BIOCHEMISTRY

Test	Result	Unit	Biological Reference Interval
FASTING BLOOD SUGAR (FBS)	85.00	mg/dl	70-99
LIPID PROFILE (CHOL,TRIG,HDL,LDL,VLDL)			
CHOLESTEROL TOTAL	249.00 H		50-200
TRIGLYCERIDES	92.00	mg/dl	0-150
RENAL PACKAGE - 2 (RFT FASTING)			
SERUM CREATININE			
SERUM CREATININE	0.6	mg/dl	0.6-1.2
eGFR	116.05	mL/min/1.73m2	
BLOOD UREA NITROGEN (BUN)	10.00	mg/dl	7-20
HDL CHOLESTROL (HDLC)	90.00 H	mg/dl	35-70
LDL CHOLESTEROL	140.00 H	mg/dl	0-100
SODIUM, SERUM	142.00	mmol/L	135-150
POTASSIUM, SERUM	4.50	mmol/L	3.5-5
VLDL CHOLESTEROL	18.40	mg/dl	0-40
CHOLESTEROL /HDL RATIO	2.77		0-5
CHLORIDE	100.00	mmol/L	95-106
CALCIUM	9.90	mg/dl	8.5-10.1
MAGNESIUM	1.70 L	mg/dL	1.8-2.4



 Dr. SMRITI RATHORE MBBS MD
 PATHOLOGY

Appointments

1800-309-0309

Emergencies

8821-818181
NHMMI Narayana Superspeciality Hospital
(A unit of Narayana Hrudayalaya Limited) CIN: L85110KA2000PLC027497

Registered Office: 258/A, Bommasandra Industrial Area, Anekal Taluk, Bangalore 560099

Hospital Address: New Dhantari Road, Lalpur, Raipur 492001

 Tel +91 771 4210901 / 902 | Fax +91 771 408 1106 | Email: info.rpr@narayanahealth.org | www.narayanahealth.org


DEPARTMENT OF LABORATORY MEDICINE Unit of Narayana Health

MRN	: 17540000317609	Department	: OBSTETRICS & GYNAECOLOGY
Name	: Farheen Kazi	Specimen	: SERUM
Age / Sex	: 28 Year(s) / Female	Visit Type	: OP
Sample No	: 1R2212100230	Collected On	: 10/12/2022 10:05 AM
Consulting DR	: Dr. Manisha Sharma	Referred DR	: Dr. Manisha Sharma
Patient Address	: 365/2K Nrea of glorious school boriya road krishna nagar Raipur null Chhattisgarh,India	Received On	: 10/12/2022 10:30 AM
		Reported On	: 10/12/2022 12:21 PM
		Report Type	: Final

BIOCHEMISTRY

Test	Result	Unit	Biological Reference Interval
URIC ACID	3.70	mg/dl	2.6-6
PHOSPHORUS	4.60	mg/dl	2.6-4.7



DR. SMRITI RATHORE MBBS MD
PATHOLOGY

Appointments

1800-309-0309



Emergencies

8821-818181

DEPARTMENT OF LABORATORY MEDICINE Unit of Narayana Health

MRN : 17540000317609
Name : Farheen Kazi
Age / Sex : 28 Year(s) / Female
Sample No : 22212100125
Consulting DR : Dr. Manisha Sharma
Patient Address : 365/2K Nrea of glorious school boriya road
 krishna nagar Raipur null Chhattisgarh,India

Department : OBSTETRICS & GYNAECOLOGY
Specimen : WHOLE BLOOD
Visit Type : OP
Collected On : 10/12/2022 10:05 AM
Referred DR : Dr. Manisha Sharma
Received On : 10/12/2022 10:30 AM
Reported On : 10/12/2022 12:05 PM
Report Type : Final

Test	Result	Unit	Biological Reference Interval
COMPLETE BLOOD COUNT (CBC)			
HAEMOGLOBIN (HB%)	12.70 L	g/dl	13-18
RED BLOOD CELL COUNT	5.04	Million/ul	3.8-5.8
PCV (PACKED CELL VOLUME) / HEMATOCRIT	38.3	%	36-46
MCV (MEAN CORPUSCULAR VOLUME)	75.9 L	fl	76-96
MCH (MEAN CORPUSCULAR HAEMOGLOBIN)	25.20 L	pg	27-32
MCHC (MEAN CORPUSCULAR HAEMOGLOBIN CONCENTRATION)	33.20	%	30-35
RED CELL DISTRIBUTION WIDTH (RDW)	13.80	%	11.6-14.0
PLATELET COUNT	210.00	Thous/ μ l	150-400
TOTAL LEUKOCYTE COUNT (TLC)	4.8	Thousand/cu.mm	4.0-10.0
DIFFERENTIAL COUNT (DC)			
Neutrophils	60	%	40-75
Lymphocytes	34	%	20-45
Monocytes	04	%	2-10
Eosinophils	02	%	1-6
Basophils	00	%	0-1
NRBC	0.0		


Dr. SMRITI RATHORE MBBS MD
 PATHOLOGY

Appointments

1800-309-0309

Emergencies

8821-818181
NH MMI Narayana Superspeciality Hospital

(A Unit of Narayana Hrudayalaya Limited) CIN: LB5110RA2000PLC027497

Registered Office: 258/A, Bommasandra Industrial Area, Anekal Taluk, Bangalore 560099

Hospital Address: New Dhantari Road, Lalpur, Raipur 492001

Tel +91 771 4210901 / 902 | Fax +91 771 408 1106 | Email: info.rpr@narayanahealth.org | www.narayanahealth.org

DEPARTMENT OF LABORATORY MEDICINE Unit of Narayana Health

MRN : 17540000317609	Department : OBSTETRICS & GYNAECOLOGY
Name : Farheen Kazi	Specimen : blood
Age / Sex : 28 Year(s) / Female	Visit Type : OP
Sample No : 1R2212100231	Collected On : 10/12/2022 10:05 AM
Consulting DR : Dr. Manisha Sharma	Referred DR : Dr. Manisha Sharma
Patient Address : 365/2K Nrea of glorious school boriya road krishna nagar Raipur null Chhattisgarh,India	Received On : 10/12/2022 10:30 AM
	Reported On : 10/12/2022 12:20 PM
	Report Type : Final

Test	Result	Unit	Biological Reference Interval
LIVER FUNCTION TEST(LFT)			
BILIRUBIN TOTAL	0.50	mg/dl	0-1.3
BILIRUBIN DIRECT	0.20	mg/dl	0-0.3
TOTAL PROTEIN	7.90	gm/dL	6.4-8.2
BILIRUBIN INDIRECT	0.30		
SERUM ALBUMIN	4.50	gm/dL	3.4-5
SERUM GLOBULIN	3.40		
ALBUMIN TO GLOBULIN (A/G)RATIO	1.32		1-2.1
SGOT (AST)	25.00	IU/L	15-37
SGPT (ALT)	24.00 L	IU/L	30-65
ALKALINE PHOSPHATASE (ALP)	93.00	IU/L	50-136
GAMMA GLUTAMYL TRANSFERASE (GGT)	13	U/L	5-85



NH MMI Narayana Superspeciality Hospital

(A unit of Narayana Hrudayalaya Limited) CIN: L85110KA2003PLC027497

Registered Office: 258/A, Bommasandra Industrial Area, Anekal Taluk, Bangalore 560099

Hospital Address: New Dhamtari Road, Laipur, Raipur 492001

Tel +91 771 4210901 / 902 | Fax +91 771 408 1106 | Email: info.rpr@narayanahealth.org | www.narayanahealth.org

Dr. SMRITI BATHORE MD Appointments
PATHOLOGY



1800-309-0309

Emergencies

8821-818181

DEPARTMENT OF LABORATORY MEDICINE Unit of Narayana Health

MRN : 17540000317609 Department : OBSTETRICS & GYNAECOLOGY
 Name : Farheen Kazi Specimen : SERUM
 Age / Sex : 28 Year(s) / Female Visit Type : OP
 Sample No : 1R2212100232 Collected On : 10/12/2022 10:05 AM
 Consulting DR : Dr. Manisha Sharma Referred DR : Dr. Manisha Sharma
 Patient Address : 365/2K Nrea of glorious school boriya road Received On : 10/12/2022 10:30 AM
 krishna nagar Raipur null Chhattisgarh,India Reported On : 10/12/2022 01:07 PM
 Report Type : Final

Test	Result	Unit	Biological Reference Interval
THYROID PROFILE (T3, T4, TSH)			
TRI IODO THYRONINE (T3)	1.13	ng/dL	0.6-1.81
THYROXINE (T4)	7.95	ug/dl	3.2-12.6
TSH (THYROID STIMULATING HORMONE)	2.07	mIU/mL	0.35-5.50



NH MMI Narayana Superspeciality Hospital

(A Unit of Narayana Hrudayalaya Limited) CIN: L85110KA2000PLC027497

Registered Office: 258/A, Bommasandra Industrial Area, Anekal Taluk, Bangalore 560099

Hospital Address: New Dhamtari Road, Lalpur, Raipur 492001

Tel +91 771 4210901 / 902 | Fax +91 771 408 1106 | Email: info.rpr@narayanahealth.org | www.narayanahealth.org

Dr. SMRITI RATHOREMBBS MD
PATHOLOGY

Appointments

1800-309-0309

Emergencies

8821-818181

DEPARTMENT OF LABORATORY MEDICINE Unit of Narayana Health

MRN : 17540000317609	Department : OBSTETRICS & GYNAECOLOGY
Name : Farheen Kazi	Specimen : WHOLE BLOOD
Age / Sex : 28 Year(s) / Female	Visit Type : OP
Sample No : 1R2212100233	Collected On : 10/12/2022 10:05 AM
Consulting DR : Dr. Manisha Sharma	Referred DR : Dr. Manisha Sharma
Patient Address : 365/2K Nrea of glorious school boriya road krishna nagar Raipur null Chhattisgarh,India	Received On : 10/12/2022 10:30 AM
	Reported On : 10/12/2022 01:08 PM
	Report Type : Final

Test	Result	Unit	Biological Reference Interval
HBA1c			
HBA1c	5.3	%tage	

Reference Group HBA1c in %

Non diabetic Adult (18 years or more) < 5.7

At risk (Prediabetes) 5.7 - 6.4

Diagnosing Diabetes >= 6.5

Estimated Average Glucose	105.41	mg/dL	
---------------------------	--------	-------	--

Note:
Abnormal results are highlighted.
Results relate to the sample only.
Kindly correlate clinically.



NH MMI Narayana Superspeciality Hospital

(A unit of Narayana Hrudayodaya Limited) CIN: L85110KA2000PLC027407

Registered Office: 258/A, Bommasandra Industrial Area, Anekal Taluk, Bangalore-560099

Hospital Address: New Dhamtari Road, Lalpur, Raipur 492001

Tel +91 771 4210901 / 902 | Fax +91 771 408 1106 | Email: info.rpr@narayanahealth.org | www.narayanahealth.org

Dr. SMRITI RATHORE MBBS MD
PATHOLOGY

Appointments

1800-309-0309

Emergencies

8821-818181

DEPARTMENT OF PATHOLOGY LAB

MRN : 17540000317609
 Name : Farheen Kazi
 Age / Sex : 28 Year(s) / Female
 Sample No : 0,1R2212100229,1R2212100230,1R2212100231,1R2212100232,1R2212100233,22212100124,22212100125,7R2212100057,7R2212100058,92212100003
 Consulting DR : Dr. Manisha Sharma
 Patient Address : 365/2K Nrea of glorious school boriya road krishna nagar Raipur null Chhattisgarh,India

Department : OBSTETRICS & GYNAECOLOGY
 Specimen : blood,PLASMA,SERUM,Stool,SWA B,URINE,WHOLE BLOOD
 Visit Type : OP
 Collected On : 10/12/2022 10:05 AM
 Referred DR : Dr. Manisha Sharma
 Received On : 10/12/2022 10:30 AM
 Reported On : 12/12/2022 10:05 AM
 Report Type : Final

HISTOPATHOLOGY

EHP MEDIWHEEL FULL BODY HEALTH CHECK PACKAGE FEMALE BELOW 40 YRS

PAP SMEAR

GENERAL CATEGORIZATION	Smear show superficial and intermediate squamous epithelial cells in background of inflammatory cells
MATERIAL RECEIVED	Received one unstained smear.
SPECIMEN TYPE	Pap Smear.
IMPRESSION	Inflammatory Smear Correlate clinically.
Lab No	2022/C/896

-- End of Report --

Result Entered by



Dr. SMRITI RATHORE MBBS MD
PATHOLOGY

NH MMI Narayana Superspeciality Hospital

(A Unit of Narayana Hrudayalaya Limited), CIN: L85110KA2000PLC027497

Registered Office: 258/A, Bommasandra Industrial Area, Anekal Taluk, Bangalore 560099

Hospital Address: New Dhamtari Road, Lalpur, Raipur 492001

Tel +91 771 4210901 / 902 | Fax +91 771 408 1106 | Email: info.rpr@narayanahealth.org | www.narayanahealth.org



Appointments

1800-309-0309

Emergencies

8821-818181

ECHOCARDIOGRAPHY REPORT

Patient ID : 17540000317609 Report Date : 10/12/2022
Patient Name: : Mrs. Farheen Kazi
Age / Gender : 28Years/ Female

MEASUREMENT

AO : 28 (20 - 35)mm LVID(d) : 47 (36 - 52)mm IVS: 09 (06 -11)mm
LA : 31 (19 - 40)mm LVID s : 28 (23 - 39)mm PW: 09 (06 - 11)mm
EF : 60%

VALVES

Mitral Valve : Normal
Aortic valve : Normal
Tricuspid Valve : Normal
Pulmonary Valve : Normal

CHAMBERS

Left Atrium : Normal
Right Atrium : Normal
Left Ventricle : Normal
Right Ventricle : Normal

SEPTAE

IVS : Intact
IAS : Intact

GREAT ARTERIES

Aorta : Normal
Pulmonary Artery : Normal



Patient ID : 17540000317609 Report Date : 10/12/2022
Patient Name: : Mrs. Farheen Kazi
Age / Gender : 28Years/ Female

WALL MOTION ABNORMALITIES

No RWMA at rest

FINAL DIAGNOSIS

No RWMA at rest
Normal LV systolic function, LVEF-60%.
Normal cardiac chambers dimension
IVC normal & collapsing >50% with respiratory variation.
No I/C clot, vegetation or pericardial effusion

S. Gouniyal

Dr. S.Gouniyal
MD, DM
Senior Interventional Cardiologist



DR. PRASHANT MADHARIA
MD, PGDCC
Consultant Non-Invasive Cardiology

Dr. JINESH JAIN
MD, DM
Consultant, interventional Cardiology

ECHOCARDIOGRAPHY REPORT

Patient ID	: 17540000317609	Report Date	: 10/12/2022
Patient Name:	: Mrs. Farheen Kazi		
Age / Gender	: 28Years/ Female		

MEASUREMENT

AO : 28 (20 - 35)mm **LVID(d)** : 47 (36 - 52)mm **IVS**: 09 (06 -11)mm
LA : 31 (19 - 40)mm **LVID s** : 28 (23 - 39)mm **PW**: 09 (06 - 11)mm
EF : 60%

VALVES

Mitral Valve : Normal
Aortic valve : Normal
Tricuspid Valve : Normal
Pulmonary Valve : Normal

CHAMBERS

Left Atrium : Normal
Right Atrium : Normal
Left Ventricle : Normal
Right Ventricle : Normal

SEPTAE

IVS : Intact
IAS : Intact

GREAT ARTERIES

Aorta : Normal
Pulmonary Artery : Normal



NH MMI Narayana Superspeciality Hospital

(A unit of Narayana Hrudyalaya Limited) CIN: L85110KA2000PLC027497

Registered Office: 258/A, Bommasandra Industrial Area, Anekal Taluk, Bangalore 560099

Hospital Address: New Dhamtari Road, Lalpur, Raipur 492001

Tel +91 771 4210901 / 902 | Fax +91 771 408 1106 | Email: info.rpr@narayanahealth.org | www.narayanahealth.org



Appointments

1800-309-0309

Emergencies

8821-818181

Patient ID : 17540000317609	Report Date : 10/12/2022
Patient Name : Mrs. Farheen Kazi	
Age / Gender : 28Years/ Female	

WALL MOTION ABNORMALITIES

No RWMA at rest

FINAL DIAGNOSIS

No RWMA at rest
Normal LV systolic function. LVEF-60%.
Normal cardiac chambers dimension
IVC normal & collapsing >50% with respiratory variation.
No I/C clot, vegetation or pericardial effusion



Dr. S.Gouniyal
MD, DM
Senior Interventional Cardiologist



DR. PRASHANT MADHARIA
MD, PGDCC
Consultant Non- Invasive Cardiology

Dr. JINESH JAIN
MD, DM
Consultant, interventional Cardiology

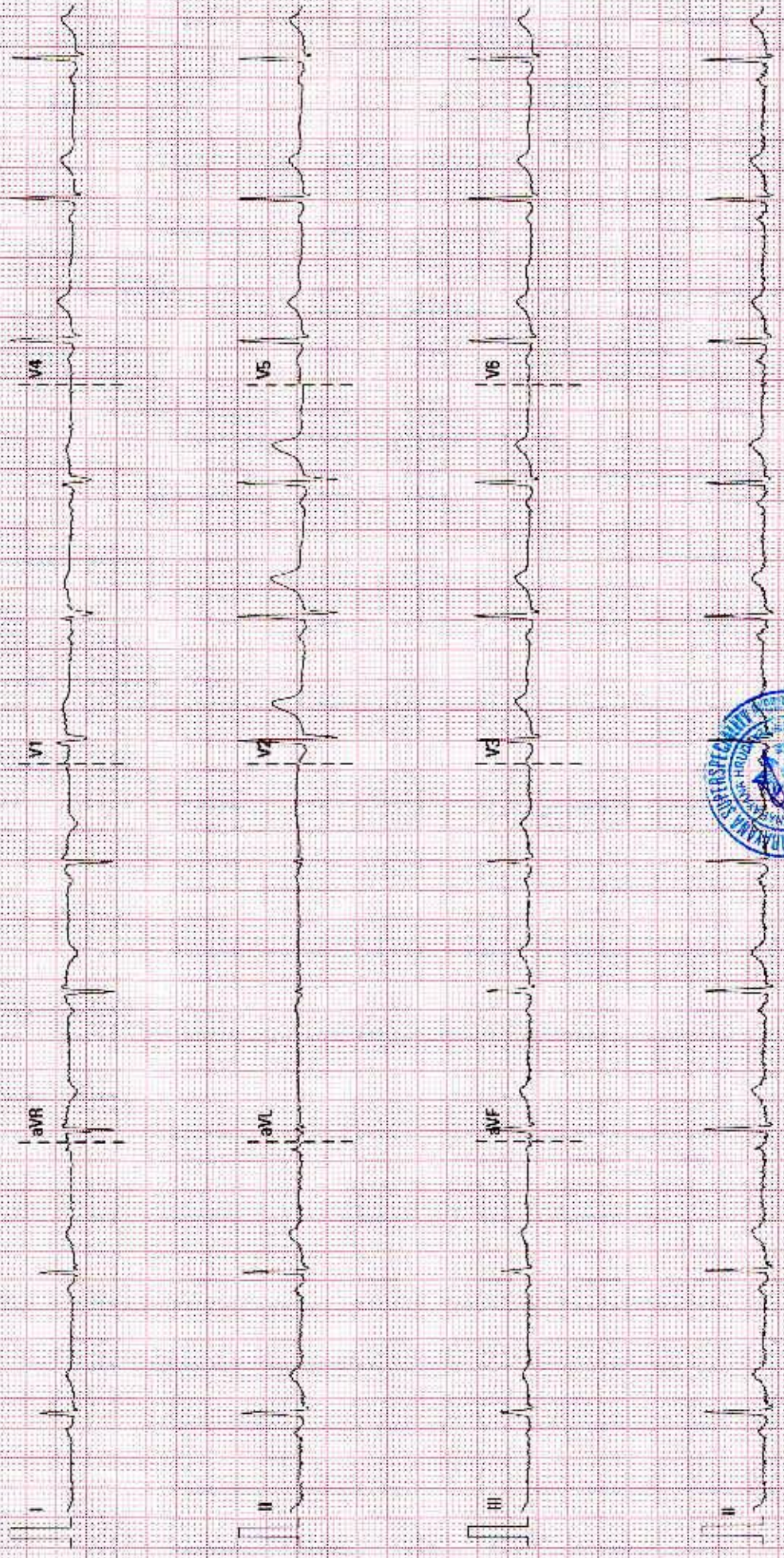
2022-12-10 13:15:27

ID: 317605
Name: FARHEEN KAZI
Age: 28 Years
Gender: Female

Vent. Rate 67 bpm
PR Interval 140 ms
QRS Duration 76 ms
QT/QTc Interval 374/386 ms
P/QRS/T Axes 34/61/56 deg
QTc-Hodges

Sinus rhythm
Normal ECG
Unconfirmed Diagnosis

"Please Xerox This Copy"



Patient Name	Farheen Kazi	Requested By	DR.M.SHARMA
MRN	17540000317609	Procedure Date Time	2022-12-10 13:57:05
Age/Sex	28Y 10M/Female	Hospital	NH-RAIPUR

CHEST RADIOGRAPH (PA VIEW)

CLINICAL DETAILS:For health checkup.

FINDINGS:

- The lung fields and bronchovascular markings appear normal.
- The cardiac size is within normal limits.
- Mediastinum and great vessels are within normal limits.
- Trachea is normal and is central. The hilar shadows are unremarkable.
- The costo-phrenic angles are clear. No evidence of pleural effusion or pneumothorax.
- The visualized bones and soft tissue structures appear normal.
- Both the diaphragmatic domes appear normal.

IMPRESSION:

- **Normal chest radiograph.**



DR VIJENDRA RUPRELA
MBBS, DMRD, DNB, MNAMS
CONSULTANT RADIOLOGIST

* **This is a digitally signed valid document.** Reported Date/Time: 2022-12-10 20:35:57

NAME: MS. FARHEEN KAZI

REF. BY: DR. MANISHA SHARMA

DATE: 10.12.2022

SONOGRAPHY OF ABDOMEN AND PELVIS

The Real time, B mode, gray scale sonography was performed.

LIVER : The liver is normal in size 14.9cm & reveals normal echotexture with smooth outlines.

PORTAL VEIN : The portal vein is normal in calibre.

GALL BLADDER : The gall bladder is partially distended.

Visualized proximal CBD is normal in calibre.

SPLEEN : The spleen is normal in size 8cm. No evidence of focal lesion is noted.

PANCREAS : The visualized pancreas is normal in size, shape, contours and echotexture.

B/L KIDNEYS :

The right kidney measures - 9.6 x 4.3cm and left kidney measures - 10.2 x 4.8cm in size. Both kidneys reveal normal cortical echotexture and have smooth margins. Cortico-medullary differentiation is maintained. No calculus or hydronephrosis is seen.

URINARY BLADDER : The urinary bladder is well distended.

UTERUS: The uterus is anteverted and normal in size 7.6 x 3.9 x 3.6cm. The endometrial thickness is 4mm.

Both ovaries are normal in size and echotexture. No adnexal mass is seen.

Right ovary measures : 2.5 x 1.9cm. Left ovary measures: 2.5 x 1.2cm.

No free fluid is seen in the peritoneal cavity.

Excessive intrabowel gases are noted.

IMPRESSION :

- **THE SONOGRAPHY OF THE ABDOMEN AND PELVIS IS WITHIN NORMAL LIMITS.**

ADVISED: Clinical correlation & appropriate further evaluation.



DR. RANJANA KEDIA
MBBS, CBET
CONSULTANT SONOLOGIST

