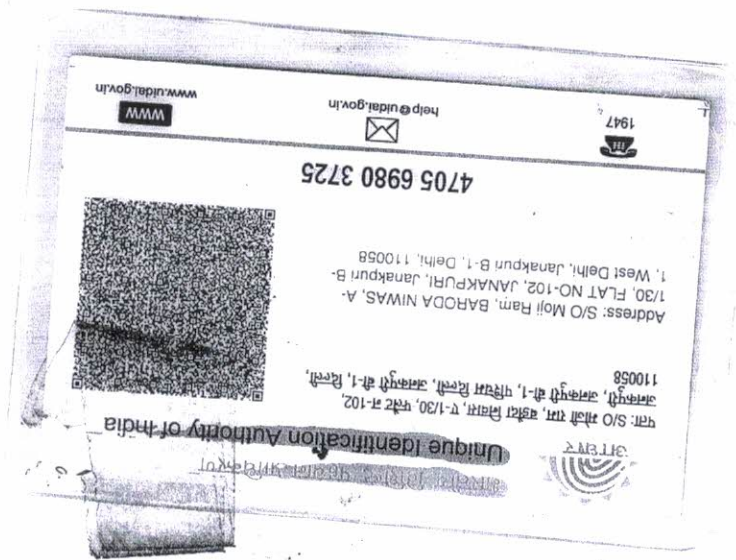


For Health check up
one plus Ultrasound
@Janakpur
[Signature]
26/2/22


[Signature]

Dr. NITIN AGARWAL
MBBS, MD
Regn. No. DMC-R-1436



ULTRASOUND LAB
Vihar, Pitam Pura,
Delhi-110034
2480101, 9599913051
E-mail: pneplusul@gmail.com





Dr. NITIN AGARWAL
MBBS, MD
Regn No. DMC-R-1436

for Annual Health check up
one plus Ultrasound, Papanicolaou

Singh

26/02/22

ONEPLUS ULTRASOUND LAB
47, Harsh Vihar, Pitam Pura,
Delhi-110034
Ph. 011-42480101, 9599913051
E-mail: oneplusul@gmail.com

ONEPLUS ULTRASOUND LAB

47, HARSH VIHAR, PITAMPURA, DELHI- 110034

Mr. SATYAVIR SINGH
 Age : 49M
 Ref. by : MEDHEEL
 Indication1 :
 Indication2 :
 Indication3 :
 COMMENTS : Normal ECG.

ID : 1890
 H/W/M : 165/60
 Recorded : 26-2-2022 13:08
 Medication1 :
 Medication2 :
 Medication3 :

[Handwritten Signature]

BPM : 85
 BP : 138/88
 P Axis : 69 deg
 QRS Axis : 68 deg
 T Axis : 52 deg

P duration : 93 msec
 PR duration : 150 msec
 QRS duration : 106 msec
 QT interval : 300 msec
 QTc interval : 343 msec

Raw E.C.G.(Seq)

[Handwritten Signature]

Unconfirmed Report Reviewed By:

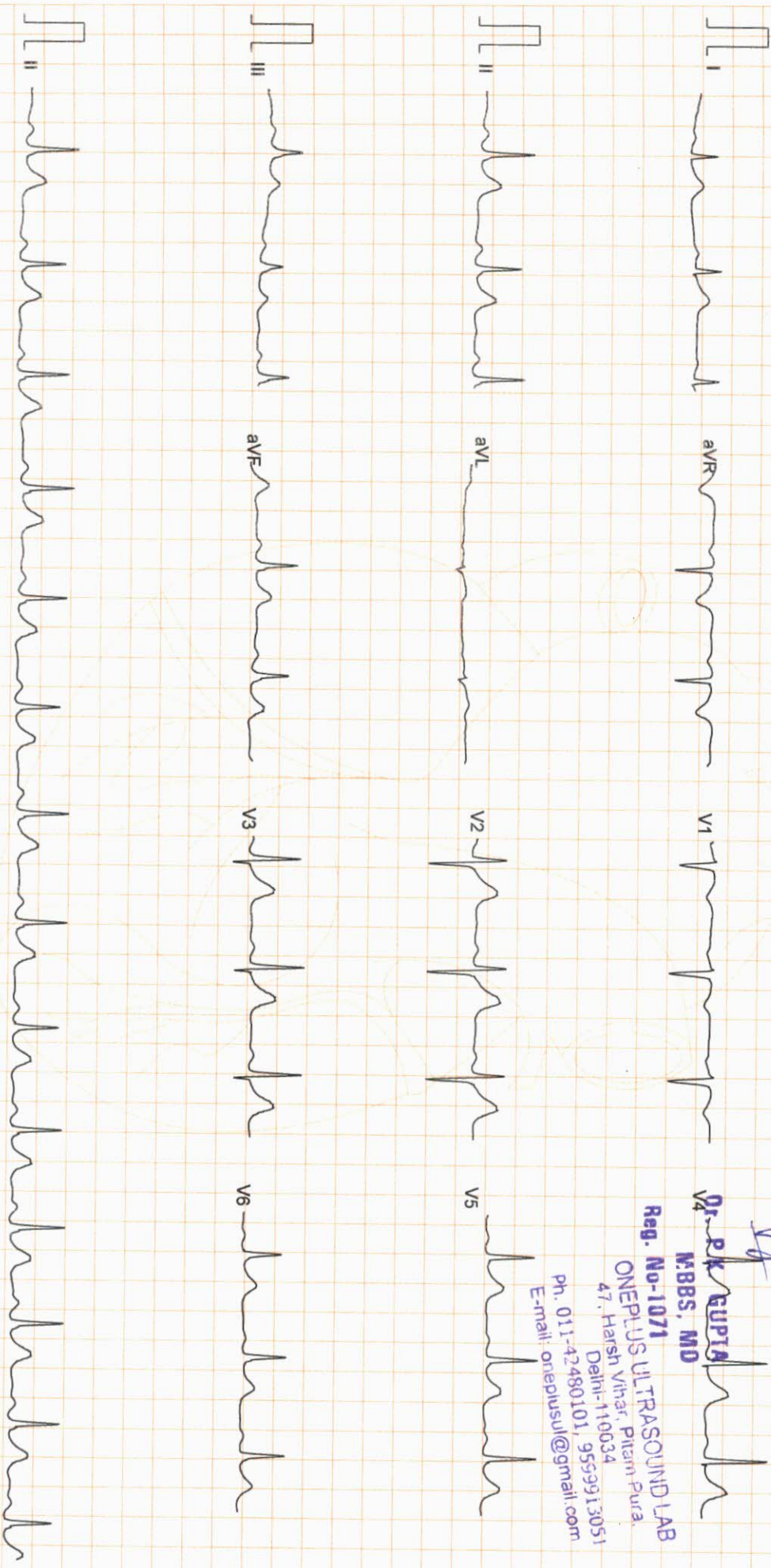
Cardiologist

[Handwritten Signature]
Dr. P.K. Gupta

M.B.B.S, MD

Reg. No-1071

ONEPLUS ULTRASOUND LAB
 47, Harsh Vihar Pitam Pura,
 Delhi-110034
 Ph. 011-42480101, 9559913051
 E-mail: oneplusul@gmail.com



Filtered

25mm/sec 10mm/mV

ACE 2.0 W

CardiCom, INDIA

ONEPLUS ULTRASOUND LAB

47, HARSH VIHAR PITAMPURA DELHI 110034

ID : 991

H/Wt : 165/60
Recorded : 26-2-2022 13:10

Mr. SATYAVIR SINGH
Age/Sex : 49/M
Ref. by : MEDIWHEEL
Indication1 :
Indication2 :
Indication3 :

TREADMILL TEST SUMMARY REPORT
Protocol: BRUCE
History:
Medication1 :
Medication2 :
Medication3 :

PHASE	PHASE TIME	STAGE TIME	SPEED (Km./Hr.)	GRADE (%)	H.R. (BPM)	B.P. (mmHg)	RPP X100	II	ST LEVEL (mm) V2	V5	METS
SUPINE					80	138/88	110	0.8	1.3	0.8	
STANDING					77	138/88	106	0.7	1.3	0.9	
STAGE 1	2:59	2:59	2.70	10.00	102	150/90	153	1.4	1.5	1.2	4.80
STAGE 2	5:59	2:59	4.00	12.00	116	160/92	185	3.4	1.7	1.1	7.10
STAGE 3	8:59	2:59	5.40	14.00	119	170/94	202	3.2	0.0	0.4	10.00
STAGE 4	10:29	1:29	6.70	16.00	151	180/96	271	1.6	2.1	1.3	11.99
PEAK EXER	10:34	1:34			150	180/96	270	1.8	2.3	1.1	12.10
RECOVERY	2:59	2:59	0.00	0.00	111	138/88	153	0.7	1.1	0.6	

RESULTS

Exercise Duration : 10:34 Minutes
Max Heart Rate : 151 bpm 88 % of target heart rate 171 bpm
Max Blood Pressure : 180/96 mmHg
Max Work Load : 12.10 METS
Reason of Termination :

Next for id-10-21

GA

[Signature]

Cardiologist
Dr. P.K. GUPIA
MBBS, MD
Reg. No-1071

ONEPLUS ULTRASOUND LAB
47, Harsh Vihar, Pitampura,
Delhi-110034
Ph. 011-42480101, 9599913051
E-mail: oneplusul@gmail.com

ONEPLUS ULTRASOUND LAB

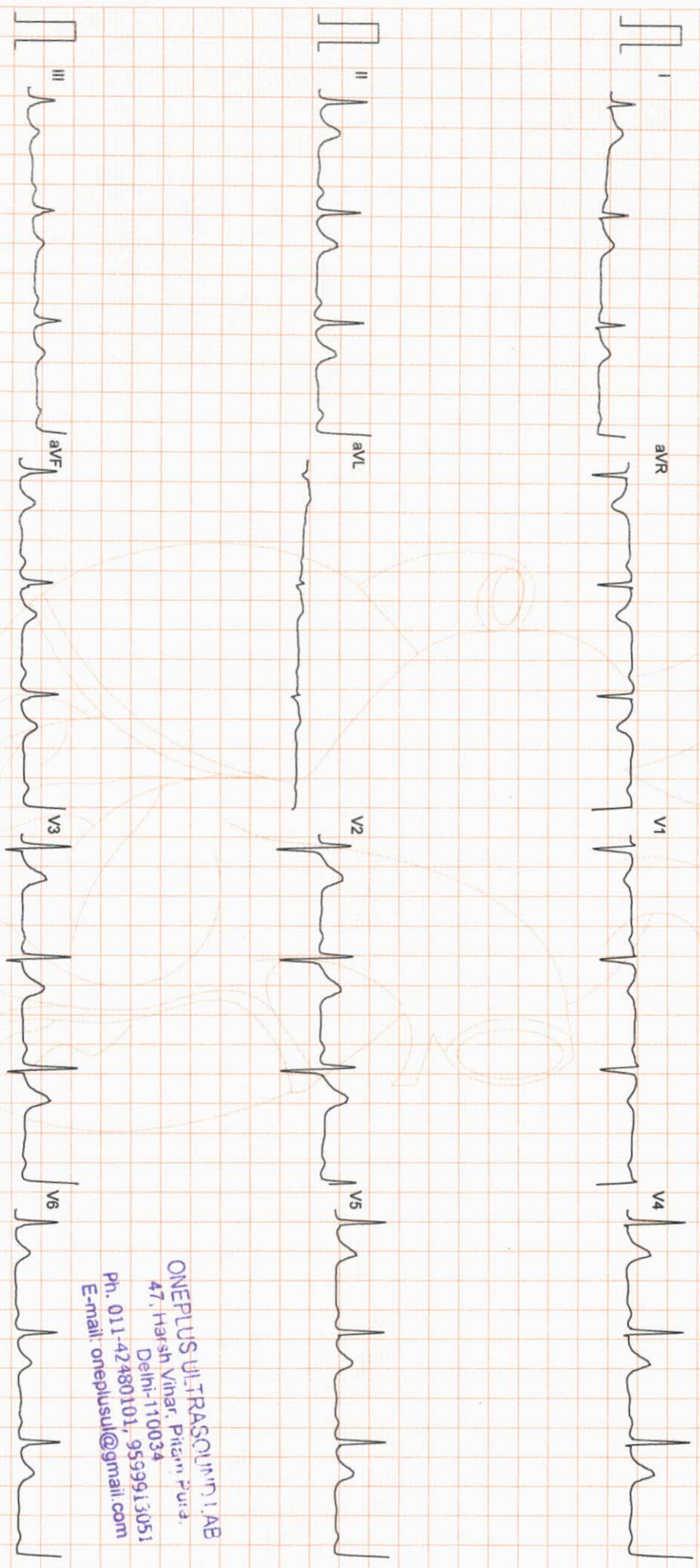
SUPINE
PRETEST

ST @ 10mm/mV
80ms PostJ

Mr. SATYAVIR SINGH
I.D. : 991
AGE/SEX : 49/M

RATE : 80 BPM
B.P. : 138/88 mmHg

RAW E.C.G.



ONEPLUS ULTRASOUND LAB
47, Harsh Vihar, Pitam Pura,
Delhi-110034
Ph. 011-42480101, 9559913051
E-mail: oneplusul@gmail.com

Filtered

25mm/sec 10mm/mV



CardiCom, INDIA Ph.:091-731-2620740

ONEPLUS ULTRASOUND LAB

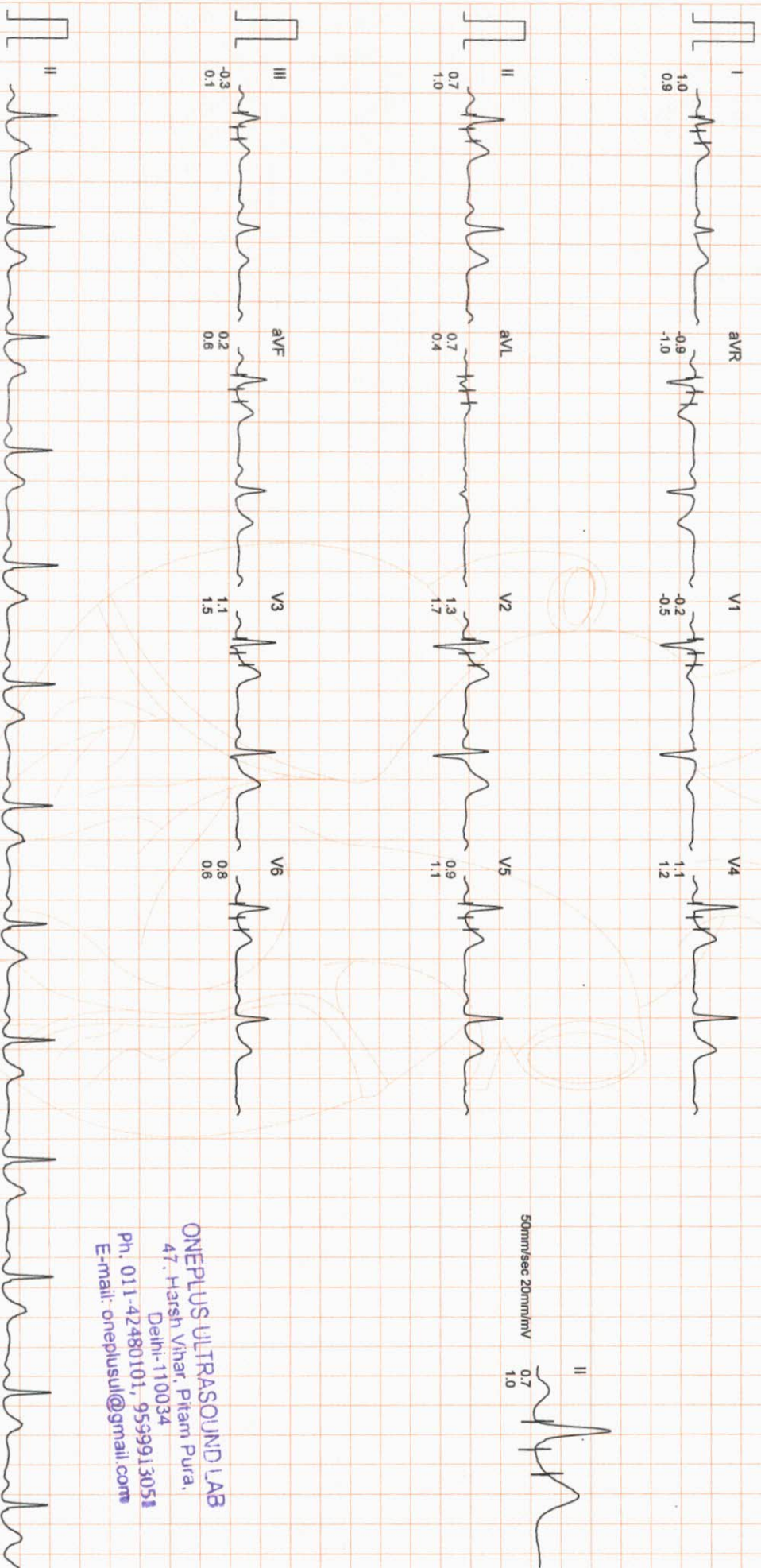
STANDING
PRETEST

ST @ 10mm/mV
80ms PostJ


Mr. SATYAVIR SINGH
I.D. : 991
AGE/SEX : 49/M
RECORDED : 26-2-2022 13:10

RATE : 77 BPM
B.P. : 138/88 mmHg

LINKED MEDIAN



ONEPLUS ULTRASOUND LAB
47, Harsh Vihar, Pitam Pura,
Delhi-110034
Ph. 011-42480101, 9599913051
E-mail: oneplusul@gmail.com



ONEPLUS ULTRASOUND LAB

Mr. SATYAVIR SINGH

I.D. : 991

AGE/SEX : 49/M

RECORDED : 26-2-2022 13:10

RATE : 102 BPM

B.P. : 150/90 mmHg

BRUCE

EXERCISE 1

PHASE TIME : 2:59

STAGE TIME : 2:59

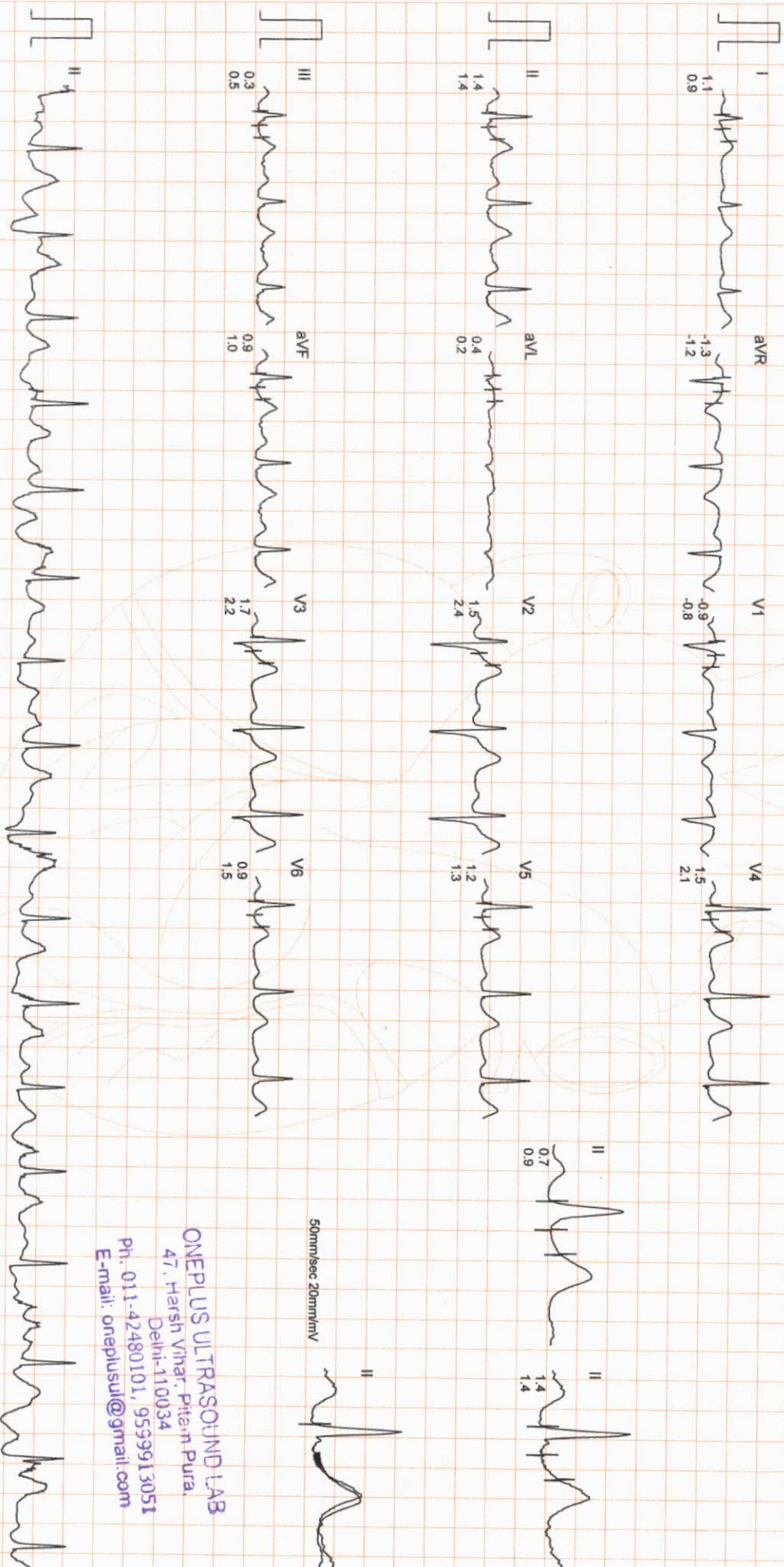
ST @ 10mm/mV

80ms PostJ

SPEED : 2.7 Km./Hr.

GRADE : 10.0 %

LINKED MEDIAN



50mm/sec 20mm/mV

ONEPLUS ULTRASOUND LAB
47, Harsh Vihar, Pitam Pura,
Delhi-110034
Ph. 011-42480101, 9539913051
E-mail: oneplusul@gmail.com

ONEPLUS ULTRASOUND LAB

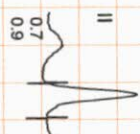
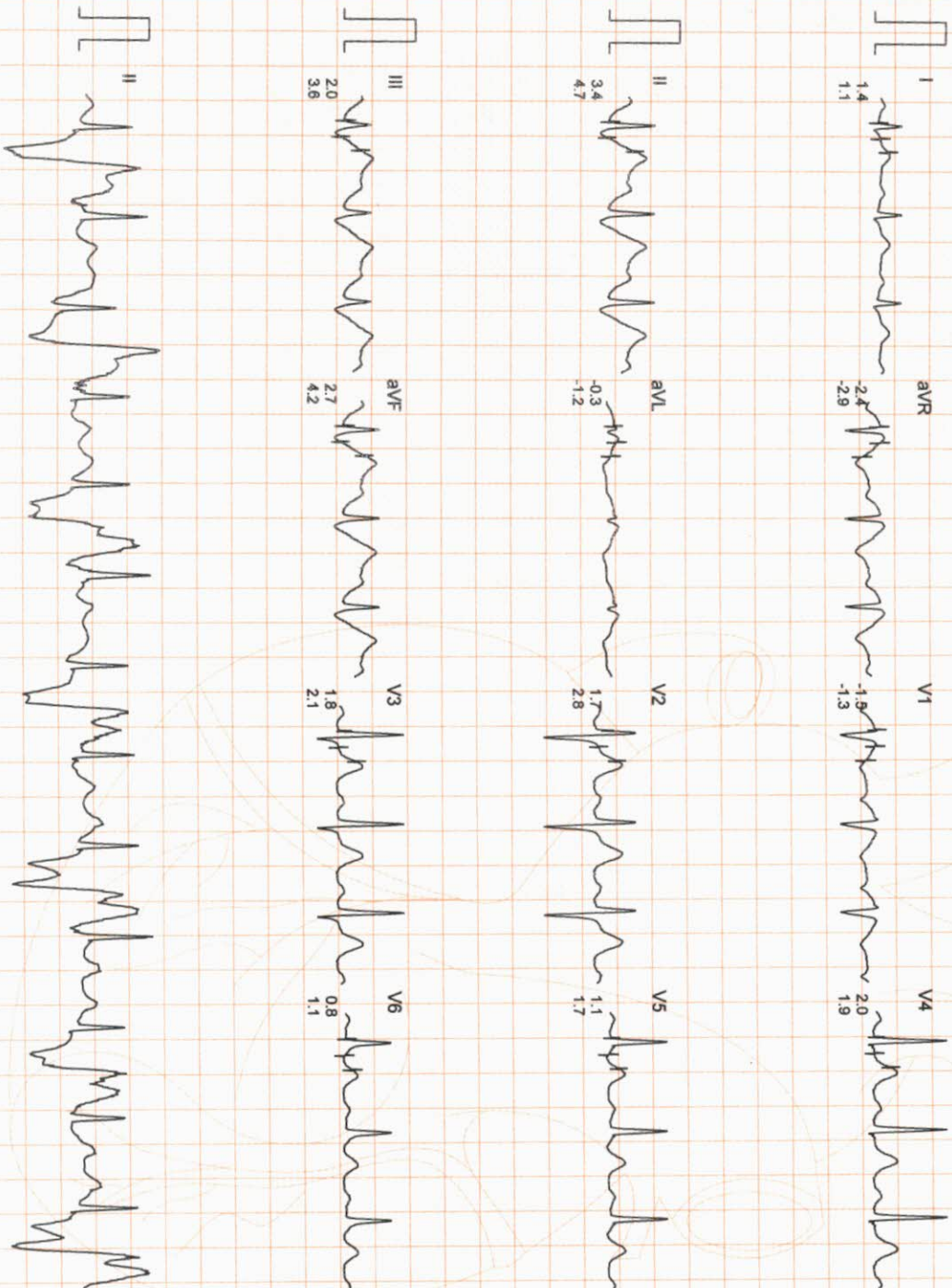
Mr. SATYAVIR SINGH
 I.D. : 991
 AGE/SEX : 49/M
 RECORDED : 26-2-2022 13:10

RATE : 116 BPM
 B.P. : 160/92 mmHg

BRUCE
 EXERCISE 2
 PHASE TIME : 5:59
 STAGE TIME : 2:59

ST @ 10mm/mV
 80ms PostJ
 SPEED : 4.0 Km./HR.
 GRADE : 12.0 %

LINKED MEDIAN



50mm/sec 20mm/mV



ONEPLUS ULTRASOUND LAB
 47, Harsh Vihar, Pitam: Pura,
 Delhi-110034
 Ph. 011-42480101, 9599913051
 E-mail: oneplusul@gmail.com

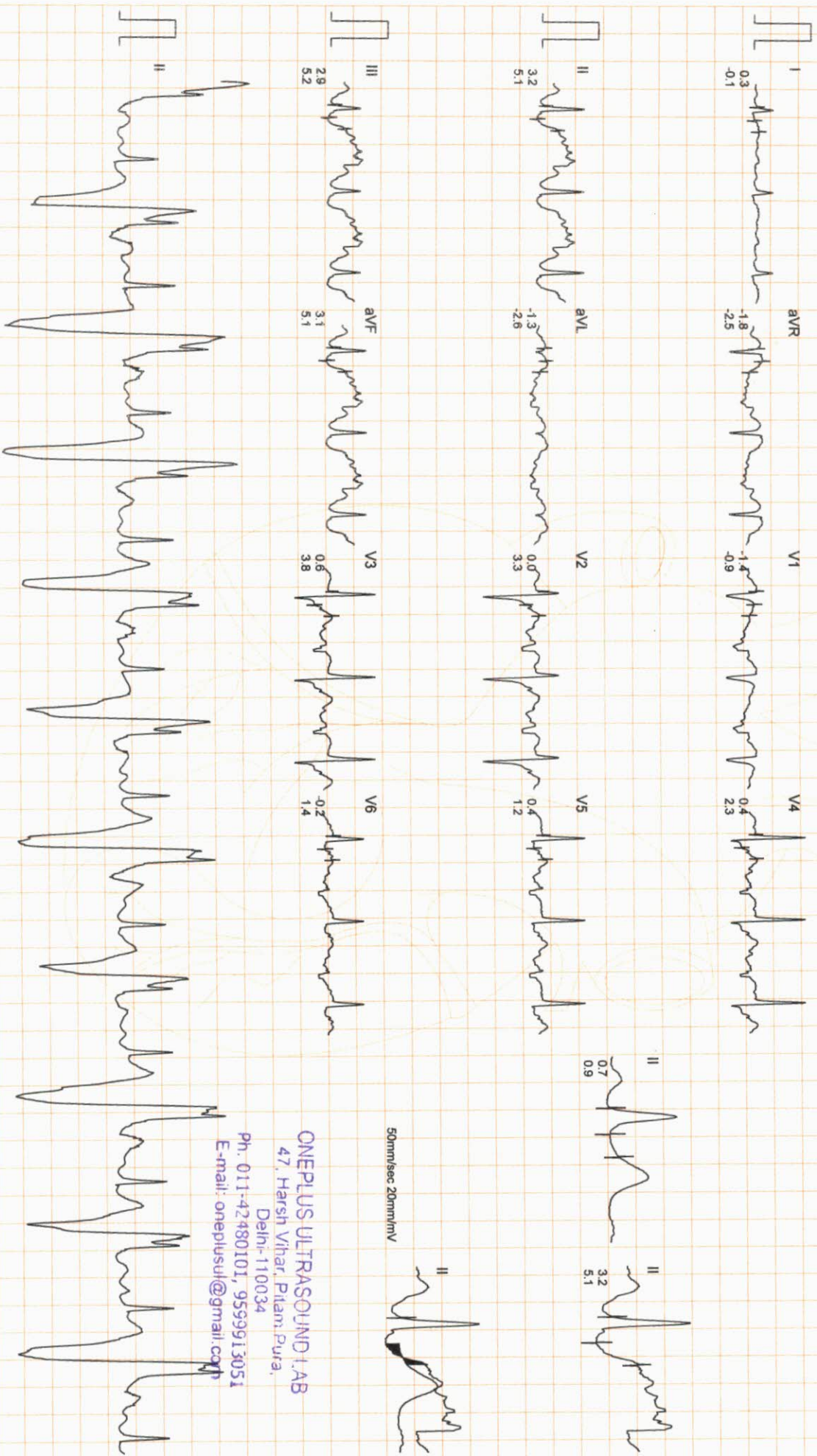
ONEPLUS ULTRASOUND LAB

Mr. SATYAVIR SINGH
I.D. : 991
AGE/SEX : 49/M
RECORDED : 26-2-2022 13:10

RATE : 119 BPM
B.P. : 170/94 mmHg

BRUCE
EXERCISE 3
PHASE TIME : 8:59
STAGE TIME : 2:59

ST @ 10mm/mV
80ms PostJ
SPEED : 5.4 Km./Hr.
GRADE : 14.0 %
LINKED MEDIAN



ONEPLUS ULTRASOUND LAB
47, Harsh Vihar, Pitam, Pura,
Delhi-110034
Ph. 011-42480101, 9599913051
E-mail: oneplusul@gmail.com

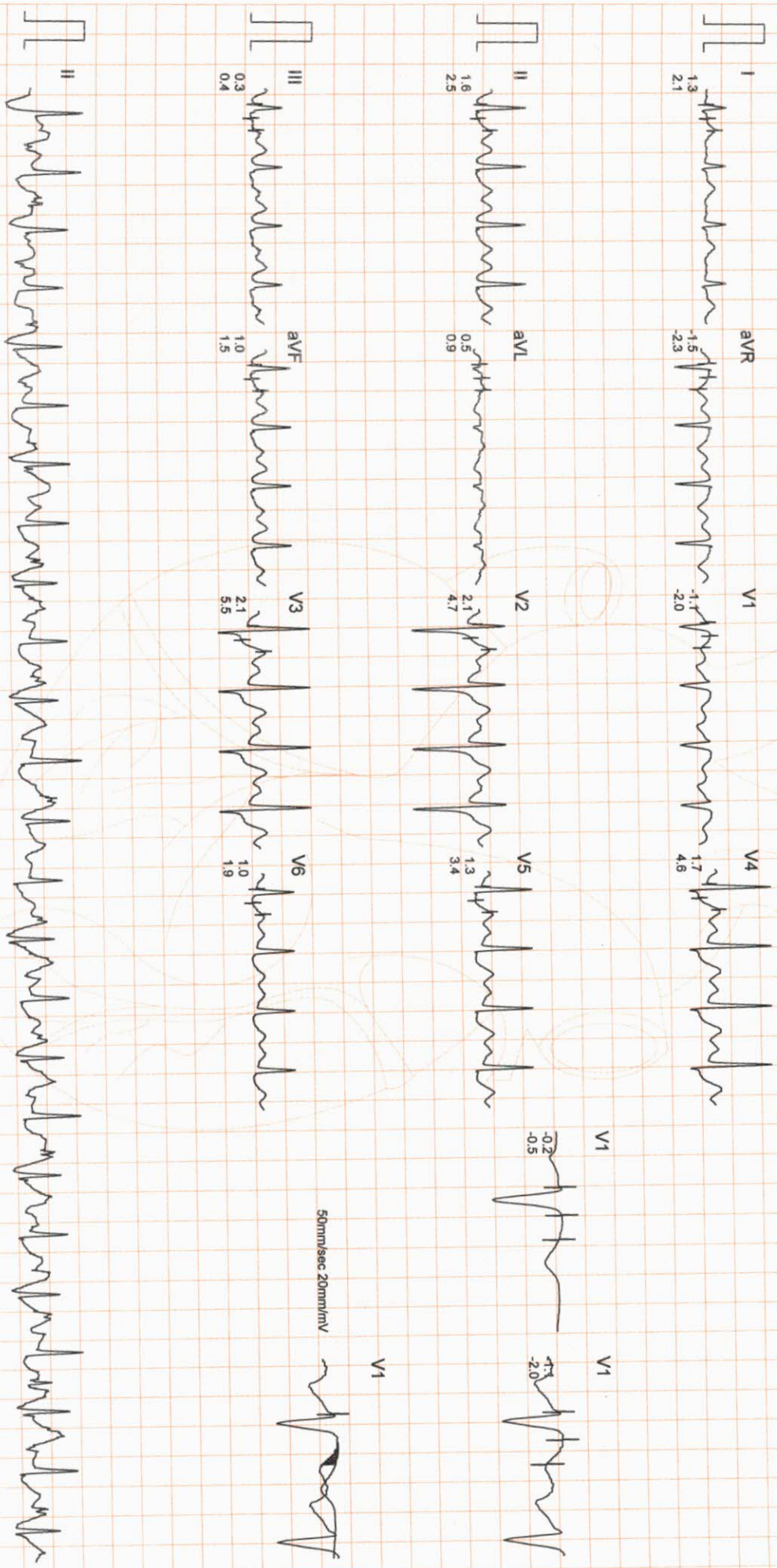
ONEPLUS ULTRASOUND LAB

MR. SATYAVIR SINGH
I.D. : 991
AGE/SEX : 49/M
RECORDED : 26-2-2022 13:10

RATE : 151 BPM
B.P. : 180/96 mmHg

BRUCE
EXERCISE 4
PHASE TIME : 10:29
STAGE TIME : 1:29

ST @ 10mm/mV
80ms PostJ
SPEED : 6.7 Km./Hr.
GRADE : 16.0 %
LINKED MEDIAN



ONEPLUS ULTRASOUND LAB

Mr. SATYAVIR SINGH

I.D. : 991

AGE/SEX : 49/M

RECORDED : 26-2-2022 13:10

RATE : 150 BPM

B.P. : 180/96 mmHg

BRUCE
PEAK EXER

PHASE TIME : 10:34

STAGE TIME : 1:34

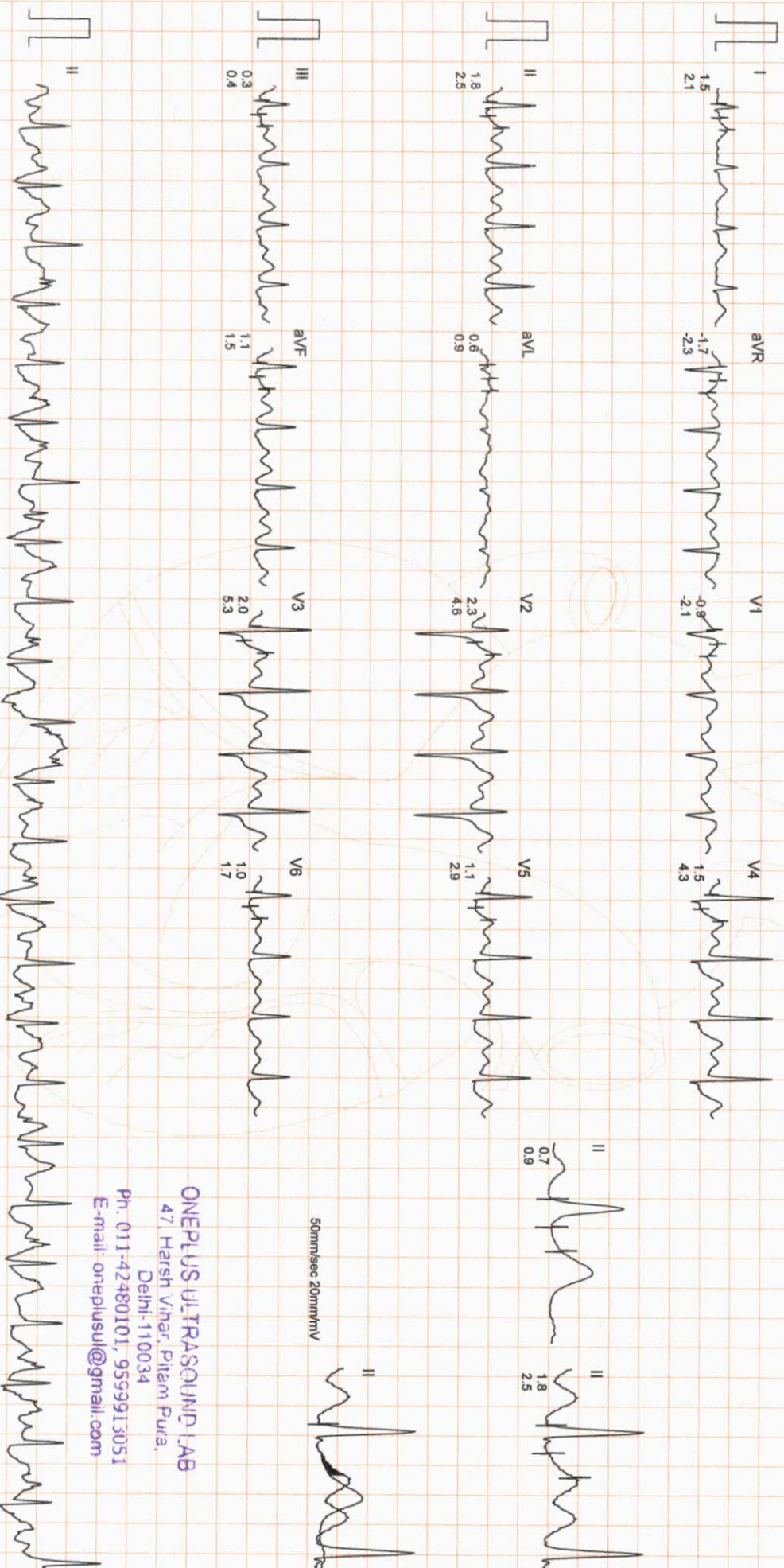
ST @ 10mm/mV

80ms PostJ

SPEED : 6.7 Km./Hr.

GRADE : 16.0 %

LINKED MEDIAN



50mmsec 20mm/mV

ONEPLUS ULTRASOUND LAB

47, Harsh Vihar, Pitam Pura,

Delhi-110034

Ph: 011-42480101, 9559913051

E-mail: oneplusul@gmail.com

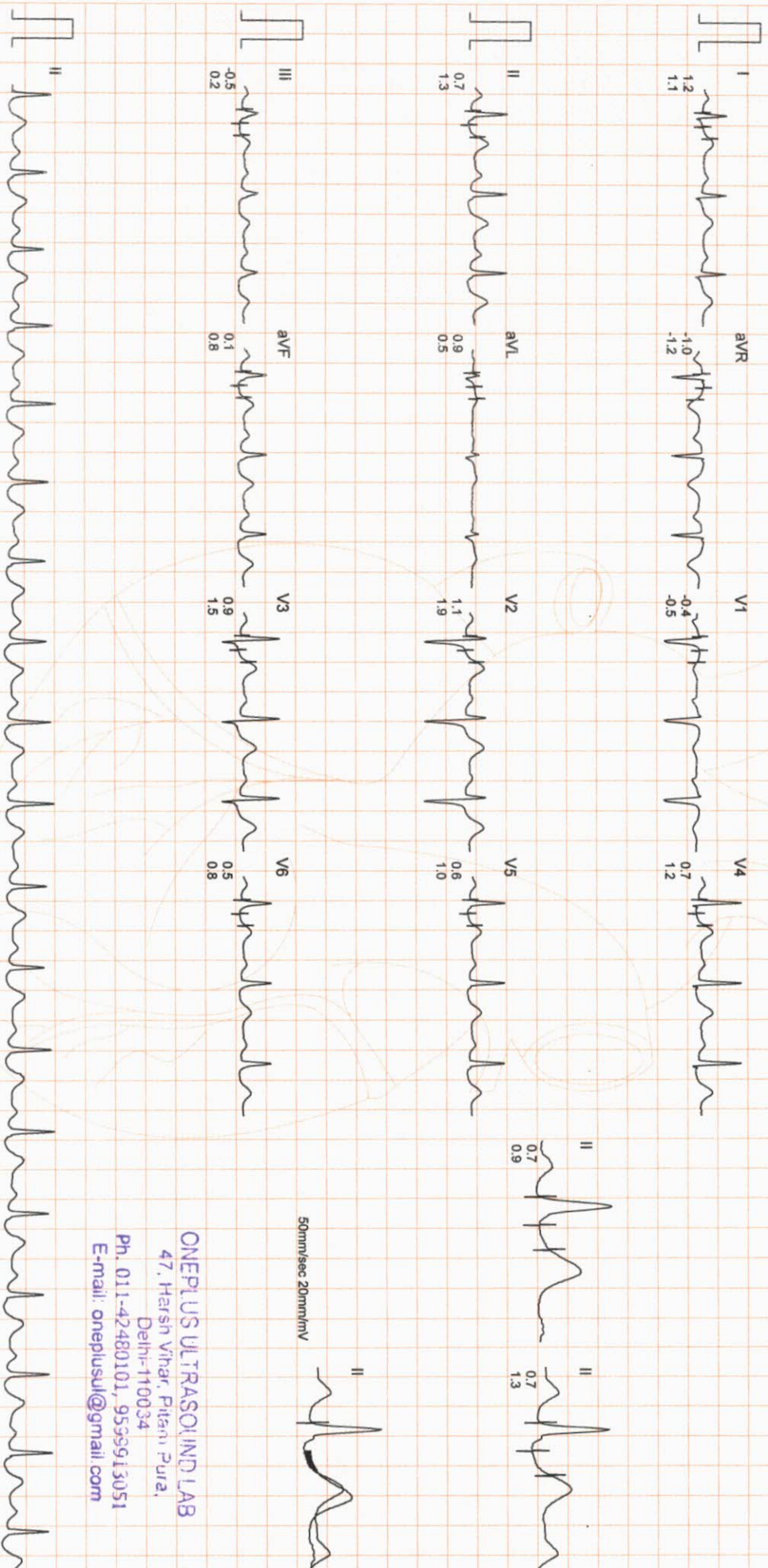
ONEPLUS ULTRASOUND LAB

Mr. SATYAVIR SINGH
I.D. : 991
AGE/SEX : 49/M
RECORDED : 26-2-2022 13:10

RATE : 111 BPM
B.P. : 138/88 mmHg



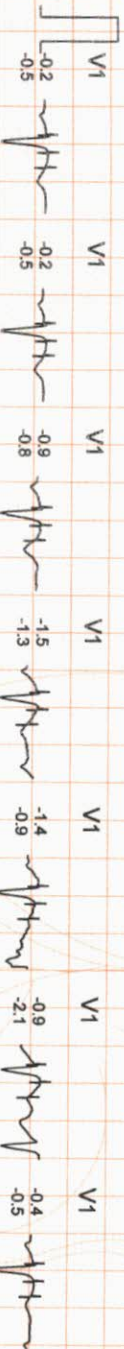
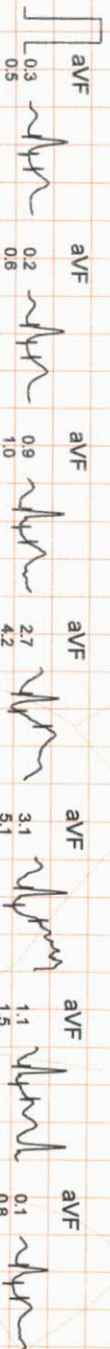


BRUCE
RECOVERY
PHASE TIME : 2:59

ST @ 10mm/mV
80ms PostI
SPEED : 0.0 Km./Hr.
GRADE : 0.0 %
LINKED MEDIAN



ONEPLUS ULTRASOUND LAB
47, Harsh Vihar, Pitara Pura,
Delhi-110034
Ph. 011-42480101, 9539913051
E-mail: oneplusul@gmail.com

STAGE	TIME	HR	BP	SpO2
SUPINE		80 bpm	138/88	80ms PostJ
STANDING		77 bpm	138/88	80ms PostJ
STAGE 1	2:59	102 bpm	150/90	80ms PostJ
STAGE 2	5:59	118 bpm	160/92	80ms PostJ
STAGE 3	8:59	119 bpm	170/94	80ms PostJ
PEAK EXERCISE	10:34	160 bpm	180/96	80ms PostJ
RECOVERY	2:59	111 bpm	138/88	80ms PostJ






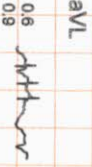











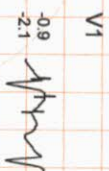
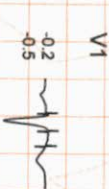
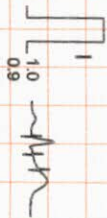
ONEPLUS ULTRASOUND LAB
 47, Harsh Vihar, Pitam Pura,
 Delhi-110034
 Ph. 011-42480101, 9599913051
 E-mail: oneplusul@gmail.com

STANDING
 0.0Kmph
 0.0%
 77 bpm
 B.P. 138/88
 80ms PostU

PEAK EXERCISE
 10.34
 1.34
 6.7Kmph
 16.0%
 150 bpm
 B.P. 180/96
 80ms PostU

STANDING
 0.0Kmph
 0.0%
 77 bpm
 B.P. 138/88
 80ms PostU

PEAK EXERCISE
 10.34
 1.34
 6.7Kmph
 16.0%
 150 bpm
 B.P. 180/96
 80ms PostU



ONEPLUS ULTRASOUND LAB
 47, Harsh Vihar, Pitam Pura,
 Delhi-110034
 Ph. 011-42480101, 9599913050
 E-mail: oneplusul@gmail.com



OnePLUS
Ultrasound Lab
— QUALITY FIRST... ALWAYS! —

Dr. Nitin Agarwal
Pathologist & Director
Ex. Sr. Res. MAMC
& Lok Nayak Hospital
Ex. Chief of Lab Dr. Lal Path Labs.

Dr. Pooja (Garg) Agarwal
Radiologist & Director
MAMC & Lok Nayak Hospital

Name	: Mr. SATYAVIR SINGH	Age/Sex	: 49 YRS/Male
Ref. By	: Dr. MEDIWHEEL	Lab No	: 012202260037
Date	: 26-Feb-2022	Patient ID	: LSHHI91748

ULTRASOUND EXAMINATION----WHOLE ABDOMEN

Liver is normal in size and normal in outline with normal echopattern. Intrahepatic biliary radicles are not dilated. No abscess or mass lesion seen. Hepatic veins, portal vein, IVC and aorta are normal. CBD is normal in caliber.

Gall bladder is well distended with anechoic lumen. Wall thickness is normal.

Both kidneys are normal in size, shape, position, outline and echopattern. Corticomedullary differentiation is maintained. No pelvicalyceal dilation or mass lesion is seen.

Spleen is normal in size and echotexture. No mass lesion seen.

Pancreas is normal in size, outline and echotexture.

Urinary bladder is normal in shape and position. No evidence of intravesical stone or mass seen.


Prostate is normal in size, shape and echopattern.

Prostate measures 2.8 x 3.5 x 3.8 cm. **Weight of prostate is 19 grams.**

No abnormal bowel wall thickening seen in right iliac fossa.
No free fluid seen anywhere in abdomen.

IMPRESSION:

- Normal study.

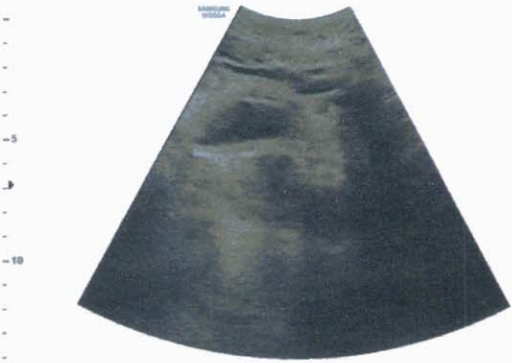
DR. POOJA GARG
RADIOLOGIST
REG NO- DMC/R/03398
Dr. POOJA GARG
M.B.B.S., D.M.R.D
Reg No. DMC/R/03398
Radiologist

Type By : DARSHITA

47, Harsh Vihar, Pitampura, New Delhi-110034 | Ph.: 011-42480101, 9599913051
E-mail: oneplusul@gmail.com | Web.: www.oneplusul.in

MR SATYAVEER 49/M
OnePlus Ultrasound Lab
CA1-7A / Abdomen / FR 27Hz
MI 1.5 26-02-2022
Tib 0.1 11:48:38 AM

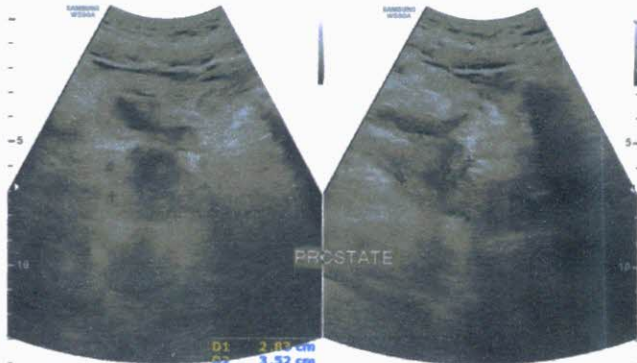G51 DR130-FA11 P100-Frq Pen. 14.0cm



MR SATYAVEER 49/M
OnePlus Ultrasound Lab
CA1-7A / Abdomen / FR 27Hz
MI 1.5 26-02-2022
Tib 0.1 11:49:16 AM

G51 DR130-FA11 P100-Frq Pen. 14.0cm

G51 DRT30-FA11 P100-Frq Pen. 14.0cm



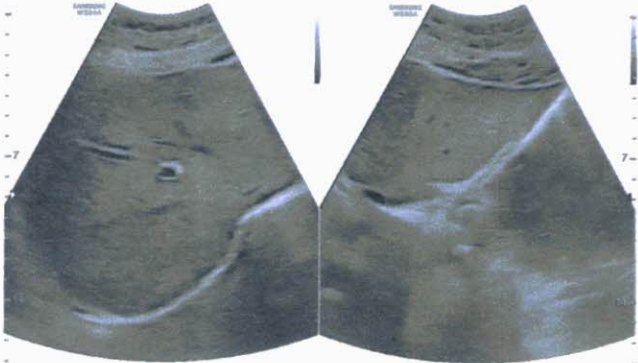D1 2.83 cm
D2 3.52 cm
D3 3.76 cm
Vol. 19.57 ml

D1 2.83 cm
D2 3.52 cm

MR SATYAVEER 49/M
OnePlus Ultrasound Lab
CA1-7A / Abdomen / FR 23Hz
MI 1.5 26-02-2022
Tib 0.2 11:49:28 AM

G55 DR130-FA11 P100-Frq Pen. 17.0cm

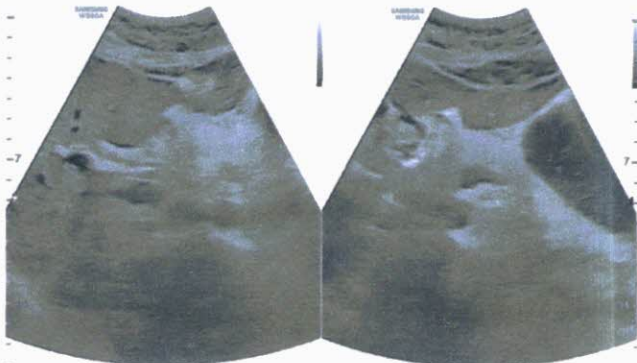
G55 DRT30-FA11 P100-Frq Pen. 17.0cm



MR SATYAVEER 49/M
OnePlus Ultrasound Lab
CA1-7A / Abdomen / FR 23Hz
MI 1.5 26-02-2022
Tib 0.2 11:49:33 AM

G55 DR130-FA11 P100-Frq Pen. 17.0cm

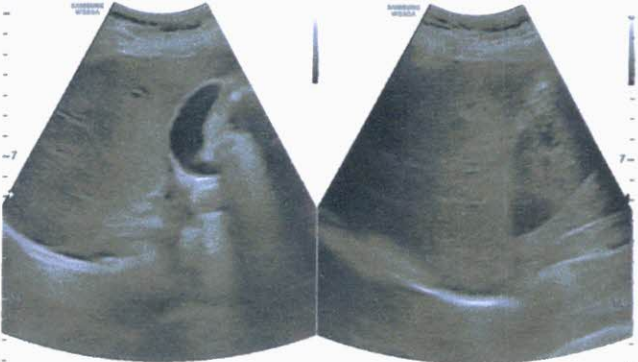G55 DR130-FA11 P100-Frq Pen. 17.0cm



MR SATYAVEER 49/M
OnePlus Ultrasound Lab
CA1-7A / Abdomen / FR 23Hz
MI 1.5 26-02-2022
Tib 0.2 11:49:50 AM

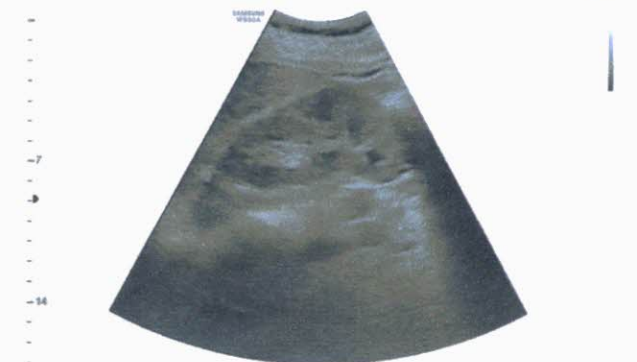G59 DR130-FA11 P100-Frq Pen. 17.0cm

G59 DRT30-FA11 P100-Frq Pen. 17.0cm



MR SATYAVEER 49/M
OnePlus Ultrasound Lab
CA1-7A / Abdomen / FR 23Hz
MI 1.5 26-02-2022
Tib 0.2 11:49:50 AM

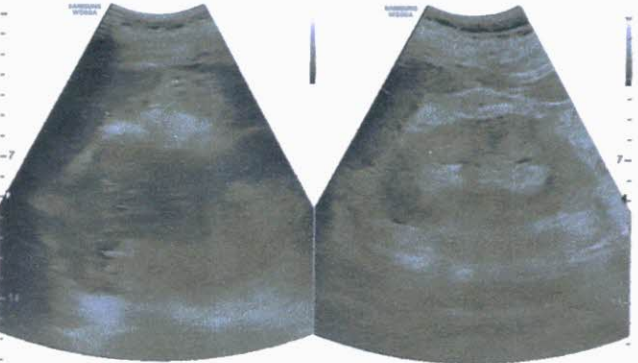G59 DR130-FA11 P100-Frq Pen. 17.0cm



MR SATYAVEER 49/M
OnePlus Ultrasound Lab
CA1-7A / Abdomen / FR 23Hz
MI 1.5 26-02-2022
Tib 0.2 11:50:15 AM

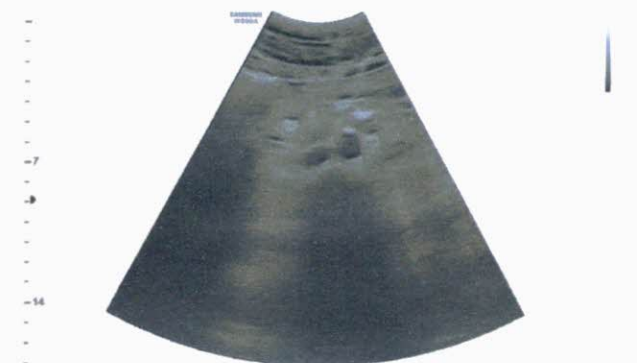G56 DR130-FA11 P100-Frq Pen. 17.0cm

G56 DR130-FA11 P100-Frq Pen. 17.0cm



MR SATYAVEER 49/M
OnePlus Ultrasound Lab
CA1-7A / Abdomen / FR 23Hz
MI 1.5 26-02-2022
Tib 0.2 11:50:29 AM

G50 DR130-FA11 P100-Frq Pen. 17.0cm





OnePLUS
Ultrasound Lab
— QUALITY FIRST... ALWAYS! —

Dr. Nitin Agarwal

Pathologist & Director
Ex. Sr. Res. MAMC
& Lok Nayak Hospital
Ex. Chief of Lab Dr. Lal Path Labs.

Dr. Pooja (Garg) Agarwal


Radiologist & Director
MAMC & Lok Nayak Hospital

Name	: Mr. SATYAVIR SINGH	Age/Sex	: 49 YRS/Male
Ref. By	: Dr. MEDIWHEEL	Lab No	: 012202260037
Date	: 26-Feb-2022	Patient ID	: LSHHI91748

X-ray-Chest PA view

Bony cage and soft tissues are normal.
Cardiothoracic ratio is normal.
Mediastinum is normal.
Both hila are normal.
Both costophrenic angles are clear.
Both domes of diaphragm are normal.
Lung fields are clear. No parenchymal lesion seen.

IMPRESSION: Normal Study.

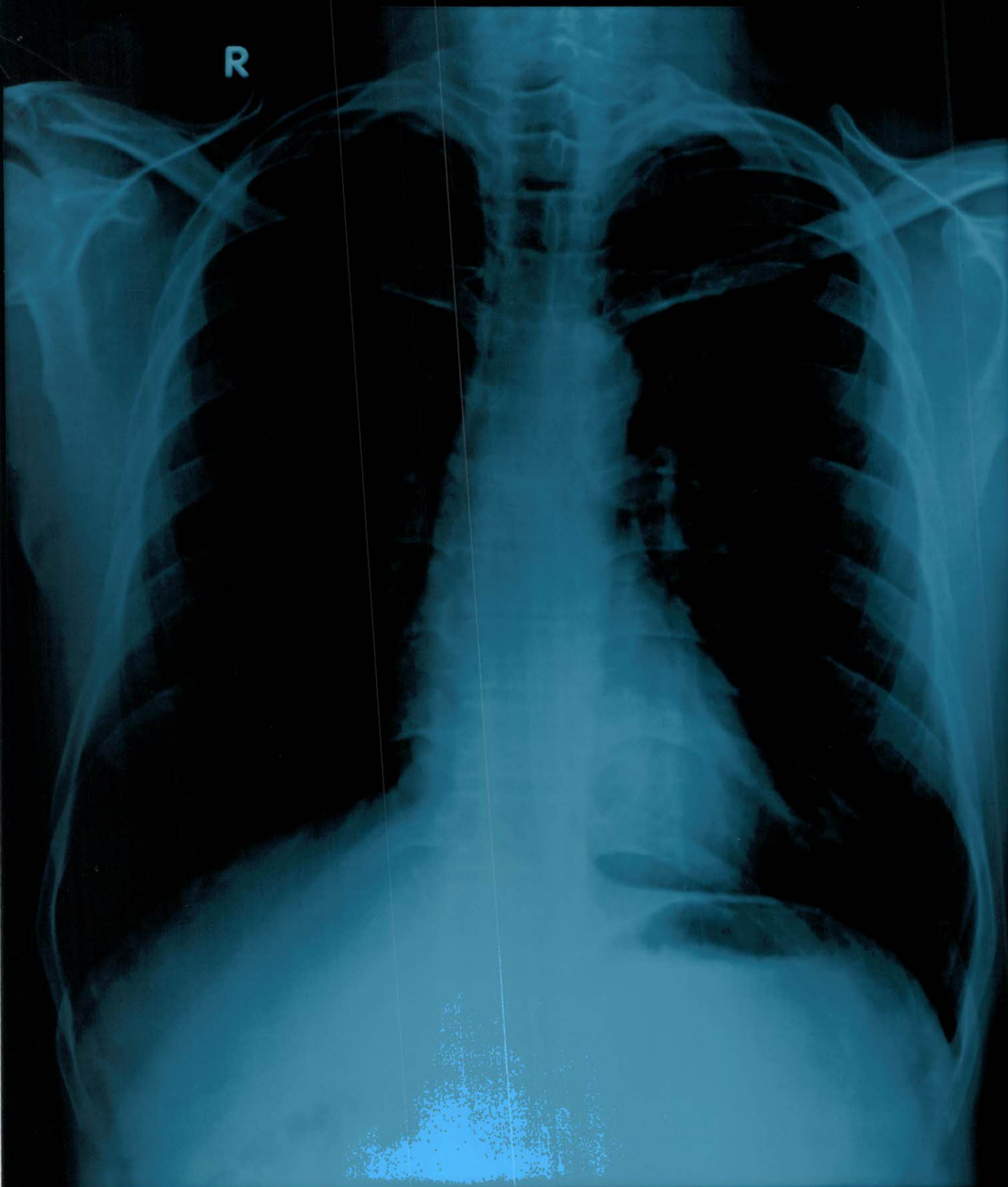

DR. POOJA GARG
RADIOLOGIST
REG NO- DMC/R/03398

Dr. POOJA GARG
M.B.B.S., D.M.R.D.
Reg No. DMC/R/03398
Radiologist

Type By : DARSHITA

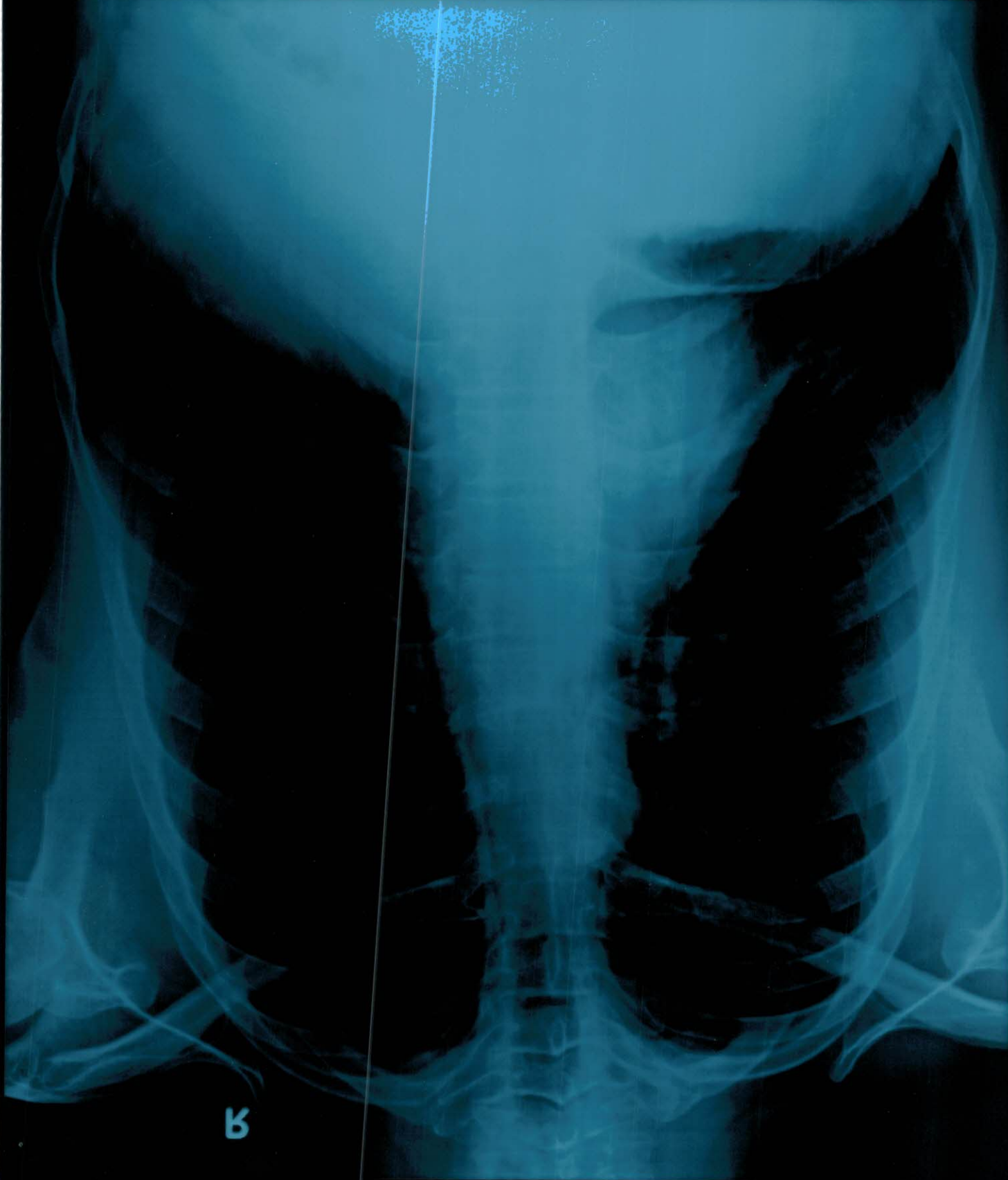
47, Harsh Vihar, Pitampura, New Delhi-110034 | Ph.: 011-42480101, 9599913051
E-mail: oneplusul@gmail.com | Web.: www.oneplusul.in

R



MR SATYAVIR SINGH AGE 49 YRS 26-2-2022 M CHEST PA
ONEPLUS ULTRASOUND LAB,47-HARSH VIHAR,PITAMPURA

АПТЭШС М 2202-2-82 ЗРЭ 49 АСА НАИИР ПИВАТАС РМ
ОИЕРГУС ПГТРАСОИИД ГЛВ, 47-НАР2Н ВИНАР, ПИТАМЬУКА



В