


ONEPLUS ULTRASOUND LAB
47 Harsh Vihar, Pitam Pura,
Delhi-110034
Ph. 011-42480101, 9599913051
E-mail onepusul@gmail.com

DR. NITIN AGARWAL
MBBS, MD
Regn. No. DMC-R-1436

Kulka



ONEPLUS ULTRASOUND LAB
47 Harsh Vihar, Pitam Pura,
Delhi-110034
Ph. 011-42460101, 9599913051
E-mail: oneplusul@gmail.com

DR. NITIN AGARWAL
MBBS, MD
Regn. No. DMC-R-1436

Kuber



ONEPLUS ULTRASOUND LAB

47, HARSH VIHAR, PITAMPURA, DELHI - 110034

Mr. ROHIT YADAV
Age : 34/M

ID : 2280

Ref. by : MEDIVHEEL

Indication1 :

Indication2 :

Indication3 :

COMMENTS : Normal ECG.

Recorded : 14-8-2023 9:04

Medication1 :

Medication2 :

Medication3 :

BPM : 68
P Axis : 114/68 deg
QRS Axis : 39 deg
T Axis : 32 deg

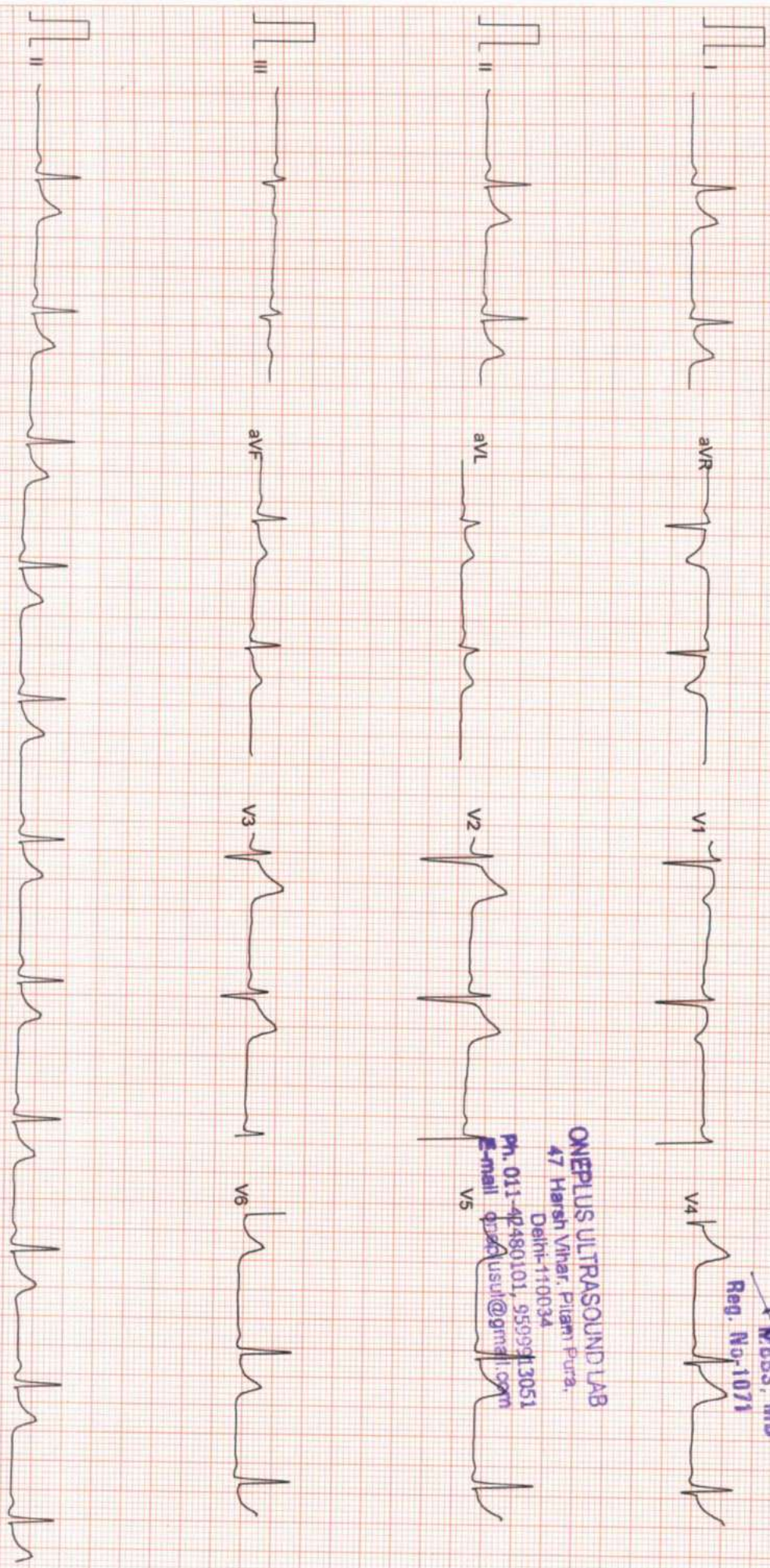
P duration : 93 msec
PR duration : 133 msec
QRS duration : 103 msec
QT Interval : 326 msec
QTc Interval : 340 msec

Raw E.C.G.(Seq)

Unconfirmed Report Reviewed By:
Cardiologist

Dr. PA GUPTA
MBBS, MD
Reg. No. 1071

ONEPLUS ULTRASOUND LAB
47 Harsh Vihar, Pitam Pura,
Delhi-110034
Ph. 011-42480101, 9509913051
E-mail: oneplusul@gnail.com



Filtered

25mm/sec 10mm/mV

CardiConn, INDIA

ONEPLUS ULTRASOUND LAB

47, HARSH VIHAR PITAMPURA DELHI 110034

Mr. ROHIT YADAV
Age/Sex : 34/M
Ref. by : MEDIWHEEL

ID : 998
H/Wt : 176/80
Recorded : 14-8-2023 9:07

Indication1 :
Indication2 :
Indication3 :

TREADMILL TEST SUMMARY REPORT
Protocol: BRUCE
History:
Medication1 :
Medication2 :
Medication3 :

PHASE	PHASE TIME	STAGE TIME	SPEED (Km./Hr.)	GRADE (%)	H.R. (BPM)	B.P. (mmHg)	RPP X100	II	ST LEVEL (mm) V2	V5	METS
SUPINE STANDING					66	114/68	75	1.3	3.3	1.9	
STAGE 1	2:59	2:59	2.70	10.00	65	114/68	74	1.3	3.4	2.0	
STAGE 2	5:59	2:59	4.00	12.00	92	114/68	104	1.4	3.8	2.2	4.80
STAGE 3	8:59	2:59	5.40	14.00	104	124/70	128	1.5	4.0	2.4	7.10
STAGE 4	9:59	0:59	6.70	16.00	130	140/76	182	0.9	3.7	2.3	10.00
PEAK EXER	10:01	1:01			171	150/80	256	0.0	1.9	1.3	11.32
RECOVERY	2:59	2:59	0.00	0.00	173	150/80	259	0.0	1.9	1.3	
			0.00	0.00	64	116/70	74	0.8	2.1	1.0	11.36

RESULTS

Exercise Duration : 10:01 Minutes
Max Heart Rate : 173 bpm 93 % of target heart rate 186 bpm
Max Blood Pressure : 150/80 mmHg
Max Work Load : 11.36 METS
Reason of Termination :

Negative for ischemia

ONEPLUS ULTRASOUND LAB
47 Harsh Vihar, Pitam Pura,
Delhi-110034
Ph. 011-42480101, 9599913051
E-mail onepiusul@gmail.com

Dr. P.K. GUPTA
MBBS, MD
Reg. No-1071
Cardiologist

Rohit

Mr. ROHIT YADAV
I.D. : 998
AGE/SEX : 34/M
RECORDED : 14-8-2023 9:07

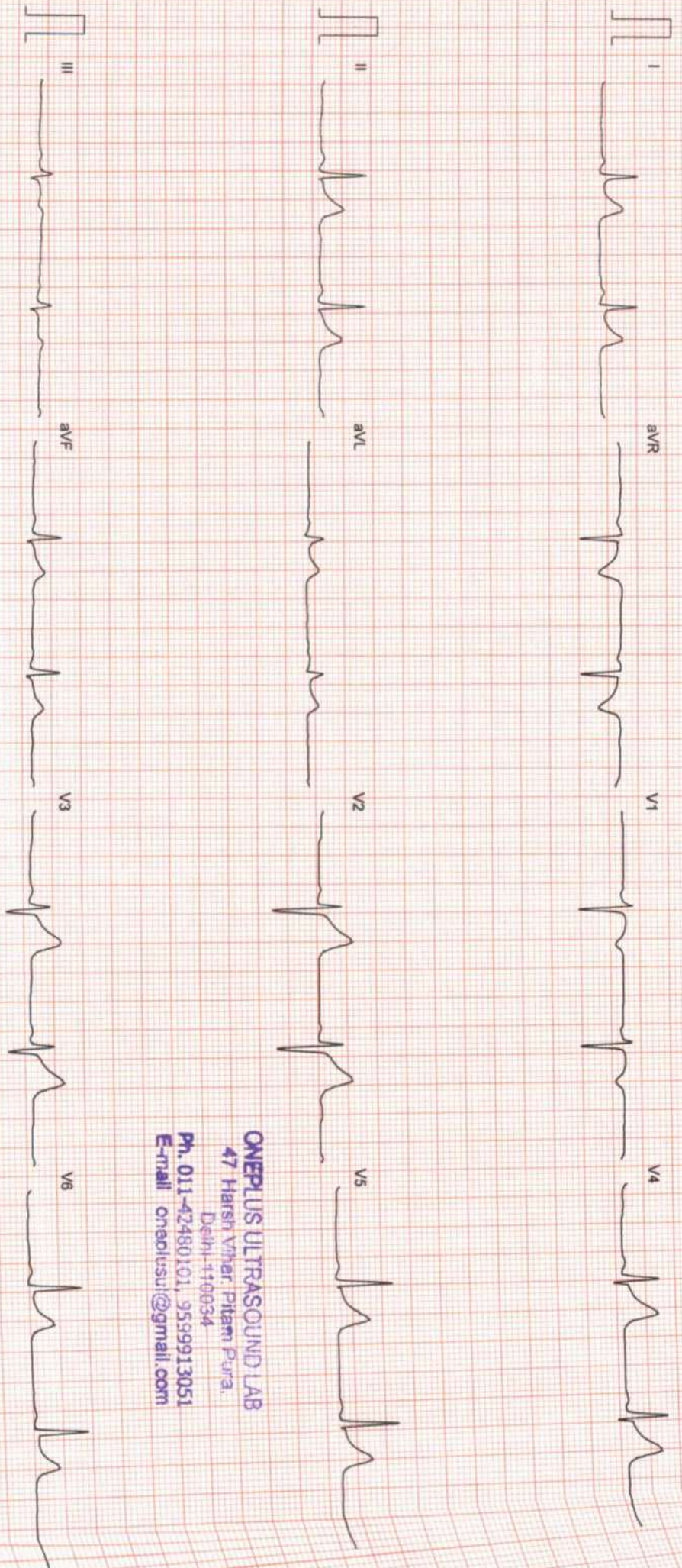
RATE : 66 BPM
B.P. : 114/68 mmHg

ONEPLUS ULTRASOUND LAB

SUPINE
PRETEST

ST @ 10mm/mV
80ms PostJ

RAW E.C.G.



ONEPLUS ULTRASOUND LAB
47 Harsh Vihar Pitam Pura,
Delhi-110034
Ph. 011-42480101, 9599913051
E-mail onepusul@gmail.com

Filter: 30

25mm/sec 10mm/mV

CardiCom, INDIA Ph: 001-773-999999

M. ROHIT YADAV
ID : 998
AGE/SEX : 34/M
RECORDED : 14-8-2023 9:07

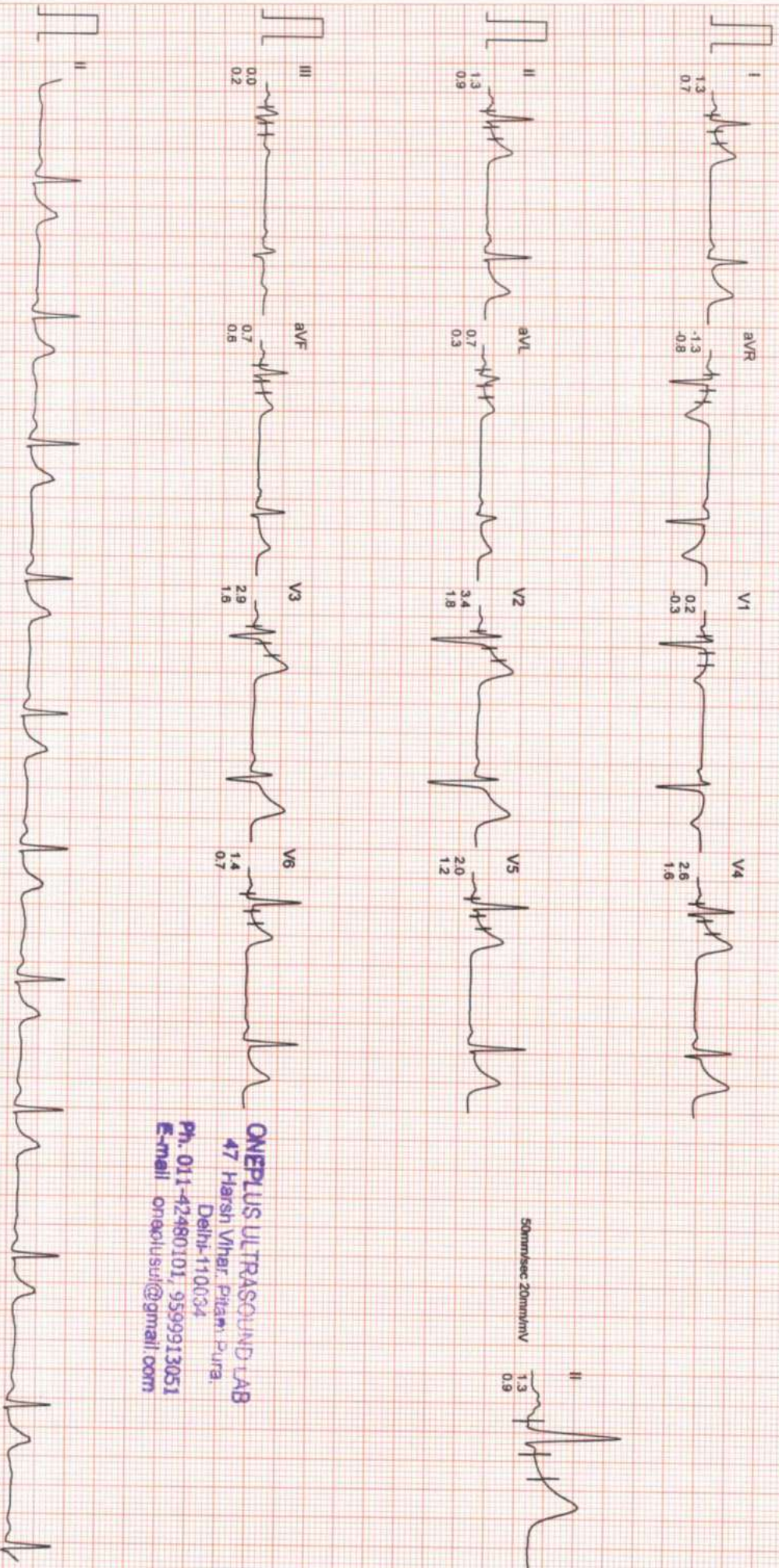
RATE : 65 BPM
B.P. : 114/68 mmHg

ONEPLUS ULTRASOUND LAB

STANDING
PRETEST

ST @ 10mm/mV
80ms PostJ

LINKED MEDIAN



ONEPLUS ULTRASOUND LAB
47 Harsh Vihar, Pitam, Purva,
Delhi-110034
Ph. 011-42480101, 9599913051
E-mail onepplusul@gmail.com

ONEPLUS ULTRASOUND LAB

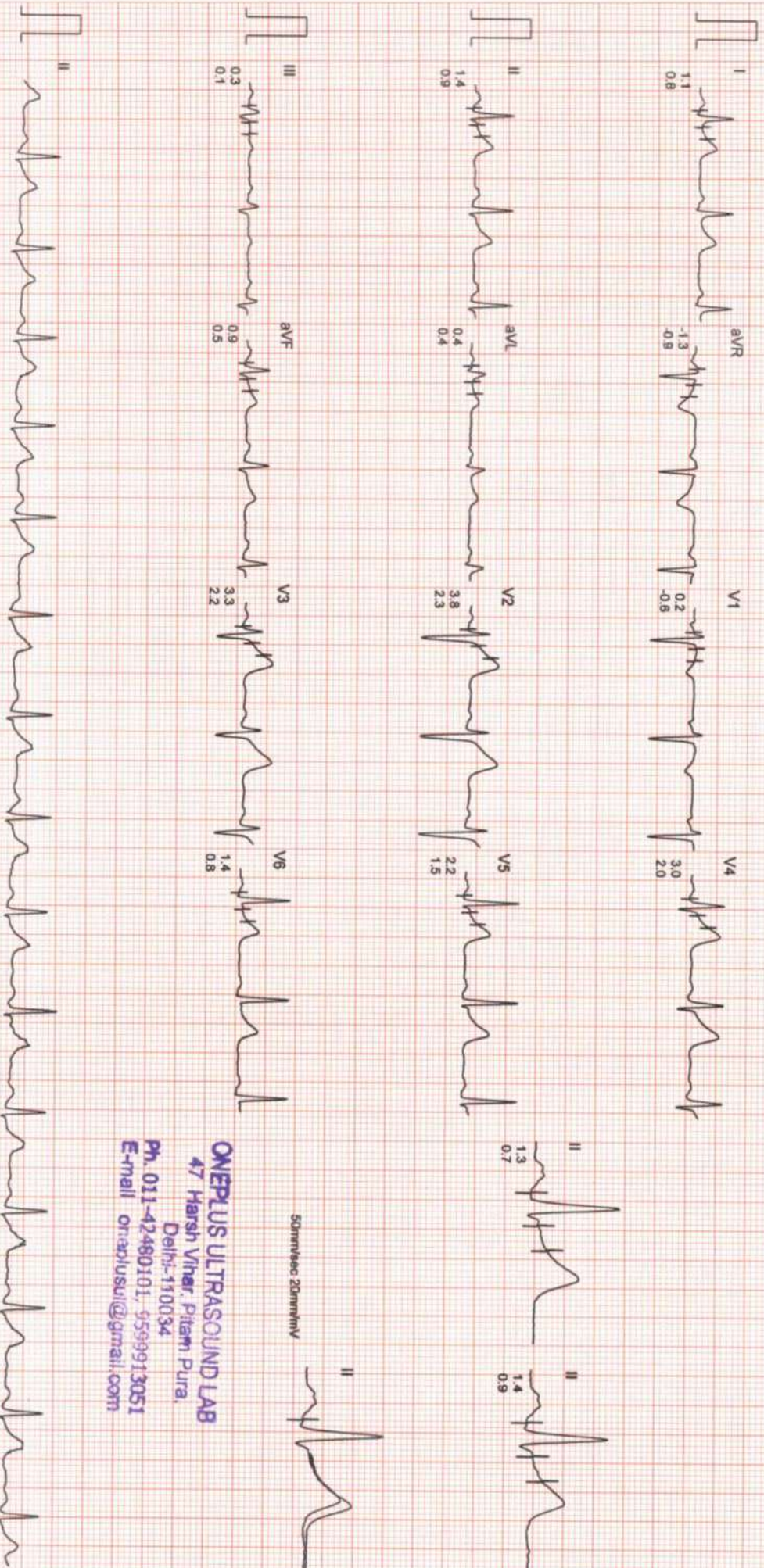
Mr. ROHIT YADAV
I.D. : 998
AGE/SEX : 34/M
RECORDED : 14-8-2023 9:07

RATE : 92 BPM
B.P. : 114/68 mmHg

BRUCE
EXERCISE 1
PHASE TIME : 2:59
STAGE TIME : 2:59

ST @ 10mm/mV
80ms PostJ
SPEED : 2.7 Km./Hr.
GRADE : 10.0 %

LINKED MEDIAN



50mm/sec 20mm/mV

ONEPLUS ULTRASOUND LAB
47 Harsh Vihar, Pitam Pura,
Delhi-110034
Ph. 011-42480101, 9599913051
E-mail onepusul@gmail.com

Entered

Computer Corrected Baseline

25mm/sec 10mm/mV

CardiCom, INDIA Ph: 031-731-2620740, T: 731-2431214

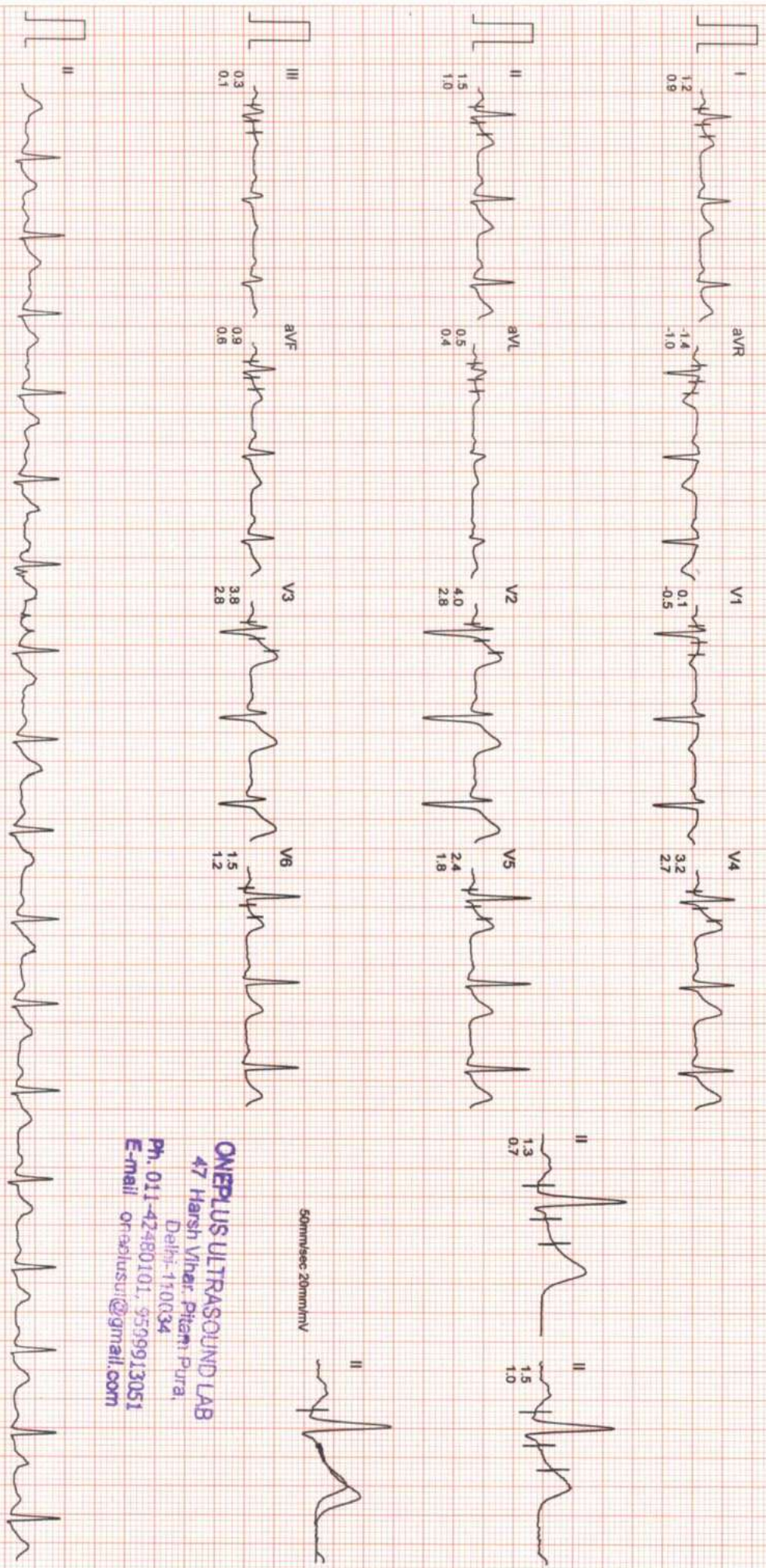
ONEPLUS ULTRASOUND LAB

Mr. ROHIT YADAV
 I.D. : 998
 AGE/SEX : 34/M
 RECORDED : 14-8-2023 9:07

RATE : 104 BPM
 B.P. : 124/70 mmHg

BRUCE
 EXERCISE 2
 PHASE TIME : 5:59
 STAGE TIME : 2:59

ST @ 10mm/mV
 80ms PostJ
 SPEED : 4.0 Km./Hr.
 GRADE : 12.0 %
 LINKED MEDIAN



ONEPLUS ULTRASOUND LAB
 47 Harsh Vihar, Pitam, Pura,
 Delhi-110034
 Ph. 011-47480101, 9599913051
 E-mail: oneplusul@gmail.com

ONEPLUS ULTRASOUND LAB

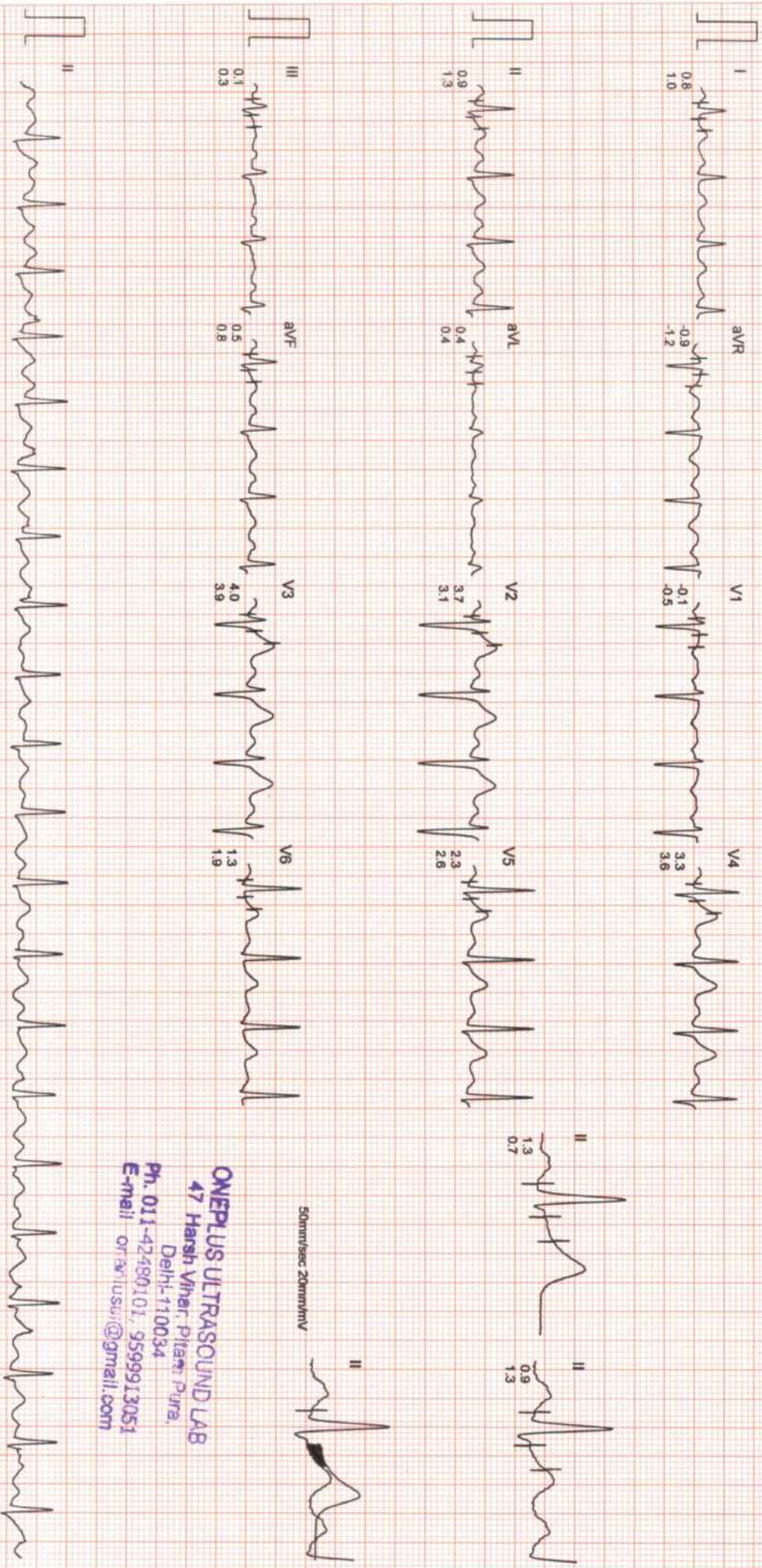
M. ROHIT YADAV
I.D : 998
AGE/SEX : 34/M
RECORDED : 14-8-2023 9:07

RATE : 130 BPM
B.P. : 140/76 mmHg

BRUCE
EXERCISE 3
PHASE TIME : 8:59
STAGE TIME : 2:59

ST @ 10mm/mV
80ms PostJ
SPEED : 5.4 Km./Hr.
GRADE : 14.0 %

LINKED MEDIAN



50mm/sec 20mm/mV

ONEPLUS ULTRASOUND LAB
47 Harsh Vihar, Pitam Pura,
Delhi-110034
Ph. 011-42480101, 9599913051
E-mail: oneplusul@ gmail.com

ONEPLUS ULTRASOUND LAB

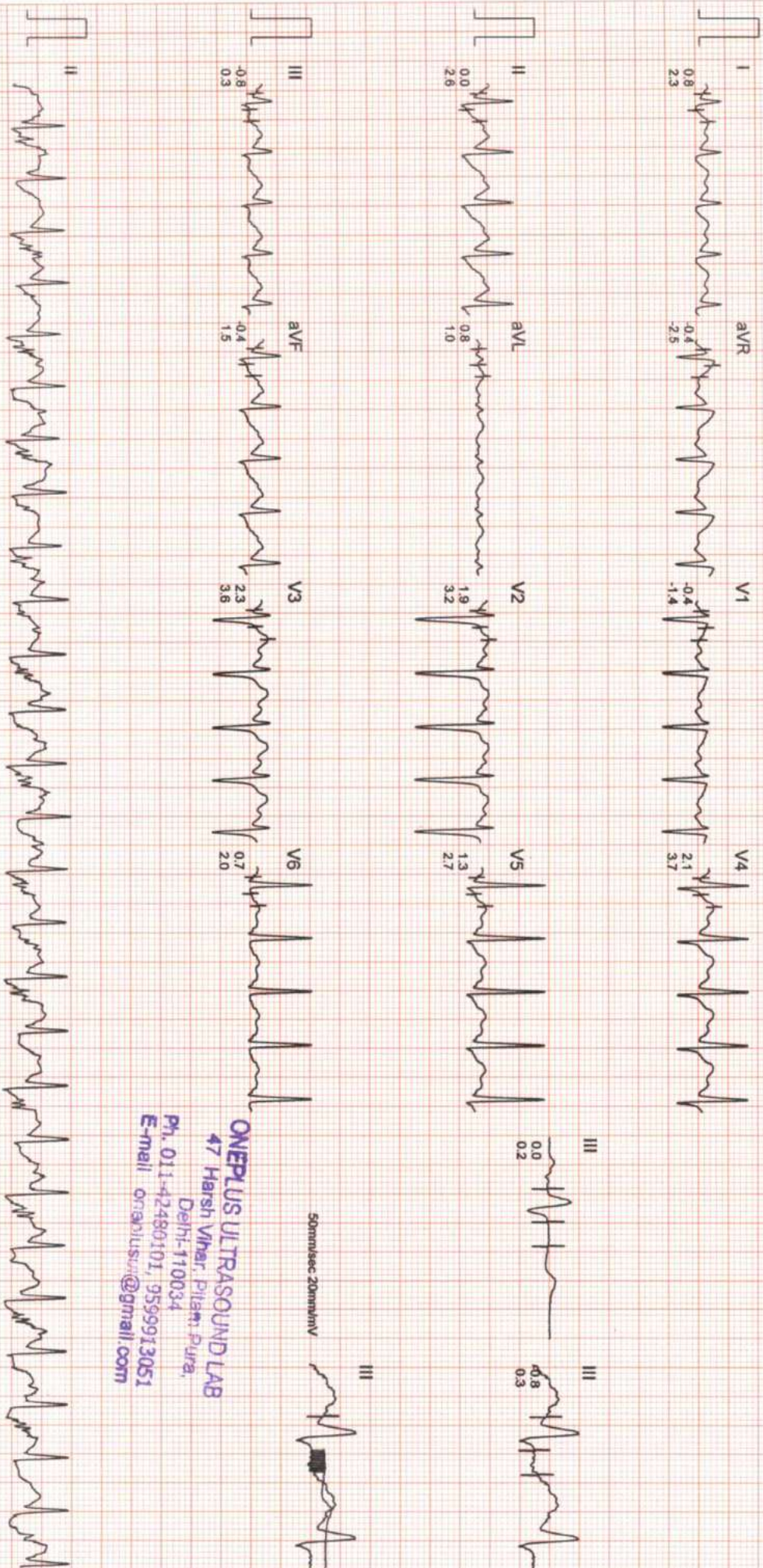
Mr. ROHIT YADAV
ID : 998
AGE/SEX : 34/M
RECORDED : 14-8-2023 9:07

RATE : 171 BPM
B.P. : 150/80 mmHg

BRUCE
EXERCISE 4
PHASE TIME : 9:59
STAGE TIME : 0:59

ST @ 10mm/mV
80ms PostJ
SPEED : 6.7 Km./Hr.
GRADE : 16.0 %

LINKED MEDIAN



ONEPLUS ULTRASOUND LAB
47 Harsh Vihar, Pitam, Pura,
Delhi-110034
Ph. 011-42480101, 9599913051
E-mail onepusul@gmail.com

ONEPLUS ULTRASOUND LAB

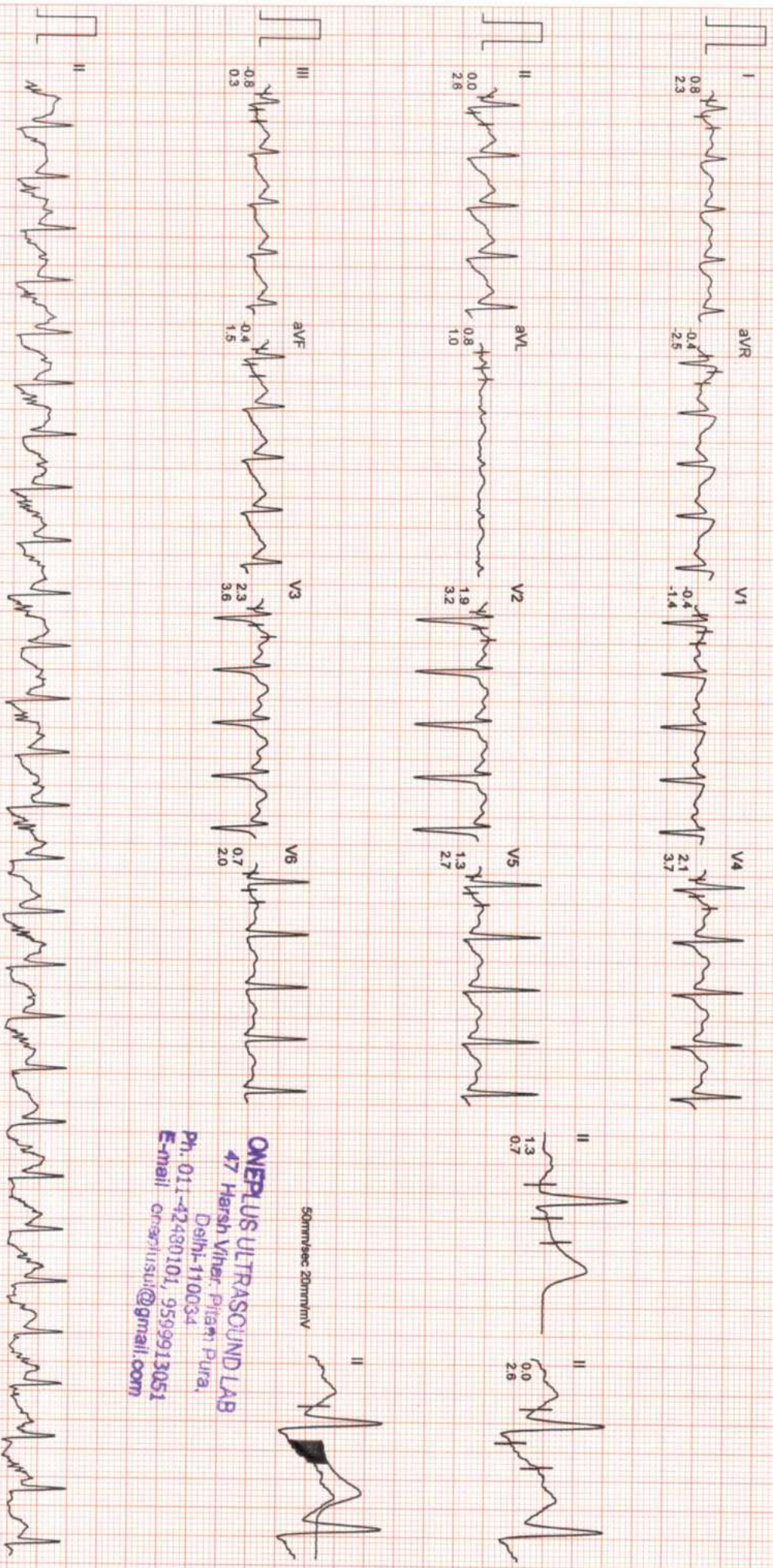
Mr. ROHIT YADAV
 ID : 998
 AGE/SEX : 34/M
 RECORDED : 14-8-2023 9:07

RATE : 173 BPM
 B.P. : 150/80 mmHg

BRUCE
 PEAK EXER
 PHASE TIME : 10:01
 STAGE TIME : 1:01

ST @ 10mm/mV
 80ms PostJ
 SPEED : 6.7 Km./Hr.
 GRADE : 16.0 %

LINKED MEDIAN



50mm/sec 20mm/mV

ONEPLUS ULTRASOUND LAB
 47 Hersh Vihar, Pitam Pura,
 Delhi-110034
 Ph. 011-42480101, 9599913051
 E-mail: onepplus@gmail.com

ONEPLUS ULTRASOUND LAB

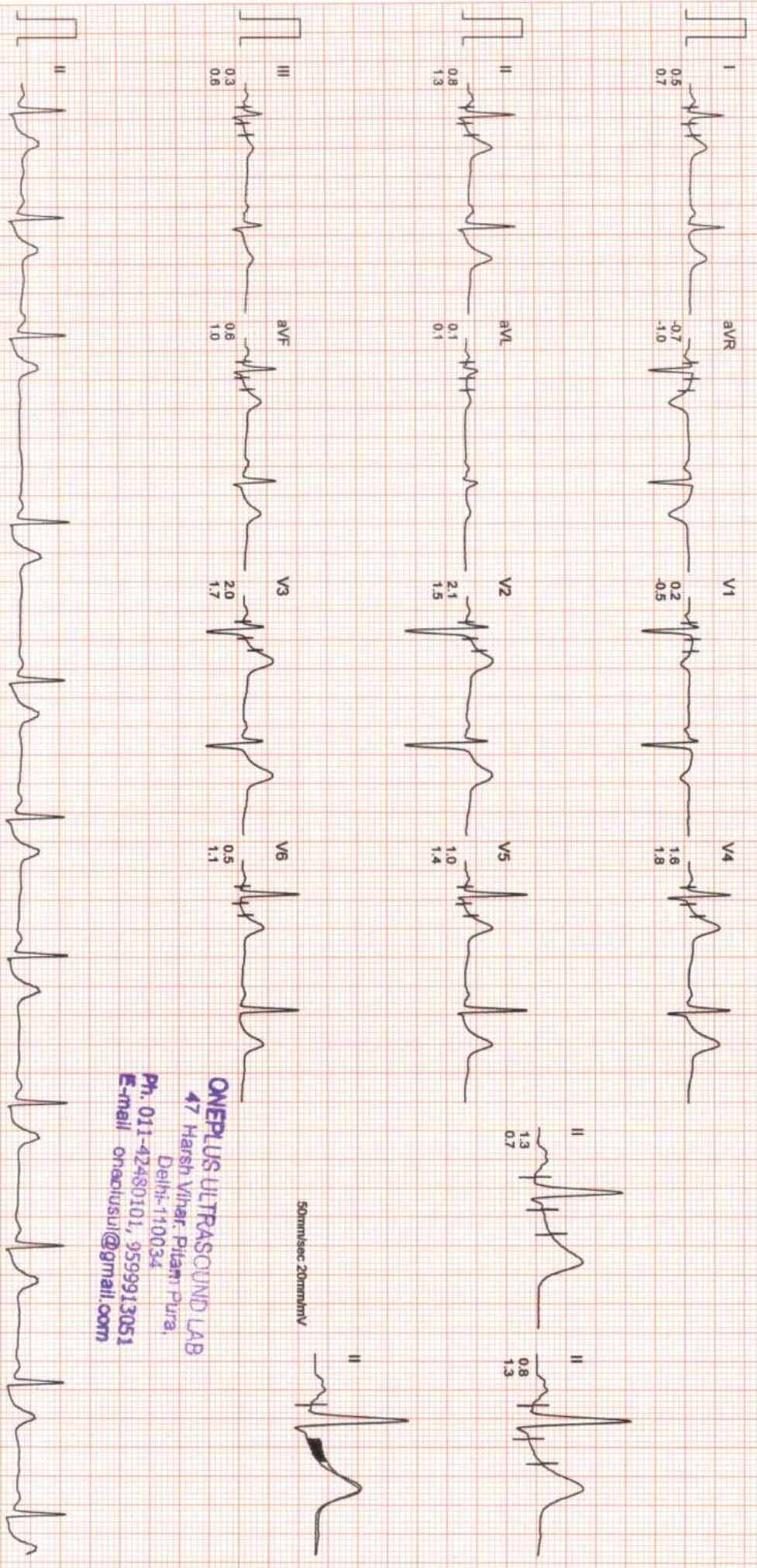
Mr. ROHIT YADAV
I.D. : 998
AGE/SEX : 34/M
RECORDED : 14-8-2023 9:07

RATE : 64 BPM
B.P. : 116/70 mmHg

BRUCE
RECOVERY
PHASE TIME : 2:59

ST @ 10mm/mV
80ms PostJ
SPEED : 0.0 Km/HR.
GRADE : 0.0 %

LINKED MEDIAN



ONEPLUS ULTRASOUND LAB
47 Harsh Vihar, Pitampura,
Delhi-110034
Ph. 011-42480101, 9599913051
E-mail onclusul@gmail.com

50mmsec 20mm/mV





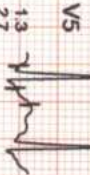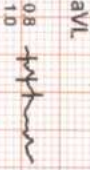





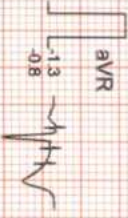

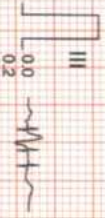




ONEPLUS ULTRASOUND LAB
 47 Harsh Vihar, Pitam Pura,
 Delhi-110034
 Ph. 011-42480101, 9599913051
 E-mail oneplusul@gmail.com

STANDING
0.0kmph
0.0%
65 bpm
B.P. 114/68
80ms PostJ

PEAK EXERCISE
10.01
1.01
6.7kmph
16.0%
173 bpm
B.P. 150/80
80ms PostJ

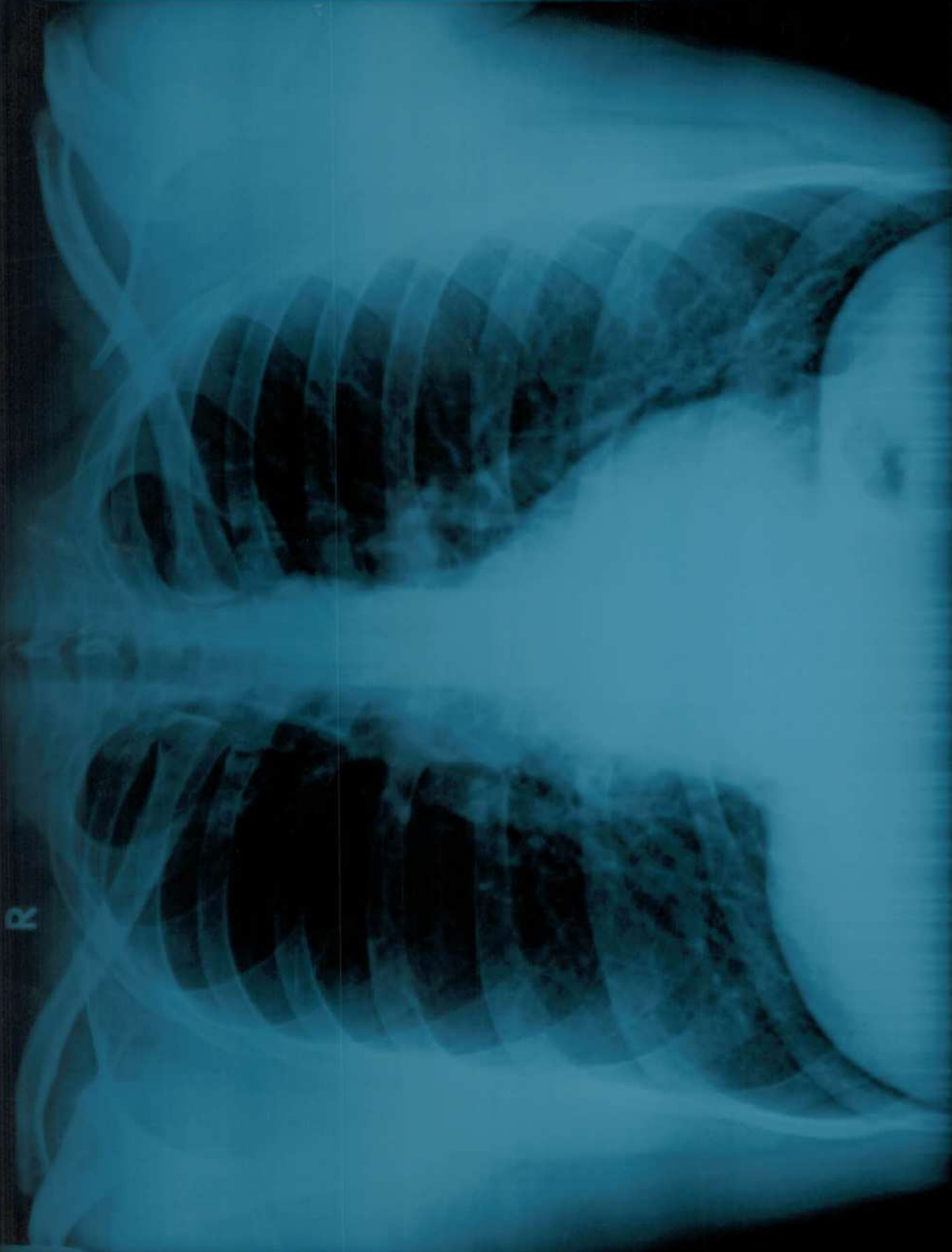
STANDING
0.0kmph
0.0%
65 bpm
B.P. 114/68
80ms PostJ

PEAK EXERCISE
10.01
1.01
6.7kmph
16.0%
173 bpm
B.P. 150/80
80ms PostJ



ONEPLUS ULTRASOUND LAB
47 Harsh Vihar, Pitam Pura,
Delhi-110034
Ph. 011-42460101, 9559913051
E-mail: onepplusul@gmail.com

R



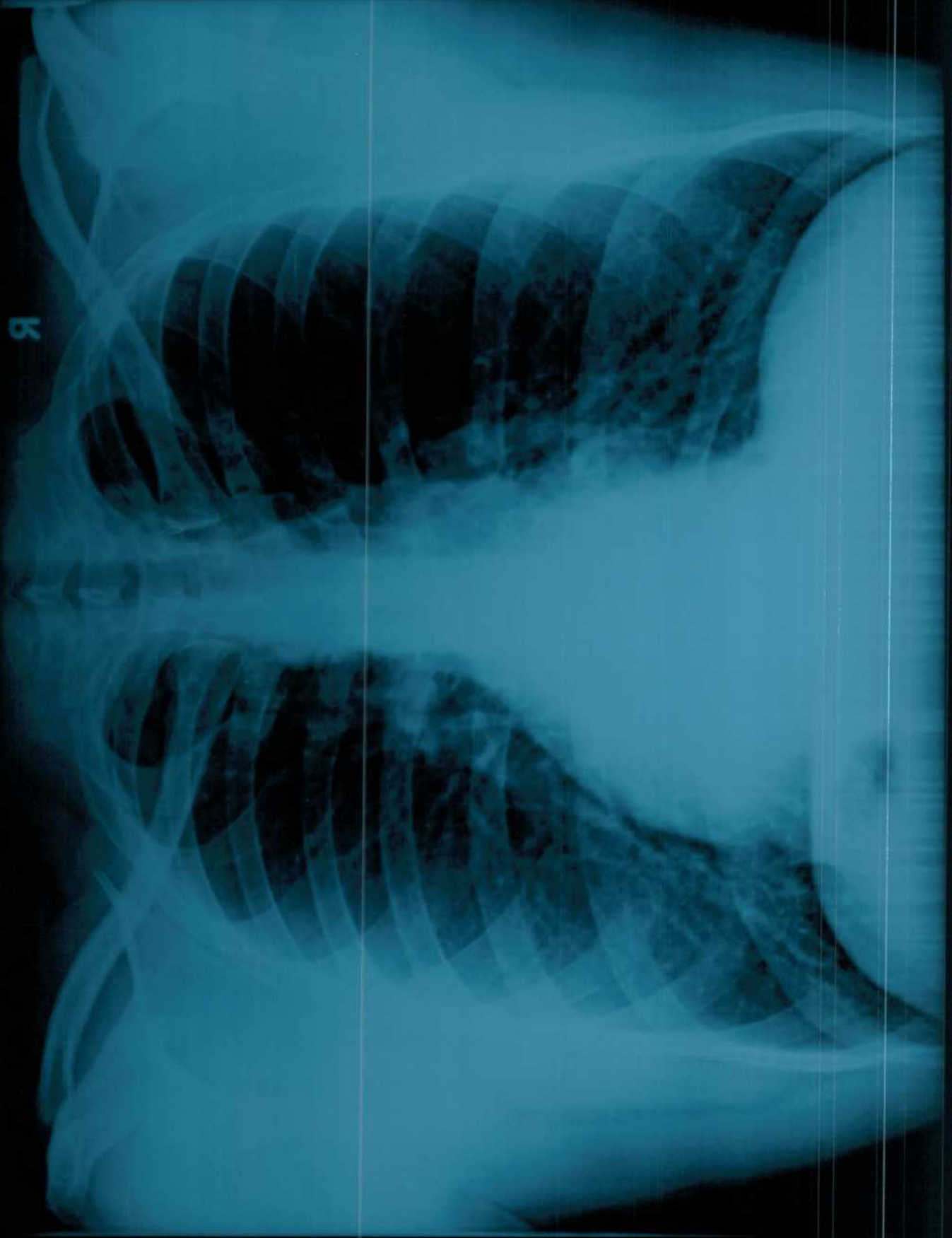
MR ROHIT YADAV AGE 34 YRS 14-08-2023 M CHEST PA VIEW 8/14/2023

CHEPILSILU (PASCHEH) A1632 HOSPITALIYAR CUTAMPORA

DR. P. U. S. M. DE VASCOINDI, MB, B.S., PGDIPRSI, AIHA, IS, PTL, AMBUROVA

MRS. ROHINI YADAV, AGE 34 YRS, 14-08-2023, M, CHEST PA VIEW, 8/14/2023

R





Dr. Nitin Agarwal
Pathologist & Director
MBBS MD (Pathology)
Ex. Sr. Res. MAMC & Lok Nayak Hospital
Ex. Chief of Lab Dr. Lal Path labs.

Dr. Pooja (Garg) Agarwal
Radiologist & Director
MBBS (MAMC) DMRD (MAMC)
Imaging Expert in Fetal And Maternal Medicine,
University of Barcelona, Spain
Fetal Medicine Foundation (UK) Accreditation

Name	: Mr. ROHIT YADAV
Ref. By	: Dr. MEDIWHEEL
Date	: 14-Aug-2023
Age/Sex	: 34 YRS/Male
Lab No	: 012308140003
Patient ID	: LSHH198580

X-ray-Chest PA view

Bony cage and soft tissues are normal.
Cardiothoracic ratio is normal.
Medastinum is normal.
Both hila are normal.
Both costophrenic angles are clear.
Both domes of diaphragm are normal.
Prominent bronchovascular markings are noted in bilateral lung fields.
No parenchymal lesion seen.

Please correlate clinically.

Dr. Pooja GARG
MBBS DMRD
RADIOLOGIST
REG NO-DMC/R/08398

Type By : anshika

47, Harsh Vihar, Pitampura, Delhi-34 ☎ 011-4248 0101, 9599913051
Email: oneplusul@gmail.com 🌐 www.oneplusul.in



Name	: Mr. ROHIT YADAV
Ref. By	: Dr. MEDIWHEEL
Date	: 14-Aug-2023
Age/Sex	: 34 YRS/Male
Lab No	: 012308140003
Patient ID	: LSHH198580

ULTRASOUND EXAMINATION---WHOLE ABDOMEN

Liver is normal in size (13.3 cm) and outline with normal echopattern. No abscess or mass lesion seen. Hepatic veins, portal vein, IVC and aorta are normal. Intrahepatic biliary radicles are not dilated. CBD is normal in caliber.

Gall bladder is well distended with anechoic lumen. Wall thickness is normal.

Both kidneys are normal in size, shape, position, outline and echopattern. Corticomedullary differentiation is maintained. No pelvicalyceal dilation or calculus or mass lesion is seen.

Spleen is normal in size and echotexture. No mass lesion seen.

Pancreas is normal in size, outline and echotexture.

Urinary bladder is normal in shape and position. No evidence of intravesical stone or mass seen.

Prostate is normal in size, shape and echopattern. **Prostate measures 3.5 x 3.1 x 3.0 cm. Weight of prostate is 17.8 grams.**

No abnormal bowel wall thickening seen in right iliac fossa.

No free fluid seen anywhere in abdomen.

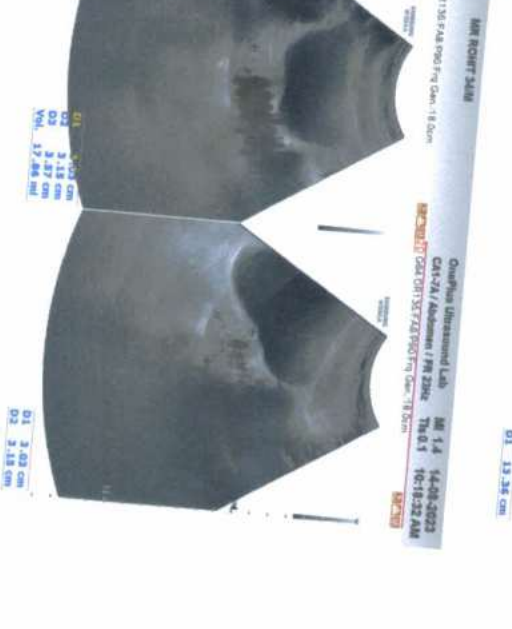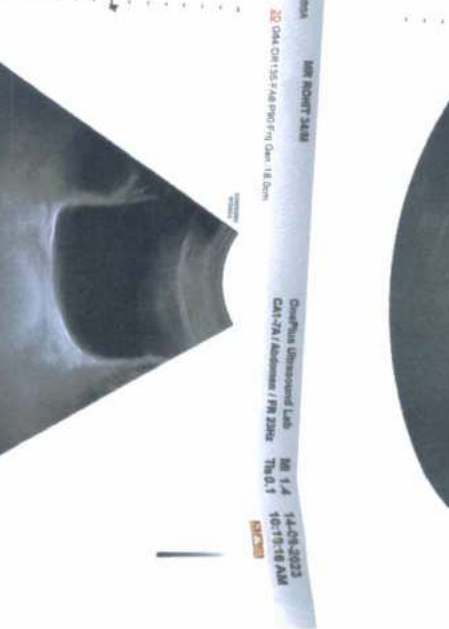
IMPRESSION: Normal Study.


DR. POOJA GARG
RADIOLOGIST
REG NO- DMC/R/03398

Type By : anshika

47, Harsh Vihar, Pitampura, Delhi-34 ☎ 011-4248 0101, 9599913051
Email: oneplusul@gmail.com 🌐 www.oneplusul.in

Ultrasound Image Report





Handwritten label for Sample 1, possibly including a date or location.



Handwritten label for Sample 2, possibly including a date or location.




Handwritten label for Sample 3, possibly including a date or location.



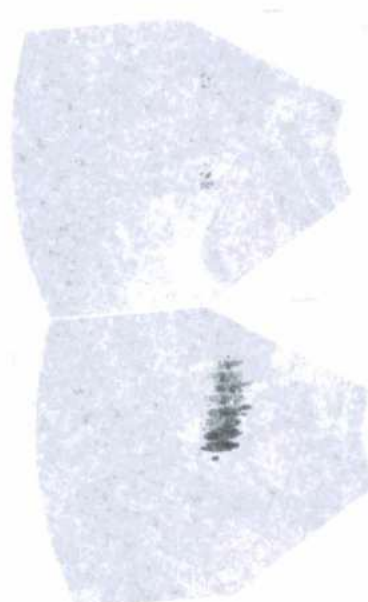Handwritten label for Sample 4, possibly including a date or location.




Handwritten label for Sample 5, possibly including a date or location.



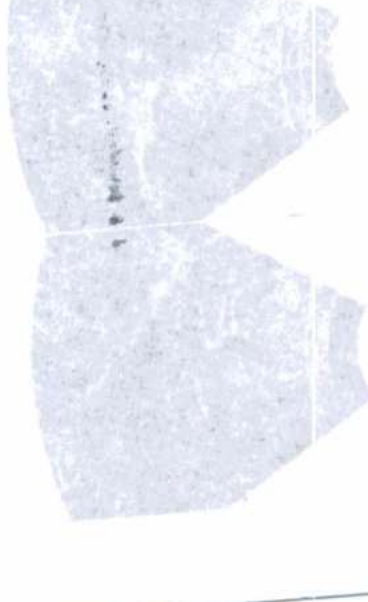Handwritten label for Sample 6, possibly including a date or location.



Handwritten label for Sample 7, possibly including a date or location.



Handwritten label for Sample 8, possibly including a date or location.



Handwritten label for Sample 9, possibly including a date or location.

Vertical handwritten text on the right side of the page, possibly a title or a section header.

Dr. Nitin Agarwal
 Pathologist & Director
 MBBS MD (Pathology)
 Ex. Sr. Res. MAMC& Lok Nayak Hospital
 Ex. Chief of Lab Dr. Lal Path labs.

Dr. Pooja (Garg) Agarwal
 Radiologist & Director
 MBBS (MAMC) DMRD (MAMC)
 Imaging Expert in Fetal And Maternal Medicine,
 University of Barcelona, Spain
 Fetal Medicine Foundation (UK) Accreditation



NAME: **MR. ROHIT YADAV**

AGE/GENDER: **34 YRS/Male**

PATIENT ID: **:98580**

REFERRED BY: **Dr. MEDIWHEEL**

CENTRE NAME: **ONEPLUS ULTRASOUND LAB**

LAB NO.:

REPORT DATE: **:14/Aug/2023 04:03PM**

SPECIMEN RECEIVED: **:14/Aug/2023 08:50AM**

SPECIMEN DATE: **:14/Aug/2023 08:35AM**

Barcode No: **10151418**

Ref. Range: **:012308140003**

Unit:

Result:

Test Name:

HAEMATOLOGY
Medi Wheel Health checkup < 40 Male

Glycosylated Hemoglobin (HbA1c) HPLC
 5.0 %
 Non Diabetic adults <5.7
 Prediabetic (at risk) 5.7-6.4
 Diabetes >6.4

Estimated average blood glucose (eag) CALCULATED
 97

Reference range (mg/dl):

90 - 120:Excellent control, 121 - 150:Good Control, 151 - 180:Average Control, 181 - 210:Action Suggested

>211:Panlc value

BLOOD GROUP (ABO)

Forward and Reverse grouping (Slide & Tube)

O

POSITIVE

NOTE :

* Apart from major A,B,H antigens which are used for ABO grouping and Rh typing, many minor blood group antigens exist. Agglutination may also vary according to titre of antigen and antibody.
 * So before transfusion, reconfirmation of blood group as well as cross-matching is needed.
 * Presence of maternal antibodies in newborns, may interfere with blood grouping.
 * Auto agglutination (due to cold antibody, falciparum malaria, sepsis, internal malignancy etc.) may also cause erroneous result.

Checked By.

DR. NITIN AGARWAL
 MBBS,MD(PATHOLOGIST)

DR. NITIN AGARWAL
 MBBS, MD
 Regn. No. DMC-R-1436

Page 1 of 7

47, Harsh Vihar, Pitampura, Delhi-34 ☎ 011-4248 0101, 9599913051
 Email: oneplusul@gmail.com 🌐 www.oneplusul.in

* All disputes are subject to Delhi jurisdiction only. * Not for medico legal case. * All congenital anomalies in a foetus may not be diagnosed in routine obstetric ultrasound. * Clinical correlation is essential for final diagnosis. * If test results are unsatisfactory please contact personally or on phone. * This report is for perusal of doctors only.



Dr. Nitin Agarwal
 Pathologist & Director
 MBBS MD (Pathology)
 Ex. Sr. Res. MAMC& Lok Nayak Hospital
 Ex. Chief of Lab Dr. Lal Path labs.

Dr. Pooja (Garg) Agarwal
 Radiologist & Director
 MBBS (MAMC) DMRD (MAMC)
 Imaging Expert in Fetal And Maternal Medicine,
 University of Barcelona, Spain
 Fetal Medicine Foundation (UK) Accreditation



NAME: MR. ROHIT YADAV	AGE/GENDER: 34 YRS/Male	PATIENT ID: 98580	REFERRED BY: Dr. MEDIWHEEL	CENTRE NAME: ONEPLUS ULTRASOUND LAB
LAB NO.	REPORT DATE	SPECIMEN RECEIVED	SPECIMEN DATE	Barcode No
:012308140003	:14/Aug/2023 12:58PM	:14/Aug/2023 08:50AM	:14/Aug/2023 08:35AM	:10151418

HAEMATOLOGY

CBC

Test Name	Result	Unit	Ref. Range
Haemoglobin	13.8	g/dl	13.0-17.0
Total Leucocyte Count	5900	/cumm	4000-10000
Differential leucocyte count			
Neutrophils	53	%	40-80
Lymphocyte	39.70	%	20-40
Monocytes	5.00	%	2-10
Eosinophils	2.0	%	1-6
Basophils	0.3	%	0-2
RBC Count	4.90	million/cumm	4.5 - 5.5
Hematocrit(PCV)	44.4	%	40-50
MCV	91.2	fl	83-101
MCH	28.4	pg	27-32
MCHC	31.2	g/dL	31.5-34.5
RDW-CV	14.2	%	11.4-14.0
Platelet count	161000	/cumm	150000-410000

Checked By.

DR. NITIN AGARWAL
 MBBS, MD (PATHOLOGIST)
 MBBS, MD (MAMC)
 MBBS, MD (MAMC)
 Page 2 of 2

47, Harsh Vihar, Pitampura, Delhi-34 ☎ 011-4248 0101, 9599913051
 Email: oneplusul@gmail.com www.oneplusul.in

* Clinical correlation is essential for final diagnosis. * If test results are unsatisfactory please contact personally or on phone. * This report is for perusal of doctors only. * All disputes are subject to Delhi jurisdiction only. * Not for medico legal case. * All congenital anomalies in a foetus may not be diagnosed in routine obstetric ultrasound.

Email: oneplusul@gmail.com | www.oneplusul.in

47, Harsh Vihar, Pitampura, Delhi-34 | 011-4248 0101, 9599913051

DR. NITIN AGARWAL
MBBS, MD
Page 3 of 7
Regn. No. DMC-R-1436

DR. NITIN AGARWAL
MBBS, MD (PATHOLOGIST)



Checked By.

LIPID PROFILE

Test Name	Result	Unit	Ref. Range
Bilirubin Total	0.54	mg/dl	0.1-1.2
Bilirubin Conjugated	0.23	mg/dl	0-0.4
Bilirubin Unconjugated	0.31	mg/dl	up to 0.7
SGOT (AST)	31	U/L	0-46
SGPT (ALT)	37	U/L	0-49
Alkaline phosphatase	96	U/L	40-129
GAMMA GT	24	U/L	10-45
Total Protein	6.9	gm/dl	6.60 - 8.70
Albumin serum	3.9	g/dL	3.0-5.2
Globulin	3.00	gm/dl	1.8-3.4
Albumin/Globulin Ratio	1.30		1.10 - 2.50

LFT (LIVER FUNCTION TEST)

Test Name	Result	Unit	Ref. Range
Blood sugar fasting	86	mg/dl	70-100 mg/dl
Blood sugar pp	87	mg/dL	70.0-140.0
Bun (blood urea nitrogen)	11.68	mg/dl	8.9-21.6
Uric acid, serum	4.6	mg/dl	3.5-7.2
Creatinine, serum	0.6	mg/dl	0.60-1.2

BIOCHEMISTRY

Test Name	Result	Unit	Ref. Range
Blood sugar fasting	86	mg/dl	70-100 mg/dl
Blood sugar pp	87	mg/dL	70.0-140.0
Bun (blood urea nitrogen)	11.68	mg/dl	8.9-21.6
Uric acid, serum	4.6	mg/dl	3.5-7.2
Creatinine, serum	0.6	mg/dl	0.60-1.2

NAME: **MR. ROHIT YADAV** | AGE/GENDER: 34 YRS/Male | PATIENT ID: 98580 | REFERRED BY: DR. MEDIWHEEL | CENTRE NAME: ONEPLUS ULTRASOUND LAB

LAB NO.: | REPORT DATE: 14/Aug/2023 04:03PM | SPECIMEN RECEIVED: 14/Aug/2023 08:50AM | SPECIMEN DATE: 14/Aug/2023 08:35AM | Barcode No: 10151418

Dr. Nitin Agarwal | Pathologist & Director | MBBS MD (Pathology) | Ex. Sr. Res. MAMC& Lok Nayak Hospital | Ex. Chief of Lab Dr. Lal Path labs.

Dr. Pooja (Garg) Agarwal | Radiologist & Director | MBBS (MAMC) DMRD (MAMC) | Imaging Expert in Fetal And Maternal Medicine, University of Barcelona, Spain | Fetal Medicine Foundation (UK) Accreditation





Dr. Nitin Agarwal
 Pathologist & Director
 MBBS MD (Pathology)
 Ex. Sr. Res. MAMC& Lok Nayak Hospital
 Ex. Chief of Lab Dr. Lal Path labs.

Dr. Pooja (Garg) Agarwal
 Radiologist & Director
 MBBS (MAMC) DMRD (MAMC)
 Imaging Expert in Fetal And Maternal Medicine,
 University of Barcelona, Spain
 Fetal Medicine Foundation (UK) Accreditation



NAME FIRST... LAST... ALWASI, **DR. ROHIT YADAV**

Barcode No	:10151418
SPECIMEN DATE	:14/Aug/2023 08:35AM
SPECIMEN RECEIVED	:14/Aug/2023 08:50AM
REPORT DATE	:14/Aug/2023 04:03PM
LAB NO.	:012308140003
AGE/GENDER	:34 YRS/Male
PATIENT ID	:98580
REFERRED BY	:DR. MEDIWHEEL
CENTRE NAME	:ONEPLUS ULTRASOUND LAB

Test Name	Result	Unit	Ref. Range
Cholesterol	190	mg/dl	50-200
Triglycerides	90	mg/dL	25-150
HDL Cholesterol	45	mg/dL	40 - 60
LDL cholesterol	127	mg/dL	<100
VLDL cholesterol	18.0	mg/dL	5-40
Cholesterol/HDL Ratio	4.2	Calculated	Low Risk 3.3-4.97 Average Risk 4.4-7.1 Moderate Risk 7.1-11.0 High Risk >11.0
LDL/HDL Ratio	2.8	Calculated	0 - 3.55

According to ATP III and NCEP guidelines

Parameter	Normal	Desirable	Borderline	High
Total cholesterol	<200	200-239	240	
Triglycerides	<150	150-199	200-499	500
LDL	Optimal <100	130-159	160-180	190
HDL	Near Optimal 100-129	>40 : LOW 60 : HIGH		

BUN/Creatinine ratio

Parameter	Result	Unit	Ref. Range
UREA	25.00	mg/dl	15-45
Bun (blood urea nitrogen)	11.68	mg/dl	8.9-21.6
CREATININE	0.60	mg/dl	0.30-1.10

Checked By:

DR. NITIN AGARWAL
 MBBS,MD(PATHOLOGIST)
 REGISTR. NO. DMC-R-1436

47, Harsh Vihar, Pitampura, Delhi-34 ☎ 011-4248 0101, 9599913051

Email: onepplus@gmail.com 📧 www.oneplusul.in


• Clinical correlation is essential for final diagnosis. • If test results are unsatisfactory please contact personally or on phone. • This report is for perusal of doctors only. • All disputes are subject to Delhi jurisdiction only. • Not for medico legal case. • All congenital anomalies in a foetus may not be diagnosed in routine obstetric ultrasound.

Email: oneplusul@gmail.com | www.oneplusul.in

47, Harsh Vihar, Pitampura, Delhi-34 | 011-4248 0101, 9599913051

Page 5 of 7

DR. NITIN AGARWAL
MBBS, MD (PATHOLOGIST)
Regn. No. DMC-R-1436



Checked By.

Sp. gravity	1.020	1.005-1.030
Transparency	CLEAR	CLEAR
Colour	PALE YELLOW	PALE YELLOW

Physical examination

URINE ROUTINE (Strip/microscopy)

CLINICAL PATHOLOGY

1. Primary hypothyroidism is accompanied by depressed serum T3 and T4 values and elevated serum TSH level.
2. Primary hyperthyroidism is accompanied by elevated serum T3 and T4 levels along with depressed TSH values.
3. Slightly elevated T3 levels may be found in pregnancy and estrogen therapy, while depressed levels may be encountered in severe illness, renal failure and during therapy with drugs like propranolol and propylthiouracil.
4. Although elevated TSH levels are nearly always indicative of primary hypothyroidism, and may be seen in secondary thyrotoxicosis.

Reference ranges - Interpretation of Diagnostic tests - (Jacques Wallach)

AGE	TSH (µIU/ml)	AGE	TSH (µIU/ml)
1-4 weeks	1.00 - 19.0	16-20 yrs	0.25 - 5.0
1-12 mths	1.70 - 9.1	21 - 80 yrs	0.25 - 5.0
1-5 yrs	0.80 - 8.2	1 st trimester	0.25 - 5.0
6-10 yrs	0.25 - 5.0	II nd trimester	0.50 - 5.0
11-15 yrs	0.25 - 5.0	II rd trimester	0.4 - 6.0

AGE WISE VARIATION IN TSH

Test Name	Result	Unit	Ref. Range
TSH (Thyroid Stimulating Hormone) <small>Enzyme linked fluorescent assay</small>	3.80	µIU/ml	0.25-5.0
Thyroxine total [T4] <small>ECLIA</small>	7.60	µg/dl	4.4 - 10.8
Tritodothyronine total [T3] <small>ECLIA</small>	0.86	ng/dl	0.52-1.9

THYROID PROFILE (T3, T4, TSH)

ENDOCRINOLOGY

Test Name	Result	Unit	Ref. Range
BUN/Creatinine ratio <small>CALCULATED</small>	19.47		10.0 - 20.0

NAME: MR. ROHIT YADAV	AGE/GENDER: 34 YRS/Male	PATIENT ID: 98580	REFERRED BY: DR. MEDIWHEEL
LAB NO.:	REPORT DATE:	SPECIMEN RECEIVED:	SPECIMEN DATE:
Barcode No: 10151418	14/Aug/2023 08:35AM	14/Aug/2023 08:50AM	14/Aug/2023 04:03PM
CENTRE NAME: ONEPLUS ULTRASOUND LAB		LAB NO.: 012308140003	



OnePLUS
Ultrasound Lab



Dr. Nitin Agarwal
Pathologist & Director
MBBS MD (Pathology)
Ex. Sr. Res. MAMC& Lok Nayak Hospital
Ex. Chief of Lab Dr. Lal Path labs.

Dr. Pooja (Garg) Agarwal
Radiologist & Director
MBBS (MAMC) DMRD (MAMC)
Imaging Expert in Fetal And Maternal Medicine,
University of Barcelona, Spain
Fetal Medicine Foundation (UK) Accreditation

Email: onepiusul@gmail.com | www.onepiusul.in

47, Harsh Vihar, Pitampura, Delhi-34 | 011-4248 0101, 9599913051

Checked By.

DR. NITIN AGARWAL
MBBS, MD
Regn. No. DMC-R-1436

DR. NITIN AGARWAL
MBBS, MD (PATHOLOGY)



Page 6 of 7

Physical examination
 Colour BROWNISH
 Consistency SEMI LOOSE
 Blood ABSENT
 Mucus ABSENT
 Chemical examination, stool Absent

STOOL ROUTINE(MANUAL METHOD/MICROSCOPY)

Test Name	Result	Unit	Ref. Range
Pus cells, Microscopy	1-2	/HPF	0-2
Epithelial cells, Microscopy	1-2	/HPF	NIL
R.B.C., Microscopy	NIL	/HPF	NIL
Crystals, Microscopy	NIL	/HPF	NIL
Bacteria, Microscopy	NIL	/HPF	NIL
Others, Microscopy	NIL	/HPF	NIL

Microscopic examination
 Urine protein Ionization NIL
 Urine sugar Oxidation Reaction NIL
 Bilirubin, urine NEGATIVE
 Urobilinogen P-Aminobenzoic Acid and Phenazopyridine Reaction NORMAL
 Ketones Acetoacetate and Dichlorobenzene Reaction NEGATIVE

Chemical examination
 pH Double Indicators Test 6.00
 Reaction ACIDIC
 Ref. Range 5.0-8.0

NAME: **MR. ROHIT YADAV**
 AGE/GENDER: 34 YRS/Male
 PATIENT ID: 98580
 REFERRED BY: Dr. MEDIWHEEL
 CENTRE NAME: ONEPLUS ULTRASOUND LAB
 REPORT DATE: 14/Aug/2023 04:03PM
 LAB NO.: 012308140003
 SPECIMEN RECEIVED: 14/Aug/2023 08:50AM
 SPECIMEN DATE: 14/Aug/2023 08:35AM
 Barcode No: 10151418



OnePLUS
 Ultrasound Lab



Dr. Nitin Agarwal
 Pathologist & Director
 MBBS MD (Pathology)
 Ex. Sr. Res. MAMC& Lok Nayak Hospital
 Ex. Chief of Lab Dr. Lal Path labs.

Dr. Pooja (Garg) Agarwal
 Radiologist & Director
 MBBS (MAMC) DMRD (MAMC)
 Imaging Expert in Fetal And Maternal Medicine,
 University of Barcelona, Spain
 Fetal Medicine Foundation (UK) Accreditation

Clinical correlation is essential for final diagnosis. • If test results are unsatisfactory please contact personally or on phone. • This report is for perusal of doctors only. • All disputes are subject to Delhi jurisdiction only. • Not for medico legal case. • All congenital anomalies in a foetus may not be diagnosed in routine obstetric ultrasound.

47, Harsh Vihar, Pitampura, Delhi-34 ☎ 011-4248 0101, 9599913051
 Email: oneplusul@gmail.com 🌐 www.oneplusul.in

Page 7 of 7

Checked By.

DR. NITIN AGARWAL
 MBBS, MD (PATHOLOGY)
 MBBS, MD
 Regn. No. DMCA-1436

[Handwritten Signature]

*** End Of Report ***

Test Name	Result	Unit	Ref. Range
pH	6.00		5.0-8.0
Double Indicators Test			
Microscopic examination			
Pus cells	0-1	/HPF	
R.B.C.	NIL	/HPF	
Microscopy			
Ova	NIL	/HPF	
Microscopy			
Cysts	NIL		
Microscopy			
Bacteria	NIL		
Microscopy			
Others	PRESENT	/HPF	
Microscopy			

NAME FIRST... ALWAYS: **MR. ROHIT YADAV**
 AGE/GENDER: 34 YRS/Male
 PATIENT ID: 98580
 REFERRED BY: DR. MEDIWHEEL
 CENTRE NAME: ONEPLUS ULTRASOUND LAB

Barcode No
 SPECIMEN DATE
 SPECIMEN RECEIVED
 REPORT DATE
 LAB NO.

10151418
 14/Aug/2023 08:35AM
 14/Aug/2023 08:50AM
 14/Aug/2023 04:03PM
 012308140003



Dr. Nitin Agarwal
 Pathologist & Director
 MBBS MD (Pathology)
 Ex. Sr. Res. MAMC& Lok Nayak Hospital
 Ex. Chief of Lab Dr. Lal Path Labs.

Imaging Expert in Fetal And Maternal
 Fetal Medicine Foundation (UK) Accredited
 University of Barcelona
 MBBS (MAMC)



16