

DAKSH HOSPITAL

396 - 397, Gandhi Nagar, Scheme No. 8, ALWAR -301001

Ref. No.

Date.....


MEDICAL EXAMINATION REPORT

Mediwheel (BOB)

Name: Mrs. Sonika Gupta Age: 32yrs Sex: Female Date: 28/09/2024

General Physical Examination

Height	: 158cm	Weight	: 58 Kg
Pulse	: 93 /mt	BP	: 120/70 mm/hg
Respiration	: 18/mt	BMI	: 23.2 kg/m ²

Systemic Exam:- NORMALDental Check up :- NORMALEye check-up :- NORMALSkin Check up:- NORMALENT Check up:- NORMALGynae Check up:- 2-3 PM on - Pich & Paps smear refused
28-30 LD-1kgImpression:- Increase in serum cholesterol & triglycerideRecommendation:- Life style modification

 Dr. Mukesh Kumar Gupta
 MD Gen. Medicine
 Reg. No 5423/16262

 डॉ० मुकेश गुप्ता
 M.D.F.C.C.S.
 फिजिशियन एवं प्रमुख रोग विशेषज्ञ
 दक्ष हॉस्पिटल, अलवर
 रजि० नं०-5423/16262

Results

Run Date 28/09/2024 12:59:52 PM

Operator DAKSH

Last Name

Sample ID 24

First Name MRS.SONIKA GUPTA

Department

Gender Female Age

Physician DR. MUKESH GUPTA M.D

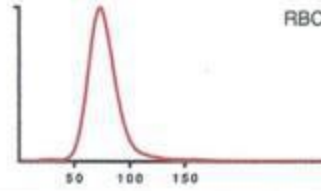
Patient ID AUTO_PID25051

Type Woman

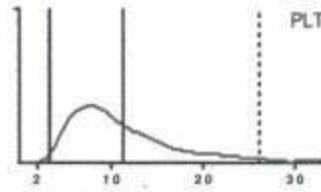
Date of birth

Sample comments

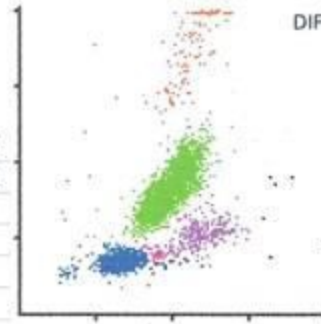
			Range
RBC	4.26	10 ⁹ /μL	3.80 - 5.50
HGB	11.2	g/dL	11.5 - 15.2
HCT	32.5	%	35.0 - 46.0
MCV	76.3	μm ³	77.0 - 97.0
MCH	26.2	pg	26.0 - 34.0
MCHC	34.4	g/dL	32.0 - 35.0
RDW-CV	15.6	%	11.0 - 17.0
RDW-SD	47.9	μm ³	37.0 - 49.0



			Range
PLT	210	10 ³ /μL	150 - 450
PCT	0.22	%	0.15 - 0.40
MPV	10.4	μm ³	8.0 - 11.0
PDW	16.5	μm ³	11.0 - 22.0
P-LCC	73	10 ³ /μL	44 - 140
P-LCR	35.0	%	18.0 - 50.0



			Range
WBC	6.08	10 ³ /μL	3.50 - 10.00
	#	Range	%
NEU	3.74	1.60 - 7.00	61.6
LYM	1.96	1.00 - 3.00	32.3
MON	0.11	0.20 - 0.80	1.8
EOS	0.19	0.00 - 0.50	3.1
BAS	0.07	0.00 - 0.15	1.2 h
LIC	0.01	0.00 - 0.10	0.2



Dr. R.S. Gupta
Dr. R.S. GUPTA
 MD (Pathology) (MAHE)
 RMC No. 7924/19778

Dr. Mukesh Gupta
TECHNOLOGIST

Date :- 28/09/2024

Name :- MRS. SONIKA GUPTA

Age & Sex :- 32Yrs/ Female

Refd. :- Dr Mukesh Gupta M.D.

	TEST NAME	RESULT	REFERENCE RANGE	
	ESR	10	00 -20 mm/hrs	
	Blood Group & Rh Factor	O ⁺ POSITIVE		
	HbA1C	4.9	4 - 5.6%	
	Blood Sugar (R)	104.5	< 150 mg/dl	
	Blood Sugar (PP)	-	< 140 mg/dl	
	Urine Sugar (F)	NIL	-	
	Urine Sugar (PP)	-	-	
LIVER	S.Bilirubin Total	0.90	0.30 - 1.20 mg/dl	
	S.Bilirubin Direct	0.20	0.10 - 0.30 mg/dl	
	S.Bilirubin Indirect	0.70	0.30 - 0.90 mg/dl	
	S.G.O.T.	27	> 37 u/l	
	S.G.P.T.	39	> 40 u/l	
	S.Alk. Phosp.	189	80 - 306 u/l	
	G.G.T.	28	5 -40 u/l	
	Total Protein	6.9	6.5 - 8.5 gm/dl	
	Albumin	3.8	3.8 - 5.4 gm/dl	
	Globulin	3.1	2.3 - 3.5 gm/dl	
	A/G Ratio	1.2	-	
	AST/ALT Ratio	0.6	-	
KIDNEY	Blood Urea	35.4	15 -45 mg/dl	
	S.Creatinine	1.2	0.60 - 1.30 mg/dl	
	BUN	23.6	6 -24 mg/dl	
	S.Uric Acid	5.2	M 3.1 - 7.0, F 2.5 - 5.6 mg/dl	
	BUN/Creatinine Ratio	19.1	-	
LIPID PROFILE	Total Cholesterol	245.1	Up to 200 mg/dl	
	S HDL	45.1	30 - 70 mg/dl	
	S.LDL	161.1	Up to 170 mg/dl	
	S.VLDL	39.1	5.0 - 40 mg/dl	
	S. Triglycerides	195.1	Up to 170 mg/dl	
	LDL/HDL Ratio	3.5	-	
	Total Cholesterol/ HDL Ratio	5.4	-	
THYROID	T3	102.7	40 - 181 ng/dl	
	T4	7.8	4.6 - 10.5 µg/dl	
	TSH	3.57	0.30 - 5.0 mIU/l	
	URINE EXAMINATION		Microscopic Examination:	
General/Chemical Examination:	Colour	Pale Yellow	RBC	Absent
	Reaction	Acidic	WBC	2 - 3
	Specific Gravity	QNS	Epithelial Cells	1 - 2
	Appearance	Clear	Cast	Absent
	Albumin	TRACE	Crystal	Absent
	Sugar	Nil	Spermatozoa	Absent
			Amorphous Sediments	Absent
			Other	Absent
X-RAY CHEST	NORMAL STUDY			
	STOOL EXAMINATION		Microscopic Examination:	
			RBC	

Dr. R.S. GUPTA
MD (Pathology) (M.D.)
RMC No. 1924/19773

TECHNOLOGIST

All investigation have their own limitations regarding the sensitivity & specificity of individual assay procedures, Isolated laboratory investigations never confirm the final diagnosis of the disease. They only help in arriving at a diagnosis in conjunction with clinical presentation and other related investigations. Report is not valid for medico-legal purpose subject to ALWAR jurisdiction only.

Date :- 28/09/2024

Name :- Mrs. Sonika Gupta

Refd. :- Dr Mukesh Gupta MD

Age & Sex :- 32Yrs/ Female

CYTO-PATHOLOGY

PAP SMEAR

1. Specimen type	Received two conventional smears.
2. Specimen adequacy	Smears are satisfactory for evaluation.
3. Microscopic finding	Smears are moderately cellular comprises of predominantly intermediate with mature superficial squamous epithelial cells arranged in clusters & scattered singly.
4. Inflammation	Not seen
5. Bacilli	Not seen
6. Endocervical cells	Not seen
7. Koilocytic changes	Not seen
8. Trichomonas	Not seen
9. Dysplasia	Nil
10. Neoplasia	Nil
11. Endometrial cells	Nil

Impression:- Negative for intraepithelial lesion or malignancy


Dr. R.S. GUPTA
MD (Pathology) (MAHE)
RMC No. 7924/19778


TECHNOLOGIST

All investigation have their own limitations regarding the sensitivity & specificity of individual assay procedures, Isolated laboratory investigations never confirm the final diagnosis of the disease. They only help in arriving at a diagnosis in conjunction with clinical presentation and other related investigations. Report is not valid for medico-legal purpose subject to ALWAR jurisdiction only.



दक्ष हॉस्पिटल

396, गाँधी नगर स्कीम नं.8, अलवर (राज०) ☎ 0144-2703340

Sonography / 2D Echo Cardiography / Doppler Report

• 2D/ ECHO REPORT

Name: - Mrs SONIKA GUPTA

Age: - 32 Yrs

Date: - 28-Sep-24

Reg. No.: - Alw/2009/04
BOB health checkup

PROCEDURES:

M-MODE/2D/DOPPLER/COLOR/CONTRAST B.A.S. M²

MEASUREMENT:		DOPPLER:						
AOD	18	NORMAL	MV	1.1	NORMAL (cm/sec.)	MR	No	
LA	19	(20- 37mm)	AV	1.7	(0.8- 1.3)	AR	No	
AVO	15	(19- 40mm)	TV	0.6	(1.2- 1.8)	TR	No	
RVDd.	11	(12- 25mm)	PV	0.8	(0.3- 0.8)	PR	No	
		(03- 09mm)			(0.7- 1.1)			
LVDd	42	(37- 56mm)	MITRAL VALVE-					
LVDs	25.9	(22- 40mm)			AML	Normal		
IVS d	7	(06- 12mm)			PML	Normal		
IVS s	10		AORTIC VALVE				Normal	
PWd	5	(05- 10mm)	TV & PV are normal.					
LV FUNCTION								
M- E- S Separation		<0.9cm						
Minor		24.42%						
LV Ejection Fraction	70%	65 +/- 12%						

MITRAL E>A
LV WALL MOTION: NO RWMA
ALL CARDIAC CHAMBERS ARE NORMAL
ALL VALVES ARE NORMAL
NO CLOT, VEGETATION, PERICARDIAL EFFUSION

Adv: - Follow up/ review at higher center for confirmation

Note:- Please Correlate clinically. Due to technical limitations as well as inaccuracies inherent in the laboratory and statistical analysis of biological process. Diagnostic accuracy of ECHO is up to 95% only.
Report is not valid for medico-legal purpose.


Dr. Mukesh Gupta
PHYSICIAN
Physician & Sonologist
RM 5423/16262



"भ्रूण लिंग परीक्षण की शिकायत
104 टोल फ्री सेवा पर भी की
जा सकती है"

भ्रूण लिंग परीक्षण की शिकायत 104 टोल फ्री सेवा पर भी की जा सकती है।



दक्ष हॉस्पिटल

396, गाँधी नगर स्क्रीम नं.8, अलवर (राज०) ☎ 0144-2703340

Sonography / 2D Echo Cardiography / Doppler Report

NAME :- MRS SONIKA GUPTA/F/32 YRS

28-Sep-24

BOB HEALTH CHECKUP

U.S.G. OF ABDOMEN & PELVIS

LIVER

Liver is 13.8 cm with normal echo-texture. Intra hepatic biliary radicals are not dilated. No evidence of focal or diffuse lesion.

GALL BLADDER

Gall bladder is normal.

PANCREAS

Pancreas is normal in size, shape & echo-texture. No evidence of focal or diffuse lesion. MPD not dilated.

SPLEEN

11.3 cm normal in size with normal shape & echo-texture. Spleen vein is normal. No evidence of focal or diffuse lesion.

KIDNEY

Both kidneys are normal size shape and echo-texture.

URINARY BLADDER

UB is normal.

UTERUS:

Uterus is normal in size (7.6x3.4x4.5cm) with homogenous echo-texture. Endometrial 6 mm in thickness & echo genicity.

OVARIES:

Both ovaries are normal size, shape & echo-texture.

Advice- follow up/ hormonal study review at higher center for confirmation

Please correlate clinically. USG accuracy is 95 % due to technical limitations as well as inaccuracies inherent in the laboratory and statistical analysis biological process.
This report is not valid for medico-legal cases.

DR. MUKESH GUPTA
SONOLOGIST

Dr. Mukesh Kumar Gupta
Physician & Sonologist
RM 5423/16262



"भ्रूण लिंग परीक्षण की शिकायत
104 टोल फ्री सेवा पर भी की
जा सकती है"

भ्रूण लिंग परीक्षण की शिकायत 104 टोल फ्री सेवा पर भी की जा सकती है।

Female Years

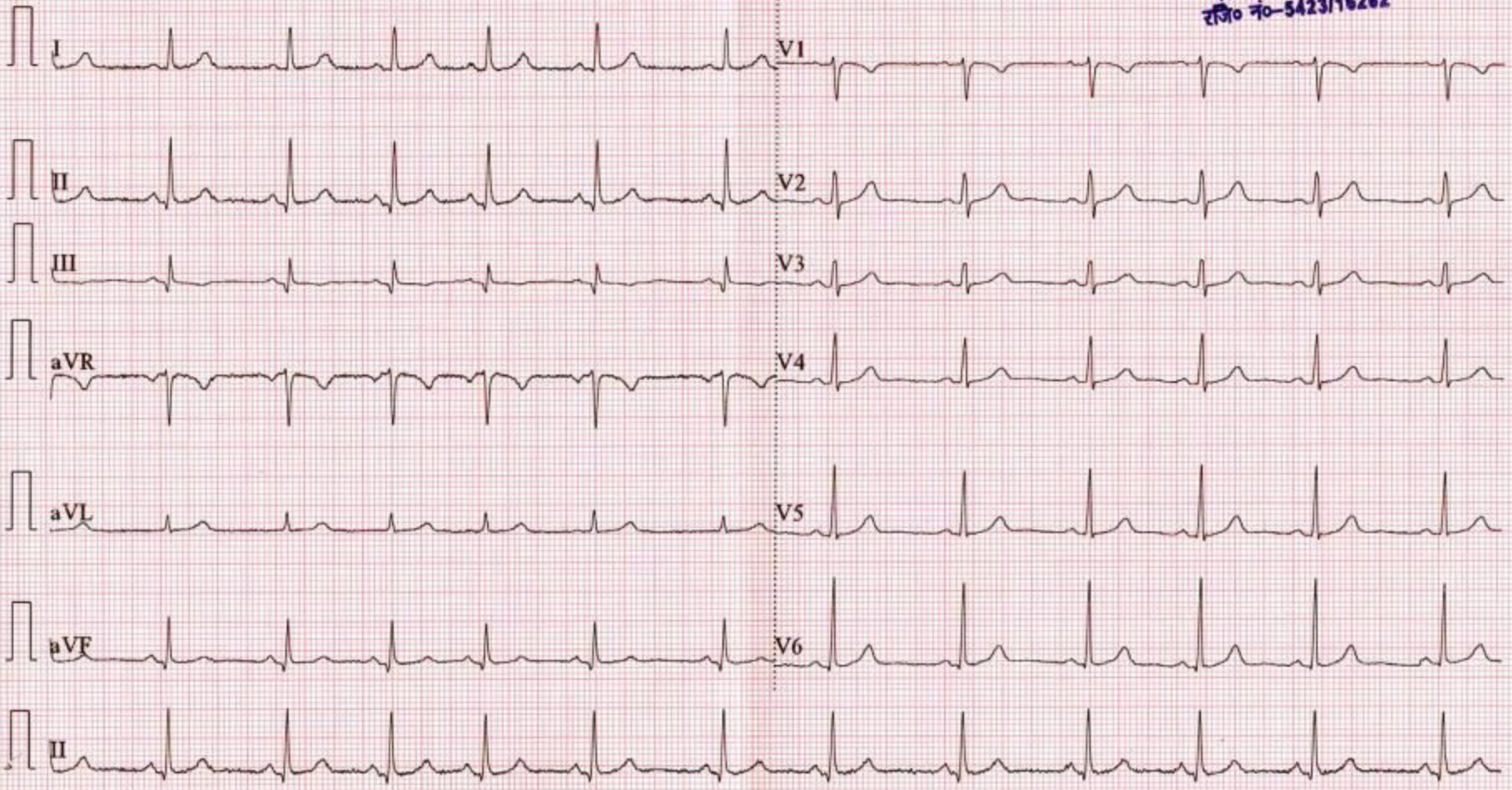
HR : 76 bpm
P : 96 ms
PR : 134 ms
QRS : 78 ms
QT/QTc : 362/407 ms
P/QRS/T : 63/42/26 °
RV5/SV1 : 1.161/0.611 mV

Diagnosis Information:
Sinus Arrhythmia
Poor R Wave Progression(V3)

ll

डॉ० मुकेश गुप्ता
M.D.F.C.C.S.
किल्जिबिन एवं नयुमैर रोग विशेषज्ञ
दक्ष हॉस्पिटल, अलवर
रजि० नं०-5423/18262

Report Confirmed by:



R

