

Meeliwhat.



भारतीय विशिष्ट ओळख प्राधिकरण

भारत सरकार

Unique Identification Authority of India  
Government of India

नोंदविण्याचा क्रमांक / Enrollment No 1190/10945/04966

To,  
अभिजीत सखाराम ताटकर  
Abhijeet Sakharam Tatkar  
S/O Sakharam Tatkar  
Building No. 11, Block No. 31, Swa Griha C.H.S.  
Lokmanya Nagar, K G Marg  
Gokhale Road South Prabhadevi  
Dadar West  
Mumbai  
Maharashtra 400025

18/10/2011

Ref. 33 / 01C / 63886 / 65835 / P



UE113307296IN



HARI CHHABLANI  
FELLOW INTENSIVE CARE  
MMC REG. NO. - 91702

आपला आधार क्रमांक / Your Aadhaar No. :

9006 7245 5000

NATIONAL RESOURCE CENTRE  
42, RAJENDRA NAGAR (S.E.)

आधार - सामान्य माणसाचा अधिकार



भारत सरकार  
GOVERNMENT OF INDIA



अभिजीत सखाराम ताटकर  
Abhijeet Sakharam Tatkar  
जन्म वर्ष / Year of Birth : 1970  
पुरुष / Male



9006 7245 5000

Handwritten signature

57/m

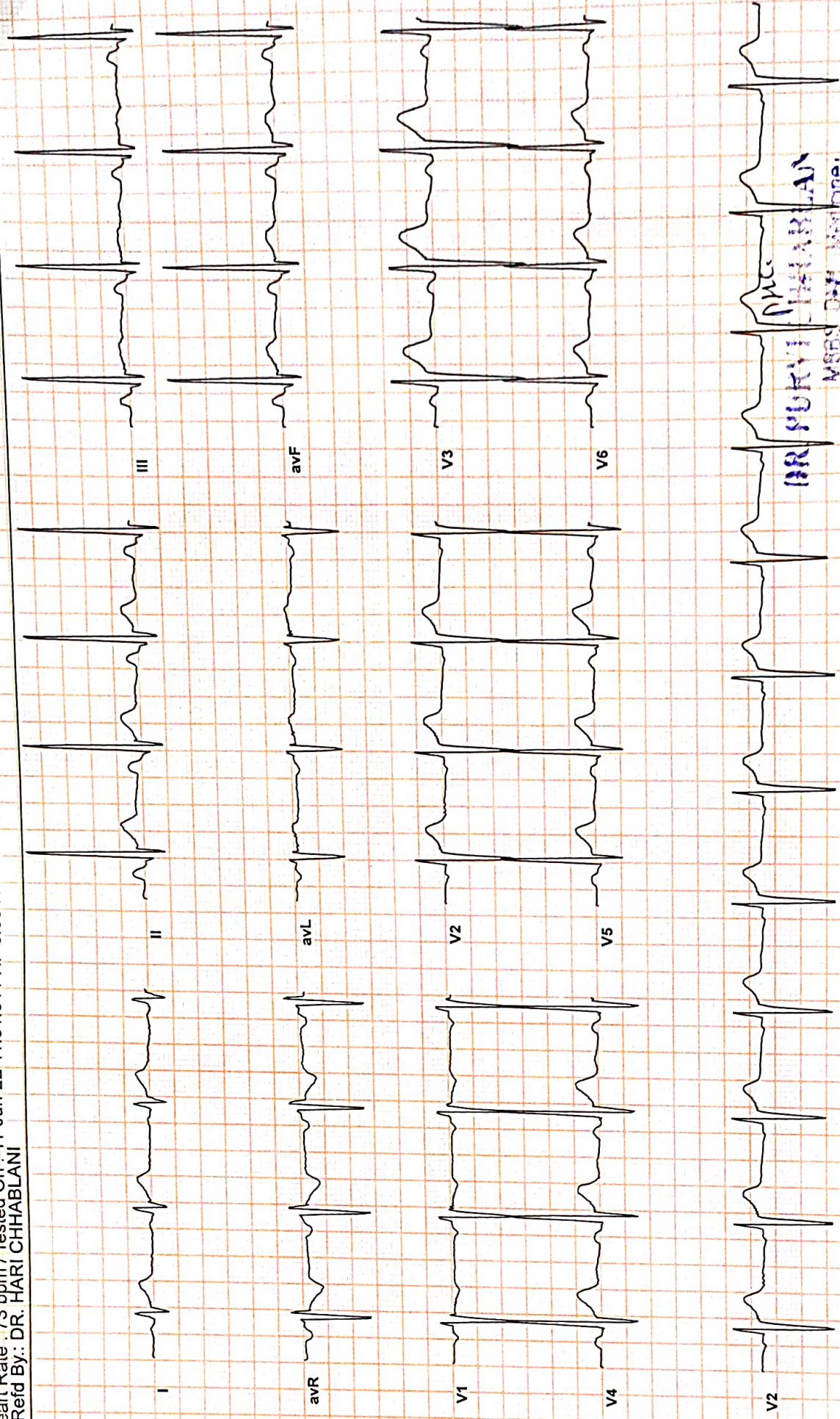
आधार - सामान्य माणसाचा अधिकार

12/12/1970

ECG

DR PLUS HEALTHCARE CENTRE- MUMBAI CENTRAL

1891 / ABHIJEET TATKAR / 52 Yrs / M  
Heart Rate : 73 bpm / Tested On : 11-Jun-22 11:51:01 / HF 0.05 Hz - LF 100 Hz / Notch 50 Hz / Sn 1.00 Cm/mV / Sw 25 mm/s



DR PURVI CHHABLANI

MSBS, DM, Medicine.  
Consultant Physician And Intensivist

Reported By: DR. PURVI CHHABLANI

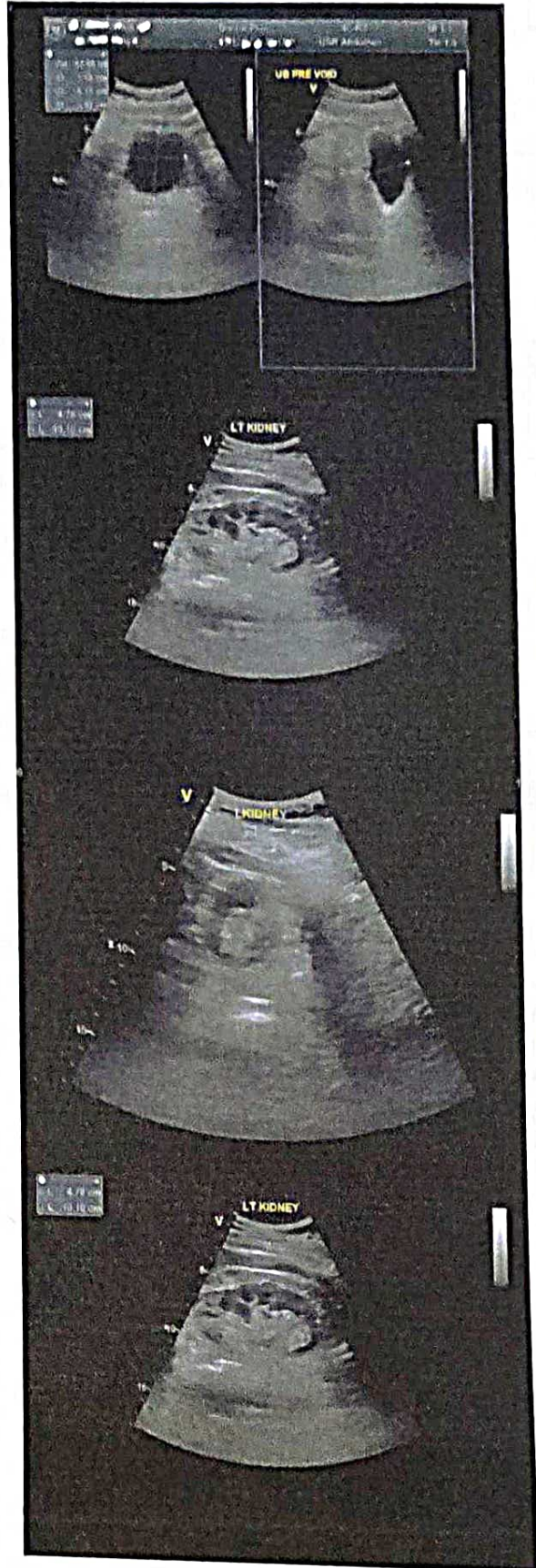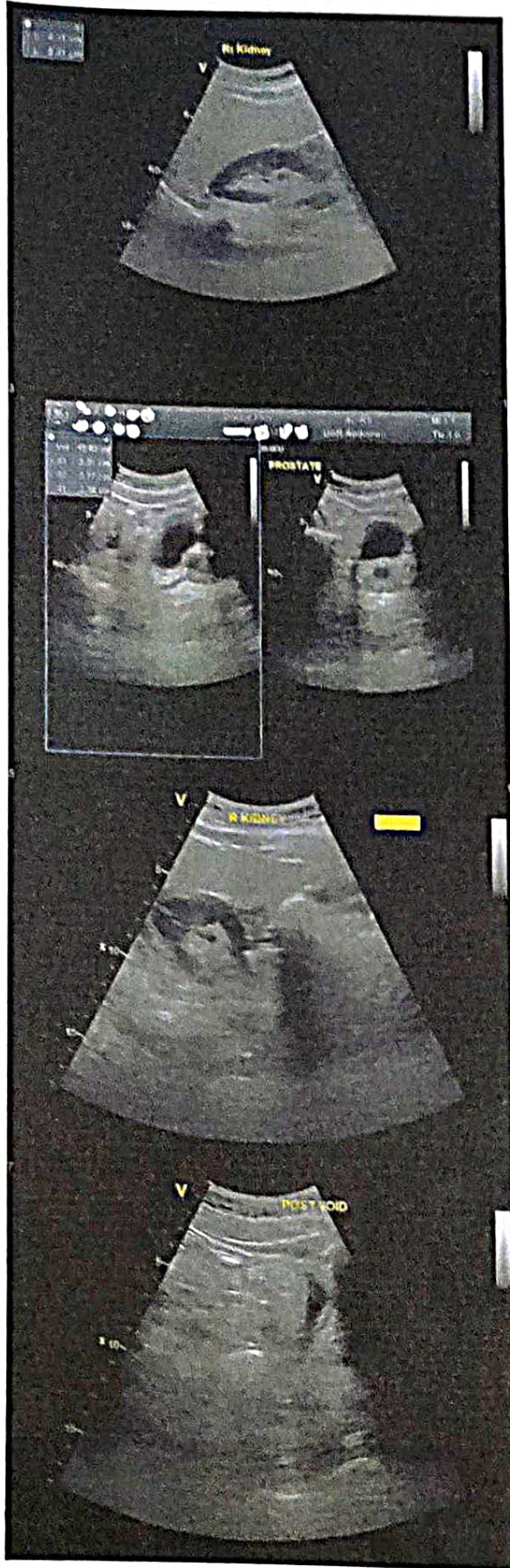WHL

Name **ABHIJEET TATKAR**

Sex **Male**

Age **52**

Date





# Dr-Plus Healthcare Centre

NATHANI HEIGHTS, B-Wing, Shop No. 42, Ground Floor, Opp. Mumbai Central Station (East), Mumbai - 400 008.

|               |   |                 |      |          |
|---------------|---|-----------------|------|----------|
| Patient Name  | : | ABHIJEET TATKAR | Sex: | Male     |
| Doctor's Name | : | SELF            | Age: | 52 Years |
| Date          | : | 11/06/2022      |      |          |

## ULTRASONOGRAPHY OF THE ABDOMEN AND THE PELVIS:

The relevant sonographic findings include the following:

### HEPATOBIILIARY APPARATUS

The liver is normal in size and echogenicity. No obvious focal parenchymal lesion is seen. Extrahepatic biliary radicals are not dilated.

The portal vein and the common bile duct are normal.

### GALL BLADDER

The gall bladder is adequately distended. The wall thickness is normal.

No echogenic contents are noted in its lumen. There is no pericholecystic collection noted.

### PANCREAS

The pancreas shows normal echogenicity and size.

No focal or diffuse lesions are noted. No evidence of calcification is noted.

### SPLEEN

The spleen appears normal in size and echogenicity. No focal or diffuse lesions are noted.

No evidence of calcification is noted.

### KIDNEYS

Right Kidney measure: 10.9 x 5.6 cm, Left kidney measure: 10.5 x 5.6 cm

Both the kidneys appear normal in size, shape and echogenicity. Both the pelvicalyceal system is normal and both corticomedullary differentiations are well maintained. There is no obvious focal or diffuse lesion noted.

No evidence of any calculus seen in either kidney.

### URINARY BLADDER

The urinary bladder shows anechoic contents. Its wall thickness appears normal.

No significant post void residue.

### PROSTATE

The Prostate appears normal and shows a normal echogenicity.

No evidence of calcification is seen.

There is no obvious evidence of abdominal or pelvic lymphadenopathy or ascites noted.

**IMPRESSION: No significant abnormality is detected.**

  
Dr. VICTOR X. COUTINHO  
MBBS, DMRE  
Radio-Sonologist

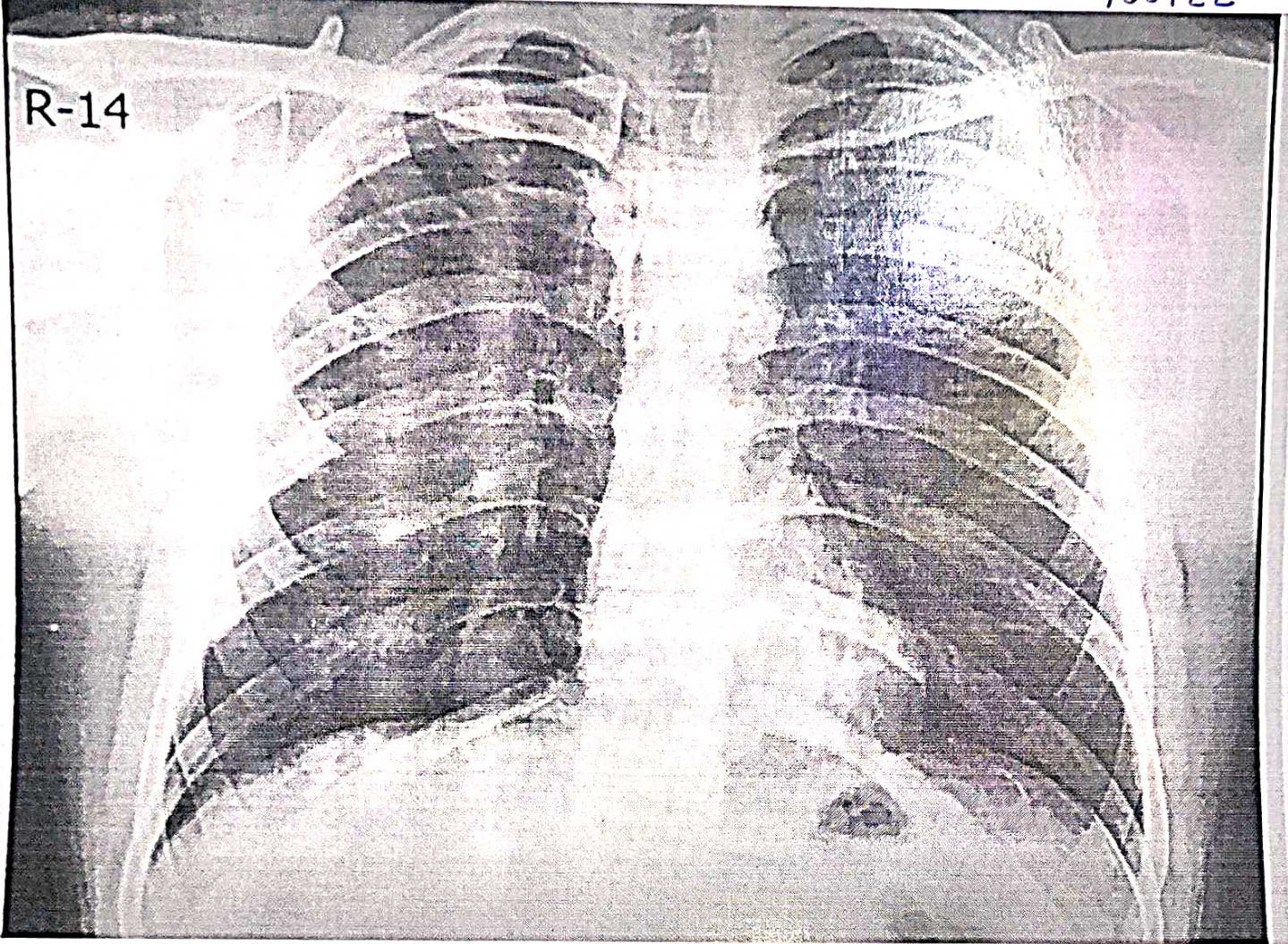
DR. PLUS HEALTHCARE CENTRE  
NATHANI HEIGHTS, B-WING,  
42, MUMBAI CENTRAL (EAST)

ABHIJIT JAIKAR

52/M

11/06/22

R-14





Patient's Name : ABHIJEET TATKAR

Report Date : 11/06/2022

Referred By : SELF

Age : 50 Years

Sex : MALE

## X- RAY CHEST

BOTH THE LUNG FIELED ARE CLEAR.

THE HILAR SHADOWS APPEAR NORMAL.

THE COSTO-PHRENIC ANGELS ARE CLEAR.

THE CARDIAC SHADOWS APPEAR NORMAL.

THE TRACHEAL IS CENTRAL IN POSITION.

THE BONY CAGE APPEARS NORMAL.

  
DR. A.J. MAZUMDAR

MD. DMRE, MDRD

'DR. PLUS HEALTHCARE CENTRE'  
NATHANI HEIGHTS', B-WING,  
42, MUMBAI CENTRAL (EAST)



# Dr-Plus Healthcare Centre

NATHANI HEIGHTS, B-Wing, Shop No. 42, Ground Floor, Opp. Mumbai Central Station (East), Mumbai - 400 002.

Full Name

ABHIJEET TATKAR

52/M

11/06/2022

Life to be assured:

## HAEMOGRAM

### Normal Range

|                      |  |                        |  |
|----------------------|--|------------------------|--|
| 1.                   | Red Blood Cell Count                           | 4.9                    | [M : 4.5 - 5.6 / F : 3.5 - 5.5/cu.mm]    |
| 2.                   | Hb%  | 15.6                   | [M: 14-18 / F : 11-16%]                  |
| 3.                   | Hematocrit                                     | 48.8                   | [M : 40-53 / F : 30-47 %]                |
| 4.                   | Indices:                                       |                        |  |
| (a)                  | MCV(Mean Corpuscular Volume)                   | 90.4                   | [79-101 cu.mi.]                          |
| (b)                  | MCH(Mean Corpuscular Hb)                       | 30.5                   | [27-32 pg]                               |
| (c)                  | MCHC(Mean Corpuscular Hb Concentration)        | 32.0                   | [32-38%]                                 |
| 5.                   | Morphology                                     |                        |  |
|                      | Macrocytes :                                   | --                     | Microcytes: -- Hypochromia: --           |
|                      | Poikilocytosis:                                | --                     | Anisocytosis: --                         |
| 6.                   | Target cells:                                  | --                     |  |
|                      | Spherocytes:                                   | --                     | Elliptocytes: --                         |
| 7.                   | <b>TOTAL W.B.C.Count</b>                       | 7,500                  | {4000-11000/cu.mm}                       |
| Differential Count 0 |  |                        |  |
| a)                   | Neutrophils :                                  | 60                     | [45 - 70%] c) Eosinophils: 02 [01 - 06%] |
| b)                   | Lymphocytes :                                  | 34                     | [20 - 45%] d) Monocytes: 03 [00 - 08%]   |
| e)                   | Basophils :                                    | 01                     | [00 - 01%]                               |
| 8.                   | <b>Platelets :3.87</b>                         |                        | 1.5-4.5 Lacks/cu.mm                      |
| 9.                   | <b>Erythrocyte Sedimentation Rate (ESR):12</b> | 20 mm at end of 1 hour | Method : Westergrens                     |

## ROUTINE URINE EXAMINATION (RUA)

### 1. Physical Examination:

|       |                  |        |      |           |        |
|-------|------------------|--------|------|-----------|--------|
| (i)   | Colour:          | YELLOW | (ii) | Sediment: | CLEAR  |
| (iii) | Transparency:    | CLEAR  | (iv) | Reaction: | ACIDIC |
| (v)   | Specific gravity | 1.015  |      |           |        |

### 2. Chemical Examination:

|       |            |     |      |               |     |
|-------|------------|-----|------|---------------|-----|
| (i)   | Protein :  | NIL | (ii) | Sugar:        | NIL |
| (iii) | Bile salt: | NIL | (iv) | Bile pigment: | NIL |

### 3. Microscopic Examination:

|       |                  |        |      |                   |             |
|-------|------------------|--------|------|-------------------|-------------|
| (i)   | Red Blood Cells: | ABSENT | (ii) | Epithelial Cells: | 2 TO 3/ HPF |
| (iii) | Crystals:        | ABSENT | (iv) | Pus Cells:        | 2 TO 3/HPF  |
| (v)   | Casts:           | ABSENT | (vi) | Deposits:         | ABSENT      |

DR. JAYKESH PATKAR  
M.D., M.N.B. (Pathology)  
Reg. No. 2013/05/1660



# Dr-Plus Healthcare Centre

NATHANI HEIGHTS, B-Wing, Shop No. 42, Ground Floor, Opp. Mumbai Central Station (East), Mumbai - 400 008.

Full Name ABHIJEET TATKAR 52/M 11/06/2022  
Life to be assured:

|    | Type of Test                  | Actual Reading | Normal Range    |
|----|-------------------------------|----------------|-----------------|
| 1  | Fasting Blood Sugar           | 78.6           | 70-100 mg%      |
| 2  | PPBS                          | 113.5          | 110 TO 140 mg%  |
| 3  | Total Cholesterol             | 170.3          | 120-200 mg%     |
| 4  | VERY LOW DENSINTY LEVEL(VLDL) | 20.2           | 10-30 mg/dl     |
| 5  | High Density Lipid (HDL)      | 49.0           | 40-60 mg%       |
| 6  | Low Density Lipid (LDL)       | 99.1           | <u>Upto 150</u> |
| 7  | S. Triglycerides              | 111.5          | 50-150 mg%      |
| 8  | CHOL/HDL                      | 3.4            | Upto 5          |
| 9  | HDL/LDL                       | 0.4            |                 |
| 10 | S. Creatinine                 | 0.8            | 0.5-1.2 mg%     |
| 11 | Blood Urea Nitrogen (BUN)     | 16.5           | 7-21 mg%        |
| 12 | BUN/CREAT RATIO               | 20.6           |                 |
| 13 | S. Proteins                   | 6.8            | 6.0-7.9 mg%     |
| 14 | (a) Albumin                   | 3.7            | 3.5-5.5 mg%     |
| 15 | (b) Globulin                  | 3.1            | 2.0-3.5 mg%     |
| 16 | A/G RATIO                     | 1.1            |                 |
| 17 | S. Bilirubin                  | 0.9            | 0.3-1.3mg%      |
| 18 | (a) Direct                    | 0.7            | 0.0-0.8 mg%     |
| 19 | (b) Indirect                  | 0.2            | 0.0-0.5 mg%     |
| 20 | SGOT (AST)                    | 23.6           | 05-34 IU        |
| 21 | SGPT (ALT)                    | 28.4           | 05-40 IU        |
| 22 | GGTP (GGT)                    | 34.5           | 05-50 IU        |
| 23 | SGOT/SGPT                     | 0.8            |                 |
| 24 | HBA1C                         | 5.2            | UPTO 6.5        |
| 25 | S. Alkaline Phosphatase       | 95             | 30-115 IU       |
| 26 | T3                            | 128.3          | 80-180ng/dl     |
| 27 | T4                            | 6.2            | 4.6-12 ug/dl    |
| 28 | TSH                           | 2.4            | 0.4-4.0 mIU/L   |
| 29 | SERUM URIC ACID               | 5.5            | 2.5-7.2mg/dl    |
| 30 | URINE SUGAR PP                | ABSENT         |                 |
| 31 | URINE SUGAR FASTING           | ABSENT         |                 |
| 32 | BLOOD GROUP                   | "A POSITIVE "  |                 |

DR. BAKESH PATKAR  
M.D., D.N.B. (Pathology)  
No. 2013/05/1660





**Dr. Hari Chhablani**

Cardiometabolic Physician & Intensivist  
M.B.B.S., F.C.C.P. (RESP. MED.), PGDHHM,  
PGDMLS, FELLOW INTENSIVE CARE MED.

ATTACHED TO: Wockhardt Hospital • Salfee Hospital • Apollo Spectra Hospital

NATHANI HEIGHTS, B-Wing, Shop No. 42, Ground Floor, Opp. Mumbai Central Station (East),  
Mumbai - 400 008. • Cell : 98206 46163 • E : drharichhablani@gmail.com

## PHYSICIAN REPORT

NAME: ABHIJEET TATKAR 52/M

DATE: 11/06/2022

PRESENTING COMPLAINS : EPISODE OF UNCONSCIOUSNESS FEW DAYS BACK.  
C/O POST JOGGING GIDDINESS SINCE LAST - 5 DAYS .

TREATMENT : NIL .

PAST HISTORY : NIL

FAMILY HISTORY: NOT SIGNIFICANT

HABITS : NIL.

DENTAL EXAMINATION: NAD

HT.- 177 CM. WT.-72 Kg.

P: 72 /MIN ., REGULAR

BP: 124/80

RS: CLEAR CVS: S1,S2 REGULAR

PA: SOFT

CNS: CLINICALLY NAD

EYE EXAMINATION : NEAR VISION -B/E N6 , DISTANT VISION -BE-- 6/6 , COLOUR VISION - NORMAL

LABS: ATTACHED

ECG: ATTACHED

CHEST X-RAY : ATTACHED

SONOGRAPHY : ATTACHED

2-D- ECHO : ATTACHED

IMPRESSION : REFER TO NEUROLOGIST .

DR.HARI CHHABLANI

DR. HARI CHHABLANI

(RESP. MED. (INTENSIVE) PGDHHM) PGDMLS  
FELLOW INTENSIVE CARE  
MMC REG. NO. - 91702



GASJEM



**Mumbai, Maharashtra, India**  
Shop No 65, Nathani Heights, Marzban Parsi Colony, Dalal Estate, Mumbai Central, Mumbai, Maharashtra 400008, India  
Lat 18.968746°  
Long 72.819939°  
11/06/22 09:28 AM

