

**Diwakar Diagnostic Centre  
E-7/636, Arera Colony, Bhopal**

908 / ATUL KULKARNI / 42 Yrs / M / 0 Cms / 0 Kg Date: 10-Dec-2022 Refd By : BOB

**Report :**

TEST OBJECTIVE	: ROUTINE CHECK UP
RISK FACTOR	: HYPERTENSION
ACTIVITY	: MODERATE ACTIVE
MEDICATION	: TEMISARTAN
BRIEF HISTORY	: HYPERTENSION LAST 2 YEARS
REASON FOR TERMINATION	: FATIGUE, HEART RATE ACHIEVED
EXERCISE TOLERANCE	: AVERAGE
EXERCISE INDUCED ARRHYTHMIAS	: NO
HAEMODYNAMIC RESPONSE	: NORMAL
CHRONOTROPIC RESPONSE	: NORMAL
FINAL IMPRESSION	: STRESS TEST IS NEGATIVE FOR EXERCISE INDUCED ISCHAEMIC HEART DISEASE



PTO

Right Kidney is normal in size, shape and position. Corticomedullary differentiation (CMD) is well maintained. Normal cortical thickness is noted. No E/O hydronephrosis or calculus is noted.

Pancreas appear normal in size, shape and echo texture with smooth contour. No peripancreatic pathology seen. (Not seen due to gases)  
Spleen is normal / enlarged in size and normal in echo texture.  
IVC and aorta appear to be normal.  
No evidence of lymphadenopathy is noted.  
No evidence of free fluid is noted.

No E/O Subdiaphragmatic Collection.  
Gall Bladder is physiologically well distended / collapsed. No E/O echogenic foci in GB lumen. GB wall is normal / thickened. No E/O pericholecystic collection. common duct reveals normal course and caliber.

Liver appears normal / enlarged in size and shape with smooth in outline. Normal / increased parenchymal echogenicity is noted. No E/O focal lesion / IHBR dilatation is seen. Hepatic veins and portal veins appear normal. *gr II fatty liver*

WHOLE ABDOMEN ULTRASOUND REPORT

Indication :

Name : Mrs. *Arun Kulkarni*  
Age : *42* / Male  
R/B No. *Heedth check-up*  
Date *10/12/2022*



**डॉ. सविता क्लिनिक**  
34, भूतल, मोहिनी अदिति आर्कड, शाहपुरा मस्जिद के पास  
भरत नगर रोड, ई-7/194, अररा कॉलोनी, भोपाल - 462038  
Mob. : 8989649694, 9516333619  
Clinic Registration : CL/5392/Jun/2017  
PNDT Registration : MPPCPNDT/BPL/2017/206



908 / ATUL KULKARNI / 42 Yrs / M / 0 Cms / 0 Kg Date: 10-Dec-2022 Refd By : BOB

Stage	Time	Duration	Belt Speed (mph)	Elevation	METs	Rate	% THR Achieved	BP	RPP	PVC	Comments
Supine	00:13	0:01	00.0	00.0	01.0	93	52 %	130/80	120	00	
Standing	00:24	0:01	00.0	00.0	01.0	89	50 %	130/80	115	00	
HV	00:34	0:01	00.0	00.0	01.0	087	49 %	130/80	113	00	
Warm Up	00:45	0:02	01.7	10.0	01.0	091	51 %	130/80	118	00	
ExStart	00:50	0:07	01.7	10.0	01.1	101	57 %	130/80	131	00	
BRUCE Stage 1	03:50	3:00	01.7	10.0	04.7	120	67 %	140/90	168	00	
BRUCE Stage 2	06:50	3:00	02.5	12.0	07.1	139	78 %	150/98	208	00	
PeakEx	07:06	0:16	03.4	14.0	07.4	146	82 %	150/98	219	00	
Recovery	08:05	1:00	00.0	00.0	01.1	104	58 %	140/90	145	00	
Recovery	09:05	2:00	00.0	00.0	01.0	109	61 %	130/80	141	00	
Recovery	09:22				00.0	000	0 %	---/---	000	00	

**Findings :**

Exercise Time : 06:17  
 Max HR Attained : 146 bpm 82% of Target 178  
 Max BP Attained : (Sys) 150/98  
 Max WorkLoad Attained : 7.4 Fair response to induced stress  
 Test End Reasons : Fatigue, Heart Rate Achieved

**Left Kidney** is normal is size, shape and position. CMD is well maintained. Normal cortical thickness is noted. No E/O hydronephrosis or calculus is noted.

**Urinary Bladder** is well distended (physiological) / collapsed. Its contents are echo free. No E/O bladder wall thickening is noted. Post-void residue is insignificant.

**Prostate** is normal in size, shape and echo texture with smooth outline. No E/O focal lesion is noted.

**Uterus** is ante/retro vered and normal in size, shape and echotexture with smooth outline. No E/O focal lesion is noted, endometrial echo appear normal. Cervical and vaginal shadows appear normal.

**Right Ovary** appears Enlarged / Normal in size, shape and echo texture.

**Left Ovary** appears Enlarged / Normal in size, shape and echo texture.

Impression : Normal study. Grade II fatty liver.

*[Handwritten signature]*

Advised clinical Correlation.



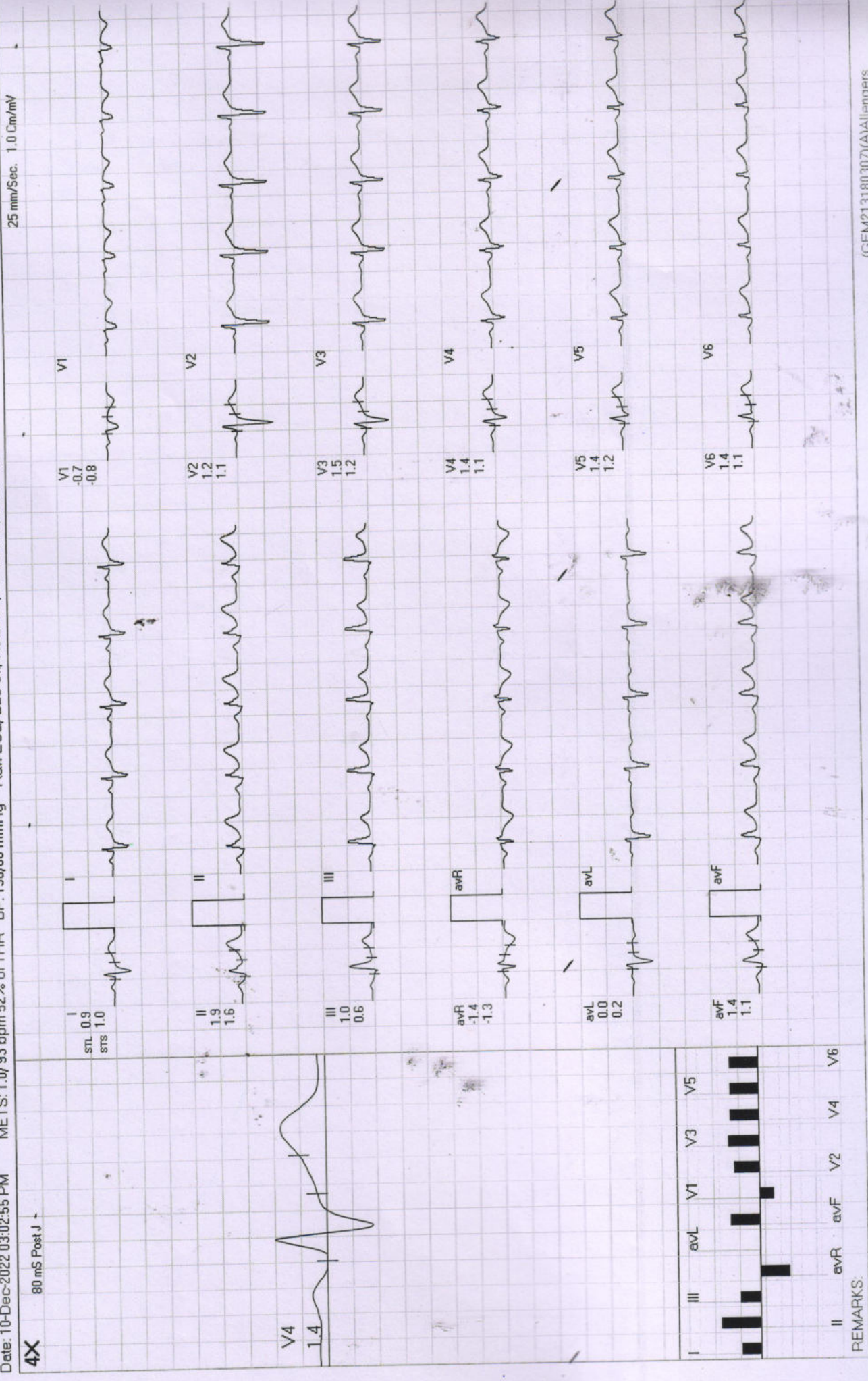
SUPINE

Diwakar Diagnostic Centre

908 / ATUL KULKARNI / 42 Yrs / M

ExTime: 00:12 0.0 mph. 0.0%

Date: 10-Dec-2022 03:02:55 PM METS: 1.0/93 bpm 52% of THR BP: 130/80 mmHg Rew ECG/BLC On/ HF 0.05 Hz/LF 20 Hz





Age 42 YRS/M  
 Date 10/12/2022

**SOUND REPORT**

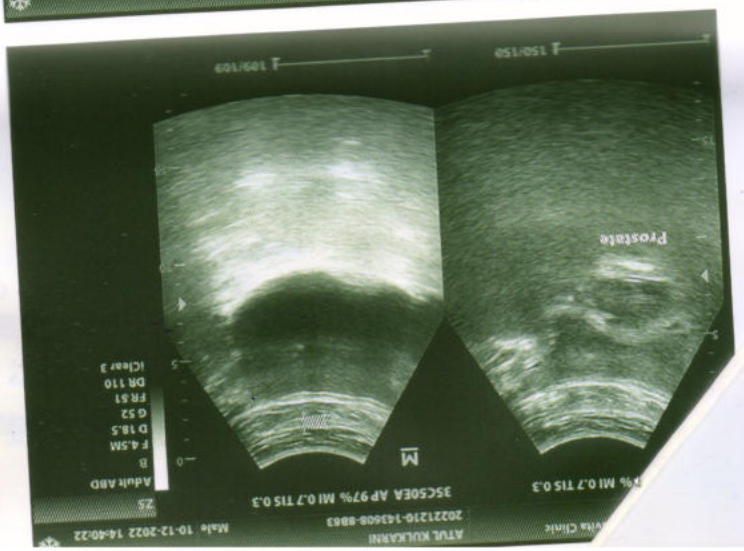
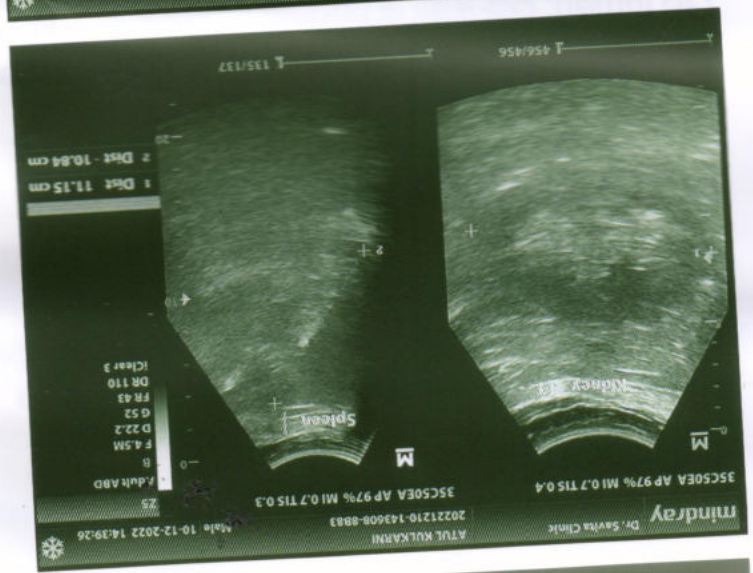
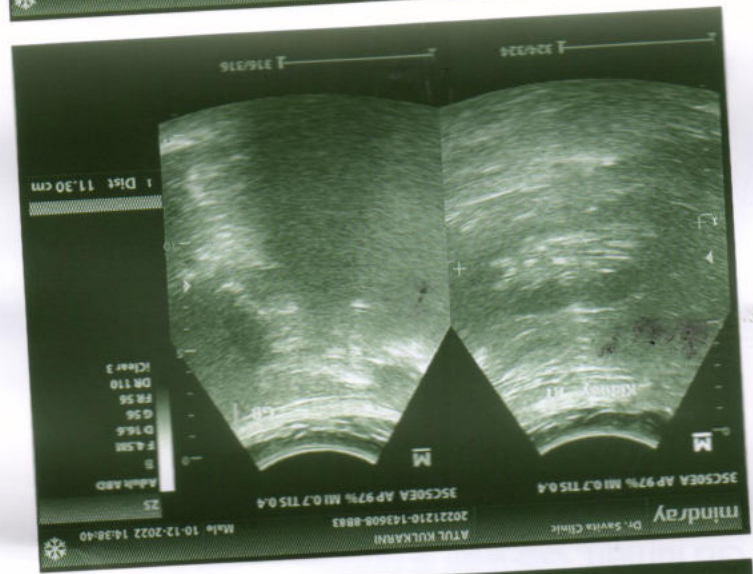
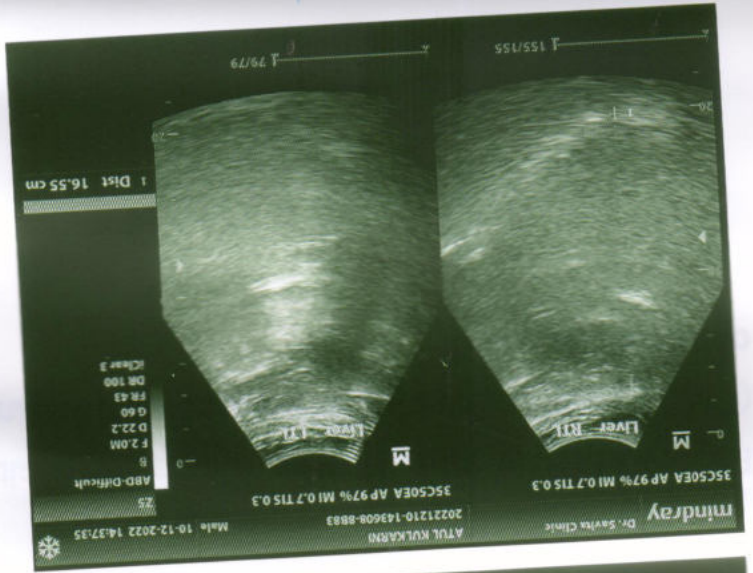
nd shape with smooth in outline.  
 is noted. No E/O focal lesion / IHBR  
 appear normal. *gr II fatty liver*

collapsed. No E/O echogenic foci in  
 pericholecystic collection. common

no texture with smooth  
 t seen due to gases)  
 in echo texture.

n. Corticomedullary differentiation  
 ss is noted. No E/O hydronephrosis

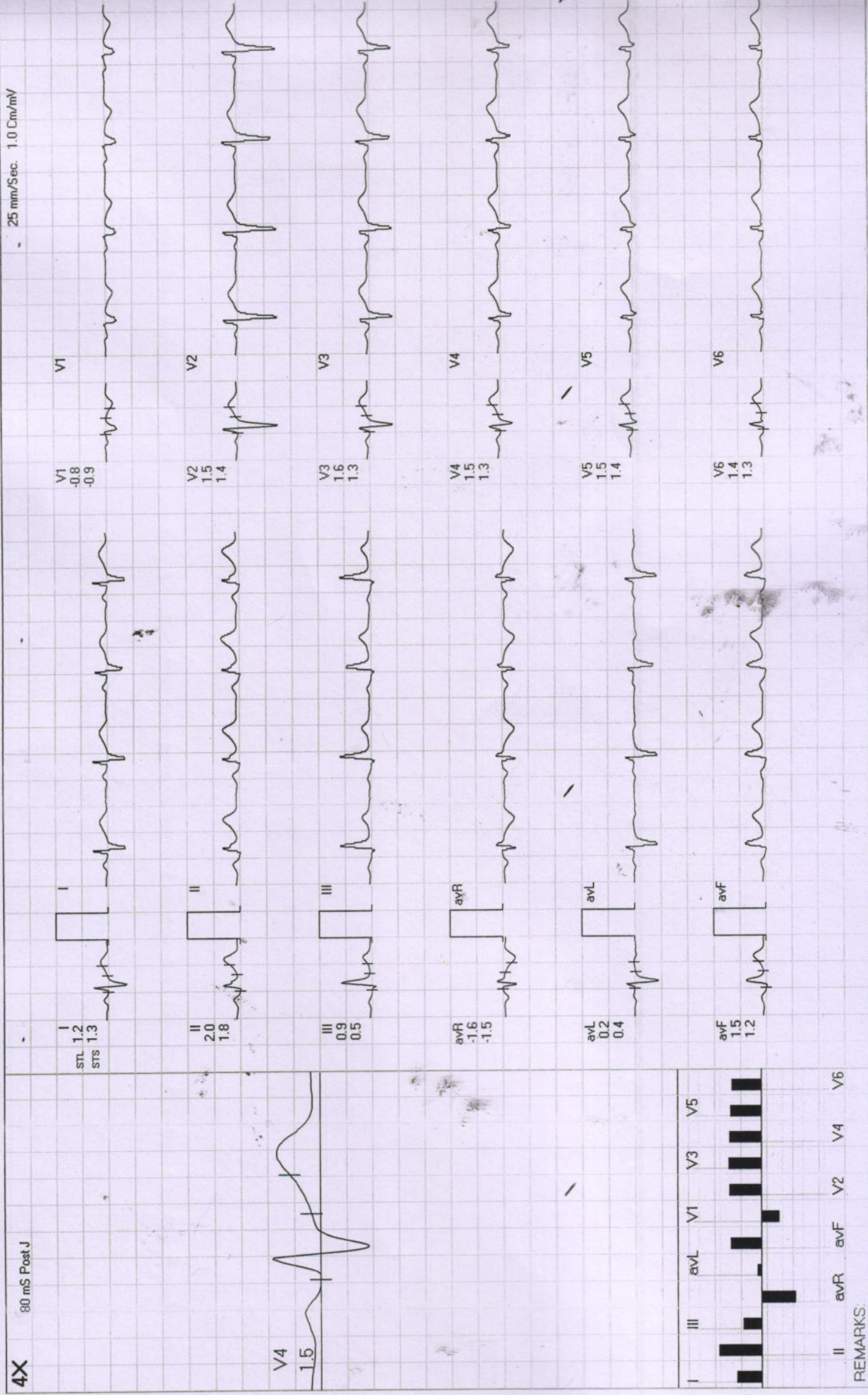
PTO





Date: 10-Dec-2022 03:02:55 PM METS: 1.0/83 bpm 46% of THR BP: 130/80 mmHg Raw ECG/ BLC On/ HF 0.05 Hz/LF 20 Hz

ExTime: 00:23 0.0 mph, 0.0%





Pt Name :- Mr. Atul Kulkarni  
 Age :- 42/M  
 Lab. No. :- 01  
 Date :- 10/12/2022

### EXAMINATION OF BLOOD

TEST	RESULT	NORMAL VALUE
Haemoglobin	15.3gms%	Female 12-16gms%, Male 14-18gms%
Red Cell count	5.11	4.5-5.6 million /cumm
Platelet Count	2.97	1.5-5.6 Lac/cumm
Leucocytes per.cumm	5700/cumm	5000-11000/cumm
Neutrophils	55%	50-70%
Lymphocytes	35%	20-40%
Eosinophils	05%	0-7%
Monocytes	05%	2-8%
PCV	47.0	37-47
MCV	92.1	76-96
MCH	29.9	27-32
MCHC	32.5	31-35
ESR	08	Male 0-9, Female 0-20mm/FHR
Blood Group	"B" Positive	By slide method
Total Serum Cholesterol	180.0	100-250 mg%
Serum Triglyceride	155.0	Up to 150 mg%
Serum Cholesterol HDL	49.0	Up to 65 mg%
Serum Cholesterol LDL	100.0	Up to 125 mg%
VLDL	31.0	Up to 30 mg%
S.Bilirubin(Total)	0.9	0.2-1.0mg/dl
Direct	0.5	0.0-0.25mg/dl
Indirect	0.4	
SGOT	26.0	5-35U/L
SGPT	30.0	8-40U/L
Alk Phosphatase	8.9	3-13 KA units
S. Protein(Total)	7.0	6.0-8.0mg%
Albumin	4.9	3.7-5.3mg%
Globulin	2.4	1.5 to 3.5 mg%
Blood Urea	20.0	Up to 40 mg%
S.Creatine	0.98	0.5-1.4mg/dl
S.Uric Acid	6.0	3.5-7.5mg%
G6TP	24.0	5-35 UL/dl
Fasting Blood Sugar	84.2	Up to 110 mg%
PP Blood Sugar	110.0	Up to 125 mg%
Glycosylated Hemoglobin	5.5	Below - 6.0 % -Non Diabetic control 6-7 % -Excellent control Above- 8 % -Poor control
Thyrod Stimulating Hormone(TSH)	3.5	0.27-4.2

Pathologist

All test have technical limitation. Collaborative clinic pathological interpretation is mandatory. In case of disparity test may be repeated immediately. Typographical mistakes should be get correct instantly. This report is not valid for medico legal purpose

Dr. B. M. Agarwal  
 MBBS, DCP  
 Consultant Pathologist







HV

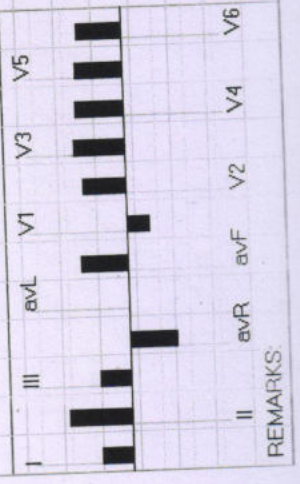

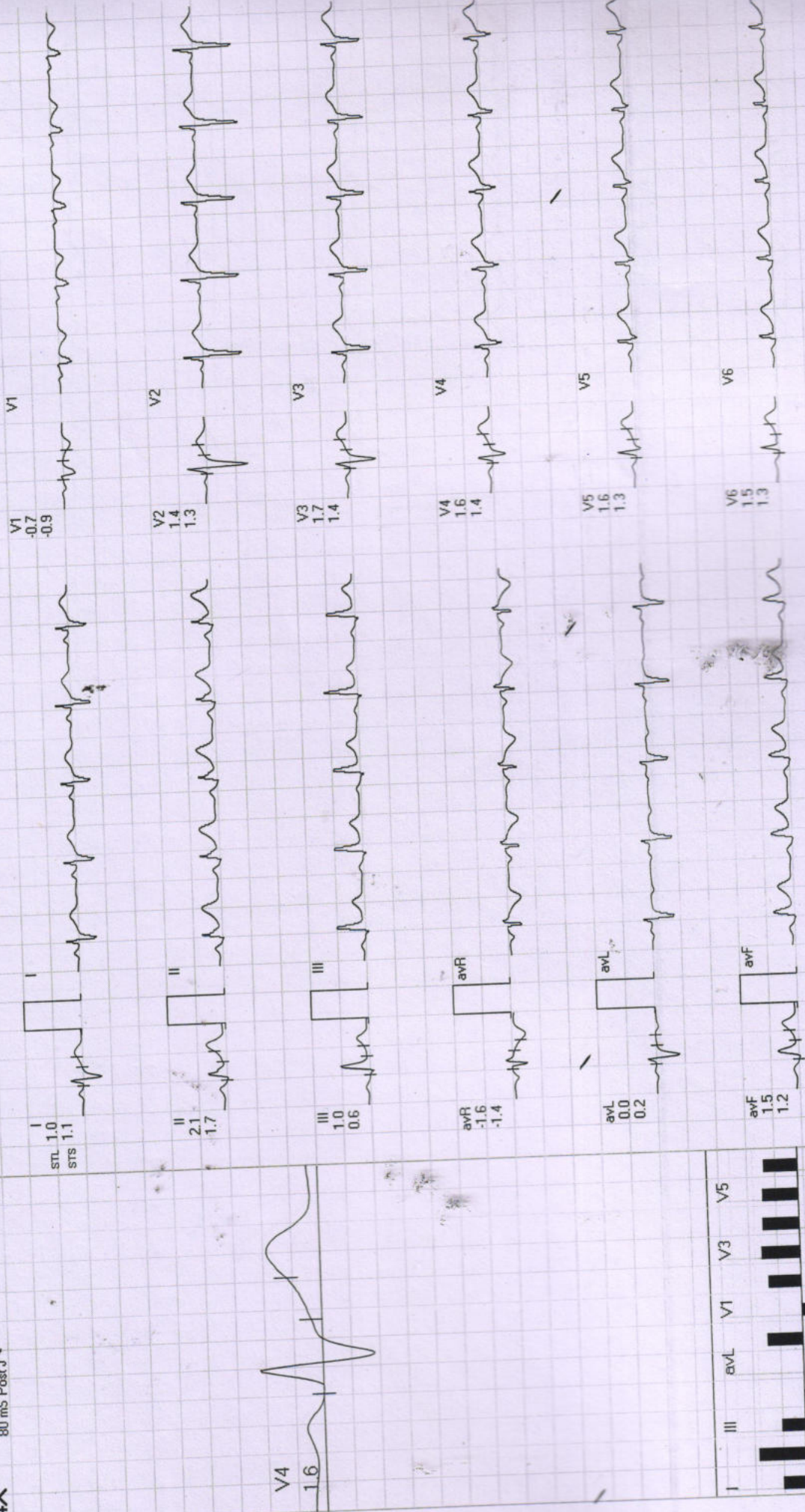
# Diwakar Diagnostic Centre

908 / ATUL KULKARNI / 42 Yrs / M

ExTime: 00:33 0.0 mph. 0.0%

Date: 10-Dec-2022 03:02:55 PM METS: 1.0/ 89 bpm 50% of THR BP: 130/80 mmHg Raw ECG/BLC On/ Natch On/ HF 0.05 Hz/LF 20 Hz

4X 80 ms Post J



REMARKS:



Pathologist

Dr. B. M. Agarwal  
MBBS, DCP  
Consultant Pathologist

A. PHYSICAL EXAMINATION	
1. Colour	Pale Yellow
2. Appearance	Clear
3. Specific Gravity	Q.N.S.
B. CHEMICAL EXAMINATION	
1. Reaction	Acidic
2. Albumin	Nil
3. Sugar	Nil
4. Bile Salts	Absent
C. MICROSCOPIC EXAMINATION	
Pus Cells	2-3/HPF
R.B.C.	Nil
Epithelial Cell	2-3/HPF
Cast	Nil
Crystals(Cal.Oxa)	Nil
Bacteria	Nil
Amorphous	Nil
T. Vaginitis	Nil

### URINE ANALYSIS

Pt Name :- Mr. Atul Kulkarni  
Age :- 42/M  
Lab. No. :- 01  
Date :- 10/12/2022

**डिवाकर डायग्नोस्टिक सेंटर**  
E-7/636, पंजाब रोड, बँक के पास, मंग रोड, अरुण कॉलोनी भायल ( म.प. )  
फोन: 0755-2465288, 0755-3520545 फा: 9826340190





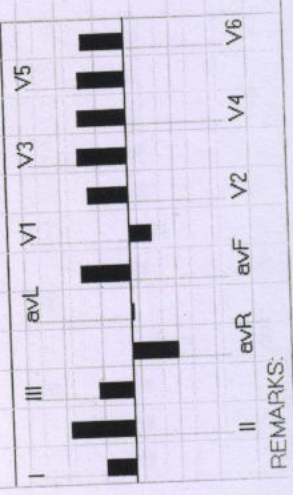
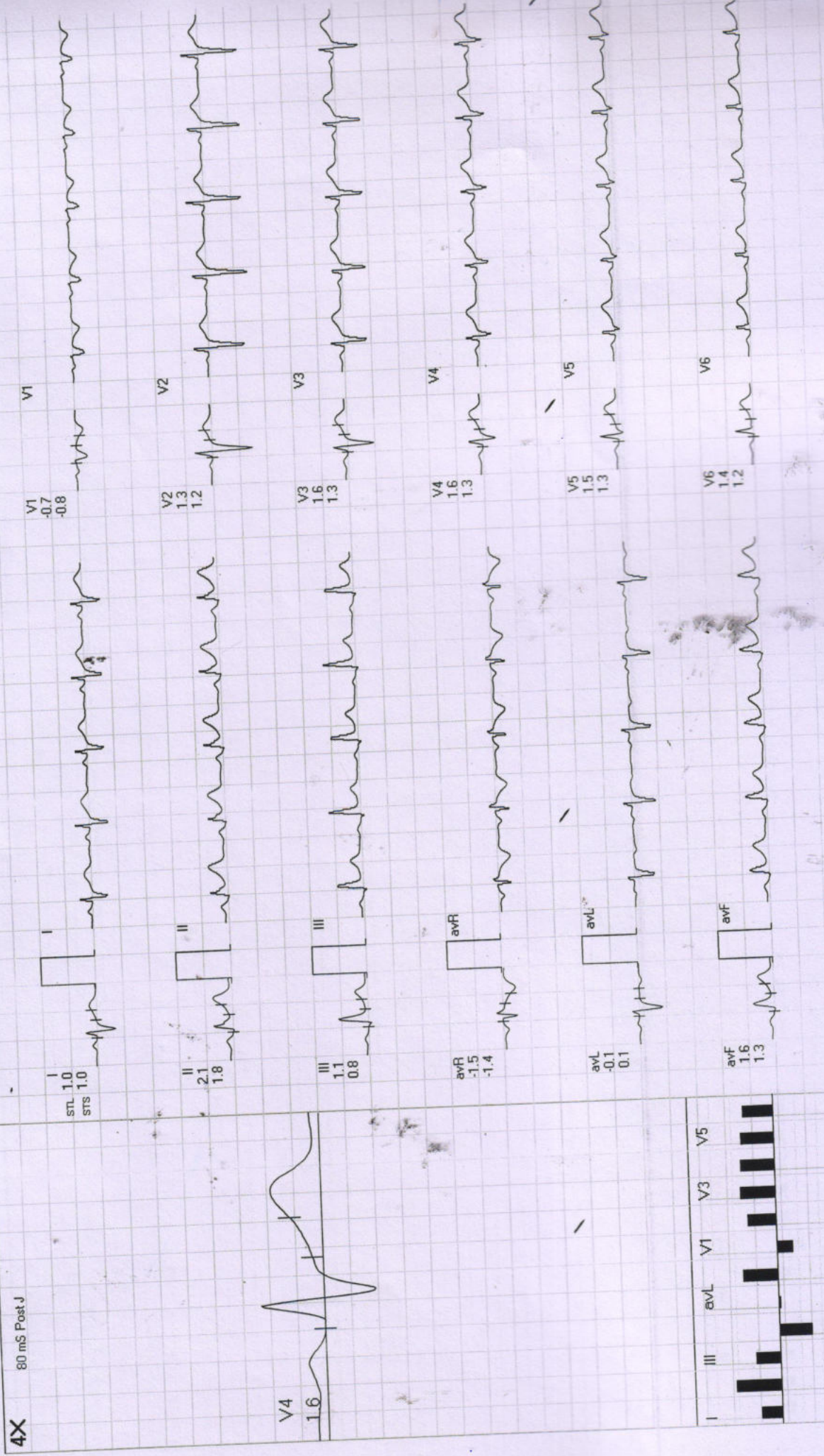
WARM UP

Diwakar Diagnostic Centre

908 / ATUL KULKARNI / 42 Yrs / M

Date: 10-Dec-2022 03:02:55 PM METS: 1.0/ 91 bpm 51% of THR BP: 130/80 mmHg Raw ECG/ BLC On/ Natch On/ HF 0.05 Hz/LF 20 Hz

ExTime: 00:44 1.0 mph, 0.0%  
25 mm/Sec. 1.0 Cm/mV



REMARKS:



ExStrt

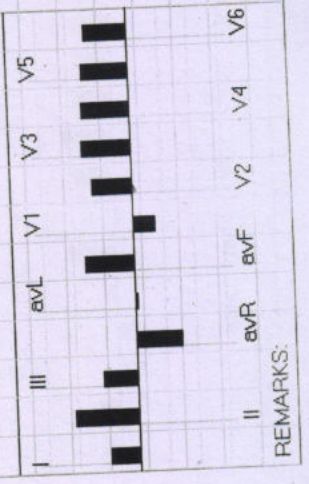

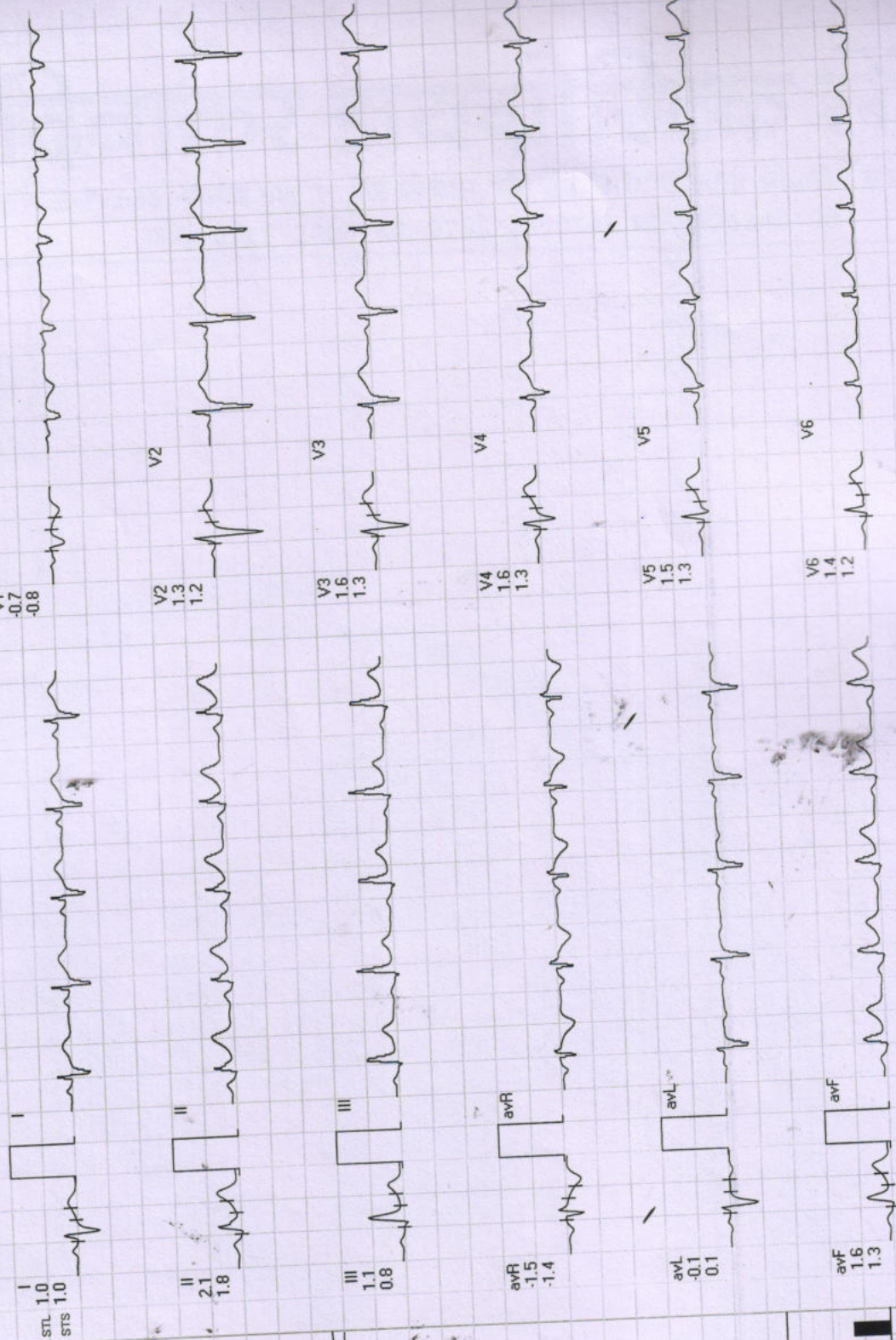
ExTime: 00:00 0.0 mph, 0.0%  
25 mm/Sec. 1.0 Cm/mV

Diwakar Diagnostic Centre

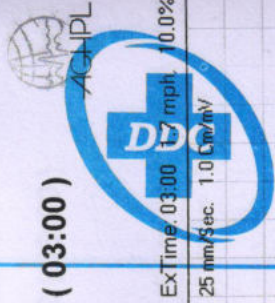908 / ATUL KULKARNI / 42 Yrs / M

Date: 10-Dec-2022 03:02:55 PM METS: 1.0/91 bpm 51% of THR BP: 130/80 mmHg Raw ECG/ BLC On/ Notch On/ HF 0.05 Hz/LF 20 Hz

4X 80 mS Post J -



REMARKS:

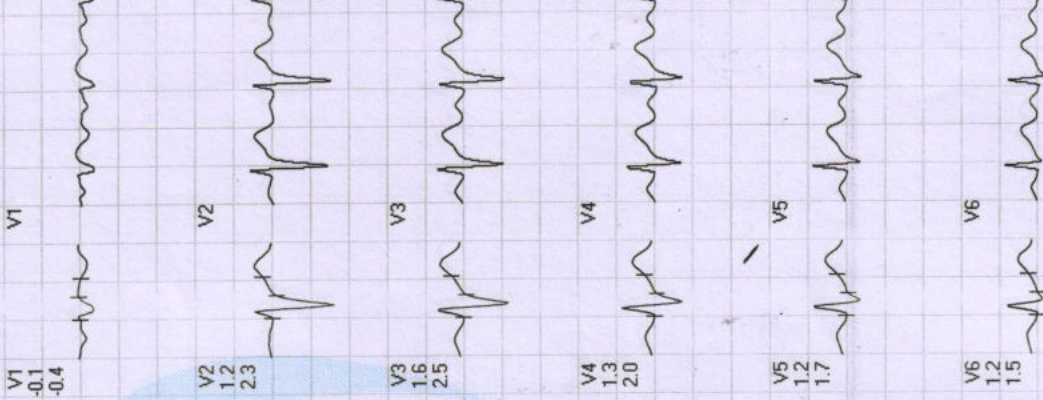



Date: 10-Dec-2022 03:02:55 PM METS: 4.7/120 bpm 67% of THR BP: 140/90 mmHg Raw ECG/ BLC On/ Notch On/ HF 0.05 Hz/LF 20 Hz

ExTime: 03:00 17 mpt 10.0%  
25 mm/sec. 1.0 Cm/mv

4X

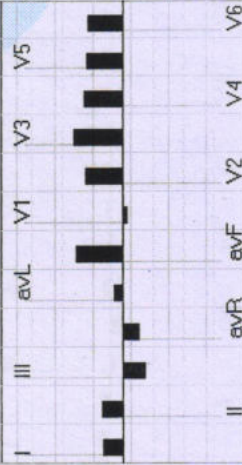
80 mS Post J



# दिवाकर डायग्नोस्टिक सेंटर

E-7/636, प्रजाब नेशनल बँक के पास, मैन रोड, अरेरा कालोनी भोपाल ( म.प्र. )

फोन: 0755-2465288, 0755-3520545 मो: 9826340190




REMARKS:



Ext Time: 06:00 2.5 mph, 12.0%

Date: 10-Dec-2022 03:02:55 PM METS: 7.1/139 bpm 78% of THR BP: 150/98 mmHg Raw ECG/BLC On/ Natch On/ HF 0.05 Hz/LF 20 Hz

4X 60 mS Post J



# दिवाकर डायग्नोस्टिक सेंटर

E-7/636, पंजाब नेशनल बैंक के पास, सैन रोड, अरेरा कॉलोनी भोपाल ( म.प्र. )  
फोन: 0755-2465288, 0755-3520545 मो: 9826340190

I	II	III	avR	avL	avF	V1	V2	V3	V4	V5	V6
0.4	0.3	-0.1	-0.3	0.2	0.1	0.1	0.9	0.9	0.5	0.3	0.2
1.3	0.8	-0.5	-1.1	0.9	0.1	0.1	2.4	2.4	1.8	1.6	1.2

REMARKS:



PeakEx

Ex Time: 06.16 3.4 mph 14.0%  
25 mm/Sec. 1.0 cm/mV

Diwakar Diagnostic Centre

908/ATUL KULKARNI / 42 Yrs / M

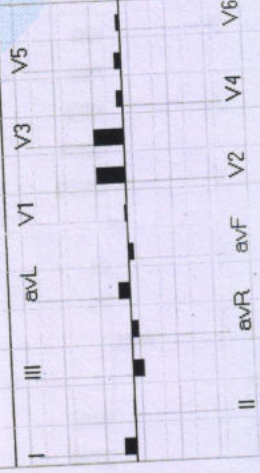
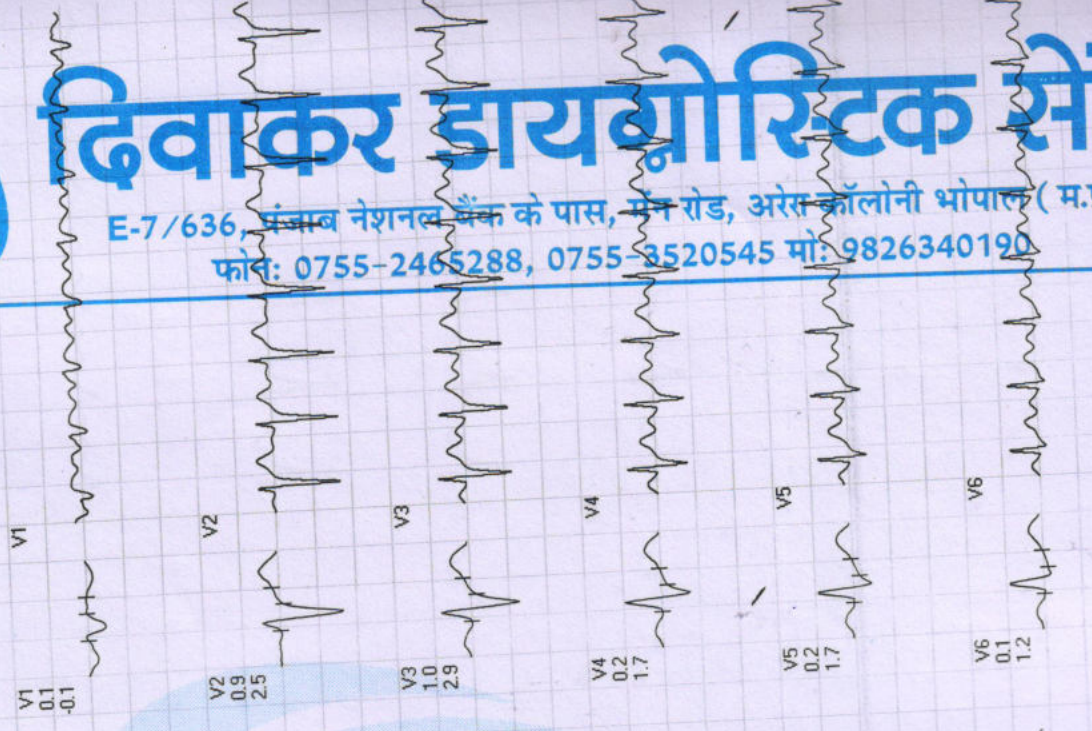

Date: 10-Dec-2022 03:02:55 PM

METS: 7.4/146 bpm 82% of THR BP: 150/98 mmHg

Raw ECG/BLC On/ Natch On/ HF 0.05 Hz/LF 20 Hz

4X

60 mS Post J



REMARKS:

# दिवाकर डायग्नोस्टिक सेंटर

E-7/636, पंचाब नेशनल बैंक के पास, मंग रोड, अरेस कॉलोनी भोपाल ( म.प्र. )

फोन: 0755-2465288, 0755-3520545 मो: 9826340190

(GEM218180307)(A)Allengers



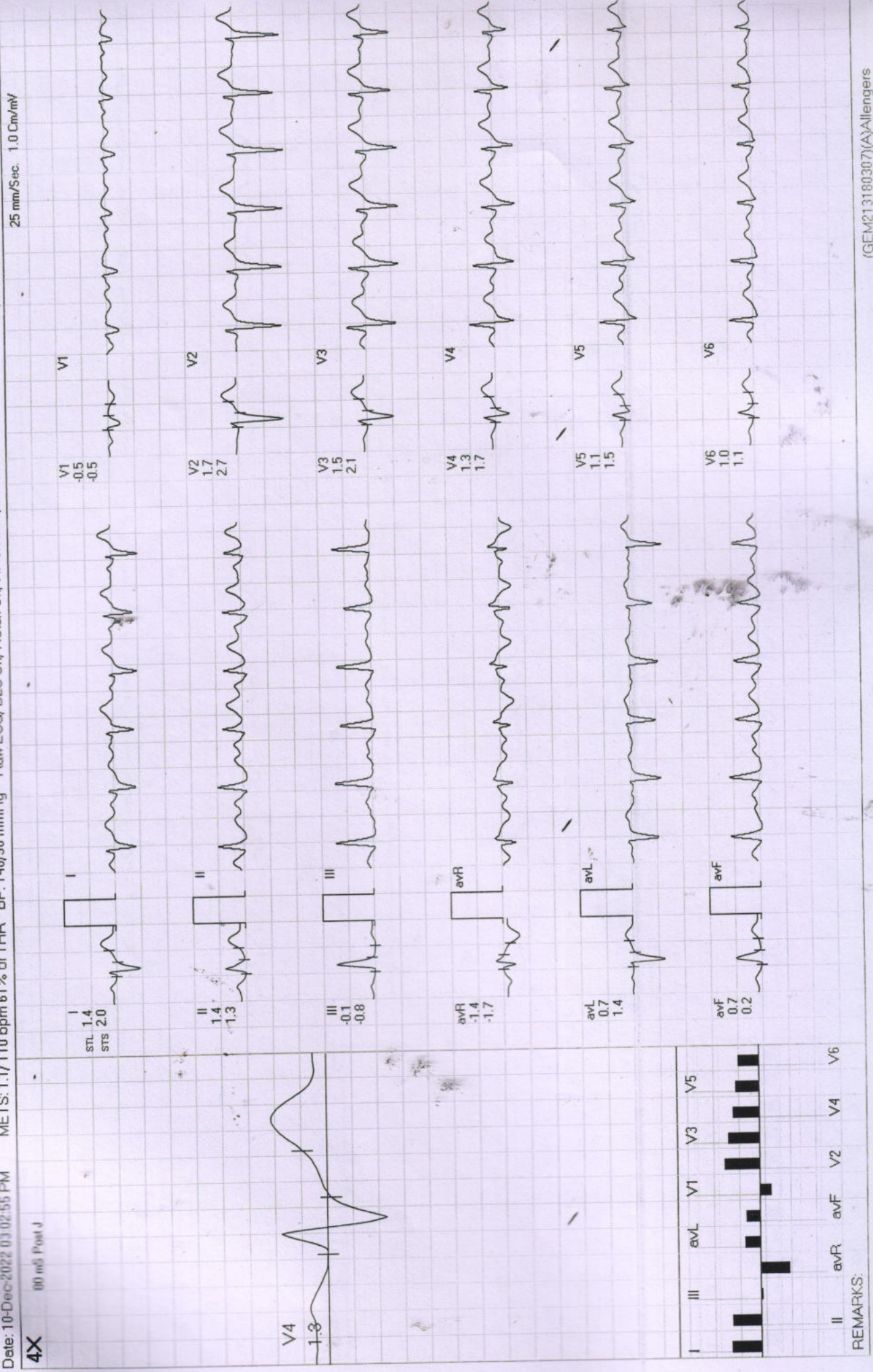
Recovery : ( 01:00 )

Diwakar Diagnostic Centre

908 / ATUL KULKARNI / 42 Yrs / M

ExTime: 06:16 0.0 mph, 0.0%

Date: 10-Dec-2022 03:02:55 PM METS: 1.1/110 bpm 61% of THR BP: 140/90 mmHg Raw ECG/BLC On/ Notch On/ HF 0.05 Hz/LF 20 Hz



REMARKS:





Recovery : ( 02:00 )

# Diwakar Diagnostic Centre

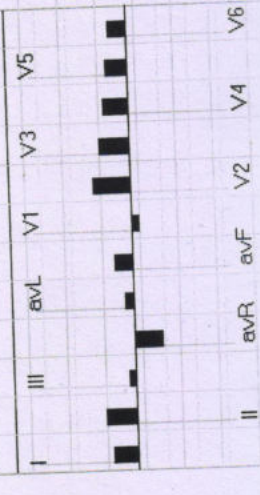

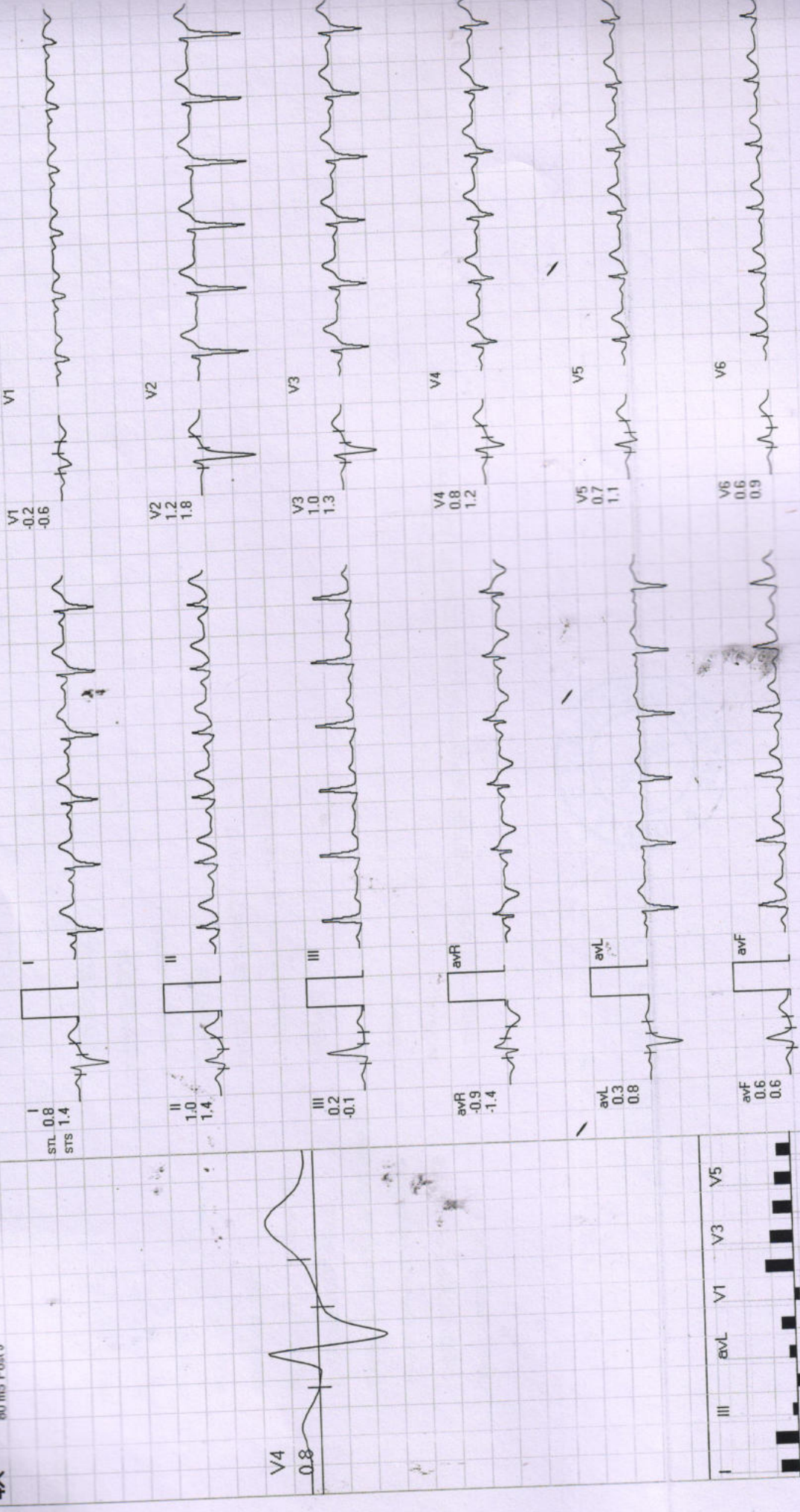
908 / ATUL KULKARNI / 42 Yrs / M

ExTime: 06:16 0.0 mph, 0.0%

25 mm/Sec. 1.0 Cm/mV

Date: 10-Dec-2022 03:02:55 PM METS: 1.0/109 bpm 61% of THR BP: 130/80 mmHg Raw ECG/BLC On/ Notch On/ HF 0.05 Hz/LF 20 Hz

4X 80 mS Post J



REMARKS: